

# Adalimumab in Recalcitrant Severe Psoriasis Associated with Atopic Dermatitis

Savas Yayli<sup>a</sup> Nathalie Irla<sup>b</sup> Nikhil Yawalkar<sup>b</sup>

<sup>a</sup>Department of Dermatology, School of Medicine, Karadeniz Technical University, Trabzon, Turkey; <sup>b</sup>Department of Dermatology, Inselspital, Bern University Hospital and University of Bern, Bern, Switzerland

## Key Words

Adalimumab · Psoriasis · Atopic dermatitis

## Abstract

Tumor necrosis factor- $\alpha$  inhibitors may induce various cutaneous side effects including eczematous-like lesions. The management of such side effects can be challenging. Herein, we report a case of a 55-year-old man who had a flare-up and subsequent improvement of atopic dermatitis during treatment of severe psoriasis with adalimumab.

© 2013 S. Karger AG, Basel

## Introduction

While the efficacy of tumor necrosis factor (TNF)- $\alpha$  inhibitors for the treatment of chronic plaque psoriasis has been well established, their therapeutic benefits in atopic dermatitis (AD) has remained controversial [1–3]. In addition, some reports, including large case series, have even described the induction of eczematous and AD-like lesions by TNF- $\alpha$  inhibitors and have advised against their use in patients with an atopic constitution and eczema [4–7]. We here report a case on the management of psoriasis associated with AD using adalimumab.

Savas Yayli, MD  
Department of Dermatology, School of Medicine  
Karadeniz Technical University  
TR-61080 Trabzon (Turkey)  
E-Mail savasyayli@gmail.com

## Case Report

A 55-year-old man with long-standing severe recalcitrant plaque psoriasis was treated with an 80-mg loading dose of adalimumab, and thereafter 40 mg every other week. The patient had an atopic constitution with a personal history of allergic rhinoconjunctivitis and asthma, and he was concomitantly suffering from slightly active AD in his armpits. There was no family history of atopic disorders. After 3 months of therapy with adalimumab, a marked improvement of his psoriasis (PASI 75 response) was observed (fig. 1a, b). However, together with this improvement, new eczematous lesions had begun to flare up on his neck, armpits, and hands (fig. 2a–d). Localization of the eczematous lesions was characteristic of a flare-up of AD. His atopic constitution was further substantiated by positive skin prick tests to house dust mites, cats, grass and birch pollen as well as by raised total IgE levels (253 kU/l; normal value <100 kU/l). Therapy with adalimumab was continued due to a beneficial response of the psoriatic lesions, while the eczematous lesions were temporarily treated with topical corticosteroids (mometasone ointment for 3 weeks daily and twice weekly thereafter). The topical corticosteroids were discontinued after 6 weeks. Together with further amelioration of the psoriatic lesions (fig. 1c), a marked improvement of his AD was subsequently also observed during the following 5 months (fig. 2e–h).

## Discussion

Psoriasis and AD belong to the most frequent chronic inflammatory skin diseases. The clinical and pathophysiological features between psoriasis and AD differ substantially and an inverse association of both diseases has also been reported [8–11]. Although the simultaneous occurrence of both diseases appears to be rare, few patients, as described in this case, may concomitantly have psoriasis and AD. Indeed, genomic studies indicate that psoriasis and AD may have a couple of shared genes which regulate the proliferation and differentiation of epidermal cells and modulate general cutaneous inflammatory mechanisms [12, 13]. In addition, both diseases are characterized by T-cell-dominated dermal infiltrates and a good responsiveness to T-cell-directed agents. Recent studies have further delineated the phenotype of the infiltrating T cells in psoriasis and AD [10, 11]. While psoriasis is mainly mediated by Th1 and Th17 cells, AD is driven by Th2 and Th22 cells. Furthermore, Th1 cells producing cytokines like IFN- $\gamma$  and TNF- $\alpha$  are also thought to contribute to the chronic phase of AD.

The recognition of TNF- $\alpha$  as a key regulator of inflammation in general and its possible involvement in the development of chronic AD lesions also led to the use of TNF- $\alpha$  inhibitors in AD [14]. While some reports have failed to show substantial beneficial responses, others have demonstrated successful treatment of recalcitrant AD by TNF- $\alpha$  inhibitors [1–3]. Although a flare-up of AD was initially noted in our patient, therapy with adalimumab could be continued and ultimately lead to amelioration of both psoriasis and AD. To our knowledge, this is the first case reporting the successful management of psoriasis associated with AD using adalimumab.

As noted in our case, some reports, including large case series, have also described the induction of eczematous and AD-like lesions by TNF- $\alpha$  inhibitors [4–7]. These eczematous eruptions were either newly developed or flared up in patients with an atopic constitution. Most of these AD-like reactions were of moderate intensity and were managed well with topical corticosteroid or calcineurin inhibitors [5, 6], although severe cases necessitating hospitalization or discontinuation of treatment have also been reported [7].

In conclusion, physicians should be aware that eczematous lesions may flare up during the therapy with TNF- $\alpha$  inhibitors, especially in patients with an atopic constitution. However, these flares can often be managed without withdrawing the TNF- $\alpha$  inhibitor and by using topical corticosteroids. Furthermore, based on some similarities in the inflammatory process of both chronic AD and psoriasis, as well as the encouraging therapy results in at least some cases, TNF- $\alpha$  inhibitors may even be beneficial for patients with severe AD at a chronic stage.

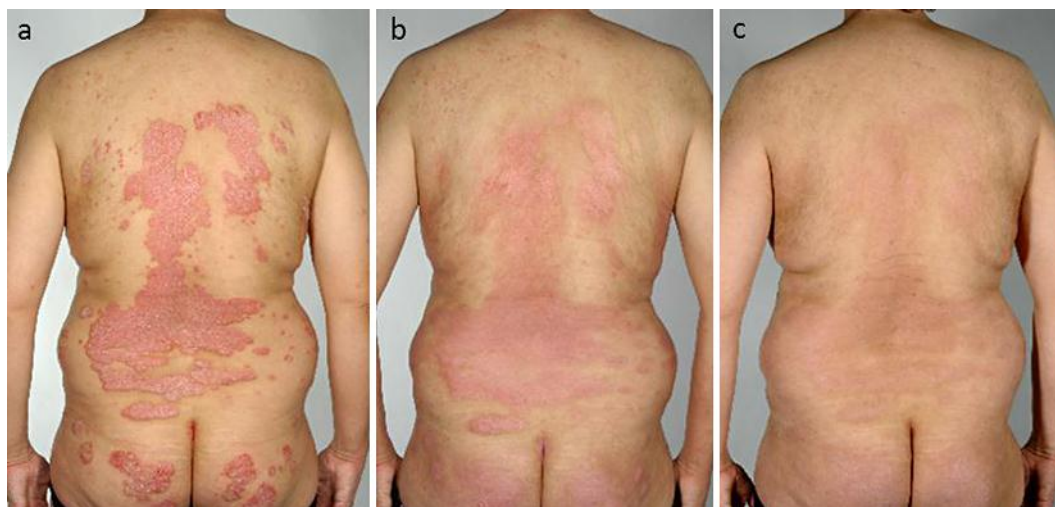### Disclosure Statement

Nikhil Yawalkar has served as a consultant to Abbott.

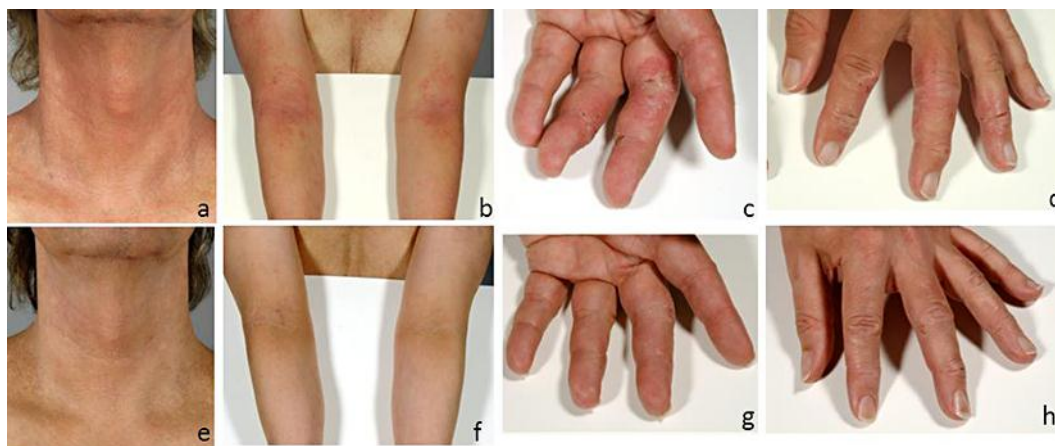
### References

- 1 Jacobi A, Antoni C, Manger B, et al: Infliximab in the treatment of moderate to severe atopic dermatitis. *J Am Acad Dermatol* 2005;52:522–526.
- 2 Cassano N, Loconsole F, Coviello C, et al: Infliximab in recalcitrant severe atopic eczema associated with contact allergy. *Int J Immunopathol Pharmacol* 2006;19:237–240.
- 3 Rullan P, Murase J: Two cases of chronic atopic dermatitis treated with soluble tumor necrosis factor receptor therapy. *J Drugs Dermatol* 2009;8:873–876.
- 4 Davaine AC, Saraux A, Prigent S, et al: Cutaneous events during treatment of chronic inflammatory joint disorders with anti-tumor necrosis factor alpha: a cross-sectional study. *J Eur Acad Dermatol Venereol* 2008;22:1471–1477.
- 5 Chan JL, Davis-Reed L, Kimball AB: Counter-regulatory balance: atopic dermatitis in patients undergoing infliximab infusion therapy. *J Drugs Dermatol* 2004;3:315–318.
- 6 Mangge H, Gindl S, Kenzian H, et al: Atopic dermatitis as a side effect of anti-tumor necrosis factor-alpha therapy. *J Rheumatol* 2003;30:2506–2507.
- 7 Dumont-Berset M, Laffitte E, Gerber C, et al: Eczematous drug eruption after infliximab. *Br J Dermatol* 2004;151:1272–1273.
- 8 Henseler T, Christophers E: Disease concomitance in psoriasis. *J Am Acad Dermatol* 1995;32:982–986.
- 9 Guttman-Yassky E, Nogales KE, Krueger JG: Contrasting pathogenesis of atopic dermatitis and psoriasis. 1. Clinical and pathologic concepts. *J Allergy Clin Immunol* 2011;127:1110–1118.
- 10 Guttman-Yassky E, Nogales KE, Krueger JG: Contrasting pathogenesis of atopic dermatitis and psoriasis. 2. Immune cell subsets and therapeutic concepts. *J Allergy Clin Immunol* 2011;127:1420–1432.
- 11 Eyerich S, Onken AT, Weidinger S, et al: Mutual antagonism of T cells causing psoriasis and atopic eczema. *N Engl J Med* 2011;365:231–238.
- 12 Wilsman-Theis D, Hagemann T, Jordan J, et al: Facing psoriasis and atopic dermatitis: are there more similarities or more differences? *Eur J Dermatol* 2008;18:172–180.
- 13 Cookson WO, Ubhi B, Lawrence R, et al: Genetic linkage of childhood atopic dermatitis to psoriasis susceptibility loci. *Nat Genet* 2001;27:372–373.
- 14 Grewe M, Walther S, Gyufko K, et al: Analysis of the cytokine pattern expressed in situ in inhalant allergen patch test reactions of atopic dermatitis patients. *J Invest Dermatol* 1995;105:407–410.

Yayli et al.: Adalimumab in Recalcitrant Severe Psoriasis Associated with Atopic Dermatitis



**Fig. 1.** Marked improvement of psoriasis during treatment with adalimumab. **a** Before treatment. **b** After 3 months. **c** After 8 months.



**Fig. 2.** **a–d** Flare-up of AD at month 3. **e–h** Subsequent amelioration of AD after application of topical corticosteroids for 6 weeks and continuing treatment with adalimumab with a few remaining lesions after 8 months.