Eur J Pediatr (2016) 175:557–561
DOI 10.1007/s00431-015-2671-9

ORIGINAL ARTICLE

Acute hemorrhagic edema of young children: a prospective case series

Alessandra Ferrarini[1] · Cecilia Benetti[1] · Pietro Camozzi[1] · Alessandro Ostini[1] · Giacomo D. Simonetti[1] · Gregorio P. Milani[2] · Mario G. Bianchetti[1] · Sebastiano A. G. Lava[3]

Received: 22 July 2015 / Revised: 4 November 2015 / Accepted: 16 November 2015 / Published online: 25 November 2015

Abstract Acute hemorrhagic edema of young children is a rare leukocytoclastic vasculitis that has been reported exclusively in small retrospective cases series, case reports, or quizzes. Considering that retrospective experience deserves confirmation in at least one observational prospective study, we present our experience with 16 children (12 boys and 4 girls, 5–28 months of age) affected by acute hemorrhagic edema. The patients were in good general conditions and with a low-grade or even absent fever. They presented with non-itching red to purpuric targetoid lesions not changing location within hours, with non-pitting and sometimes tender indurative swelling, and without mucous membrane involvement or scratch marks. Signs for articular, abdominal, or kidney involvement were absent. Antinuclear or antineutrophil cytoplasmic autoantibodies were never detected. The cases were managed symptomatically as outpatients and fully resolved within 4 weeks or less. No recurrence or familiarity was noted.

Conclusion: This is the first prospective evaluation of hemorrhagic edema. Our findings emphasize its distinctive tetrad: a well-appearing child; targetoid lesions that do not change location within hours; non-pitting, sometimes tender edema; complete resolution without recurrence.

What is known
- *Acute hemorrhagic edema of young children is considered a benign vasculitis.*
- *There have been ≈100 cases reported in small retrospective case series.*

What is new
- *The first prospective evaluation of this condition emphasizes its features: febrile prodrome; well-appearing child; targetoid lesions not changing location within hours; non-pitting, sometimes tender indurative edema; absent extracutaneous involvement; resolution within 3 weeks.*
- *Antineutrophil cytoplasmic autoantibodies do not play a pathogenic role.*

Keywords Acute hemorrhagic edema of young children · Antineutrophil cytoplasmic autoantibodies · Child · Finkelstein–Seidlmayer disease · Leukocytoclastic vasculitis

Communicated by David Nadal

Alessandra Ferrarini and Cecilia Benetti contributed equally to this work.

✉ Mario G. Bianchetti
mario.bianchetti@eoc.ch

Alessandra Ferrarini
Alessandra.Ferrarini@eoc.ch

Cecilia Benetti
ceciliabenetti@hotmail.it

Pietro Camozzi
camozzip@gmail.com

Alessandro Ostini
ostini.alessandro@gmail.com

Giacomo D. Simonetti
Giacomo.Simonetti@eoc.ch

Gregorio P. Milani
yoyobiancorosso@hotmail.com

Sebastiano A. G. Lava
sebastiano.lava@bluewin.ch

[1] Pediatric Department of Southern Switzerland, Bellinzona, Switzerland

[2] Present address: Foundation IRCCS Ca' Granda, Ospedale Maggiore Policlinico, Pediatric Emergency Department, Milan, Italy

[3] Present address: University Children's Hospital Berne, University of Berne, Berne, Switzerland

Introduction

Acute hemorrhagic edema of young children is an unusual vasculitis that affects children aged 4 months to 4 years [8, 9, 23]. The condition, which is often referred to as acute hemorrhagic edema of infancy [10], cockade purpura and edema, Finkelstein–Seidlmayer disease, or Henoch–Schönlein syndrome of early childhood, is surmised to be a variant of Henoch–Schönlein syndrome [8, 9, 23].

Acute hemorrhagic edema has been so far documented in case reports and in 14 small retrospective case series (published between 1979 and 2011) including 5 to 12 cases each [1–3, 5, 6, 8, 12–14, 16, 18, 19, 21, 22]. The mentioned 14 reports included 101 unrelated children (72 boys and 29 girls aged between 4 and 48, median 18 months) affected with acute hemorrhagic edema. The condition presented with targetoid lesions and non-pitting edema that developed within 24–48 h in a well-appearing child without relevant articular, abdominal, or renal involvement, resolved within approximately 1 ½ week and did not recur. Two thirds of the cases developed after a simple, mostly viral illness (rarely after a vaccination). The platelet count was determined in 27 cases and found to be mildly elevated in 20. Antinuclear autoantibodies, determined in 11 cases, were within normal ranges (antineutrophil cytoplasmic autoantibodies were never tested). The diagnosis was made on a clinical basis and confirmed by a skin biopsy disclosing a leukocytoclastic vasculitis in 42 cases (testing for IgA, performed in 25 skin specimens, was positive in 8).

The purposes of this article are to present our prospective experience with this vasculitis and to evaluate the relevance of circulating antineutrophil autoantibodies.

Patients and methods

Between December 2006 and December 2013, children presented to the Emergency unit, Pediatric Department of Southern Switzerland, with non-itching red to purpuric targetoid lesions were re-examined within 24 h by an experienced senior pediatrician (MGB) to confirm or infirm the diagnosis of acute hemorrhagic edema of young children. The diagnosis was made in children with purpuric targetoid lesions not changing location within hours, non-pitting indurative swelling, and absent mucous membrane involvement [8, 9]. A biopsy was not a prerequisite for diagnosis [8, 9].

The children underwent a careful structured skin and mucous membrane examination established in advance. Considerable weight was put on the presence of non blanching lesions such as targetoid lesions, pitting or non-pitting swelling (with or without induration and pain), mucous membrane involvement, scratch marks, and external genital involvement. The skin findings and their localization were carefully recorded in a standard, predefined way. Furthermore, the patients were examined with emphasis on vital signs and abdominal or articular findings. Acute illnesses or vaccinations preceding the skin lesions by ≤10 days were considered triggers. An inquiry was also made about personal or family (in first- or second-degree relatives) history of similar lesions and maternal HIV and syphilis testing during pregnancy. Besides blood white cell (population reference $3.0–12.5\times10^9$/L) and platelet (reference $150–450\times10^9$/L) counts, C-reactive protein (reference ≤5 mg/L), alanine and aspartate aminotransferase (reference ≤35 U/L), creatine kinase (reference ≤400 U/L), creatinine (reference age dependent), and antinuclear and IgG antineutrophil cytoplasmic autoantibodies (by indirect immunofluorescence) were determined in all cases. A dipstick urinalysis for hematuria and proteinuria was also performed. Testing for *Mycoplasma pneumoniae* by polymerase chain reaction in a nasopharyngeal swab was performed in children with history of lower respiratory tract illness.

Advice for no treatment or treatment, if needed, with acetaminophen or ibuprofen and against systemic steroids or antihistamines was given [9].

In all cases, the progression was evaluated at our institution or by an interview with the family pediatrician or the relatives of the child. Finally, a follow-up telephone interview with the relatives was conducted 4 months later concerning relapses or new cases within the family.

The investigator-initiated, non-commercially sponsored survey had been approved by our institutional review board, and informed consent was obtained from all participants. Anonymized patient information was used for data analysis. The one-sample Mann–Whitney–Wilcoxon test and the χ^2 goodness of fit test were used to compare the results with those of the general population. Significance was assumed when $P<0.05$.

Results

The diagnosis of acute hemorrhagic edema of young children was suspected in 18 unrelated Caucasian children aged between 5 and 28 months. An experienced pediatrician made the diagnosis of urticaria multiformis in 2 children (aged 11 and 20 months) and that of acute hemorrhagic edema in the remaining 16 children (Table 1). The diagnosis was always made clinically and no skin biopsy was necessary. The children presented with large, round, red to purpuric target-like plaques, and often tender ($N=5$) non-pitting edema distributed over the cheeks, ears, and lower and upper extremities, with relative sparing of the trunk, as shown in Fig. 1. Plaques and edema involving the scrotum and the penis were noted in two boys. Mucous membrane involvement or scratch marks were never observed. Poor eye contact, pallor, cyanosis and coldness of the digits, altered capillary refill, blood pressure or respiratory rate, respiratory effort, yellow scleral

Table 1 Clinical and laboratory data of 16 patients affected with acute hemorrhagic edema of young children

Age, months	13 [9–18]
Gender, ♂:♀	12:4▲
Prodrome	
Upper respiratory tract illness, *N*	5
Lower respiratory tract illness[a], *N*	2
Simple febrile illness, *N*	2
Diarrhea, *N*	2
Urinary tract infection, *N*	1
Immunization[b], *N*	1
Rectal body temperature >38.0 °C	4
White blood cell count	
Absolute value, 10^9/L	8.6 [7.4–10.8]
>12.5×10^9/L	3
Platelet count	
Absolute value, 10^9/L	358‡ [320–484]
>450×10^9/L, *N*	7
C-reactive protein >5 mg/L	9
Plasma aminotransferases increased, *N*	0
Plasma creatine kinase increased, *N*	0
Plasma creatinine increased, *N*	0
Circulating autoantibodies	
Antinuclear, *N*	0
Cytoplasmic, *N*	0
Urinalysis pathological, *N*	0
Duration of skin lesions	
Absolute value, weeks	2.0 [1.5–3.0]
>4.0 weeks, N	0

Data are given either as relative frequency or as median and interquartile range (which includes half of the data)

▲ $P<0.05$; ‡ $P<0.01$ versus general population

[a] Molecular testing for *Mycoplasma pneumoniae* was negative in these patients

[b] Against diphtheria, tetanus, pertussis, poliomyelitis, and *Haemophilus influenzae* type B

discoloration, lymphadenopathy, enlarged liver or spleen, abdominal pain, and joint pain or swelling were never noted. In 12 (75 %) cases, the lesions developed within 10 days after an infectious disease (Table 1). Many cases had mild thrombocytosis or increased C-reactive protein. White blood cell count, aminotransferases, creatine kinase, creatinine, IgG antinuclear and antineutrophil cytoplasmic autoantibodies, and urinalysis were normal. The children never had previous episodes or positive family history of acute hemorrhagic edema or a pathological maternal HIV or syphilis screening during pregnancy. All cases were managed as outpatients. Acetaminophen or ibuprofen were prescribed, respectively, in five (31 %) and four (25 %) cases. In all cases, the lesions fully resolved within 4 weeks. The 4-month follow-up interview never disclosed relapses or new cases within the family.

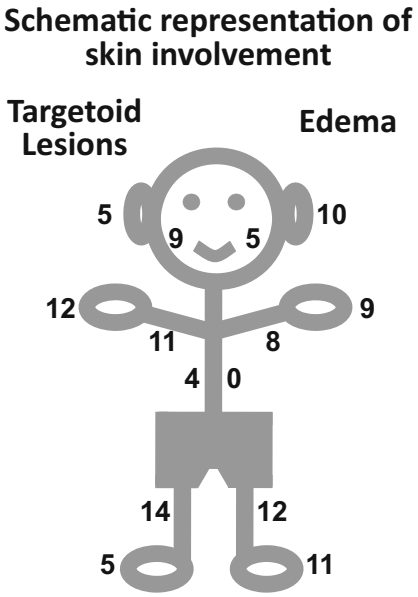

Fig. 1 Distribution and number of skin lesions among 16 cases (12 boys and 4 girls) of acute hemorrhagic edema of young children. Edema was tender in five cases. Targetoid lesions and edema involving the scrotum and the penis were noted in two boys. Mucous membrane involvement or scratch marks were never observed

There were no missing data for the 16 cases of acute hemorrhagic edema included in this survey.

Discussion

The results of this prospective investigation emphasize the distinctive features of acute hemorrhagic edema of young children: a febrile prodrome (or, more rarely, an immunization); a well-appearing child with a low-grade or absent fever, without pruritus and scratch marks; targetoid lesions that do not change location within hours and mostly spare the trunk; non-pitting, sometimes tender edema; and absent mucous membrane and extracutaneous involvement. Furthermore, the condition mostly resolves within 3 weeks and does not recur or run in families. Finally, laboratory tests do not disclose kidney, liver, or muscle involvement and circulating antinuclear or IgG antineutrophil cytoplasmic autoantibodies and often reveal, like in other vasculitides, a marginal increase in platelet count and inflammatory markers.

It has been suggested that acute hemorrhagic edema is often triggered by *M. pneumoniae* [7]. Our study suggests that this association is uncommon.

The differential diagnosis includes non-accidental skin bruising, drug-induced skin lesions, syphilis, systemic capillary leak syndrome, discolored leg syndrome after vaccination, lesions of systemic bacterial infections such as meningococcal and non-meningococcal Waterhouse–Friderichsen syndrome and Pseudomonas sepsis, atypical Henoch–Schönlein

Table 2 Main differential diagnosis of apparently targetoid skin lesions (= polycyclic) skin lesions, i.e. lesions arranged in concentric circles resembling a bull's eye, in childhood

Condition	Targetoid lesions	Mucous membrane involvement	Pruritus or scratch marks
Erythema multiforme[a]	Targetoid lesions that persist at the same location for days and follow a symmetric distribution with predilection for the extensor surfaces of the extremities	Erosions with fibrin membranes, occasionally ulcerations with predilection for lips, oropharynx, nose, and conjunctivae and anogenital region	None
Acute hemorrhagic edema of young children	Targetoid lesions that persist at the same location for days and involve cheeks, ears, and extremities	Very uncommon	None
Urticaria	Apparently targetoid lesions with clear centers and an outer red zone that change location within hours	Swelling of the tongue, lips, throat, and area around the eyes is common (no erosions or blisters)	Common
Urticaria muliformis	Variant of urticaria with apparently targetoid lesions characterized by annular wheals with dusky centers that change location within hours		

[a] It has been suggested that, in children 2–(3)years or less of age, acute hemorrhagic edema is commonly misdiagnosed as erythema multiforme without mucous membrane involvement (in this age group acute hemorrhagic edema is likely more frequent than erythema multiforme). For these cases, the term erythema multiforme infantile has been sometimes advocated [4]

syndrome and especially conditions presenting with apparently targetoid lesions (Table 2) such as urticaria, urticaria multiformis, and erythema multiforme [4, 8, 9, 11, 15, 20, 23].

In everyday practice (Fig. 2), the diagnosis is made in well-appearing children ≤4 years presenting with seemingly frightening red to purpuric targetoid lesions and indurative non-pitting swelling [8, 9, 23]. Like in Henoch–Schönlein syndrome [23], testing for antinuclear and antineutrophil autoantibodies is negative and the diagnosis is made clinically without the need for routine biopsy (however, many dermatologists perform a biopsy in any dermatosis suspected of being a vasculitis).

Paracetamol, nonsteroidal anti-inflammatory agents, or antimicrobials have been prescribed in many children with acute hemorrhagic edema or Henoch–Schönlein syndrome. However, these conditions do not recur following re-exposition, indicating that drugs play a role in a very small minority of cases [8, 9].

Acute hemorrhagic edema and Henoch–Schönlein syndrome are not considered familial diseases [8, 9, 23]. Very recently, however, we described [17] a family in which four members in two generations had acute hemorrhagic edema (obviously, these patients were not included in this analysis).

Because of the benign course and spontaneous resolution, treatment is unnecessary. Often antibiotics are initially prescribed but are withdrawn after obtaining negative culture results. Once the condition is recognized, reassurance and observation are crucial.

In conclusion, this prospective case series with a suitably long follow-up confirms the customarily recognized features of acute hemorrhagic edema of young children and demonstrates for the first time that antineutrophil cytoplasmic autoantibodies are not involved in its pathogenesis.

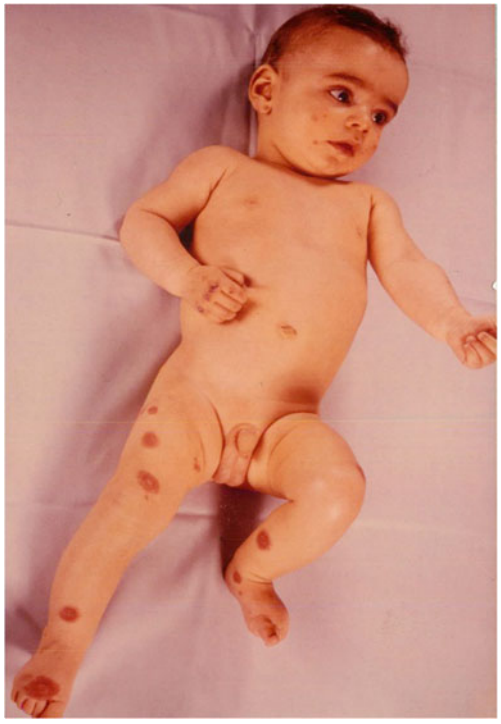

Fig. 2 Targetoid skin lesions in a well-doing 9-month-old boy affected with acute hemorrhagic edema of young children. A technically difficult venipuncture accounts for the lesions on the right hand (permission to publish the picture was obtained)

Authors' contributions Alessandra Ferrarini, Mario G. Bianchetti, and Sebastiano A. G. Lava participated in the study concept and design. Cecilia Benetti, Pietro Camozzi, Alessandro Ostini, Giacomo D. Simonetti, and Gregorio P. Milani participated in the acquisition, analysis, and interpretation of data. Giacomo D. Simonetti and Mario G. Bianchetti participated in the statistical analysis. Alessandra Ferrarini, Pietro Camozzi, Alessandro Ostini, and Gregorio P. Milani participated in the drafting of the manuscript. Cecilia Benetti, Giacomo D. Simonetti, Gregorio P. Milani, Mario G. Bianchetti, and Sebastiano A. G. Lava participated in the critical revision of the manuscript.

Compliance with ethical standards

Funding None.

Conflict of interest The authors declare that they have no competing interests.

Ethical approval All procedures performed in studies involving human participants were in accordance with the ethical standards and with the 1964 Helsinki declaration and its later amendments.

Informed consent Informed consent was obtained from all participants.

References

1. Alp H, Artaç H, Alp E, Reisli I (2009) Acute infantile hemorrhagic edema: a clinical perspective (report of seven cases). Marmara Med J 22:155–161
2. Al-Sheyyab M, El-Shanti H, Ajlouni S, Sawalha D, Daoud A (1995) The clinical spectrum of Henoch-Schönlein purpura in infants and young children. Eur J Pediatr 154:969–972
3. Amitai Y, Gillis D, Wasserman D, Kochman RH (1993) Henoch-Schönlein purpura in infants. Pediatrics 92:865–867
4. Bianchetti MG (2015) Quiz FMH 60. Paediatrica 26:46–47
5. Cabrera Roca G, Domínguez Ortega F, Perdomo Mesa E, Medina Calvo F, Báez Marrero O (1998) Edema agudo hemorrágico del lactante: Presentation de 5 casos. An Esp Pediatr 48:73–75
6. Çaksen H, Odabaş D, Kösem M, Arslan S, Oner AF, Ataş B, Akçay G, Ceylan N (2002) Report of eight infants with acute infantile hemorrhagic edema and review of the literature. J Dermatol 29: 290–295
7. Di Lernia V (2009) Mycoplasma pneumoniae: an aetiological agent of acute haemorrhagic oedema of infancy. Australas J Dermatol 55: e69–e70
8. Fiore E, Rizzi M, Ragazzi M, Vanoni F, Bernasconi M, Bianchetti MG, Simonetti GD (2008) Acute hemorrhagic edema of young children (cockade purpura and edema): a case series and systematic review. J Am Acad Dermatol 59:684–695
9. Fiore E, Rizzi M, Simonetti GD, Garzoni L, Bianchetti MG, Bettinelli A (2011) Acute hemorrhagic edema of young children: a concise narrative review. Eur J Pediatr 170:1507–1511
10. Jacobzone C, Plantin-Eon I, Vic P, Broussine L, Plantin P (2001) Plaidoyer pour renommer «l'oedème aigu hémorragique du nourrisson». Arch Pediatr 8:770–771
11. Kemmeren JM, Vermeer-de Bondt PE, van der Maas NA (2009) Discolored leg syndrome after vaccination–descriptive epidemiology. Eur J Pediatr 168:43–50
12. Krause I, Lazarov A, Rachmel A, Grunwald MM, Metzker A, Garty BZ, Halevy S, Nitzan M (1996) Acute haemorrhagic oedema of infancy, a benign variant of leucocytoclastic vasculitis. Acta Paediatr 85:114–117
13. Lambert D, Laurent R, Bouilly D, Saint-Mont C, Estavoyer JM, Agache P, Chapuis JL (1979) Oedème aigu hémorragique du nourrisson. Données immunologiques et ultrastructurales. Ann Dermatol Venereol 106:975–987
14. Legrain V, Lejean S, Taïeb A, Guillard JM, Battin J, Maleville J (1991) Infantile acute hemorrhagic edema of the skin: study of ten cases. J Am Acad Dermatol 24:17–22
15. Milani GP, Dellepiane RM, Castellazzi ML, Mazzoni MB, Bianchetti MG, Fossali EF (2013) Episodic idiopathic systemic capillary leak syndrome in a girl. Pediatr Int 55:e81–e82
16. Moradinejad MH, Entezari P, Mahjoub F, Ziaee V (2011) Acute hemorrhagic edema of infancy; a report of five Iranian infants and review of the literature. Iran J Pediatr 21:107–112
17. Ostini A, Ramelli GP, Mainetti C, Bianchetti MG, Ferrarini A (2015) Recurrent Finkelstein-Seidlmayer disease in four first-degree relatives. Acta Derm Venereol 95:622–623
18. Pérez Fernández F, García Aldana D, Torres Borrego J, Luque Moreno M (2006) Edema agudo hemorrágico infantil: experiencia con cinco casos. Acta Pediatr Esp 64:399–401
19. Poyrazoğlu HM, Per H, Gündüz Z, Düşünsel R, Arslan D, NarIn N, Gümüş H (2003) Acute hemorrhagic edema of infancy. Pediatr Int 45:697–700
20. Robl R, Robl M, Marinoni LP, Abagge KT, Carvalho VO (2014) Target-shaped edematous purple lesions: is it child abuse? Arch Dis Child 99:44–45
21. Saraçlar Y, Tinaztepe K, Adalioğlu G, Tuncer A (1990) Acute hemorrhagic edema of infancy (AHEI)—a variant of Henoch-Schönlein purpura or a distinct clinical entity? J Allergy Clin Immunol 86: 473–483
22. Suehiro RM, Soares BS, Eisencraft AP, Campos LM, Silva CA (2007) Acute hemorrhagic edema of childhood. Turk J Pediatr 49: 189–192
23. Ting TV (2014) Diagnosis and management of cutaneous vasculitis in children. Pediatr Clin North Am 61:321–346