

## Short Research Communication

# *Brucella melitensis* prosthetic joint infection

Domenica Flury<sup>1</sup>, Henrik Behrend<sup>2</sup>, Parham Sendi<sup>3</sup>, Matthias von Kietzell<sup>1</sup>, Carol Strahm<sup>1</sup>✉

1. Department of Infectious Diseases, Cantonal Hospital of St. Gallen, St. Gallen;
2. Department of Orthopaedics and Traumatology, Cantonal Hospital of St. Gallen, St. Gallen;
3. Department of Infectious Diseases, Bern University Hospital, University of Bern, Bern, Switzerland.

✉ Corresponding author: Carol Strahm, M.D., Department of Infectious Diseases, Cantonal Hospital of St. Gallen, 9007 St. Gallen, Switzerland Tel. +41 71 494 26 33 Fax. +41 71 494 63 39 Carol.Strahm@kssg.ch

© Ivyspring International Publisher. This is an open access article distributed under the terms of the Creative Commons Attribution (CC BY-NC) license (<https://creativecommons.org/licenses/by-nc/4.0/>). See <http://ivyspring.com/terms> for full terms and conditions.

Published: 2017.04.05

## Abstract

Periprosthetic joint infection (PJI) due to *Brucella* spp. is rare. We report a case in a 75-year-old man and review 29 additional cases identified in a literature search. The diagnosis of *Brucella* PJI is challenging, in particular in non-endemic countries. Serological tests prior to joint aspiration or surgical intervention are reasonable. Involvement of infection control and timely information to laboratory personnel is mandatory upon diagnosis. There is no uniform treatment concept, neither with respect to surgical intervention nor for the duration of antimicrobials. Most cases have a successful outcome, irrespective of surgical modality, and with an antimicrobial combination regimen for 12 or more weeks.

Key words: *Brucella*, Periprosthetic joint infection

## Intrroduction

Periprosthetic joint infection (PJI) due to *Brucella* is rare. We present a case of PJI due to *Brucella melitensis* and review the literature with respect to clinical presentation, diagnosis and treatment.

## Case Report

A 75-year-old man from Turkey presented with a six-months history of progressing knee pain. His personal history included total right knee arthroplasty (TKA) because of osteoarthritis 12 years prior to, and one stage exchange due to aseptic loosening 4 years prior to admission. On presentation, radiographs of the right knee showed loosening of the prosthesis with migration of the tibial component (Figure 1a, b). Before referral to our center, *B. melitensis* grew in synovial fluid specimen obtained via arthrocentesis.

The patient was born and raised in Turkey: He had moved to Switzerland at the age of 44. He reported to spend his summers in Turkey. There, he owns a house in a rural area, and commonly ingests

fresh unpasteurized cheese and milk.

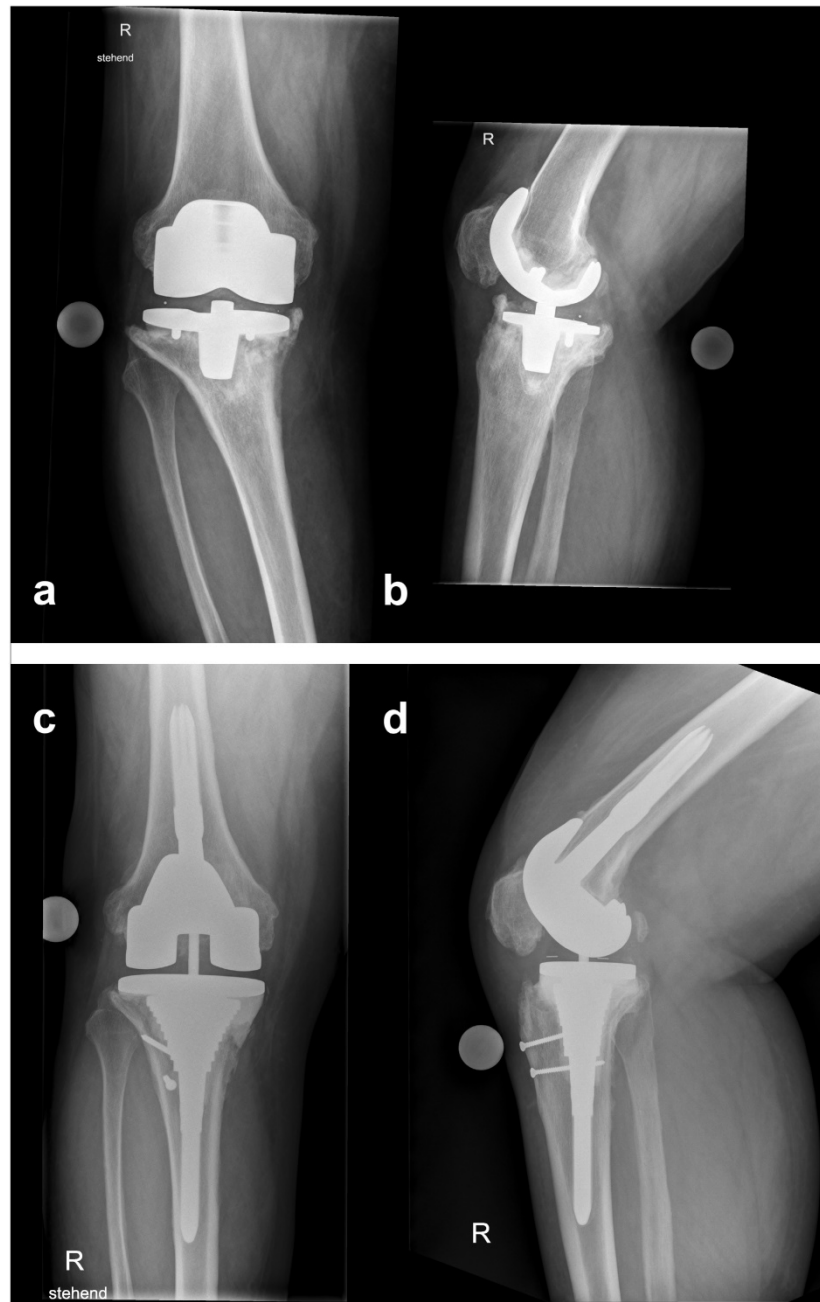
On presentation, he was afebrile and no episodes of fever or night sweats were reported. Blood tests showed a C-reactive protein (CRP) of 18 mg/l (norm < 8 mg/l); leukocytes and thrombocytes were within normal range. Chest and lumbar radiographs, as well as abdominal ultrasound, were normal. Two sets of blood cultures remained negative. Serological test for antibodies against *Brucella* spp. were positive (IgG/IgA of 1:240 U/mL, normal < 20 U/ml; *Brucella* IgG/M/A Serion ELISA classic, SERION® Immunologics, Wuerzburg, Germany).

A combined antimicrobial therapy consisting of doxycycline 100 mg twice per day and intravenous (IV) gentamicin 5 mg/kg once daily was started one week prior to surgery. The surgical plan included a two-stage exchange with a short interval. After removal of the implant, a mobile antibiotic loaded spacer (containing gentamicin and vancomycin) was implanted. Surgery was carried out under aerosol isolation precautions and laboratory personnel were

informed about possible risk of exposure. *B. melitensis* grew in 3, and *Propionibacterium acnes* in 4 out of 10 obtained biopsies, sonication was negative. Thus, penicillin was added to the regimen (24 million units IV divided in 6 doses per day). After 2.5 weeks, a revision TKA was implanted (LCS Revision®, DePuy Synthes, Warsaw, IN). The further clinical course was uneventful. In the postoperative period, treatment with rifampin 450 mg twice per day was added, and gentamicin discontinued. Because *P. acnes* proved to

be susceptible to doxycycline, treatment with penicillin was stopped and continued with doxycycline plus rifampin. Three months after surgery, monotherapy with doxycycline for another three months was prescribed.

At the 2-year follow-up examination, the patient reported good joint function (ROM 0/5/105, WOMAC-Scale 12, VAS 80, EQ-5D 1) without clinical signs of infection. Radiographs showed a properly aligned TKA and no signs of loosening (Figure 1cd).



**Figure 1.** Initial anteroposterior (a) and lateral (b) radiographs at referral showing a loose and displaced femoral and tibial component. Anteroposterior (c) and lateral (d) radiographs at follow-up 2 years after reimplantation.

## Review of the Literature

### Methods

For identifying published case reports, PubMed, PMC and Scopus databases were searched using the search string “Brucell\* AND (prosth\* OR replacement OR arthroplasty) AND (knee OR hip OR joint)”. Further a google query for “Brucella PJI” was

performed. No restriction for time period of publications was applied. Two authors (DF and CS) reviewed titles and abstracts without restriction on date or language. Cases with symptoms consistent with PJI and *Brucella* spp. recovered from either synovial fluid culture or biopsy samples were included.

**Table 1.** Demographics and diagnostics

Patient No	Demographics		Country of Exposure	Involved Prosthesis	Age of PJ (months)	Previous Revisions	Symptoms	Cultures					Brucella Serologies*	References
	Age & sex	Exposure risk						Species	Aspiration	Tissue	Blood Culture	Co-infection		
1	24, f	na	Saudi Arabia	TKR bilateral	2	no	local symptoms	<i>B. melitensis</i>	pos	na	na	no	pos	1
2	72, m	unpasteurized dairy products	Turkey	TKR	48	no	local symptoms	<i>B. melitensis</i>	na	pos	neg	no	pos	2 (27)
3	50, m	farmer, cattle	Spain	THR	0	no	systemic and local	<i>B. melitensis</i>	na	pos	pos	no	pos	3
4	71, m	farmer, cattle	Spain	THR	36	no	local symptoms	<i>B. melitensis</i>	na	pos	na	yes	na	3
5	67, f	na	Mexico	THR	24	no	local symptoms	<i>B. abortus</i>	neg	pos	na	no	na	4 (26)
6	65, f	unpasteurized dairy products	Portugal	TKR bilateral	na	no	systemic and local	<i>B. melitensis</i>	neg	pos	na	no	na	5
7	63, f	unpasteurized dairy products	Turkey	TKR	24	yes	systemic and local	<i>B. melitensis</i>	neg	pos	neg	no	pos	6
8	71, f	na	Spain	TKR	48	no	systemic and local	<i>Brucella sp</i>	pos	na	na	no	pos	7
9	68, f	na	Iran	TKR	12	no	local symptoms	<i>Brucella sp</i>	neg	pos	na	no	na	8
10	54, m	farmer	United States	THR	6	no	systemic and local	<i>B. abortus</i>	neg	pos	na	no	pos	9
11	62, m	na	Turkey	TKR	24	no	systemic and local	<i>B. melitensis</i>	pos	na	na	no	pos	10
12	47, m	unpasteurized dairy products	Lebanon	THR	168	no	local symptoms	<i>Brucella sp</i>	na	pos	na	no	pos	11
13	79, m	contact with cattle	Israel/Argentina	TKR	144	no	local symptoms	<i>B. melitensis</i>	na	pos	na	no	na	12
14	51, m	contact with goats	Thailand	TKR	60	no	systemic and local	<i>B. melitensis</i>	pos	na	pos	no	pos	13
15	na	unpasteurized dairy products	India	THR	na	na	na	<i>B. melitensis</i>	pos	na	na	na	na	14
16	74, m	shepherd	Greece	TKR bilateral	4	no	systemic and local	<i>B. melitensis</i>	pos	na	pos	no	pos	15
17	67, f	unpasteurized dairy products	Italy	TKR bilateral	48	no	local symptoms	<i>Brucella sp</i>	neg	pos	na	no	na	16
18	74, m	unpasteurized dairy products	Italy	TKR	108	no	local symptoms	<i>B. melitensis</i>	na	pos	na	no	pos	17
19	65, f	na	Turkey	TKR bilateral	96	no	systemic and local	<i>B. melitensis</i>	pos	na	na	no	pos	18
20	63, m	contact with cattle	Spain	THR	60	no	local symptoms	<i>B. melitensis</i>	pos	pos	neg	no	na	19
21	60, m	contact with goats	Spain	TKR	14	no	local symptoms	<i>B. melitensis</i>	pos	na	neg	no	pos	20
22	66, f	contact with cattle	Spain	THR	36	no	local symptoms	<i>B. abortus</i>	pos	na	na	no	na	21
23	71, m	farmer, cattle	Spain	THR	63	yes	local symptoms	<i>B. melitensis</i>	na	pos	na	no	pos	21
24	68, m	na	Italy	TKR	24	no	local symptoms	<i>B. melitensis</i>	pos	na	na	no	pos	22
25	56, m	farmer, sheep	Spain	THR	60	no	systemic and local	<i>B. melitensis</i>	pos	na	neg	no	pos	23
26	38, m	unpasteurized dairy products	Israel	THR	48	no	local symptoms	<i>B. melitensis</i>	neg	pos	na	no	pos	24
27	61, m	unpasteurized dairy products	Israel	TKR	36	yes	local symptoms	<i>B. melitensis</i>	pos	pos	na	yes	pos	24
28	67, m	unpasteurized dairy products	Israel	TKR	168	no	systemic and local	<i>B. melitensis</i>	pos	na	na	no	pos	24
29	64, f	unpasteurized dairy products	Turkey	TKR	60	no	local symptoms	<i>B. melitensis</i>	pos	na	na	no	pos	25
30	75, m	unpasteurized dairy products	Turkey	TKR	144	yes	local symptoms	<i>B. melitensis</i>	pos	pos	neg	yes	pos	this case

\* Serum agglutination (=standard tube agglutination (SAT)) was used in most cases. Only positive results were quoted because of limited comparability among the different tests used; THR total hip replacement; TKR total knee replacement; PJ prosthetic joint; na not available.

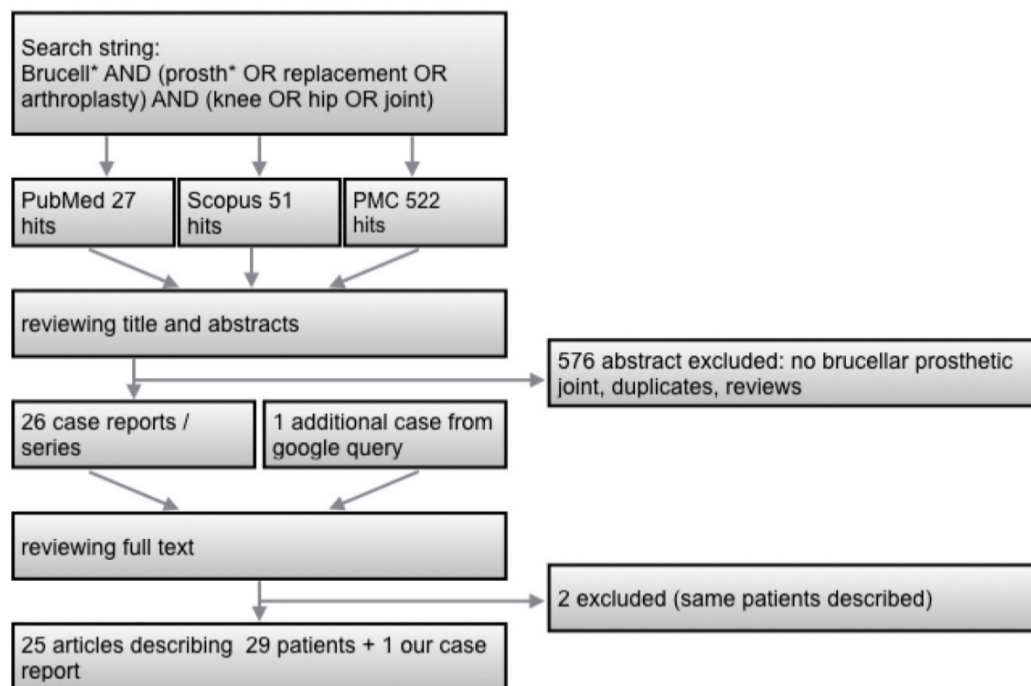
## Results

The literature screening procedure is illustrated in Figure 2. Twenty-five published articles describing 29 patients were identified [1-25] (Table 1). Three of them were co-infections. Two articles describing the same patients were excluded [26, 27].

Most patients were male and originated from southern Europe (Spain, Portugal, Italy, Portugal, Greece), or the Middle East (Turkey, Israel, Lebanon, Iran, Saudi Arabia). The majority reported a history that was congruent with the pathogenesis (e.g., regular consumption of unpasteurized dairy products, occupational exposure to animals).

Eleven hip and 19 knee infections were described. The range of time interval between implantation of the prosthesis and the diagnosis of PJI was very broad (from immediately postoperative up to 168 months) with a median of 48 months. 62% (18/29) of patients had only local symptoms, and 38% (11/29) both systemic (mainly fever, malaise) and local symptoms. More than half of the patients (17/29) had a radiologically documented loosening of the implant. Twenty-three cases of *B. melitensis*, three of *B. abortus* and four cases of *Brucella* sp. were described. Diagnosis was mostly made by positive joint aspiration cultures (16/23). When no aspiration was performed (7/30) or aspiration culture was negative (7/23) intraoperative tissue biopsies were diagnostic.

Only three cases had reported positive blood cultures. All cases with reported serology results revealed positive anti-*Brucella* antibodies (21/21). Three co-infections were documented, our case with *P. acnes*, one with viridans-group streptococci and one with *Acinetobacter baumannii*. In patients with radiological documented loosening, a one-stage exchange was performed in three, removal of the implant without replacement in one, and a two-stage exchange with a long interval (between 6 weeks and 6 months, median 8 weeks) in 12 cases. In twelve patients without implant loosening, eight patients were treated conservatively (i.e. without surgery), two had a debridement with retention of the prosthesis and one had a one-stage and two-stage exchange, respectively. The outcome of all patients was reported as good. However, a follow up of a year or more was reported in only 23/30 cases (maximal 10 years, median 2 years). Moreover, we cannot exclude a publication bias (i.e., only cases with a good outcome are reported). The antimicrobial regimen consisted of doxycycline and rifampin in most cases, with or without an aminoglycoside (streptomycin or gentamicin). In single cases quinolones or trimethoprim-sulfamethoxazole were used as a salvage treatment. The duration of antibiotic therapy varied markedly (median 16 weeks, range 6 weeks to 2 years) (Table 2).



**Figure 2.** Flow-chart for literature research.

**Table 2.** Treatment and follow-up.

Patient No	Implant Loosening	Surgical Treatment	Implant-free Interval (weeks)	Antimicrobial Treatment and Duration (weeks)	Good outcome	Follow-up (years)	References
1	no	none		Dox/Rif 76w	yes	1.5	1
2	no	DAIR (arthroscopy)		Dox/Rif 6wk	yes	1	2 (27)
3	no	none		Strep(2w)/Dox 106w	yes	5	3
4	yes	one-stage exchange		Strep(1.5w)/Dox/Rifa 25.5 w	yes	3	3
5	yes	two-stage exchange	24	Dox/Rif 20w	yes	2	4 (26)
6	yes	two-stage exchange	6	Dox/Rif 12 w	yes	10	5
7	no	none		Dox/Rif 16w	yes	3	6
8	no	none		Dox/Rif 6.5w; then Strep(3w)/Dox 12w	yes	<1	7
9	no	two-stage exchange	24	na	na	na	8
10	no	one-stage exchange		Tet 6w, then Tet 24w, then Strep(6w)/Tet 58w	yes	2	9
11	yes	two-stage exchange	12	Dox/Rif 12w	yes	10	10
12	yes	one-stage exchange		Dox/Rif 20w	yes	4	11
13	yes	two-stage exchange	8	Gen(3w)/Dox/Rif 25w, then Dox/Rif/Bact >52w	yes	<1	12
14	no	none		Gen(2w)/Dox/Rif 24w	yes	1	13
15	na	na		na	na	na	14
16	no	none		Strep(3w)/Dox 20w, then Bact 8w	yes	2	15
17	yes	two-stage exchange	12	Dox/Rif 12 w	yes	1.5	16
18	yes	Implant removal		Strep/Dox 4w, then Dox/Rif/Levo 32w	yes	< 1	17
19	yes	two-stage exchange	20	Dox/Rif 16w	yes	2	18
20	yes	two-stage exchange	16	Strep/Dox/Rif 12w	yes	<1	19
21	no	none		Strep/Dox/Rif 6w	yes	<1	20
22	yes	two-stage exchange	16	Dox/Rif 6w	yes	5.5	21
23	no	DAIR		Strep(6w)/Dox/Rif 24w	yes	5	21
24	no	none		Dox/Rif 8w	yes	1	22
25	yes	two-stage exchange	8	Strep(2w)/Dox/Rif 8w	yes	4	23
26	yes	two-stage exchange	6	Dox/Rif 12 w	yes	1	24
27	yes	two-stage exchange	6	Dox/Rif 12 w	yes	1	24
28	yes	two-stage exchange	6	Dox/Rif 12 w	yes	1	24
29	yes	one-stage exchange		Dox/Rif 24 w	yes	1.5	25
30	yes	two-stage exchange	2.5	Dox/Rif/Pen 24w	yes	2	this case

Strep: Streptomycin; Gen: Gentamicin; Dox: Doxycycline; Rif: Rifampin; Bact: Trimethoprim-Sulfamethoxazole; Levo: Levofloxacin; Tet: Tetracycline; Pen: Penicillin G; DAIR: debridement, antibiotics, irrigation and retention.

## Discussion

The preoperative diagnosis of *Brucella* PJI is a challenge in non-endemic countries, mainly because of the rarity of the disease, and hence, lack of clinical experience. The microbiological analyses of synovial fluid in patients with suspected PJI is part of the routine diagnostic procedure in many centers. In case of *Brucella* PJI, however, this intervention – without the required aerosol precautions – may expose personnel both in the operating room and microbiology laboratory to the pathogen [28]. In contrast, serological tests for brucellosis in previously untreated patients and in non-endemic region are reliable and safe diagnostic tools [29]. Our and all reported cases revealed significant elevated anti-*Brucella*-antibodies. Thus, it is conceivable to think of brucellosis and perform serological tests prior to synovial puncture, when the patient history (e.g.,

exposure to unpasteurized dietary products) or his ethnicity points towards this differential diagnosis.

In cases of suspected or confirmed *Brucella* PJI, infection control precautions are necessary prior to a surgical intervention. Laboratory staff must be pre-informed about potential growth of *Brucella* spp. when biopsy samples are sent for analyses [14, 28, 30]. Our literature review indicates that cultures of intra-operative tissue samples provide the best yield.

There is no uniform recommendation for the surgical procedure in *Brucella* PJI. Loose implants must be exchanged, and successful outcomes with both one-stage and two-exchanges have been reported. Although a wide range of time periods for the implant-free interval have been reported (i.e., 6 weeks to 6 months), we were unable to find a scientific rationale against a short interval. Although, *Brucella* spp. have shown to form Biofilm in vitro [31, 32], to the best of our knowledge, there are no reports



on *Brucella*-associated biofilm production on orthopedic implants. Thus, the clinical significance of *in-vitro* results requires further investigations. The overall good prognosis of *Brucella* PJI irrespective of applied treatment concept supported our surgical concept of a short interval.

Antimicrobial treatment for brucellosis requires a combination regimen, because high relapse rates have been reported with monotherapy. Rifampin, doxycycline, ciprofloxacin, trimethoprim-sulfamethoxazole and aminoglycosides have good activity against brucellosis. Antimicrobial drug resistance is unusual but can be determined by the Etest method [33]. Doxycycline plus streptomycin or doxycycline plus rifampin are the most commonly-used combinations [34-36]. Given the side effects of aminoglycosides, in particular in the elderly, we prefer not to use gentamicin or streptomycin for a prolonged treatment period.

It may be reasonable to start antimicrobial treatment prior to surgical intervention to lower the bacterial load, provided that *Brucella* spp. and other microorganisms are isolated from a preoperative joint puncture. In 10% of the described cases, a polymicrobial infection was reported. In retrospect, *P. acnes* may have been missed in our case.

The optimal treatment duration in *Brucella* PJI is unknown. In brucellosis, irrespective of infection site, less than 6 weeks with monotherapy is associated with failure [37]. In analogy to treatment recommendation for brucellar spondylitis, we targeted a combination therapy of at least 12 weeks [35].

## Conclusions

*Brucella* PJI is rare, and the diagnosis is often unexpected in non-endemic countries. Thinking of risk factors and ethnicity is the key to the diagnosis. Serological tests should be performed prior to joint puncture or surgical interventions. In case of positive anti-*Brucella*-antibodies, infection control must be involved and laboratory personnel informed prior to obtaining samples. Our review of the literature indicates that the prognosis is good, irrespective of surgical treatment modality. In rare cases, a polymicrobial infection can occur. On the basis of these data, and with respect to a shorter hospitalization period and better joint function, we prefer either a one-stage exchange or a two-stage exchange with a short interval in case of loose implants. A combination antimicrobial regimen is recommended, though, the optimal treatment duration is unknown. In our case, a 3-month course of doxycycline plus rifampin, followed by a 3

month-course of doxycycline monotherapy showed a successful outcome.

## Competing Interests

The authors have declared that no competing interest exists.

## References

- Agarwal S, Kadhi SK, Rooney RJ. Brucellosis complicating bilateral total knee arthroplasty. Clin Orthop Relat Res. 1991; 179-81.
- Atay T, Baydar ML, Heybeli N. [Brucellar Prosthetic Infection After Total Knee Arthroplasty: A Case With Retained Prosthesis by Arthroscopic and Medical Treatment]. Trakya Univ Tip Fak Derg. 2008; 25: 252-255
- Cairo M, Calbo E, Gomez L, Matamala A, Asuncion J, Cuchi E, et al. Foreign-body osteoarticular infection by *Brucella melitensis*: A report of three cases. J Bone Joint Surg Am. 2006; 88: 202-4.
- Carothers JT, Nichols MC, Thompson DL. Failure of total hip arthroplasty secondary to infection caused by *Brucella abortus* and the risk of transmission to operative staff. Am J Orthop (Belle Mead NJ). 2015; 44: E42-5.
- Dauty M, Dubois C, Coisy M. Bilateral knee arthroplasty infection due to *Brucella melitensis*: a rare pathology? Joint Bone Spine. 2009; 76: 215-6.
- Erdogan H, Cakmak G, Erdogan A, Arslan H. *Brucella melitensis* infection in total knee arthroplasty: a case report. Knee Surg Sports Traumatol Arthrosc. 2010; 18: 908-10.
- Iglesias G, Arboleya L, Arranz J. [Brucellar arthritis in a knee with prosthesis]. Revista Española de Reumatología. 1997; 24: 32-3.
- Jabalamei M, Bagherifard A, Hadi H, Qomashi I. Infected Total Knee Arthroplasty by *Brucella melitensis*: A Rare Case Report. Shafa Orthopedic Journal. 2016; In Press.
- Jones RE, Berryhill WH, Smith J, Hofmann A, Rogers D. Secondary infection of a total hip replacement with *Brucella abortus*. Orthopedics. 1983; 6: 184-6.
- Karaaslan F, Mermerkaya M, Karaoglu S, Ayvaz M. Total Knee Arthroplasty Infected by *Brucella Melitensis* Septic Loosening and Long-Term Results of Two-Stage Revision Knee Arthroplasty. Journal of Surgery. 2014; 10: 241-2
- Kasim RA, Araj GF, Afeiche NE, Tabbarah ZA. *Brucella* infection in total hip replacement: case report and review of the literature. Scand J Infect Dis. 2004; 36: 65-7.
- Klassov Y, Klassov T, Peretz O, Benkovich V. Review of periprosthetic infection of Brucellosis with presentation of a case report. American Journal of Infectious Diseases. 2016; 12: 65-72.
- Lewis JM, Folb J, Kalra S, Squire SB, Taegtmeier M, Beeching NJ. *Brucella melitensis* prosthetic joint infection in a traveller returning to the UK from Thailand: Case report and review of the literature. Travel Med Infect Dis. 2016; 14: 444-50.
- Lowe CF, Showler AJ, Perera S, McIntyre S, Qureshi R, Patel SN, et al. Hospital-associated transmission of *Brucella melitensis* outside the laboratory. Emerg Infect Dis. 2015; 21: 150-2.
- Malizos KN, Makris CA, Soucacos PN. Total knee arthroplasties infected by *Brucella melitensis*: a case report. Am J Orthop (Belle Mead NJ). 1997; 26: 283-5.
- Marbach F, Saiah L, Fischer JF, Huismans J, Cometta A. [Infection of a total knee prosthesis with *Brucella* spp]. Rev Med Suisse. 2007; 3: 1007-9.
- Marchese M, Bianchi G, Cavenago C. Total knee prosthesis infection by *Brucella melitensis*: case report and review of the literature. Journal of Orthopaedics and Traumatology. 2006; 7: 150-3.
- Oner M, Guney A, Halici M, Kafadar I. Septic Loosening Due to *Brucella Melitensis* After Bilateral Knee Prosthesis and Two-Stage Total Knee Prosthesis Revision. Erciyes Tip Dergisi/Erciyes Med J. 2012; 34: 97-9.
- Ortega-Andreu M, Rodriguez-Merchan EC, Aguera-Gavaldà M. Brucellosis as a cause of septic loosening of total hip arthroplasty. J Arthroplasty. 2002; 17: 384-7.
- Orti A, Roig P, Alcalá R, Navarro V, Salavert M, Martín C, et al. Brucellar prosthetic arthritis in a total knee replacement. Eur J Clin Microbiol Infect Dis. 1997; 16: 843-5.
- Ruiz-Iban MA, Crespo P, Diaz-Pelletier R, Rozado AM, Lopez-Pardo A. Total hip arthroplasty infected by *Brucella*: a report of two cases. J Orthop Surg (Hong Kong). 2006; 14: 99-103.
- Tassinari E, Di Motta D, Giardina F, Traina F, De Fine M, Toni A. *Brucella* infection in total knee arthroplasty. Case report and revision of the literature. Chir Organi Mov. 2008; 92: 55-9.
- Tena D, Romanillos O, Rodriguez-Zapata M, de la Torre B, Perez-Pomata MT, Viana R, et al. Prosthetic hip infection due to *Brucella melitensis*: case report and literature review. Diagn Microbiol Infect Dis. 2007; 58: 481-5.
- Weil Y, Mattan Y, Liebergall M, Rahav G. *Brucella* prosthetic joint infection: a report of 3 cases and a review of the literature. Clin Infect Dis. 2003; 36: e81-6.
- Wunschel M, Olszowski AM, Weissgerber P, Wulker N, Kluba T. [Chronic brucellosis: a rare cause of septic loosening of arthroplasties with high risk of laboratory-acquired infections]. Z Orthop Unfall. 2011; 149: 33-6.

26. Nichols M, Thompson D, Carothers JT, Klauber J, Stoddard RA, Guerra MA, et al. *Brucella abortus* exposure during an orthopedic surgical procedure in New Mexico, 2010. *Infect Control Hosp Epidemiol*. 2014; 35: 1072-3.
27. Çetdn ES, Kaya S, Atay T, Demdrd M. Brucellar Prosthetic Arthritis of the Knee Detected with the Use of Blood Culture System For the Culture of Synovial Fluid. *Firat Tıp Dergisi*. 2008;13: 153-5.
28. Mesner O, Riesenberg K, Biliar N, Borstein E, Bouhnik L, Peled N, et al. The many faces of human-to-human transmission of brucellosis: congenital infection and outbreak of nosocomial disease related to an unrecognized clinical case. *Clin Infect Dis*. 2007; 45: e135-40.
29. Mert A, Ozaras R, Tabak F, Bilir M, Yilmaz M, Kurt C, et al. The sensitivity and specificity of *Brucella* agglutination tests. *Diagn Microbiol Infect Dis*. 2003; 46: 241-3.
30. [Internet] Siegel JD, Rhinehart E, Jackson M, Chiarello L, HICPAC t. 2007 Guideline for Isolation Precautions: Preventing Transmission of Infectious Agents in Healthcare Settings. <http://www.cdc.gov/hicpac/pdf/isolation/Isolation2007.pdf>.
31. Almiron MA, Roset MS, Sanjuan N. The Aggregation of *Brucella abortus* Occurs Under Microaerobic Conditions and Promotes Desiccation Tolerance and Biofilm Formation. *Open Microbiol J*. 2013; 7: 87-91.
32. Godefroid M, Svensson MV, Cambier P, Uzureau S, Mirabella A, De Bolle X, et al. *Brucella melitensis* 16M produces a mannan and other extracellular matrix components typical of a biofilm. *FEMS Immunol Med Microbiol*. 2010; 59: 364-77.
33. Maves RC, Castillo R, Guillen A, Espinosa B, Meza R, Espinoza N, et al. Antimicrobial susceptibility of *Brucella melitensis* isolates in Peru. *Antimicrob Agents Chemother*. 2011; 55: 1279-81.
34. Alp E, Doganay M. Current therapeutic strategy in spinal brucellosis. *Int J Infect Dis*. 2008; 12: 573-7.
35. Colmenero JD, Ruiz-Mesa JD, Plata A, Bermudez P, Martin-Rico P, Queipo-Ortuno MI, et al. Clinical findings, therapeutic approach, and outcome of brucellar vertebral osteomyelitis. *Clin Infect Dis*. 2008; 46: 426-33.
36. Ulu-Kilic A, Karakas A, Erdem H, Turker T, Inal AS, Ak O, et al. Update on treatment options for spinal brucellosis. *Clin Microbiol Infect*. 2014; 20: O75-82.
37. Pappas G, Seitaridis S, Akritidis N, Tsianos E. Treatment of brucella spondylitis: lessons from an impossible meta-analysis and initial report of efficacy of a fluoroquinolone-containing regimen. *Int J Antimicrob Agents*. 2004; 24: 502-7.