Forensic Sci Med Pathol (2017) 13:367–371
DOI 10.1007/s12024-017-9880-7

CASE REPORT

Unexpected brain finding in pre-autopsy postmortem CT

Vasiliki Chatzaraki[1] · Stephan A. Bolliger[1] · Michael J. Thali[1] · Sebastian Eggert[1] · Thomas D. Ruder[1,2]

Accepted: 3 May 2017 / Published online: 7 June 2017

Abstract A case is presented in which pre-autopsy postmortem computed tomography (PMCT) revealed an unexpected brain abscess with a related frontal sinusitis and an erosion of the posterior wall of the frontal sinus. PMCT findings enabled the forensic pathologists to adapt protective measures during autopsy and protect their health from infection. Pre-autopsy PMCT has been also useful in the early differential diagnosis procedure. The complementary use of postmortem imaging and autopsy can improve the quality of forensic death investigations.

Keywords Virtopsy · Postmortem computed tomography · Brain abscess · *Streptococcus anginosus* · Sinusitis · Autopsy

Introduction

Forensic pathologists regularly face danger from infectious diseases such as HIV, tuberculosis, and other bacteria during autopsies [1–3]. It is of primary importance for forensic pathologists and autopsy technicians to be aware of the presence of any infectious diseases before an autopsy to enforce protective measures and protect their own health [3–5]. The use of postmortem imaging techniques such as postmortem computed tomography (PMCT) and postmortem magnetic resonance (PMMR) imaging has increased in forensic medicine in recent years [6]. Imaging offers many advantages, not only for the quality and the reliability of forensic findings but also for forensic pathologists' protection [3–6]. We present a case in which postmortem imaging revealed an unexpected finding compatible with a brain abscess. The early detection of this potentially infectious focus enabled forensic pathologists to take appropriate protective measures and adapt their approach to brain dissection for careful collection of tissue samples for microbiologic analysis.

Case history

A 48-year-old male was found dead on his bed in a prone position. There were no external wounds. An opened packet of non-steroidal anti-inflammatory drugs (NSAID) was found at the death scene. The deceased was delivered to the Institute of Forensic Medicine of Zurich for further examination. No medical history of the deceased was available at the time of the autopsy. The postmortem interval between the estimated time of death and PMCT was approximately 1.5–2.5 days.

Materials and methods

Whole-body postmortem imaging was carried out in the supine position. Imaging was performed on a 128-slice CT scanner (SOMATOM Definition Flash, Siemens Healthineers, Erlangen, Germany). The imaging parameters were set as follows [7]: tube voltage 120kVp, slice collimation 128 × 0.6 mm. All scans were performed using automatic dose modulation software Siemens CARE Dose 4D (CARE Dose

✉ Vasiliki Chatzaraki
vasiliki.chatzaraki@irm.uzh.ch; chatzaraki@outlook.com.gr

[1] Department of Forensic Medicine and Imaging, Institute of Forensic Medicine, University of Zurich, Winterthurerstrasse 190/52, CH-8057 Zurich, Switzerland

[2] Institute of Diagnostic, Interventional and Pediatric Radiology, University Hospital Bern, Freiburgstrasse, 3010 Bern, Switzerland

4D™, Siemens Healthineers, Erlangen, Germany). PMCT image reconstructions were performed with a slice thickness of 1.0 mm and an increment of 0.6 mm, using the soft-tissue and lung window with soft and hard kernel, respectively.

The whole-body CT scan was conducted by one radiologic technologist. Images were evaluated on a multimodality workstation (Syngo.via, Version VB10A) by one forensic pathologist (with 1 year of experience in clinical radiology and 1 year of experience in post-mortem forensic radiology) and one radiologist (with 7 years of experience in clinical radiology and 8 years of experience in post-mortem forensic radiology).

Forensic autopsy was performed by two forensic pathologists (with 14 years and 1 year of experience, respectively).

Findings

Imaging findings

PMCT of the brain revealed a well-defined, centrally hypodense lesion with a hyperdense ring in the left frontal lobe of the brain. The density of the inner content of the lesion was approximately 25 Hounsfield-Units (HU). Maximal diameters were approximately 6 × 3 cm. The lesion was surrounded by vasogenic brain edema. A midline shift to the right was also noticed (Fig. 1). Based on its radiologic appearance, the lesion was compatible with a brain abscess or necrotic tumor (metastasis or glioma).

In addition to the possible abscess, PMCT revealed opacification of the frontal sinuses (Fig. 2) and a small osseous defect in the posterior wall of the frontal sinus adjacent to the brain lesion (Figs. 2 and 3).

No further forensic relevant findings to a cause of death were detected in the whole-body PMCT.

Autopsy findings

The autopsy revealed an abscess in the left frontal lobe with liquid, yellow-green content surrounded by brain edema (Fig. 4). The lesion measured approximately 6 × 5 cm.

Additionally, the opening of the frontal sinuses revealed purulent liquid. No further infectious foci were observed during autopsy.

The liquid content of the abscess was collected for microbiological analysis. No samples from the frontal sinus content were collected.

Microbiological findings

The microbiological culture results predominantly revealed *Streptococcus anginosus* and a smaller amount of Staphylococcus hominis, which are both part of the normal human skin flora [8–11]. No anaerobic bacteria were developed. Mycobacterium tuberculosis was not detected.

Discussion

This case highlights how pre-autopsy PMCT detection of a possibly infectious brain lesion enabled forensic pathologists to adequately prepare for autopsy and thus collect a sample of the pus-filled abscess while minimizing the risk of infection by wearing appropriate protective clothing.

This case also highlights how PMCT was useful in the early differential diagnostic procedure regarding possible etiologies of the brain lesion and later – once a brain abscess was considered the most likely diagnosis – for revealing the path of the infection from the frontal sinus through the osseous defect in the posterior wall of the frontal sinus and into the frontal lobe.

In general, the differential diagnosis of a solitary intracranial, intraaxial hypodense mass lesion with a hyperdense ring and

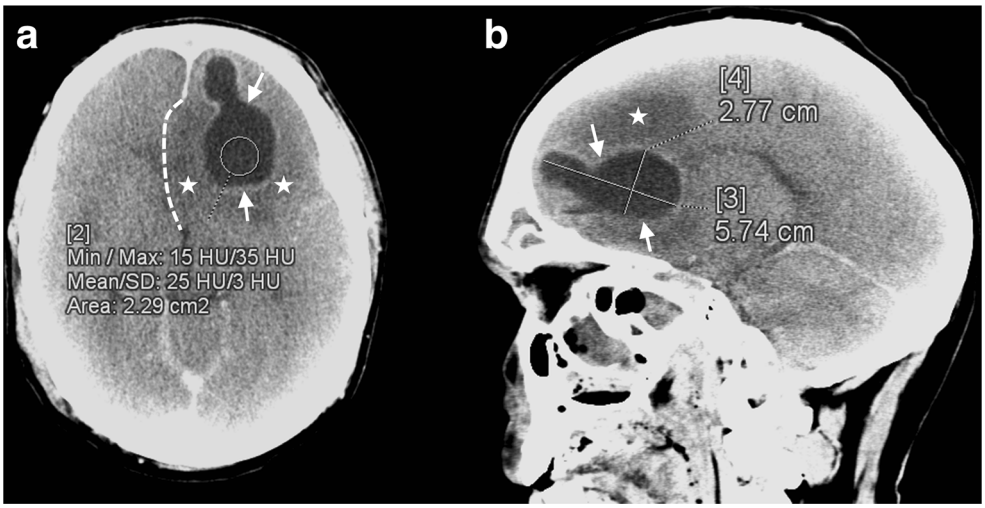

Fig. 1 Axial (1**a**) and sagittal (1**b**) PMCT image of the skull demonstrating a centrally hypodense lesion with a hyperdense ring in the left frontal lobe of the brain (approximately 6 × 3 cm, *white arrows*). Note the surrounding vasogenic edema (*asterisks*) and midline shift to the right (*dashed line*). The density of the lesion content was approximately 25 HU

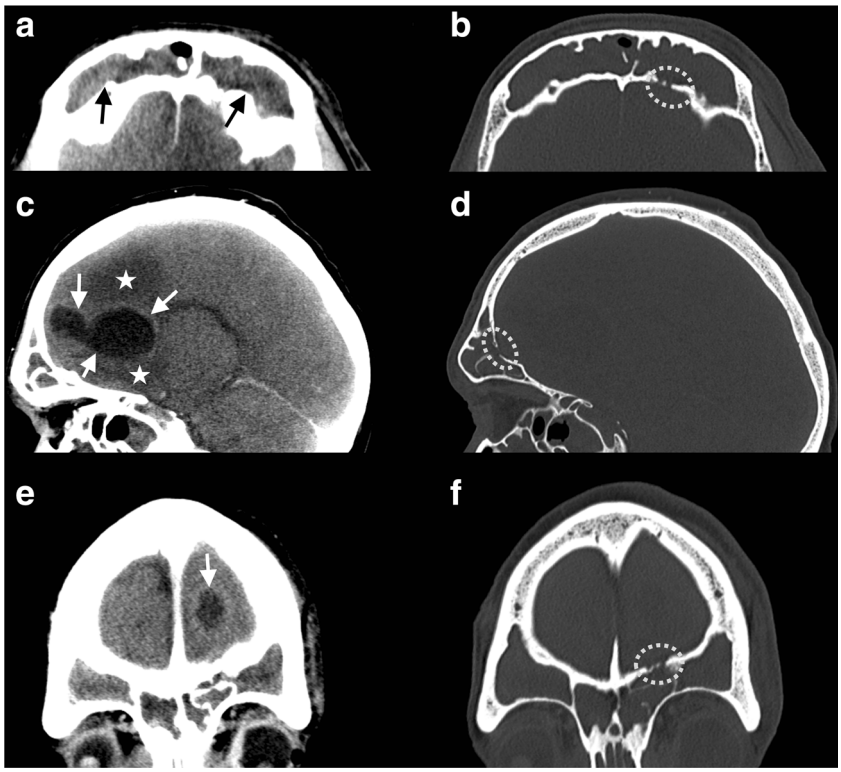

Fig. 2 Axial (**a**/**b**), sagittal (**c**/**d**), and coronal (**e**/**f**) PMCT images of the skull in soft tissue window (**a**/**c**/**e**) and bone window (**b**/**d**/**f**). Note the opacification of the frontal sinuses (*black arrows*) as well as a small osseous defect (*dashed circles*) in the posterior wall of the frontal sinus adjacent to the brain lesion (*white arrows*) and the perilesional brain edema (*asterisks*)

surrounding vasogenic edema on non-contrast CT includes primary brain tumor (glioma), metastasis, or abscess [12]. It is conceivable that PMMR imaging or PMCT-angiography may have provided further insight into the composition or vascularization of the lesion. However, in this case, the imaging characteristics of non-contrast PMCT (both the size and solitary occurrence of the lesion as well as HU values) were atypical for primary brain tumor or necrotic metastasis and were strongly suggestive of brain abscess. In addition, the coexisting frontal sinusitis and erosion of the posterior wall of the frontal sinus further supported the diagnosis of brain abscess.

The autopsy confirmed the diagnosis of brain abscess. The discrepancy between the autopsy measurements and the PMCT measurements of the abscess (6 × 5 cm and 6 × 3 cm, respectively) may be attributable to different extents of brain compression both inside and outside the skull.

Possible pathogens for brain abscess are staphylococcus, streptococcus, pneumococcus, or mycobacterium tuberculosis (in the case of immune deficiency or immunosuppression treatment), toxoplasmosis, cryptococcosis, candidiasis, aspergillosis, listeriosis, nocardiosis, mucormycosis, mycobacterium tuberculosis, atypical mycobacteria infection, or even more rarely, parasites (e.g. neurocysticercosis) [12, 13].

Streptococcus anginosus is part of the normal human bacterial flora but is capable of causing abscesses [8, 9]. Although it is a rare clinical condition, brain abscess is dangerous and potentially fatal. Brain abscess generally originates from extracerebral infectious foci, i.e. sinusitis, mastoiditis, meningitis,

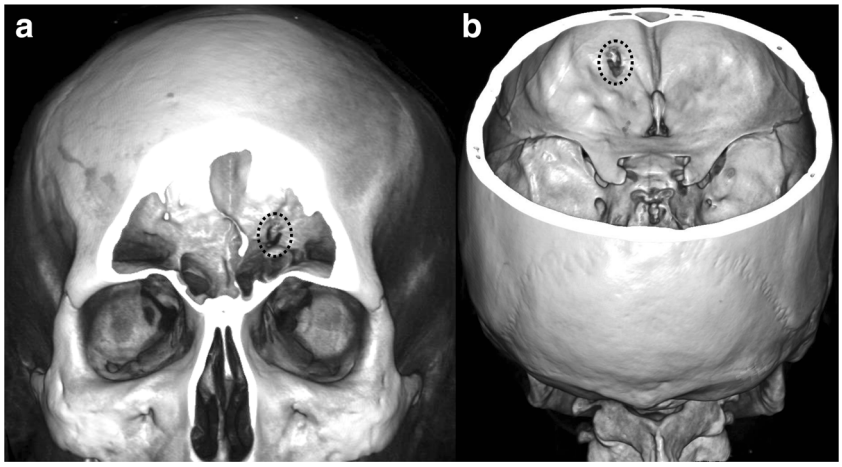

Fig. 3 Three-dimensional PMCT reconstruction of the skull. Note the small osseous defect (*dashed circles*) in the posterior wall of the left frontal sinus

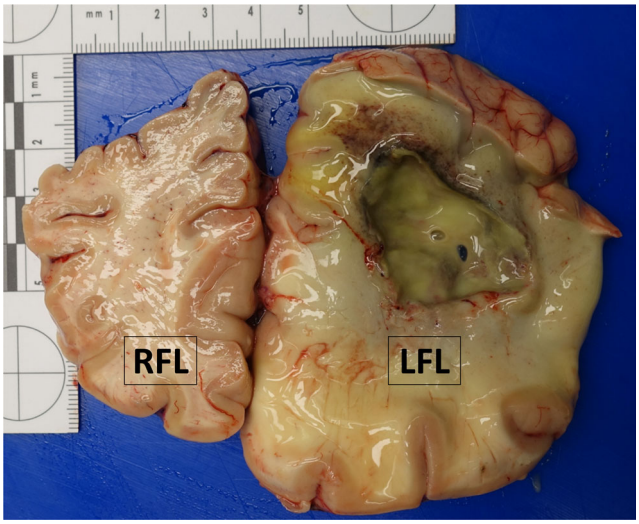

Fig. 4 Coronal cut of both frontal lobes of the brain during autopsy demonstrating the abscess in the left frontal lobe filled with yellow-greenish pus. Note the swelling of the left frontal lobe (LFL) of the brain compared with the right (RFL)

odontogenic, oral infections, endocarditis and pneumonia [8, 14–16]. The infection typically spreads via the blood stream from the infectious site to the brain parenchyma by continuous extension or by venous drainage to the cerebral vein system, i.e. the cavernous sinus, and by lymphatic drainage [10, 15]. Head trauma and neurological surgeries predispose a patient to hematogenous brain infection [10]. In addition, a previous intracerebral hemorrhage can cause injury to the blood-brain barrier and facilitate a hematogenous spread to the brain [16]. In general, single and monomicrobial abscesses are more common than multiple and polymicrobial types [14].

In this case, the brain abscess originated from a pre-existing chronic frontal sinusitis and had spread by continuous expansion through the eroded posterior wall of the frontal sinus into the brain. Sinonasal infections are a well-known risk factor for brain abscess formation [17]. Erosion of the posterior frontal sinus is also a complication of sinusitis [17]. No other infectious sites were identified at autopsy. It is worth noting that samples from frontal sinus content for microbiological culture may have provided further proof to the spreading path diagnosis but no microbiological analysis of the frontal sinus pus was conducted.

Clinical symptoms of a brain abscess include, in decreasing frequency, headache, fever, neurologic deficits, nausea and vomiting, consciousness disorders, nuchal rigidity and seizures [14]. In this case, a subsequent police investigation revealed that the deceased had indeed suffered from headaches and had been treated for sinusitis with antibiotics twice in the three months preceding his death. The deceased had not, however, visited his family physician in the four weeks prior to his demise. The presence of the opened packet of non-steroidal anti-inflammatory drugs (NSAID) at the death scene may be interpreted as an indicator of persistent headache.

Conclusion

This case reveals how pre-autopsy PMCT detection of a brain abscess from chronic frontal sinusitis enabled forensic pathologists to adapt their autopsy approach to brain dissection to collect a sample of the abscess while simultaneously minimizing the risk of infection by wearing appropriate protective clothing. This case adds to the growing body of evidence supporting the complementary use of imaging and autopsy as a means of improving the quality of forensic death investigations.

Key points

1. PMCT can detect possibly contagious findings, therefore enabling forensic pathologists to adopt protective measures.
2. It is of primary importance to match and complement PMCT with other methods' findings to reach a final diagnosis.

Acknowledgements The authors express their gratitude to Emma Louise Kessler, MD for her generous donation to the Zurich Institute of Forensic Medicine, University of Zurich, Switzerland.

Compliance with ethical standards

Human and animal rights This case report does not contain any studies with animals performed by any of the authors.

Ethical approval Ethical approval was obtained by the Cantonal Ethics Committee of Zurich, Switzerland, Nr. 2015–0686.

Conflicts of interest None declared.

References

1. Healing TD, Hoffman PN, Young SE. The infection hazards of human cadavers. Commun dis rep CDR rev. 1995;28:61–8.
2. Burton JL. Health and safety at necropsy. J Clin Pathol. 2003;56(4): 254–60.
3. Püschel K, Lieske K, Hashimoto Y, Karch H, Laufs R, Racz P, et al. HIV-infection in forensic autopsy cases. Forensic Sci Int. 1987;34: 169–74.
4. Thali MJ, Jackowski C, Oesterhelweg L, Ross SG, Dirnhofer R. VIRTOPSY – the Swiss virtual autopsy approach. Legal med. 2007;9:100–4.
5. McLaughlin S, Kind K, Thomson L, Bouhaidar R. Unexpected active tuberculosis on post mortem CT: a case report and review of the literature. Forensic Sci Int. 2016;266:e64–7.
6. Baglivo M, Winklhofer S, Hatch GM, Ampanozi G, Thali MJ, Ruder TD. The rise of forensic and postmortem radiology. J Forensic Radiol Imaging. 2013;1:3–9.
7. Flach PM, Gascho D, Schweitzer W, Ruder TD, Berger N, Ross SG, et al. Imaging in forensic radiology: an illustrated guide for postmortem computed tomography technique and protocols. Forensic Sci Med Pathol. 2014;4:583–606.

8. Al-Saffar F, Torres-Miranda D, Ibrahim S, Shujaat A. How an opportunistic infection can mess with your brain and take your breath away: a rare case of simultaneous lung and brain abscess due to *Streptococcus anginosus*. Case Rep Infect Dis. 2015;2015:462459.
9. Sim B, Watson A. Pyogenic brain abscess due to *Streptococcus anginosus*. Med J Aust. 2015;202:271.
10. Simone G, Rubini G, Conti A, Goldoni P, Falcone M, Vena A, et al. *Streptococcus anginosus* Group disseminated infection: case report and literature review. Infez Med. 2012;3:145–54.
11. Szczuka E, Trawczynski K, Kaznowski A. Clonal analysis of Staphylococcus Hominis strains isolated from hospitalized patients. Pol J Microbiol. 2014;63:349–54.
12. Weissleder R. Primer of diagnostic imaging, 3rd ed. Mosby, Philadelphia; 2003. pp. 578–579.
13. Gaillard F. Brain abscess. Radiopaedia.org. 2005-2017. https://radiopaedia.org/articles/brain-abscess-1. Accessed 22 Feb 2017.
14. Brouwer MC, Coutinho JM, Beek D. Clinical characteristics and outcome of brain abscess: systematic review and meta-analysis. Neurology. 2014;82:806–13.
15. Moazzam AA, Rajagopal SM, Sedghizadeh PP, Zada G, Habibian M. Intracranial bacterial infections of oral origin. J Clin Neurosci. 2015;22:800–6.
16. Liu K, Yang C, Zhang Y, Yuan X, Xiao H, Bai Y, et al. Brain abscess following intracerebral hemorrhage in a patient with pneumonia. J Craniofac Surg. 2016;278:773–5.
17. Gaillard F, et al. Acute sinusitis. Radiopaedia.org. 2005-2017. https://radiopaedia.org/articles/acute-sinusitis. Accessed 22 Feb 2017.