Forensic Sci Med Pathol (2017) 13:375–378
DOI 10.1007/s12024-017-9873-6

CASE REPORT

Antemortem identification by fusion of MR and CT of the paranasal sinuses

Jakob Heimer[1] · Dominic Gascho[1] · Simon Gentile[1] · Gary M. Hatch[2] · Michael J. Thali[1] · Thomas D. Ruder[1,3]

Accepted: 13 April 2017 / Published online: 20 May 2017

Abstract Radiologic forensic identification is usually performed by comparing antemortem and postmortem radiographs. While computed tomography (CT) has become a valuable addition to radiologic identification, magnetic resonance (MR) imaging has only rarely been used for this purpose. In our case, identification was accomplished using fused MR- and CT images in a survivor of a gunshot injury to the head. This case supports and highlights the possibility to perform intermodality radiologic identification comparing preexisting MR imaging to subsequently aquired CT data in living (or deceased) humans as long as manual modifications of windowing, color and contrast enable differentiation of the two modalities in the fused image.

Keywords Forensic radiology · Computed tomography · Magnetic resonance imaging · Forensic identification · Paranasal sinuses

✉ Jakob Heimer
Jakob.Heimer@irm.uzh.ch

[1] Institute of Forensic Medicine, Department of Forensic Medicine and Imaging, University of Zurich, Winterthurerstrasse 190/52, 8057 Zurich, CH, Switzerland

[2] Center for Forensic Imaging, Departments of Radiology and Pathology, University of New Mexico School of Medicine, Albuquerque, NM 87102, USA

[3] Institute of Diagnostic, Interventional, and Pediatric Radiology, University Hospital Bern, Freiburgstrasse 8, 3010 Bern, CH, Switzerland

Introduction

In the forensic sciences, identification (ID) of human remains is fundamental [1]. Conventional means of forensic identification include dactyloscopy, DNA analysis, and comparison of dental radiography [1], the latter being the earliest established radiologic identification modality [2]. Radiologic identification usually involves comparison of antemortem (AM) with postmortem (PM) medical imaging [3, 4]. Increasing use of computed-tomography (CT) and magnetic resonance (MR) [5, 6], provides contemporary forensic sciences the opportunity to apply these data sets for radiologic identification purposes. Since radiologic identification frequently relies on the visual comparison of high-density structures, such as dental or bone tissue, CT has become a valuable addition to forensic identification [7–10]. Moreover, CT allows for comparisons with radiographs [11]. MR imaging of osseous tissues has less resolution and edge detail than radiographs or CT [12] and has thus only rarely been deemed an appropriate tool for radiologic identification [13, 14]. Documentation of radiologic identification for personal ID of living individuals is rare in the literature [15], as ID for living individuals typically relies on ID-documents and fingerprints (https://www.fedpol.admin.ch/fedpol/de/home/sicherheit/personenidentifikation.html). In this case, we present a radiologic identification of a survivor of a gunshot injury to the head by comparison and fusion of MR- and CT imaging of the frontal sinuses.

Materials and methods

Case history

A 34-year-old man was taken to the hospital with extensive and disfiguring facial injury and loss of consciousness

secondary to blunt force injury and a gunshot wound of the head. Due to the severity of disfigurement, the patient's identity could not be safely established by visual means (visual comparison of his face to the ID-card found in his wallet). After admission to the trauma room, head CT was performed to assess the extent of facial and cerebral injury. The radiology department record review revealed a single prior exam of a patient who was presumed to be the same person as the disfigured patient – an MR of the brain which had been acquired more than 10 years earlier. In view of these circumstances, our institution was tasked with confirming or excluding the presumed identity of the victim based on a comparison of the head CT and the earlier brain MR.

CT imaging

CT of the skull was performed on a 128-slice scanner (Philips ICT SP, Philips Healthcare, Best, Netherlands). Further parameters were 100 kV, tube current 380 mAs; 2 mm slice thickness and 0.6 mm increment. Reconstructions for image comparison were made in a bone tissue window with a hard kernel.

MR imaging

MR imaging was performed on a 1,5 T scanner (Philips Gyroscan Intera, Philips Healthcare, Best, Netherlands). The MR imaging protocol involved T2 weighted turbo spin echo (TSE), fluid attenuation inversion recovery (FLAIR), T1 weighted fast field echo (FFE), diffusion weighted imaging (DWI) and susceptibility weighted imaging (SWI) sequences. For image comparison, a T1 weighted FFE sequence with a slice thickness of 3.2 mm was used.

Image analysis including visual comparison and image fusion was performed on a dedicated workstation using commercially available software (syngo.Via, Siemens Healthineers, Erlangen, Germany). In order to highlight the frontal sinuses, the greyscale was inverted for image (d) (Figs. 1 and 2). A color preset (Dual Energy – Liver VNC 2) was applied to the CT data set (e). Windowing as well as contrast settings were manually adjusted for both modalities in images (e) and (d). To increase the visibility of the anatomy, CT and MR were fused in images (c) and (f) using the multiplanar reformation tool of syngo.via.

Findings

Direct visual comparison of images (a) and (b) (Figs. 1 and 2) does not allow secure identification due to the poor visualization of the septation of the frontal sinuses in image (a). The fusion image (c) shows rough alignment of the frontal sinuses but the contribution of each modality to the final image cannot be differentiated. In image (d), greyscale inversion and adjustment of windowing and contrast increase visibility of the septations and shape of the sinuses. Color modification of the CT data in image (e) ensures that both modalities can be differentiated when fused. The resulting fusion image (f) sufficiently allows secure identification revealing identical septation and shape of the frontal sinuses on CT and MR.

Discussion

This case supports and highlights the possibility of performing intermodality radiologic identification comparing preexisting MR imaging to subsequently aquired CT-data in living (or deceased) humans. Direct visual comparison of CT and MR of the paranasal sinuses is challenging when relying on standard windowing and contrast settings, as the visualization of the frontal sinuses' shape and septation on MR is easily masked by the CT images of the same structures when fused. However, manual modification of windowing, color, and contrast enables differentiation of the two imaging modalities in the fused image, allowing for secure identification.

Typically, ID is performed to confirm or exclude the ID of an unidentified decedent both in individual and multiple fatality incidents. Here, the presumed ID of a living victim of a violent assault had to be confirmed from comparative imaging due to extensive facial injury. CT imaging or radiographs are

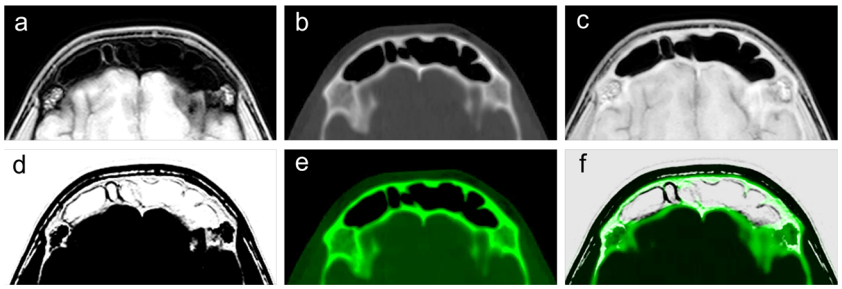

Fig. 1 First row: axial cross-section MR imaging **a**, axial cross section CT imaging **b** and fusion of both images **c** at supraorbital height; Second row: inverted axial cross section MR imaging **d**, colored axial cross section CT imaging **e** and fusion of both images **f** using windowing and color to highlight the frontal sinuses at supraorbital height

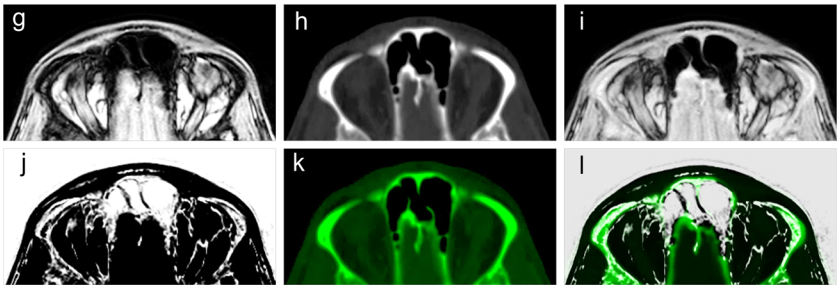

Fig. 2 First row: axial cross section MR imaging **a**, axial cross section CT imaging **b** and fusion of both images **c** at orbital height; Second row: inverted axial cross section MR imaging **d**, colored axial cross section CT imaging **e** and fusion of both images using windowing and color to highlight the frontal sinuses at orbital height

rarely used for ID in the living as most identifications are made using visual facial comparison or dactyloscopy, in addition to ethical concerns about radiation exposure [16] from imaging without a medical indication. However, this case demonstrates that if imaging is aquired for clinical purposes and is made available to forensic practicioners, the data may be used for radiologic identification.

In addition, the case also highlights the potential of radiologic identification by comparison of different imaging modalities. There are several reports in the literature where postmortem-CT has been compared to antemortem-radiographs and vice versa [10, 11, 17]. In addition to odontological examinations, the frontal sinuses are established anatomic landmarks for identification [17–20] and a standardized approach for (intramodal) CT image comparison has been proposed [21]. The International Society of Forensic Radiology and Imaging (ISFRI) has published positional statements regarding the use of conventional radiographs and PMCT for forensic identification [22, 23]. However, the potential of MR for comparative identification remains under-investigated and literature on this topic is scarce [10, 13, 14]. Overall, the comparison between MR and CT (regardless of whether it is antemortem or postmortem) is more challenging than intramodal comparison (MR to MR or CT to CT) due to the inherent differences between CT, which provides high resolution and edge detail of bone, and MR, which provides high contrast for soft tissue [12].

The syngo.via image fusion tool proved to be very helpful in addressing the fundamental challenge of intermodality comparison. Overlaying the two datasets allowed for more appropriate selection of image contrast to highlight the consistency regarding shape and size of the frontal sinuses. The fusion tool uses anatomical landmarks of the skull to register the two data sets and automatically overlay, adjust, and combine the two different datasets of the head. In this case, the fusion highlighted identical anatomy between a CT and MR of the frontal sinuses.

In conclusion, intermodality fusion of MR- and CT imaging may allow for secure radiologic identification when antemortem CT data is not available. Given the increasing amount of MR imaging worldwide, this modalilty offers a wide range of identification possibilities when adjusted properly for intermodality comparison.

Key points

1. Increasing use of computed-tomography (CT) and magnetic resonance (MR) provides data sets for radiologic identification purposes.
2. Antemortem MR imaging is a valuable source for identification purposes despite of having less resolution and edge detail for osseous tissues compared to radiographs or CT.
3. Intermodality radiologic identification by comparison of CT and MR imaging is feasible when images are fused and differentiation is enabled by manual adaptation of windowing, color, and contrast.
4. Antemortem radiologic identification may become necessary when typical antemortem identification modalities fail.

Acknowledgements The authors express their gratitude to Emma Louise Kessler, MD for her generous donation to the Zurich Institute of Forensic Medicine, University of Zurich, Switzerland.

Compliance with ethical standards

Ethical approval This article does not contain any studies with human participants or animals performed by any of the authors.Ethical approval was obtained by the Ethics Committee of the Canton of Zurich, Nr. KEK ZH-Nr. 15-0686.

Conflict of interest None.

References

1. Saukko PJ, Knight B. The establishment of identity of human remains. In: Saukko P, Knight B, editors. Knight's forensic pathology. London: Edward Arnold Ltd.; 2004. p. 98–135.
2. Brogdon BG. Forensic radiology in historical perspective. In: Thali MJ, Viner MD, Brogdon BG, editors. Brogdon's forensic radiology. Boca Raton: CRC Press; 2011. p. 9–24.

3. Jablonski NG, Shum BS. Identification of unknown human remains by comparison of antemortem and postmortem radiographs. Forensic Sci Int. 1989;42(3):221–30.
4. Brough AL, Morgan B, Rutty GN. The basics of disaster victim identification. J Forensic Radiol Imaging. 2015;3(1):29–37.
5. OECD. Computed tomography (CT) scanners (indicator). 2017.
6. OECD. Magnetic resonance imaging (MRI) units (indicator). 2017.
7. Ciaffi R, Gibelli D, Cattaneo C. Forensic radiology and personal identification of unidentified bodies: a review. Radiol Med. 2011;116(6):960–8.
8. Dedouit F, Telmon N, Costagliola R, Otal P, Florence LL, Joffre F, et al. New identification possibilities with postmortem multislice computed tomography. Int J Legal Med. 2007;121(6):507–10.
9. Dedouit F, Savall F, Mokrane FZ, Rousseau H, Crubezy E, Rouge D, et al. Virtual anthropology and forensic identification using multidetector CT. Br J Radiol. 2014;87(1036):20130468.
10. Hatch GM, Dedouit F, Christensen AM, Thali MJ, Ruder TD. RADid: a pictorial review of radiologic identification using postmortem CT. J Forensic Radiol Imaging. 2014;2(2):52–9.
11. Pfaeffli M, Vock P, Dirnhofer R, Braun M, Bolliger SA, Thali MJ. Post-mortem radiological CT identification based on classical antemortem X-ray examinations. Forensic Sci Int. 2007;171(2–3):111–7.
12. Huda W. Review of radiologic physics. 4th ed. Philadelphia: Wolters Kluwer; 2016.
13. Amberg R, Forster B, Fürmaier R. Identification by MRI. Zeitschrift für Rechtsmedizin. 1989;2(3):102.
14. Shamir L. MRI-based knee image for personal identification. Int J Biometrics. 2013;5(2):113.
15. Silva RF, Botelho TL, Prado FB, Kawagushi JT, Daruge Junior E, Berzin F. Human identification based on cranial computed tomography scan: a case report. Dentomaxillofac Radiol. 2011;40(4):257–61.
16. Hall EJ, Brenner DJ. Cancer risks from diagnostic radiology: the impact of new epidemiological data. Br J Radiol. 2012;85(1020):e1316–7.
17. Ruder TD, Kraehenbuehl M, Gotsmy WF, Mathier S, Ebert LC, Thali MJ, et al. Radiologic identification of disaster victims: a simple and reliable method using CT of the paranasal sinuses. Eur J Radiol. 2012;81(2):e132–8.
18. Christensen AM. Assessing the variation in individual frontal sinus outlines. Am J Phys Anthropol. 2005;127(3):291–5.
19. Auffret M, Garetier M, Diallo I, Aho S, Ben SD. Contribution of the computed tomography of the anatomical aspects of the sphenoid sinuses to forensic identification. J Neuroradiol. 2016;43(6):404–14.
20. Yoshino M, Miyasaka S, Sato H, Seta S. Classification system of frontal sinus patterns by radiography. Its application to identification of unknown skeletal remains. Forensic Sci Int. 1987;34(4):289–99.
21. Ruder TD, Brun C, Christensen AM, Thali MJ, Gascho D, Schweitzer W, et al. Comparative radiologic identification with CT images of paranasal sinuses – development of a standardized approach. J Forensic Radiol Imaging. 2016;7:1–9.
22. Morgan B, Alminyah A, Cala A, O'Donnell C, Elliott D, Gorincour G, et al. Use of post-mortem computed tomography in disaster victim identification. Positional statement of the members of the disaster victim identification working group of the International Society of Forensic Radiology and Imaging; may 2014. J Forensic Radiol Imaging. 2014;2(3):114–6.
23. Viner MD, Alminyah A, Apostol M, Brough A, Develter W, O'Donnell C, et al. Use of radiography and fluoroscopy in disaster victim identification. Positional statement of the members of the disaster victim identification working group of the International Society of Forensic Radiology and Imaging. J Forensic Radiol Imaging. 2015;3(2):141–5.