

# Management of Pleural Effusion by Combining Talc Poudrage and Indwelling Pleural Catheter: A Retrospective Single Center Study

Gorensek BS, Schmid RA\* and Hokschi B

Division of General Thoracic Surgery, University Hospital Bern, Bern, Switzerland

\*Corresponding author: Schmid RA, Division of General Thoracic Surgery, University Hospital Bern, Bern, Switzerland, Tel: +0041632 37 45; E-mail: ralph.schmid@insel.ch

Received date: January 13, 2017; Accepted date: January 31, 2017; Published date: February 15, 2017

Copyright: © 2017 Schmid RA, et al. This is an open-access article distributed under the terms of the Creative Commons Attribution License, which permits unrestricted use, distribution, and reproduction in any medium, provided the original author and source are credited.

## Abstract

**Objective:** In 2013 we started to combine VATS poudrage with simultaneous insertion of an indwelling pleural catheter (IPC) for management of malignant pleural effusions (MPE) to achieve successful pleurodesis, avoid recurrence of MPE and shorten hospitalization time. The aim of this study was to distinguish whether the combination treatment is superior over standard VATS poudrage.

**Methods:** This retrospective descriptive study analyses data of patients with MPE treated at our department since the implementation of the method. The historic control group included patients with MPE treated with VATS poudrage alone.

**Results:** There were 117 patients, 67 patients were treated with the new approach (IPC group) and 50 patients with VATS talc poudrage (control group). Both groups were comparable in demographic data. The postoperative hospitalization time was significantly shorter in the IPC group ( $P=0.0001$ ). Patients in the control group got 2 chest drains inserted (Ch 24/Ch 28) and in the IPC group 1 chest drain (Ch 24) plus the IPC. Chest drains could be removed quicker in the IPC group ( $P<0.0001$ ). So far there was not a single case of unsuccessful pleurodesis with our approach compared to 10% failure rate in the control group.

**Conclusion:** The combined approach is a safe and effective approach in MPE prophylaxis. Patients were discharged earlier and further treatment, e.g., chemotherapy, could be initiated in time.

**Keywords:** Malignant pleural effusion; Talc pleurodesis; Indwelling pleural catheter; Palliative medicine

## Introduction

The main focus of the treatment for MPE is to improve quality of life, since there is no cure for this condition [1]. The current standard treatment strategy for malignant pleural effusion (MPE) is talc pleurodesis, a procedure that has been implemented more than 80 years ago [2]. Today, talc pleurodesis is a safe procedure and talc is known to be the most successful pleurodesis agent with a success rate of more than 70% [3-5]. A major disadvantage of the procedure is however the need of chest tube(s) and the therefore long hospital stay up to seven days until they can be removed [6].

Indwelling pleural catheters (IPCs) are small-bore silicone tubes, which can be left in place for weeks or even months. Intermittent fluid drainage is needed until efficient pleurodesis occurs [6]. The use of IPCs improves the quality of life in patients [7]. The insertion of an IPC can reduce the hospitalization time in case of malignant pleural effusion since they can be inserted as an outpatient procedure [8].

In this retrospective analysis we report our experience with the VATS talc pleurodesis and the concomitant insertion of IPC in comparison to VATS talc pleurodesis only.

This new treatment protocol was intended to induce a better pleural adhesion, as the IPC would render the pleural space permanently dry

over a longer period than in the normal VATS talcage procedure. Our hypothesis was that a combination of both therapies offers new possibilities for efficient pleurodesis and shortens the hospitalization time.

## Materials and Methods

Since February 2013 VATS poudrage with simultaneous insertion of an IPC has been routinely performed for treatment of malignant pleural effusion at the Division of General Thoracic Surgery, Bern University Hospital, Switzerland. All patients undergoing this surgical procedure were registered in this retrospective trial until the end of May 2015 (16 months). Surgical techniques and the evaluation of patients have been uniform with an implemented standard pre-, and perioperative management from the beginning of the study period in 2013.

The control group consisted of patients, who received VATS talc poudrage without IPC. With the introduction of the new combination treatment for malignant pleural effusion only few patients are treated by VATS poudrage alone. To have a sufficient number of patients in the control group we thus had to include patients treated at our clinic as early as January 2012 and until the end of May 2015.

The Ethics Committee of the canton of Bern approved this study design and informed consent was given (KEK-BE 259/2015)

## Preoperative management

Since February 2013 all patients with a suspected or proven malignant pleural effusion have been offered a VATS talc pleurodesis with simultaneous insertion of IPC. Requirements have been a Karnofsky index >40 and a serum creatinine within the normal range. In case of curative intention patients with malignant mesothelioma have been offered VATS poudrage without IPC insertion. Patients with extreme reduced general condition (Karnofsky <40) received the IPC in local anesthesia without additional VATS poudrage. Such patients have been excluded from this trial. We have also excluded patients with a benign pleural effusion, chylothorax, pneumothorax and empyema from the analysis.

## Perioperative management and surgical techniques

All operations were performed under general anaesthesia, using a double lumen tube for selective single lung ventilation. VATS talc poudrage was performed with Steritalc Novatech 4g under video-thoroscopic visualization and by specially trained members of our staff. IPC (PleurX Catheter, CareFusion®, USA) and an additionally chest tube (24 Ch) were inserted. The chest tube was placed to ensure complete drainage of the pleural fluid and to dry pleural space. The IPC was tunnelled under the skin for about 5-8 cm and then inserted in the pleural space through one of the VATS incisions. The cuff mid-way along the catheter must be placed right behind the entry of the catheter into the skin. The developing scar tissue around the cuff established a barrier to prevent infections inside the pleural space. The thoracic drain and the IPC were set to -20 cm H<sub>2</sub>O suction as long as the patient was hospitalized. The standard chest drain was removed postoperatively and the IPC was left in situ.

The control group consisted of patients, who received VATS talc (Steritalc Novatech 4 g) poudrage without IPC. All these patients got two chest tubes (24 Ch and 28 Ch) inserted. According to the treatment protocol at our institution, the first chest tube was removed on the 4th postoperative day. The second chest tube was removed when the fluid secretion was <200 ml/day.

## Management in the postoperative course

A routine chest X-ray was performed after the operation in order to document the position of the IPC and the efficient drainage of the pleural space. In case of a VATS poudrage without IPC chest X-ray was done after removal of the second chest tube.

## Postoperative follow-up and long-term observation

Patients or their relatives were trained in correct handling of the IPC for fluid drainage at regular intervals. If they needed support by home nursing staff, this was organized. All patients with IPC were routinely seen at the outpatient department two or three weeks postoperatively. IPC was removed in local anaesthesia in case of daily fluid amount <50 ml and if there was no residuum of pleural effusion in the control chest X-ray.

## Statistical methods

P-values were calculated using the Mann Whitney U test. Statistical analysis of the primary and secondary outcomes was performed using prism statistical software. P-values of less than 0.05 were considered statistically significant.

## Results

### Demographics

A total of 117 operative procedures for malignant pleural effusion were performed at our institution from January 2012 until May 2015. 50 patients received VATS talc poudrage alone and 67 patients got an insertion of IPC in addition to VATS talc poudrage. A summary of patient's demographical data and tumour type is shown in Table 1.

	IPC group	Control group
Number of patients	67	50
Gender	Male: 38 (57%) Female: 29 (43%)	Male: 36 (72%) Female: 14 (28%)
Median age	M = 67 years (31-86)	M = 68 years (49-88)
Primary tumour (number of patients)	Lung tumour: 21 (28%) Breast Cancer: 8 (12%) Mesothelioma: 3 (5%) Melanoma 3 (5%) Other: 32 (49%)	Mesothelioma: 17 (34%) NSCLC: 9 (18%) Breast Cancer: 5 (10%) Other: 20 (40%)

**Table 1:** Patients Characteristics

Both groups are comparable in the underlying tumour type. In the IPC group there are three patients with MPM, which got also an IPC inserted because the tumour was widespread and the treatment was thought to be palliative.

### Hospitalization time

In comparison to the control group the overall median length of stay could be shortened by one day using the combined approach (seven days vs. eight days). In both groups one patient was hospitalized for 20 and 43 days, respectively, due to complications in connection with the underlying malignancy and not related to the thoracic surgery procedure (Table 2).

	IPC group	Control group
Overall length of stay (median)	7 days (3-43)	8 days (5-20)

**Table 2:** Overall length of stay.

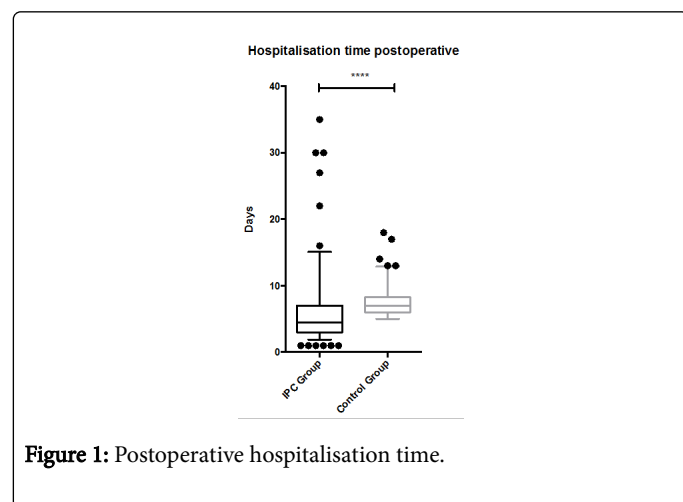
### Postoperative hospitalization time

The mean postoperative length of stay could be significantly shortened with our new approach ( $p < 0.0001$ ) (Table 3 and Figure 1).

### Time till removal of the standard thoracic drain

Results are listed in Table 4 and Figure 2. In the control group the chest tubes were removed according to the clinic standard. As a measure of caution and due to the limited experience with the new combined approach, we initially removed the chest tube after five days as well in the IPC group. But with good results we got more confident and nowadays we remove the standard thoracic drain on the first postoperative day. The overall median time till removal of the thoracic drain was significantly shorter as in the control group ( $p < 0.0001$ ).

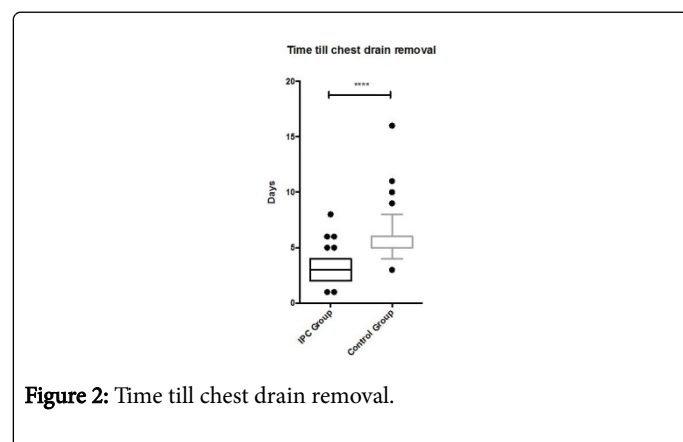
There was one patient whose drain was removed on the eighth postoperative day due to massive subcutaneous emphysema.



**Figure 1:** Postoperative hospitalisation time.

	IPC group	Control group
Postoperative hospitalization time (median)	4.5 days (1-35)	7 days (5-18)

**Table 3:** Postoperative hospitalization time.



**Figure 2:** Time till chest drain removal.

	IPC group	Control group
Days till drain (24 Ch) removal (median)	3 days (1-8)	5 days (4-16)

**Table 4:** Time till removal of the thoracic drain.

## Complications

We recorded five cases (10%) of unsuccessful pleurodesis with the thoroscopic talc pleurodesis alone. There was no case of recurrence of MPE in the group with the combined approach.

## Patient satisfaction

We recorded patient's satisfaction during the check up at our outpatient department. 90% of the patients reported to be satisfied with the course of treatment and intermittent pleural drainage did not cause them any distress during everyday life.

## Discussion

Patients with a malignant pleural effusion should be offered an effective treatment in terms of effusion prophylaxis. Given their limited life expectancy, unnecessary hospital admissions must be avoided. Symptoms like breathlessness and coughing impair their quality of life [9]. Current therapeutic options are repeated thoracentesis, pleurodesis or the insertion of an IPC. None of these treatments is perfect and all have their disadvantages, such as repeated procedures, long hospitalization or prolonged drainage with a catheter at home [10].

The first line of treatment, for patients in good performance status, is the insertion of a chest tube followed by pleurodesis [3]. Pleurodesis can either be performed by application of talc slurry or through VATS. Both are equally effective. The use of VATS allows a direct inspection of the pleura, the removing of adhesions and loculations of pleural fluid and to distribute talc evenly over the pleural surface [5]. VATS can also be used to obtain pleural biopsies with a diagnostic yield of 91-95% [11]. This makes it more versatile compared to the usage of simple talc slurries. However, according to control trials there is no difference in the pleurodesis success rate between the two procedures [5].

The insertion of an IPC is a safe and effective treatment to avoid recurrence of pleural effusion [3]. It is also an effective option to shorten the hospitalization time. It can be inserted on an outpatient basis as a day care procedure and further care is provided at home by trained healthcare professionals or by family members. However, there is a burden of on-going care such as wound dressing changes and drainages [12]. Nonetheless, according to the TIME2 trial this does not affect the quality of life in these patients [7]. The probability of spontaneous pleurodesis with an IPC insertion without additional talc poudrage lies between 26% and 76% [6,8,13]. The goal of regular drainage of IPC is symptom relief and promoting spontaneous pleurodesis by keeping the intrapleural space dry [6]. The IPC was designed to be left in situ for the remaining lifespan of the patient. However there is an increasing risk of complications the longer the IPC is left in place. According to current literature the most common complications are empyema, unspecified infection, and cellulitis [14]. These complications did not appear to be of major concern in our study. With the combination of talc and IPC the time till pleurodesis occurs is shorter and the risk of infection might be lowered because the IPC is left in situ for a shorter period of time.

The intention to combine both methods-VATS pleurodesis and IPC insertion-was to get the best out of both. According to our knowledge this is the first larger scale study combining these different types of treatment protocols. Furthermore, the combined procedure has not yet been proven to be beneficial to the patients.

We were not able to show a reduction of the overall hospitalisation time. Although there was a trend towards shorter hospital stay (seven days vs. eight days) this is not statistically significant.

A detailed look at the patients showed that the long hospitalization was caused by complications related to advanced cancer burden in the preoperative period and not because of the procedure. We did however show that the postoperative hospitalisation time could be significantly shortened. Patients with a MPE have many reasons to seek medical help and unfortunately, MPE is only one of the burdens faced by patients with advanced cancer disease.

During the period when we were performing thoroscopic talc pleurodesis only, we found a failure rate of about 10%. This is

consistent with current literature. Even in selected patients without significant trapped lung, the failure rate of pleurodesis 30 days postoperatively is around 30%. The longer the patient survives, the higher is the chance of treatment failure [5]. With our combined approach we did not have any cases of unsuccessful pleurodesis so far.

The concomitant insertion of IPC also offered a more liberal selection of patients for VATS talc pleurodesis. Even if the lung is (partially) trapped, the procedure can be done. A trapped lung is a contraindication for pleurodesis. However this is not always obvious before the operation, but with the combination therapy, partial pleurodesis could be achieved. The rest of the pleural fluid can be drained through IPC.

The treatment, with the combined therapy, at our department was finished sooner and additional treatment could be initiated earlier. It is not contraindicated to receive chemotherapy after IPC insertion, since it does not confer an increased risk of infections [15].

Patients with mesothelioma have a high incidence of tumour metastasis along IPC and at the side of the VATS ports. Usually the combined approach was not implemented in these patients. We believe that the use of IPC catheter in mesothelioma patients should be limited to those who have advanced disease and not to those whose initial treatment is thought to be curative. But with advanced symptomatic mesothelioma, IPCs are an effective method to palliate dyspnea [16].

The indication for this combination treatment needs to be considered carefully. Patients with a life span of less than a month should not be offered this procedure. Placement of an IPC under local anaesthesia is a safe alternative and also improves the quality of life. Prior studies comparing talc poudrage vs. insertion of an IPC did not demonstrate a significant difference in performance score and improvement of quality of life [7].

Patients were asked to come to our department for a check-up two to three weeks after the operation. However, some of them failed to come in because their oncologist performed all further care or their overall performance status was too bad. The IPC could be removed in about 2/3 of the time at our outpatient department within 1 or 2 months.

The primary aim of malignant pleural effusion management is palliation. Due to the study design we however lack objective data on symptom improvement and quality of life. Overall we received a positive feedback from patients at check-ups at our outpatient clinic. This positive feedback was encouraging and confirmed that our method is well accepted among our patients.

The heterogeneity of patients makes a single approach difficult. We strongly believe in this approach due to the simplicity of IPC insertion, low likelihood of complication and because it's uncomplicated use for the patients. With the overall positive experience we began to remove the standard thoracic drain on first postoperative day. We even consider doing the procedure without the additional chest tube in the future.

## Conclusion

Combining VATS talc poudrage and the insertion of IPC is a safe and effective strategy in pleural effusion prophylaxis. To assure quality

of life in terminally ill cancer patients is the main focus of their overall care. With our approach we significantly shortened the postoperative hospitalisation time, we could remove the standard thoracic drain sooner and we did not have any relapses so far.

## Limitations

Retrospective study with incomplete or lost patient data due to follow up.

## Conflict of Interest

None declared

## References

1. Lorenzo MJ, Modesto M, Pérez J, Bollo E, Cordovilla R, et al. (2014) Quality-of-Life assessment in malignant pleural effusion treated with indwelling pleural catheter: A prospective study. *Palliat Med* 28: 326-334.
2. Bethune N (1935) Pleural poudrage. *J Thorac Cardiovasc Surg* 4: 251-261.
3. Roberts ME, Neville E, Berrisford RG, Antunes G, Ali NJ, et al. (2010) Management of a malignant pleural effusion: British Thoracic Society Pleural Disease Guideline 2010. *Thorax* 65: ii32-40.
4. Cardillo G, Facciolo F, Carbone L, Regal M, Corzani F, et al. (2002) Long-term follow-up of video-assisted talc pleurodesis in malignant recurrent pleural effusions. *Eur J Cardiothorac Surg*. 21: 302-306.
5. Dresler CM, Olak J, Herndon JE, Richards WG, Scalzetti E, et al. (2005) Phase III intergroup study of talc poudrage vs. talc slurry sclerosis for malignant pleural effusion. *Chest* 127: 909-915.
6. Tremblay A, Michaud G (2006) Single-center experience with 250 tunnelled pleural catheter insertions for malignant pleural effusion. *Chest* 129: 362-368.
7. Davies HE, Mishra EK, Kahan BC, Wrightson JM, Stanton AE, et al. (2012) Effect of an indwelling pleural catheter vs chest tube and talc pleurodesis for relieving dyspnea in patients with malignant pleural effusion: the TIME2 randomized controlled trial. *Jama*, 307: 2383-2389.
8. Fysh ETH, Waterer GW, Kendall PA, Bremner PR, Dina S, et al. (2012) Indwelling pleural catheters reduce inpatient days over pleurodesis for malignant pleural effusion. *Chest* 142: 394-400.
9. Davies HE, Lee YC (2013) Management of malignant pleural effusions: questions that need answers. *Curr Opin Pulm Med* 19: 374-379.
10. Azzopardi M, Porcel JM, Koegelenberg CFN, Lee YCG, Fysh ETH (2014) Current Controversies in the Management of Malignant Pleural Effusions. *Semin Resp Care Med* 35: 723-731.
11. Froudarakis ME (2011) New challenges in medical thoracoscopy. *Respiration* 82: 197-200.
12. Chee A, Tremblay A (2011) The use of tunneled pleural catheters in the treatment of pleural effusions. *Curr Opin Pulm Med* 17: 237-241.
13. Suzuki K, Servais EL, Rizk NP, Solomon SB, Sima CS, et al. (2011) Palliation and pleurodesis in malignant pleural effusion: the role for tunneled pleural catheters. *J Thorac Oncol* 6: 762-767.
14. Meter MEM Van, Mckee KY, Kohlwe RJ (2011) Efficacy and Safety of Tunneled Pleural Catheters in Adults with Malignant Pleural Effusions: A Systematic Review. *J Gen Intern Med* 26: 70-76.
15. Morel A, Mishra E, Medley L, Rahman NM, Wrightson J, et al. (2011) Chemotherapy should not be withheld from patients with an indwelling pleural catheter for malignant pleural effusion. *Thorax* 66: 448-449.
16. Tremblay A, Patel M, Michaud G (2005) Use of tunnelled pleural catheters in malignant mesothelioma. *J Bronchol Interv Pulmonol* 12: 203-206.