

Case report

QJM

Haemodialysis in *Taxus Baccata* poisoning

M. DAHLQVIST¹, R. VENZIN², S. KÖNIG³, K. FABER⁴, W. WEINMANN³, S. TERBECK¹,
A. CESCHI⁴ and M.W. DÜNSER⁵

From the ¹Department of Intensive Care Medicine, ²Department of Nephrology and Hypertension, Inselspital, Bern Medical University, ³Institute of Forensic Medicine, Medical University of Bern, Bern, ⁴Swiss Toxicological Information Centre, Zürich, Switzerland and ⁵Department of Anaesthesiology, Perioperative and General Intensive Care Medicine, Salzburg General Hospital and Paracelsus Private Medical University, Salzburg, Austria

Address correspondence to Dr M.W. Dünser, Department of Anaesthesiology, Perioperative and General Intensive Care Medicine, Salzburg General Hospital and Paracelsus Private Medical University, Müllner Hauptstrasse 48, 5020 Salzburg, Austria. email: martin.duenser@i-med.ac.at

Case report

A 16-year-old Caucasian male with a known history of depressive disorders but no other diseases was found at home unconscious (Glasgow Coma Scale score, 7), bradycardic (heart rate, 45 b.p.m.), tachypnoic (respiratory rate, 30/min), and cyanotic. At admission to the emergency department of a regional hospital, the patient was hypotensive (70/30 mmHg), and his electrocardiogram revealed a broad-complex tachycardia with a heart rate of 155 b.p.m. The patient was endotracheally intubated and underwent repeated electrical and pharmacological (amiodarone, 300 mg i.v.; magnesium, 2 g i.v.) cardioversion attempts. Subsequently, tachycardia degenerated into bradycardic sinus rhythm with atrioventricular blockade and finally asystole. Following 30 min of cardiopulmonary resuscitation including 6 mg epinephrine i.v. and 3 mg atropine i.v., return of spontaneous circulation was achieved. Since broad-complex brady-/tachyarrhythmia persisted (Figure 1), and the patient required high-dosed epinephrine (3600 µg/h), he was transferred to the intensive care unit of a tertiary care university hospital. Activated charcoal (75 g) was administered by nasogastric tube because of a high suspicion of intoxication. Shortly after arrival at the admitting intensive care unit, the patient repeatedly needed mechanical and pharmacological resuscitation because of intermittent bradycardic

episodes/asystoles. Since external pacing failed, a transvenous pacemaker was inserted, and mild hypothermia (33°C) was induced for neuroprotection. In view of the ongoing need for high-epinephrine dosages (1200–2000 µg/h), aggravating lactic acidosis (pH, 7.24; HCO₃⁻, 16.2 mmol/L; base deficit, -10.7 mmol/l; lactate, 12.3 mmol/l) and persistent hypokalaemia (3.2 mmol/l), a 4.5 h haemodialysis session with a high-flux filter was performed as a last resort therapy. During the course of haemodialysis, cardiovascular function and heart rhythm stabilized, and epinephrine could be stopped. At the end of haemodialysis, acid–base status was normalized (pH, 7.46; HCO₃⁻, 24.6 mmol/l; base deficit, 0.5 mmol/l; lactate, 2.2 mmol/l; K⁺, 4.3 mmol/l). After rewarming from therapeutic hypothermia and discontinuation of sedation, the patient gradually regained consciousness and was extubated 36 h after intensive care unit admission. A detailed history revealed that he had gathered information about the application of *Taxus baccata* from the Internet and had ingested yew leaves in suicidal intention. Because of persistent symptoms of suicidality, he was transferred to a psychiatric institution where he continues to be seen. Physically, he made a full recovery. Both the patient and his parents have given written informed consent to publish the case anonymously in a scientific journal.

Measurements of taxine B in the serum and dialysate

Since the cause of poisoning was unclear by the time haemodialysis had been started, blood samples were drawn for diagnostic reasons before, during and after haemodialysis. Furthermore, samples of the dialysate were taken at the beginning and end of the haemodialysis session. Samples were then analysed in the toxicological laboratory at the local institute of forensic medicine. Taxine B, the alkaloid to which the highest toxicity is attributed, was extracted from branches of dried *T. baccata*.¹ Calibration samples were then prepared in blank serum at five concentrations between 1 and 1000 ng/ml. As sample preparation, protein precipitation was applied; 300 µl of acetonitrile containing an internal standard (d4-Midazolam) was added to 100 µl of calibration or patient sample. Quantification was then carried out on a hybrid triple quadrupole instrument (AB Sciex 3200 QTrap) using selected reaction monitoring scan mode. Two transitions for taxine B were used: 584 → 194 as quantifier, and 584 → 107 as qualifier. For the internal standard, the transition 330 → 295 was applied. The chromatographic separation was performed in 6 min using a linear gradient from 95% mobile phase A (water containing 0.1% formic acid) to 95% mobile phase B (acetonitrile containing 0.1% formic acid) followed by a 2 min equilibration step before the next injection. For each sample, a volume of 5 µl was injected onto a Phenomenex Synergy Polar HPLC column (50 × 2.0 mm). The concentration levels of the patient samples were finally calculated

by using area ratios (taxine B vs. the internal standard) against a linear regression of the calibration samples. Taxine B concentrations in both the serum and dialysate are presented in Figure 2.

Discussion

Taxus baccata, also known as the English yew (Figure 3), is an evergreen shrub whose toxicity is known since antiquity.² Despite of its severe toxicity, fatal poisonings with *Taxus* spp. are rarely reported.^{3,4} Most cases have been described in young subjects ingesting *Taxus* needles in suicidal intention.⁵ The toxicity of *Taxus* arises from its alkaloids taxines A and B which are present in all parts of the plant except the berries. Taxines block sodium and calcium channels, preferentially in cardiomyocytes thus causing conduction abnormalities.^{4,6} Treatment of *Taxus* poisoning is supportive.^{7,8} Our patient

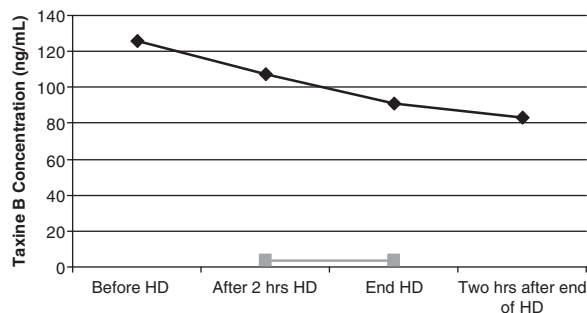


Figure 2. Concentrations of taxine B in the serum (black line) and urine (grey line) before, during and after haemodialysis.

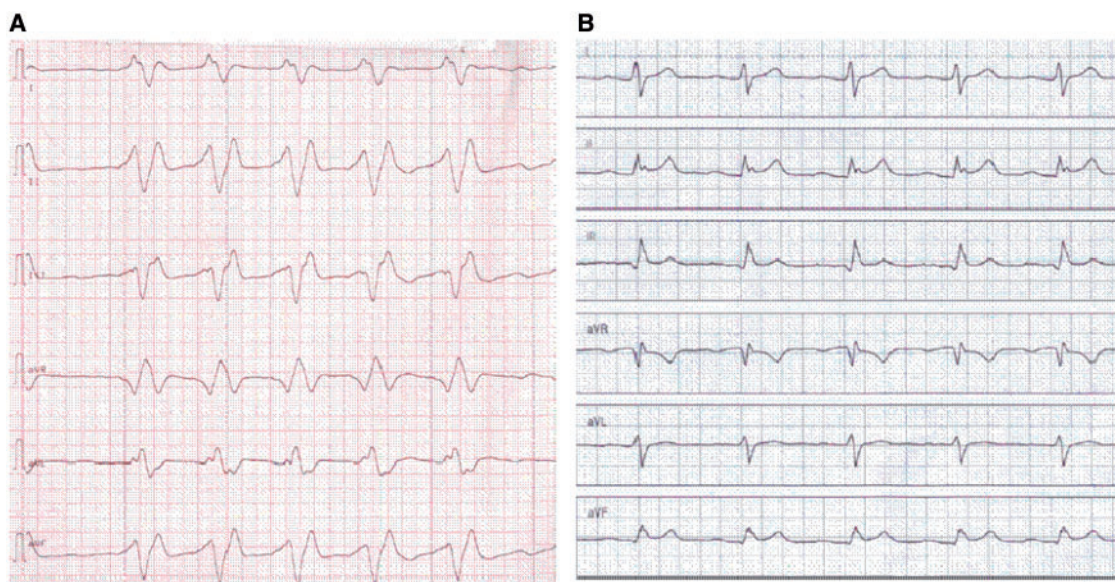


Figure 1. Electrocardiogram (25 mm/s) at intensive care unit admission (A) and 1 day following *Taxus baccata* poisoning (B).



Figure 3. *Taxus baccata* leaves with berries. Courtesy of Dr Chrisine Rauber-Lüthy of the Swiss Toxicological Information Centre, Zürich/Switzerland.

presented with typical symptoms of *Taxus* intoxication, i.e. broad-complex brady/tachyarrhythmia with atrioventricular blockade, depressed consciousness and respiratory distress.^{2-4,6-8} Further signs of yew intoxication are nausea, vomiting, abdominal pain and seizures, all of which could not be determined in the patient due to reduced consciousness. In line with earlier reports,⁹ our patient informed himself about the toxicity of *Taxus baccata* on various web sites.

Considering the large volume of distribution (60 l/m²) of the chemotherapeutic drug paclitaxel, which is an alkaloid extracted from *Taxus*, and the physicochemical properties of taxines (high molecular weight and relative water insolubility),^{10,11} effective removal of taxines by haemodialysis appears unlikely. By measuring taxine B levels before, during and after haemodialysis in the serum and dialysate, our data confirm this assumption and implies that taxine B cannot be relevantly eliminated by haemodialysis despite the use of a high-flux filter. Given the close chemical structure of taxines A and B, it is unlikely that taxine A but not taxine B is effectively removed by haemodialysis. Instead, the linear decrease in taxine B serum levels observed in our patient, suggests a endogenous zero-order elimination kinetic of taxines.

Nonetheless, the condition of our patient substantially improved during haemodialysis indicating a potential cause-effect relationship. In view of the course of taxine serum levels, we can exclude that clinical improvement was due to an exponential decrease of taxine B serum concentrations. Yet, it is theoretically possible, though practically unlikely, that taxine serum levels fell below a putative toxic

threshold during haemodialysis, thus explaining the rapid stabilization of the patient. Several mechanisms related to haemodialysis may have contributed to cardiovascular stabilization (e.g. improvement of haemodynamic function, correction of metabolic acidosis with reduction of the free fraction of taxines and normalization of hypokalaemia). A synergistic effect of electrolyte abnormalities and taxine B toxicity has been suggested before.¹²

In conclusion, this case report strongly suggests that taxines, the toxic alkaloids of *Taxus* spp., cannot be effectively removed by haemodialysis. Nevertheless, rescue haemodialysis may be beneficial, particularly in patients presenting with acid-base or electrolyte disturbances.

Conflict of interest: None declared.

References

1. Frommherz L, Kintz P, Kijewski H, Köhler H, Lehr M. Quantitative determination of taxine B in body fluids by LC-MS-MS. *Int J Legal Med* 2006; **120**:346–51.
2. Krenzelok EP, Jacobsen TD, Aronis J. Is the yew really poisonous to you? *J Toxicol Clin Toxicol* 1998; **36**:219–23.
3. Van Ingen G, Visser R, Peitenburg H, Van Der Ark AM, Voortman M. Sudden unexpected death due to *Taxus* poisoning. A report of five cases, with review of the literature. *Forensic Sci Int* 1992; **56**:81–7.
4. Willaert W, Claessens P, Vankelecom B, Vanderheyden M. Intoxication with *Taxus Baccata*: Cardiac arrhythmias following yew leaves ingestion. *Pace* 2002; **25**:511–2.
5. Pietsch J, Schulz K, Schmidt U, Andresen H, Schwarze B, Dreßler J. A comparative study of five fatal cases of *Taxus* poisoning. *Int J Legal Med* 2007; **121**:417–22.
6. Pilz B, Mesner C, Baetgen S, Luft FC. Coma in a park. *Lancet* 1999; **354**:1090.
7. Panzeri C, Bacis G, Ferri F, Rinaldi G, Persico A, Liberti F, et al. Extracorporeal life support in a severe *Taxus baccata* poisoning. *Clin Toxicol* 2010; **48**:463–5.
8. Von Dach B, Streuli RA. Lidocaine treatment of poisoning with yew needles (*Taxus baccata*). *Schweiz Med Wochenschr* 1988; **118**:1113–16.
9. Wehner F, Gawatz O. Suicidal yew poisoning – from Caesar to today – or suicide instructions on the internet. *Arch Kriminol* 2003; **211**:19–26.
10. Wilson CR, John-Michael Sauer JM, Hooser SB. Taxines: a review of the mechanism and toxicity of yew (*Taxus* spp.) alkaloids. *Toxicol* 2000; **39**:175–85.
11. Wiemik PH, Schwartz EL, Strauman JJ, Dutcher JP, Lipton RB, Paietta E. Phase I clinical and pharmacokinetic study of taxol. *Toxicol* 2001; **39**:175–85.
12. Feldman R, Chrobak J, Liberek Z, Szajewski J. 4 cases of poisoning with the extract of yew (*Taxus baccata*) needles. *Pol Arch Med Wewn* 1988; **79**:26–9.