ESC European Society of Cardiology

European Heart Journal - Cardiovascular Imaging (2018) **19**, 398–404
doi:10.1093/ehjci/jex181

Transcatheter aortic valve thrombosis: incidence, clinical presentation and long-term outcomes

Anna Franzone[1], Thomas Pilgrim[1], Alan G. Haynes[2], Jonas Lanz[1], Masahiko Asami[1], Fabien Praz[1], Lorenz Räber[1], Eva Roost[3], Bettina Langhammer[3], Stephan Windecker[1], and Stefan Stortecky[1]*

[1]Department of Cardiology, Swiss Cardiovascular Center Bern, Bern University Hospital, Freiburgstrasse 8, 3010 Bern, Switzerland; [2]Institute of Social and Preventive Medicine and Clinical Trials Unit, University of Bern, Finkenhubelweg 11, 3012 Bern, Switzerland; and [3]Department of Cardiovascular Surgery, Swiss Cardiovascular Center Bern, Bern University Hospital, Freiburgstrasse 8, 3010 Bern, Switzerland

Received 20 April 2017; editorial decision 2 June 2017; accepted 19 June 2017; online publish-ahead-of-print 29 July 2017

Aims To assess the incidence, management and long-term outcomes of transcatheter heart valve thrombosis (THVT).

Methods and results Between August 2007 and February 2016, 1396 patients were included in the Bern TAVI Registry and prospectively followed-up through echocardiographic and clinical evaluation. THVT was suspected in case of: (i) a mean transvalvular pressure gradient greater than 20 mmHg at transthoracic echocardiography, or (ii) an increase of more than 50% of the mean transvalvular pressure gradient compared with previous measurements or (iii) new symptoms or signs of heart failure with the presence of thrombus documented by transoesophageal echocardiography or multi-slice computed tomography. THVT occurred in 10 patients (0.71%) at variable time points after TAVI. Increased transvalvular pressure gradients were recorded in all patients and 7 out of 10 patients were symptomatic. Oral anticoagulant therapy (with vitamin K antagonists or non-Vitamin K antagonists) was initiated in all but two patients and resulted in normalization of transvalvular pressure gradients and amelioration of clinical status within 1 month. At long-term follow-up (between 10 and 25 months after valve thrombosis), echocardiographic findings were stable and no adverse events were reported.

Conclusion THVT is rarely detected at routine clinical and echocardiographic evaluation after TAVI. Oral anticoagulation appears effective to normalize transvalvular gradients in the majority of cases with stable clinical and haemodynamic evolution during long-term follow-up.

Keywords transcatheter aortic valve implantation • thrombosis • oral anticoagulant therapy

Introduction

Transcatheter aortic valve implantation (TAVI) is preferred over surgical aortic valve replacement (SAVR) in patients at extreme or high-surgical risk.[1] The proportion of lower risk patients undergoing TAVI continues to increase in view of favourable data among intermediate-risk patients and as consequence of the simplification of the procedure.[2–4] In this context, continuous surveillance of the transcatheter aortic valve durability has emerged. Although transcatheter aortic bioprostheses show superior haemodynamic performance in terms of transvalvular gradients and orifice area up to 5 years after the implantation compared with surgical valves, several reports recently described cases of valvular dysfunction attributable to subclinical or clinical thrombosis that occurred at variable time points after TAVI.[5–11] In the majority of cases, initiation of oral anticoagulant therapy proved effective in treating transcatheter aortic valve dysfunction and ameliorate clinical conditions of patients with symptoms at presentation, providing evidence of the putative role of thrombosis in the development of prosthesis dysfunction. Standardized protocols that indicate the optimal type and duration

* Corresponding author. Tel:+41 31 632 34 78; Fax:+41 31 632 11 31. E-mail: stefan.stortecky@insel.ch

Published on behalf of the European Society of Cardiology. All rights reserved. © The Author 2017. For permissions, please email: journals.permissions@oup.com.

source: https://doi.org/10.7892/

Downloaded from https://academic.oup.com/ehjcimaging/article-abstract/19/4/398/4056170
by E-Library Insel user
on 22 May 2018

of the pharmacological therapy to adopt in these cases are currently lacking. In addition, the impact of transcatheter heart valve thrombosis (THVT) and different regimens of anticoagulant therapy on long-term clinical outcomes is largely unknown and based on observations and limited follow-up after the diagnosis of THVT.

We sought to evaluate the frequency of THVT, its management and impact on long-term clinical outcomes among patients included into a prospective registry with active follow-up based on periodic clinical visits and echocardiographic evaluation.

Methods

Study population

Between August 2007 and February 2016, clinical, procedural and follow-up data of 1396 consecutive patients undergoing TAVI at our institution were collected in the Bern TAVI Registry. The decision to perform TAVI was based on the evaluation of the local multi-disciplinary heart team. The procedure was performed according to standardized protocols; the choice of access site, type and size of the device was based on a comprehensive evaluation of clinical and anatomical characteristics of each patient at baseline. All patients received peri-interventional heparin at a dose of 5000 IU or 70 IU/kg. Standard antithrombotic treatment at discharge comprised dual antiplatelet therapy (DAPT, aspirin and clopidogrel) for 6 months followed by lifelong aspirin. In patients with atrial fibrillation or other indication for oral anticoagulation, the adoption of an anti-thrombotic regimen (anticoagulant agents alone or in combination with single or dual antiplatelet therapy) was tailored according to the patients risk profile. The registry is approved by the local ethic committee and all participants provided written informed consent prior to inclusion.

Follow-up procedures—echocardiographic evaluation

Post-TAVI management comprised of echocardiographic assessment of the transcatheter heart valve before discharge and clinical follow-up at scheduled time-points (30 days, 1 year and yearly thereafter). Transthoracic echocardiography was performed by board certified cardiologists using parasternal and apical views. Transcatheter heart valves were assessed according to recommendations of the Valve Academic Research Consortium (VARC-2) in terms of paravalvular leakage grading and the assessment of transvalvular gradients. Aortic valve velocity was estimated from the continuous wave Doppler on the 3-or 5-chamber apical views. Peak and mean transvalvular pressure gradients were calculated according to the Bernoulli equation. The stroke volume was recorded in the left ventricular outflow tract proximal to the aortic valve by pulsed-wave Doppler. Left ventricular outflow tract (LVOT) diameter was measured in the parasternal long axis view during mid-systole. The continuity equation was used to calculate the aortic valve area. Presence of paravalvular aortic regurgitation and grading was performed according to the Valve Academic Research Consortium criteria (VARC-2). Transoesophageal echocardiography (TEE) was performed in case of increased transvalvular gradients and suspected THVT. Longitudinal and transversal planes in the high- and low-oesophageal and gastric position were used to assess THV frame and leaflet function. In case of suspected THVT, multi-detector computed tomography (MDCT) was performed to confirm the diagnosis.

MDCT acquisition and analysis

Contrast-enhanced MDCT examinations were performed as previously described.[12] Each patient received an intravenous injection of 80–120 mL of contrast medium via the antecubital vein at a flow rate of 5 mL/s and imaging acquisition was performed during an inspiratory breath-hold in a cranio-caudal direction. MDCT images were analysed using a standard software (Syngo Multimodality Workplace, Siemens Healthcare, Forchheim, Germany). Scans were evaluated for hypoattenuated leaflet thickening. THVT was defined by the presence of hypo-attenuating mass attached to the valve leaflets identifiable in at least two different projections—double-oblique axial and multi-planar reconstructions.

Definitions

THVT was suspected in presence of (i) a mean transprosthetic pressure gradient ≥20 mmHg at TTE, or (ii) an increase of more than 50% of the mean transprosthetic pressure gradients compared with previous assessment or (iii) recent or new onset of symptoms or signs of heart failure. The diagnostic confirmation was based on the TEE and MDCT evaluation.

Data management

Data collected at clinical follow-up were entered into a dedicated web-based database held at the Clinical Trials Unit, at Bern University Hospital. A clinical event committee, consisting of interventional cardiologists and cardiac surgeons, adjudicated all the clinical events on the basis of the VARC-2 criteria.

Statistical analysis

Continuous variables are reported as mean and standard deviation. Categorical data are reported as frequencies and percentages. The effect of baseline and procedural characteristics on the likelihood of having a THVT was assessed using univariate logistic regression. Effects are presented as odds ratios with 95% confidence intervals. Analyses were performed using Stata 14.1 (StataCorp, TX, USA).

Results

A total of 1396 patients were entered in the Bern TAVI Registry between August 2007 and February 2016. THVT was diagnosed in 10 patients (0.71%) at a median follow-up time of 379 days after TAVI (interquartile range, 35–524 days), as shown in *Figure 1*.

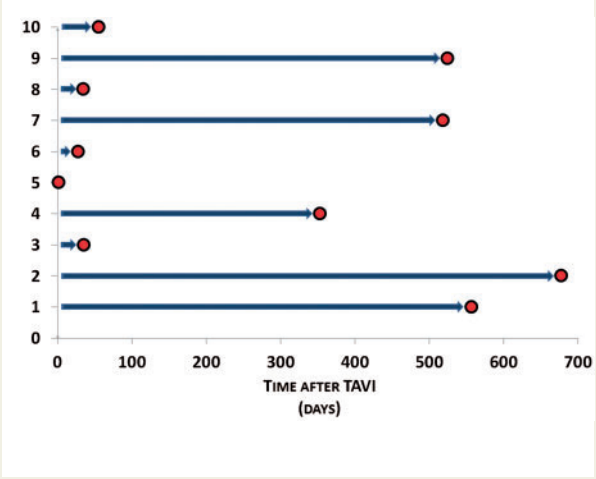

Figure 1 Timing of transcatheter heart valve thrombosis.

Downloaded from https://academic.oup.com/ehjcimaging/article-abstract/19/4/398/4056170
by E-Library Insel user
on 22 May 2018

Clinical and procedural characteristics of study population

Baseline clinical characteristics of patients with and without THVT are shown in *Table 1*. Mean age of patients with THVT was 79.7 ± 6.4; male and female were equally represented. Mean STS-PROM score was 5.3 ± 3.5%. Eight patients underwent TAVI for symptomatic, severe aortic valve stenosis and two patients were treated due to bioprosthetic heart valve failure after previous SAVR.

Procedural characteristics of the overall population are listed in *Table 2*. The majority of index procedures among patients with THVT (8/10) had been performed via transfemoral access. One case was complicated by the dislocation of the prosthesis into the ascending aorta necessitating the implantation of a second device. Three patients with subsequent THVT had undergone concomitant percutaneous coronary intervention due to significant coronary artery disease located in the proximal portion of one or more coronary arteries.

Clinical presentation of transcatheter aortic valve thrombosis

THVT was detected on the basis of increased transvalvular pressure gradients or symptoms at routine follow-up. At the time of THVT, the mean transprosthetic pressure gradient was 36.4 ± 8.3 mmHg. The majority of patients (7/10) presented with worsening dyspnoea (New York Heart Association functional class III) whereas three were asymptomatic. THVT was not associated with cerebrovascular accidents or other thromboembolic events. Representative images of TEE or MDCT that were performed to confirm the diagnosis of THVT are presented in *Figure 2*.

Anti-thrombotic therapy in patients with transcatheter aortic valve thrombosis

Anti-thrombotic regimens at different time points are detailed in *Table 3*. All patients received DAPT using 100 mg of aspirin and 75 mg of clopidogrel after the index procedure, whereas one patient with chronic atrial fibrillation and previous history of recent percutaneous coronary intervention received triple therapy consisting of DAPT and rivaroxaban at a dose of 15 mg/day. At the time of THVT, seven patients were still on DAPT and three on aspirin monotherapy: in one patient DAPT discontinuation occurred according to hospital prescription after 6 months, while in the other two patients DAPT was prematurely discontinued (<6 months after TAVI). Oral anticoagulation was initiated in all patients but two, who were managed with a continued prescription of DAPT due to excessive bleeding risk and medical non-compliance, respectively. A regimen including vitamin K antagonist only was prescribed in four patients; aspirin plus vitamin K antagonist was used in two patients; one patient received aspirin plus apixaban at a dose of 5 mg bid; one patient was treated with aspirin and rivaroxaban (at a dose of 20 mg/day). At long-term follow-up (between 10 and 25 months after TAVI), 8/10 patients were maintained on oral anticoagulation, whereas DAPT was continued in one of the two patients that did not receive oral anticoagulation.

Table 1 Baseline clinical characteristics

	Overall *N* = 1396	Patients w/o THVT *N* = 1386	Patients with THVT *N* = 10	OR (95% CI)	*P*-value
Age (years)	82.1 ± 6.1	82.1 ± 6.1	79.7 ± 6.4	0.95 (0.88–1.03)	0.26
Gender (female)	716 (51%)	711 (51%)	5 (50%)	0.95 (0.27–3.29)	0.94
Body mass index (kg/cm^2)	26.4 ± 5.1	26.4 ± 5.1	27.8 ± 4.3	1.05 (0.94–1.17)	0.40
Diabetes mellitus	364 (26%)	363 (26%)	1 (10%)	0.31 (0.04–2.48)	0.20
Hypertension	1189 (85%)	1180 (85%)	9 (90%)	1.57 (0.20–12.47)	0.65
Coronary artery disease	897 (64%)	890 (64%)	7 (70%)	1.30 (0.33–5.05)	0.70
Previous cerebrovascular accident	155 (11%)	154 (11%)	1 (10%)	0.89 (0.11–7.06)	0.91
COPD	183 (13%)	182 (13%)	1 (10%)	0.73 (0.09–5.82)	0.76
STS-PROM score	6.0 ± 4.1	6.0 ± 4.1	5.3 ± 3.5	0.95 (0.79–1.15)	0.58
LVEF (%)	53.9 ± 15.1	53.8 ± 15.1	57.2 ± 11.4	1.02 (0.97–1.07)	0.49
Mean transaortic gradient (mmHg)	42.2 ± 17.8	42.2 ± 17.8	45.7 ± 23.2	1.01 (0.98–1.04)	0.55
Aortic valve area (cm^2)	0.7 ± 0.2	0.7 ± 0.2	0.7 ± 0.3	2.01 (0.19–20.85)	0.57
Baseline medication					0.91
SAP	574 (41%)	568 (41%)	6 (60%)	1 (Reference)	
OAC	270 (19%)	270 (20%)	0 (0%)		
DAPT	217 (16%)	215 (16%)	2 (20%)	0.88 (0.18–4.40)	
OAC + SAP	109 (8%)	108 (8%)	1 (10%)	1.00 (1.00–1.00)	
Triple	23 (2%)	23 (2%)	0 (0%)		
None	199 (14%)	198 (14%)	1 (10%)		

Values are mean + SD, or *n* (%).
BMI, body mass index; COPD, chronic obstructive pulmonary disease; DAPT, dual antiplatelet therapy; LVEF, left ventricular ejection fraction; OAC, oral anticoagulant; PCI, percutaneous coronary intervention; SAP, single antiplatelet therapy; STS, Society of Thoracic Surgeons Predicted risk of mortality; SD, standard deviation; THVT, transcatheter heart valve thrombosis.

Downloaded from https://academic.oup.com/ehjcimaging/article-abstract/19/4/398/4056170
by E-Library Insel user
on 22 May 2018

Table 2 Procedural characteristics

	Overall *N* = 1396	Patients w/o THVT *N* = 1386	Patients with THVT *N* = 10	OR (95% CI)	*P* value
Access					0.64
Femoral	1178 (84%)	1170 (84%)	8 (80%)	1 (Reference)	
Transapical	200 (14%)	198 (14%)	2 (20%)	1.48 (0.31–7.01)	
Subclavian	15 (1%)	15 (1%)	0 (0%)		
Other	3 (0%)	3 (0%)	0 (0%)		
Device					0.51
Medtronic CoreValve	461 (33%)	459 (34%)	2 (20%)	1 (Reference)	
Edwards Sapien XT	386 (28%)	383 (28%)	3 (30%)	1.80 (0.30–10.81)	
Symetis Acurate	56 (4%)	55 (4%)	1 (10%)	4.17 (0.37–46.77)	
SJM Portico	13 (1%)	13 (1%)	0 (0%)		
Direct Flow Medical	1 (0%)	1 (0%)	0 (0%)		
Edwards Sapien 3	293 (21%)	291 (21%)	2 (20%)	1.58 (0.22–11.26)	
BSC Lotus	82 (6%)	80 (6%)	2 (20%)	5.74 (0.80–41.32)	
Medtronic Evolut R	87 (6%)	87 (6%)	0 (0%)		
Valve size (6)					0.009
23	227 (16%)	221 (16%)	6 (60%)	1 (Reference)	
25	54 (4%)	54 (4%)	0 (0%)		
26	562 (41%)	560 (41%)	2 (20%)	0.13 (0.03–0.66)	
27	56 (4%)	54 (4%)	2 (20%)	1.36 (0.27–6.95)	
29	400 (29%)	400 (29%)	0 (0%)		
31	80 (6%)	80 (6%)	0 (0%)		
Post-transvalvular mean gradient (mmHg)	7.7 ± 4.3	7.7 ± 4.2	9.4 ± 5.4	1.06 (0.95–1.18)	0.38
Pre-dilation	1102 (79%)	1095 (79%)	7 (70%)	0.62 (0.16–2.41)	0.51
Post-dilation	322 (23%)	320 (23%)	2 (20%)	0.83 (0.18–3.94)	0.81
Valve in series	21 (2%)	20 (1%)	1 (10%)	7.59 (0.92–62.76)	0.14
Coronary revascularization	195 (14%)	192 (14%)	3 (30%)	2.67 (0.68–10.40)	0.19
Discharge medication					**0.78**
SAP	63 (5%)	63 (5%)	0 (0%)		
OAC	95 (7%)	95 (7%)	0 (0%)		
DAPT	833 (61%)	824 (61%)	9 (90%)	0.73 (0.09–5.86)	
OAC + SAP	294 (22%)	294 (22%)	0 (0%)		
Triple	68 (5%)	67 (5%)	1 (10%)	1.00 (1.00–1.00)	
None	8 (1%)	8 (1%)	0 (0%)		

Values are mean + SD, or *n* (%).
DAPT, dual antiplatelet therapy; OAC, oral anticoagulation; PCI, percutaneous coronary intervention; SAP, single antiplatelet therapy; THVT, transcatheter heart valve thrombosis.

Follow-up

After the diagnosis of THVT, all patients were followed-up through clinical and echocardiographic evaluation at different time points up to 25 months. No additional MDCT evaluations were performed. At a median time of 4 weeks after THVT, all subjects were asymptomatic. One patient on oral anticoagulation died from carcinoma at day 165 after TAVI. As shown in *Figure 3*, transvalvular pressure gradients were normalized in all but two patients that maintained on antiplatelet therapy due to excessive bleeding risk and medical non-compliance, respectively. They were closely monitored using regular TTE evaluations that proved stable, elevated pressure gradients up to 2 years and 11 months after the diagnosis of THVT, respectively. None of the patients suffered from cerebrovascular events, any other thromboembolic complication, cardiac death or clinically significant bleeding during the observational period and in the absence of symptoms, no additional investigations were performed.

Discussion

The salient findings of this study investigating the frequency, the management and long-term outcomes of THVT among patients undergoing TAVI can be summarized as follows:

- THVT was detected in less than 1% of patients undergoing routine clinical and echocardiographic follow-up after TAVI.
- After initiation of oral anticoagulation, transprosthetic pressure gradients returned to normal values within one month of treatment.

Downloaded from https://academic.oup.com/ehjcimaging/article-abstract/19/4/398/4056170
by E-Library Insel user
on 22 May 2018

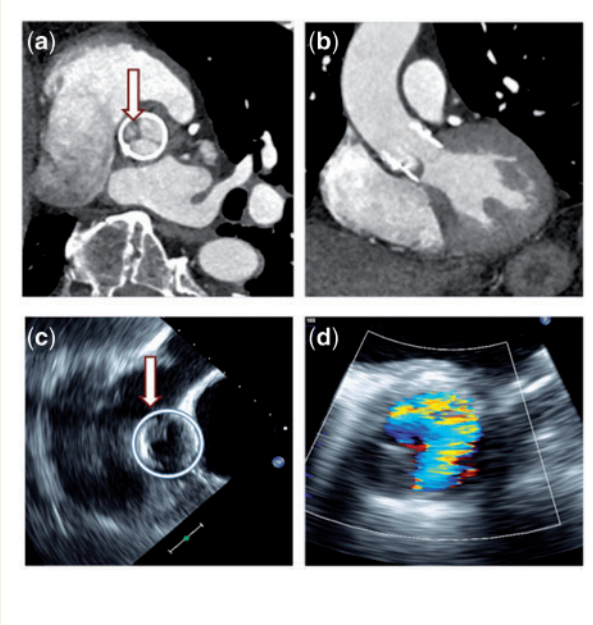

Figure 2 Computed tomographic images showing thrombosis of the non-coronary cusp in transverse (*A*) and sagittal view (*B*). 2D transoesophageal echocardiography showing thrombotic mass filling the non-coronary cusp (*C*) and immobile non-coronary cusp according to colour Doppler (*D*).

- Long-term use of oral anticoagulant therapy resulted in stable echocardiographic findings among patients evaluated up to 2 years after valve thrombosis.

Thrombus formation is a common cause of failure of blood-contacting medical devices.[13] While thrombosis of bioprosthetic surgical heart valves has been underreported, THVT represents an emerging issue and a potential speed bump for the expansion of TAVI. It was first described in two patients treated with early generation transcatheter aortic valves that experienced new onset heart failure in combination with elevated transvalvular pressure gradients.[5,14] Since then, several case reports have been published and raised the awareness of this phenomenon. To date, two main conditions can be identified: clinically overt THVT and subclinical leaflet thrombosis. In the first case, thrombus formation can affect valve function and/or cause systemic thromboembolic events. On the other side, the diagnosis of subclinical thrombosis is based on the observation of reduced leaflet motion along with corresponding hypo-attenuating opacities at follow-up MDCT. This variability in definitions and methods of detection challenge a precise estimate of THVT. In the present study, the occurrence of THVT was assessed on the basis of clinical judgement and routine echocardiographic surveillance after TAVI. THVT was found in 0.71% of patients which is in line with previous reports describing cases of THVT diagnosed by echocardiographic and clinical evaluation.[9] Nevertheless, this approach is likely to underestimate the actual occurrence of the phenomenon as, in dedicated MDCT studies, features of subclinical thrombosis were observed in 4–14% of patients after TAVI.[8,15–18] Hereto, patients included in the RESOLVE and SAVORY registries

Table 3 Anti-thrombotic therapy in patients with transcatheter aortic valve thrombosis

	1	2	3	4	5	6	7	8	9	10
Discharge (after TAVI)	ASA, clopidogrel	ASA, clopidogrel	ASA, clopidogrel	ASA, clopidogrel	ASA, clopidogrel	ASA, clopidogrel	ASA, clopidogrel	ASA, clopidogrel	ASA, clopidogrel, rivaroxaban 15 mg/die	ASA, clopidogrel
At THVT diagnosis	ASA, clopidogrel	ASA, clopidogrel	ASA	ASA, clopidogrel	ASA, clopidogrel	ASA	ASA, clopidogrel	ASA, clopidogrel, rivaroxaban 20 mg/die	ASA	ASA, clopidogrel
Treatment of THVT	Phenprocoumon	ASA, apixaban 5 mg bid	ASA, clopidogrel	Phenprocoumon	Phenprocoumon	ASA, clopidogrel	ASA,			
Phenprocoumon	ASA, Phenprocoumon	ASA, rivaroxaban 20 mg/die								
Longer-term follow-up (months after THVT)	Phenprocoumon (13)	ASA, Apixaban 5 mg bid (21)	ASA (25)	Phenprocoumon (18)	Phenprocoumon (3)	ASA, clopidogrel (12)	ASA, Phenprocoumon (19)	ASA, Phenprocoumon (19)	Phenprocoumon (21)	ASA, Phenprocoumon (10)

ASA, acetylsalicylic acid; TAVI, transcatheter aortic valve implantation; THVT, transcatheter heart valve thrombosis.

Downloaded from https://academic.oup.com/ehjcimaging/article-abstract/19/4/398/4056170
by E-Library Insel user
on 22 May 2018

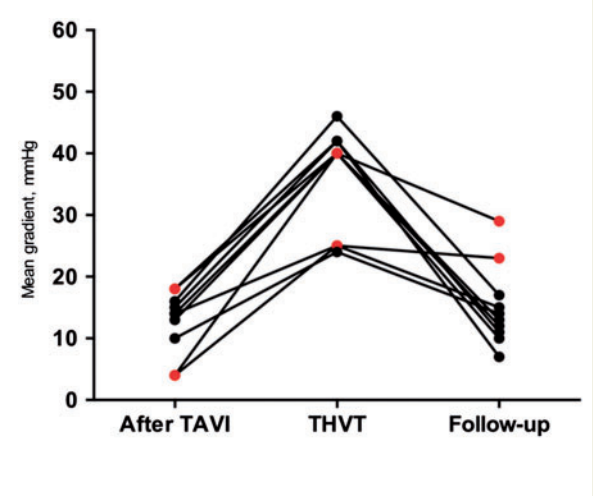

Figure 3 Transprosthetic pressure gradients measured at transthoracic echocardiography at the time of transcatheter aortic valve thrombosis at the longest available follow-up for each patient. Red dots indicate patients treated with antiplatelet agents.

($n = 931$) represent the largest cohort with systematic MDCT evaluation of leaflet motion after bioprosthetic aortic valve implantation. Abnormal leaflet motion was found in 3.6% and 13.4% of patients after SAVR and TAVI, respectively.[18] Whether these subclinical imaging findings have a direct impact on valve durability or are associated with clinical outcomes is unknown and remains to be determined. Indeed, increase in aortic valve gradient of more than 10 mmHg and higher risk of transient ischaemic attacks were reported by Chakravarty *et al.* in patients with subclinical leaflet thrombosis whereas previous reports did not find an association between imaging and clinical outcomes.

The potential mechanisms of THVT can be defined as procedure-, patient- or transcatheter heart valve-related. The procedure itself causes traumatic injury to the native valve leaflets that are left *in situ* after prosthesis implantation and may trigger thrombosis through the increased expression of tissue factor on the endothelial surface and local activation of the extrinsic coagulation pathway. Similarly, excessive catheter manipulation or aggressive post-dilation may contribute to leaflet damage. Incompletely apposed transcatheter heart valves may create areas of blood stasis or turbulence that can delay endothelialization and promote local thrombus formation. Furthermore, conditions associated with a hypercoagulable status (chronic renal disease, anaemia, diabetes, low cardiac output) are frequent in patients undergoing TAVI. So far, the majority of reported cases of THVT were in patients receiving a balloon-expandable valve. However, we found no interaction between valve types and THVT. Conversely, an association with valve size was observed with THVT occurring more often in small valves (<23 mm). Rheological perturbations and increased shear stress associated with patient–prosthesis mismatch may play a role in thrombus formation. In addition, smaller prosthesis size was found independent predictors of valve haemodynamic deterioration at 1 year after TAVI.

Valve-in-valve procedures have also been associated with increased risk of valve haemodynamic deterioration with smaller effective aortic annulus within surgical prosthesis accounting for higher mean gradients after TAVI. Interestingly, 2 of 10 patients that experienced THVT in our series received TAVI because of failed surgical prosthesis. The limited sample size of our study does not allow for definitive conclusions about the correlation between valve-in-valve procedure and THVT. However, future investigation is needed to evaluate the occurrence of this phenomenon in this setting as the management of anti-thrombotic therapy could be particularly challenging in these patients that are usually elderly and with high-risk profile.[19]

The available evidence suggests that subclinical valve thrombosis may be observed with different devices at different time points after TAVI and the routine use of MDCT is currently not recommended outside dedicated study protocols. In this context, our study provides an estimation of the occurrence of THVT as assessed by clinical evaluation at follow-up in a real world TAVI population. In a similar retrospective analysis of 642 patients, Jose *et al.*[20] recently reported a clinically detected rate of THVT of 2.8%. This mismatch with our data highlights the urgent need for unanimous definition of THVT and standardized protocols for its detection.

The general observation that prompt initiation of anticoagulation therapy was associated with the normalization of echocardiographic and clinical findings in our cohort is consistent with available evidence.[9] Several regimens of anticoagulation therapy have been adopted through the published reports and there is evidence of comparable effectiveness of novel oral anticoagulants and warfarin.[18] Moreover, the absence of anticoagulation therapy was identified as independent risk factor for the occurrence of transcatheter aortic valve dysfunction.[21] After initiation of oral anticoagulation in patients with THVT, transvalvular pressure gradients returned to baseline values and remained stable among patients maintained on oral anticoagulation therapy without bleeding events up to 2 years of follow-up. In order to apply the most appropriate treatment strategy for patients undergoing TAVI and avoid THVT, a standardized treatment recommendation for the optimal type and duration of pharmacological therapy after TAVI is needed, to ensure the balance between the risk of thrombotic events and haemorrhagic complications. In this context and pending, the results of dedicated randomized trials (NCT02556203, NCT02664649, NCT02247128), the choice of long-term oral anticoagulation in patients with clinically overt transcatheter aortic valve thrombosis seems effective and safe.

Limitations

This is an observational study reporting the experience of a single centre. The design of our study entails attrition and selection bias. Specifically, patients with sudden death or with uncertain cause of death may have died as consequence of unrecognized THVT. Thus, the true prevalence of TVHT in our cohort may be underestimated. Clinical conditions potentially increasing the thrombotic risk (such as thrombophilic diseases, resistance to antiplatelet agents) have not been considered. In addition, despite being an emerging marker of subclinical leaflet thrombosis, leaflet mobility was not systematically assessed neither at echocardiography nor MDCT.

Downloaded from https://academic.oup.com/ehjcimaging/article-abstract/19/4/398/4056170
by E-Library Insel user
on 22 May 2018

Conclusions

THVT was rarely detected at routine clinical and echocardiographic evaluation after TAVI. Transprosthetic pressure gradients were invariably increased whereas clinical presentation was variable. Long-term oral anticoagulant therapy was associated with the normalization of the transprosthetic pressure gradients and improvement of clinical status up to 2 years after the occurrence of THVT.

Conflict of interest: T.P. has received research grants to the institution from Edwards Lifesciences, Symetis and has received consulting fees from Symetis. F.P. has received consulting fees from Edwards Lifesciences outside the submitted work. L.R. has received research grants to the institution from stra Zeneca and research grants to the institution from Abbot and Sanofi/Regeneron. S.W. has received research grants to the institution from Boston Scientific, Bracco Pharmaceutical, Terumo and St Jude Medical.

References

1. Joint Task Force on the Management of Valvular Heart Disease of the European Society of Cardiology, European Association for Cardio-Thoracic Surgery, Vahanian A, Alfieri O, Andreotti F, Antunes MJ *et al*. Guidelines on the management of valvular heart disease (version 2012). *Eur Heart J* 2012;**33**:2451–96.
2. Leon MB, Smith CR, Mack MJ, Makkar RR, Svensson LG, Kodali SK *et al*. Transcatheter or surgical aortic-valve replacement in intermediate-risk patients. *N Engl J Med* 2016;**374**:1609–20.
3. Abdelghani M, Serruys PW. Transcatheter aortic valve implantation in lower-risk patients with aortic stenosis: is it justified to be the preferred treatment? *Circ Cardiovasc Interv* 2016;**9**:e002944.
4. Reardon MJ, Van Mieghem NM, Popma JJ, Kleiman NS, Sondergaard L, Mumtaz M *et al*. Surgical or transcatheter aortic-valve replacement in intermediate-risk patients. *N Engl J Med* 2017;**376**:1321–31.
5. Lancellotti P, Radermecker MA, Weisz SH, Legrand V. Subacute transcatheter CoreValve thrombotic obstruction. *Circ Cardiovasc Interv* 2013;**6**:e32–3.
6. Pingpoh C, Pache G, Nawras D, Guenkel L, Sami K, Zeh W *et al*. Valve thrombosis 7 months after transcatheter aortic valve implantation. *Ann Thorac Surg* 2014;**98**:1079–81.
7. Salido-Tahoces L, Hernandez-Antolin RA, Fernandez-Golfin C, Palomera-Rico A, Ayala-Carbonero A, Jimenez-Nacher JJ *et al*. Three cases of early lotus valve thrombosis. *JACC Cardiovasc Interv* 2016;**9**:983–6.
8. Leetmaa T, Hansson NC, Leipsic J, Jensen K, Poulsen SH, Andersen HR *et al*. Early aortic transcatheter heart valve thrombosis: diagnostic value of contrast-enhanced multidetector computed tomography. *Circ Cardiovasc Interv* 2015; doi: 10.1161/CIRCINTERVENTIONS.114.001596.
9. Latib A, Naganuma T, Abdel-Wahab M, Danenberg H, Cota L, Barbanti M *et al*. Treatment and clinical outcomes of transcatheter heart valve thrombosis. *Circ Cardiovasc Interv* 2015; doi: 10.1161/CIRCINTERVENTIONS.114.001779.
10. Makkar RR, Fontana G, Jilaihawi H, Chakravarty T, Kofoed KF, de Backer O *et al*. Possible subclinical leaflet thrombosis in bioprosthetic aortic valves. *N Engl J Med* 2015;**373**:2015–24.
11. Cota L, Stabile E, Agrusta M, Sorropago G, Pucciarelli A, Ambrosini V *et al*. Bioprostheses "thrombosis" after transcatheter aortic valve replacement. *J Am Coll Cardiol* 2013;**61**:789–91.
12. Buellesfeld L, Stortecky S, Kalesan B, Gloekler S, Khattab AA, Nietlispach F *et al*. Aortic root dimensions among patients with severe aortic stenosis undergoing transcatheter aortic valve replacement. *JACC Cardiovasc Interv* 2013; **6**:72–83.
13. Jaffer IH, Fredenburgh JC, Hirsh J, Weitz JI. Medical device-induced thrombosis: what causes it and how can we prevent it? *J Thromb Haemost* 2015;**13** (Suppl1):S72–81.
14. Trepels T, Martens S, Doss M, Fichtlscherer S, Schachinger V. Images in cardiovascular medicine. Thrombotic restenosis after minimally invasive implantation of aortic valve stent. *Circulation* 2009;**120**:e23–4.
15. Hansson NC, Grove EL, Andersen HR, Leipsic J, Mathiassen ON, Jensen JM *et al*. Transcatheter aortic heart valve thrombosis: incidence, predisposing factors, and clinical implications. *J Am Coll Cardiol* 2016;**68**:2059–2069.
16. Yanagisawa R, Hayashida K, Yamada Y, Tanaka M, Yashima F, Inohara T *et al*. Incidence, predictors, and mid-term outcomes of possible leaflet thrombosis after TAVR. *JACC Cardiovasc Imaging* 2016; doi: 10.1016/j.jcmg.2016.11.005.
17. Vollema EM, Kong WK, Katsanos S, Kamperidis V, van Rosendael PJ, van der Kley F *et al*. Transcatheter aortic valve thrombosis: the relation between hypo-attenuated leaflet thickening, abnormal valve haemodynamics, and stroke. *Eur Heart J* 2017;**38**:1207–1217.
18. Chakravarty T, Sondergaard L, Friedman J,D, Backer O, Berman D, Kofoed KF *et al*. Subclinical leaflet thrombosis in surgical and transcatheter bioprosthetic aortic valves: an observational study. *Lancet* 2017;**389**:2383–2392.
19. Deeb GM, Chetcuti SJ, Reardon MJ, Patel HJ, Grossman PM, Schreiber T *et al*. 1-Year results in patients undergoing transcatheter aortic valve replacement with failed surgical bioprostheses. *JACC Cardiovasc Interv* 2017;**10**:1034–44.
20. Jose J, Sulimov DS, El-Mawardy M, Sato T, Allali A, Holy EW *et al*. Clinical bioprosthetic heart valve thrombosis after transcatheter aortic valve replacement: incidence, characteristics, and treatment outcomes. *JACC Cardiovasc Interv* 2017; **10**:686–97.
21. Del Trigo M, Munoz-Garcia AJ, Wijeysundera HC, Nombela-Franco L, Cheema AN, Gutierrez E *et al*. Incidence, timing, and predictors of valve hemodynamic deterioration after transcatheter aortic valve replacement: multicenter registry. *J Am Coll Cardiol* 2016;**67**:644–55.

Downloaded from https://academic.oup.com/ehjcimaging/article-abstract/19/4/398/4056170
by E-Library Insel user
on 22 May 2018