

Accepted Manuscript



Perception of ABC (Asymmetry, Borders and Color) Parameters in the Screening for Melanoma. Model Exercise with Experienced Dermatologists

Luigi Naldi, MD, Giuseppe Falgheri, MD, Antonello De Bitonto, MD, Anna Di Landro, MD, Luigi Foiadelli, MD, Gianlorenzo Imberti, MD, Francesco Riva, MD, Simone Cazzaniga, DMath

PII: S0190-9622(17)32874-8

DOI: [10.1016/j.jaad.2017.12.035](https://doi.org/10.1016/j.jaad.2017.12.035)

Reference: YMJD 12201

To appear in: *Journal of the American Academy of Dermatology*

Received Date: 15 June 2017

Revised Date: 22 November 2017

Accepted Date: 10 December 2017

Please cite this article as: Naldi L, Falgheri G, De Bitonto A, Di Landro A, Foiadelli L, Imberti G, Riva F, Cazzaniga S, Perception of ABC (Asymmetry, Borders and Color) Parameters in the Screening for Melanoma. Model Exercise with Experienced Dermatologists, *Journal of the American Academy of Dermatology* (2018), doi: 10.1016/j.jaad.2017.12.035.

This is a PDF file of an unedited manuscript that has been accepted for publication. As a service to our customers we are providing this early version of the manuscript. The manuscript will undergo copyediting, typesetting, and review of the resulting proof before it is published in its final form. Please note that during the production process errors may be discovered which could affect the content, and all legal disclaimers that apply to the journal pertain.

1 **PERCEPTION OF ABC (ASYMMETRY, BORDERS AND COLOR) PARAMETERS IN THE**
2 **SCREENING FOR MELANOMA. MODEL EXERCISE WITH EXPERIENCED DERMATOLOGISTS**

3
4 Luigi Naldi,MD¹ Giuseppe Falgheri,MD² Antonello De Bitonto,MD³ Anna Di Landro,MD⁴ Luigi
5 Foadelli,MD² Gianlorenzo Imberti,MD¹ Francesco Riva,MD² Simone Cazzaniga,DMath^{4,5}

- 6
7 1. Department of Dermatology, Azienda Socio-Sanitaria Territoriale (ASST) Ospedale Papa
8 Giovanni XXIII, Bergamo - Italy
9 2. Agenzia per la Tutela della Salute, Bergamo - Italy
10 3. Policlinico S. Marco, Zingonia, Bergamo - Italy
11 4. Centro Studi Gruppo Italiano Studi Epidemiologici in Dermatologia, Bergamo - Italy
12 5. Department of Dermatology, Inselspital University Hospital, Bern - Switzerland

13
14 **Correspondence:** Prof. Luigi Naldi
15 Centro Studi GISED, Via Garibaldi 13/15 - 24122 Bergamo (Italy)
16 E-mai: luigi.naldi@gised.it
17 Tel. +39 035 2278 719 - 720 Fax +39 035 2278 673

18 **Word count:** 510

19 **Tables:** 1

20 **Figures:** 1

21
22 **Source of funding:** The study was supported by the Italian National Council on Research (CNR)
23 No. 92.02221.PF39.

24 **Conflict of interest:** The authors have no conflict of interest to disclose.

25 **To the Editor** - The ABCD rule (A for asymmetric shape, B for irregular borders, C for
26 variation in color and D for diameter greater than 6 mm) has been proposed as a reliable
27 and affordable screening method in melanoma campaigns.^{1,2} However, little is known about
28 the ability of examiners to agree on ABC parameters when faced with pigmented lesions.³
29 We designed a study to separately analyze judgments on ABC features, avoiding, as far as
30 possible, the influence of the potentially confounding effect of the observer's overall
31 diagnostic impression.

32 Twelve photographs of melanocytic nevi and eleven photographs of melanomas with
33 Breslow thickness ≤ 1.5 mm, were randomly selected from our file of excised lesions. For
34 judgment regarding symmetry and borders, the profiles of the selected lesions were traced
35 and the resultant silhouette was filled in black. To minimize the effect of dimension on the
36 judgment, all silhouettes were given the same area. For judgment regarding color, the
37 borders of the original photographs were concealed and the lesions were given a regular
38 circular border (Figure).

39 We organized two evaluation sessions, involving seven experienced dermatologists, three
40 weeks apart from each other. We projected slides obtained from the test material and
41 asked participants to independently express their judgment on symmetry, border and color
42 in a dichotomous way (e.g., color mainly homogeneous vs. mainly non-homogeneous). We
43 also organized a third session during which the original clinical photographs were shown
44 and participants were asked to classify lesions as melanocytic nevi or melanoma. Cohen's
45 kappa and Fleiss' kappa⁴ were used to assess intra-observer and inter-observer agreement
46 with multiple raters, respectively. The relation between the scores on ABC parameters and
47 the final diagnosis reached by dermatologists (i.e., nevus vs melanoma) was examined by

48 logistic regression analysis, and expressed as Odds Ratios (OR) with their 95% Confidence
49 Intervals (CI).

50 Variations were observed for intra-observer agreement on ABC parameters. The judgments
51 on borders had the highest values of agreement, with Cohen kappa ranging from 0.64 up to
52 1.00. Less satisfactory was intra-observer agreement for judgment on symmetry and color,
53 Cohen kappa ranging from 0.38 up to 0.81 for symmetry, and from 0.26 up to 0.72 for color.

54 The Table presents data on inter-observer agreement. The agreement was moderate to
55 substantial for judgment on borders and for the final diagnosis made by the dermatologists.

56 Based on logistic regression analysis, a diagnosis of melanoma was significantly associated
57 with judgment of irregular borders (OR 2.4, 95% CI 1.1 - 5.4) and haphazard color (OR 2.6,
58 95% CI 1.4 - 4.8), but not with judgment of asymmetric lesion (OR 1.3, 95% CI 0.6 - 2.9).

59 Our data point to the existence of variability in the interpretation of ABC parameters. We
60 documented high inter-observer agreement on the final diagnosis in the face of
61 unsatisfactory intra- and inter-observer agreement on specific features. Even if not a direct
62 proof of the cognitive mechanism involved, our data support the concept of an automatic
63 pattern recognition modality in the diagnosis of pigmented lesions.⁵ They also point to the
64 need for a more standardised terminology to describe the clinical features of pigmented
65 lesions.⁶

66

67 **Acknowledgements**

68 We wish to thank Gillian Jarvis for editorial assistance.

69

70

71

72 **References**

- 73 1. Abbasi NR, Shaw HM, Rigel DS, et al. Early diagnosis of cutaneous melanoma: revisiting
74 the ABCD criteria. *JAMA*. 2004;292(22):2771-2776.
- 75 2. American Academy of Dermatology Ad Hoc Task Force for the ABCDEs of Melanoma,
76 Tsao H, Olazagasti JM, et al. Early detection of melanoma: reviewing the ABCDEs. *J Am*
77 *Acad Dermatol*. 2015;72(4):717-723.
- 78 3. Aldridge RB, Zanotto M, Ballerini L, et al. Novice identification of melanoma: not quite as
79 straightforward as the ABCDs. *Acta Derm Venereol*. 2011;91(2):125-230.
- 80 4. Fleiss JL. *Statistical methods for rates and proportions*. 2nd ed. New York, NY: John Wiley ed;
81 1981:38-46.
- 82 5. Girardi S, Gaudy C, Gouvernet J, et al. Superiority of a cognitive education with
83 photographs over ABCD criteria in the education of the general population to the early
84 detection of melanoma: a randomized study. *Int J Cancer*. 2006;118(9):2276-2280.
- 85 6. Flood KS, Martin GJ, Robinson JK. Uniform Nomenclature to Describe Clinical Features of
86 Pigmented Lesions. *JAMA Dermatol*. 2017;153:973-975.

87

88

89 **Table** - Inter-observer agreement on ABC parameters and clinical diagnoses

90

Session	Kappa values			
	Symmetry	Borders	Color	Clinical diagnosis*
1 st	0.21	0.52	0.36	0.63
2 nd	0.32	0.62	0.32	

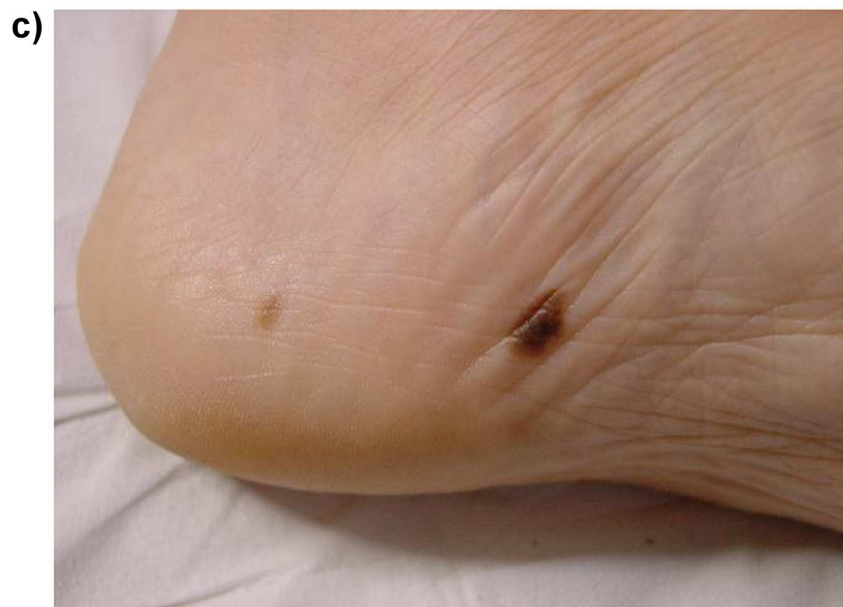
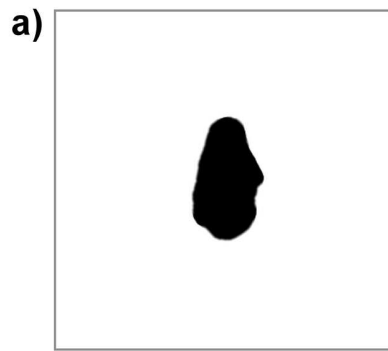
91

92

93 * This was assessed in a third final exercise

94

95 **Figure Legend-** Example of test materials prepared for the ABC perception exercise:
96 symmetry and borders were evaluated on a segmented version of the lesion filled in black
97 with a white background (a); judgment on color was performed on a regular ovoid shape
98 version of the original segmented lesion (b); original clinical photographs were used for the
99 final classification of lesions as melanocytic nevi or melanoma (c).



SCRIPT

ACCEP