

The Management of Bleeding in Exclusive Endoscopic Ear Surgery: Pilot Clinical Experience

Lukas Anschuetz^{1,2}, MD; Marco Bonali¹, MD; Pierre Guarino¹, MD; Filippo B. Fabbri¹;
Matteo Alicandri-Ciufelli¹, MD, FEBORL-HNS; Domenico Villari¹, MD; Marco
Caversaccio², MD; Livio Presutti¹, MD

¹Department of Otorhinolaryngology, Head & Neck Surgery, University Hospital of
Modena, Modena, Italy

²Department of Otorhinolaryngology, Head & Neck Surgery, Inselspital, University
Hospital and University of Bern, Bern, Switzerland

Corresponding Author

Lukas Anschuetz, MD

Department of Otorhinolaryngology, Head & Neck Surgery, University Hospital of
Modena, Modena, Italy, Via del Pozzo 71, 41100 Modena, Italy

Email: anschuetz.lukas@gmail.com

work: +390594222402, mobile: +393483895474, fax: +390594222454

Conflict of Interest

The authors declare no conflict of interest. LA holds a research fellowship by the
Bangerter-Rhyner Foundation, Bern, Switzerland and by Karl Storz GmbH,
Tuttlingen, Germany. The funders had no role in study design, data collection and
analysis, decision to publish or preparation of the manuscript.

Abstract

Objective: Transcanal exclusive endoscopic ear surgery requires the management of the endoscope and the surgical instruments in the external auditory canal. Bleeding in this narrow space is one of the most challenging issues, especially for novice endoscopic ear surgeons. We aim to assess the severity and occurrence of bleeding and describe strategies to control the bleeding during endoscopic ear surgery. We hypothesize that bleeding is reasonably controllable in endoscopic ear surgery.

Study Design: Case series with chart review.

Setting: Tertiary referral center.

Subjects and Methods: We retrospectively assessed 104 consecutive cases of exclusive endoscopic ear surgery at the University Hospital of Modena, Italy. The surgical videos and the patient charts were carefully investigated and analyzed.

Results: Used hemostatic agents were: injection of diluted epinephrine 1:200'000 (2% with mepivacaine), cottonoids soaked with epinephrine (1:1000), monopolar or bipolar cautery, washing with H₂O₂ and self-suctioning instruments. The localization of bleeding in the external auditory canal was most frequently the posterior superior part and inside of the middle ear it was the pathology itself. The statistical analysis revealed significant differences comparing the mean arterial pressure and the type of intervention between different bleeding scores.

Conclusion: The management of bleeding in endoscopic ear surgery is feasible using widely available hemostatic agents in reasonable frequency. This study gives an instructive overview on how to manage the bleeding in the exclusive endoscopic technique. Even highest bleeding scores could be managed in an exclusively endoscopic technique.

Key words: Endoscopic ear surgery; bleeding; anesthesiology; myringoplasty; tympanoplasty; cholesteatoma; stapedotomy

Accepted manuscript

Introduction

The exclusive endoscopic transcanal approach to the middle ear is nowadays gaining popularity for various indications¹. In almost every field of otologic surgery, even in pediatric patients² or approaches to the lateral skull base³, the endoscope has become a valuable tool. The main advantage of the endoscope is the enhanced visibility of the anatomy and pathology, due to the wide-angled views and the possibility to use angled scopes to explore hidden recesses such as the retro- and hypotympanum⁴. However, the one-handed surgical technique is challenging for the surgeon and bleeding in the external auditory canal (EAC) and the middle ear is a major concern. Due to the limited space in the EAC and the middle ear, a clean surgical field is mandatory to ensure patient safety and to benefit from the wide-angle vision offered by the endoscope. Moreover, even slight bleeding threatens the surgical field since the lens of the scope inside the EAC gets smeared. Since the aspiration of blood and debris requires the removal of the instrument from the EAC and the introduction of a suction tube, the management of bleeding is important to ensure the progress of the operation. The knowledge of the different considerations and procedures to ensure hemostasis is especially for novices in exclusively endoscopic ear surgery (EES) very important. The control of bleeding during the initial steps of the operation is the key to a successful take off in this emerging technique⁵.

However, a scientific analysis and an instructive description of the management of bleeding in EES is still lacking in literature. We aim to give an overview on the occurrence and the severity of bleeding during EES and to identify possible predicting factors for a more severe intraoperative bleeding. Furthermore, we aim to describe our experience on the various possibilities to achieve hemostasis in order to

successfully and safely accomplish the planned intervention. We hypothesize that bleeding is well controllable during EES.

Patients and Methods

We assessed 104 consecutive cases of exclusive endoscopic ear surgery performed at the University Hospital of Modena from November 2015 to March 2017. Surgical video recordings from our database were analyzed along with a retrospective clinical chart analysis. General data of the patients, personal medication and details of the continuously recorded anesthesiology protocols were assessed and tabularized. For this kind of retrospective investigation the local ethical committee of the University Hospital of Modena does not perform a formal ethical assessment. The study was performed according to the declaration of Helsinki. Statistical analysis was performed using GraphPad Prism.

The assessment of bleeding severity was performed according to the Boezaart grading scale⁶, which was initially designed for sinus surgery, but has recently found its use in otologic surgery as well⁷. This scale ranging from 0 to 5 is defined as follows: 0: no bleeding; 1: slight bleeding requiring no suction; 2: slight bleeding requiring occasional suctioning without threatening the surgical field; 3: slight bleeding requiring frequent suctioning, bleeding threatens surgical field a few seconds after removal of the aspiration; 4: moderate bleeding requiring frequent suctioning, bleeding threatens surgical field immediately after suction is removed; 5: severe bleeding: constant suctioning required, surgical field severely threatened. For every case two investigators assessed a bleeding score for the EAC and the middle ear. Additionally, we recorded the exact localization of the bleeding in the EAC and the middle ear.

The different methods used to achieve hemostasis during exclusive endoscopic ear surgery were identified to be the following: injection of diluted epinephrine 1:200'000 (2% with mepivacaine) into the EAC skin, bipolar or monopolar cautery (BOWA ARC 350 monopolar CUT maximal output power 300 W used at 10% of maximal power settings with a needle tip), epinephrine (1:1000) soaked cottonoids, washing with hydrogen peroxide (H₂O₂), use of a third hand and the use of self-suctioning instruments (Panetti instruments).

Results

We assessed a total of 104 surgical interventions. The surgical procedures were distributed as follows: tympanoplasty (+/- ossiculoplasty) for cholesteatoma (53%), stapedotomy (25%), type 1 tympanoplasty (13%), endoscopic approaches to the internal auditory canal (6%) and removal of middle ear tumors (3%). Twenty-three percent were cases of revision surgery and 15% were pediatric cases with age less than 16 years at the date of the operation. The main characteristics of the patients including bleeding severity and anesthesiological data are summarized in Table 1. The required hemostatic agents were analyzed according to the bleeding scale and divided into EAC and middle ear evaluation and the results summarized in Figure 1. The mean injection of diluted epinephrine 1:200'000 (2% with mepivacaine) into the EAC was 1.2 mL and mean 3.7 cottonoids soaked with epinephrine (1:1000) were necessary to control the bleeding. The use of monopolar cautery to elevate the tympano-meatal flap (TMF) was observed in 79% whereas the use of monopolar or bipolar cautery for hemostasis was necessary only in 12% and 13% respectively. The use of these basic hemostatic agents is illustrated in Figure 2. Inside the middle ear three epinephrine soaked cottonoids and one cottonoid without epinephrine were on average required to manage the bleeding. The monopolar and bipolar cautery for

hemostasis were used in 9% and 8% respectively. We observed two cases of extended glomus tympanicus type A, which were rated with the highest values on the bleeding scale. To allow constant suctioning of blood a second surgeon introduced an aspirator into the middle ear. Other used hemostatic agents were washing with H₂O₂ and self-suctioning instruments.

The localization of bleeding in the EAC was most frequently the posterior superior part (40.4%) followed by posterior inferior (20.2%), inferior (4.8%), anterior (2.9%) and multiple locations (26.9%). No specific bleeding location was observed in 4.8%. Inside the middle ear the most abundant source of bleeding was the pathology itself with 25.9% as well as granulation or scar tissue (8.7%). The most common anatomical source of hemorrhage was the anterior malleolar ligament (20.2%) and less frequent: the posterior malleolar ligament (1.9%). Multiple sources were observed in 16.4%. No bleeding was observed in 26.9% of the cases.

The continuously recorded mean arterial pressure (MAP) and the heart rate (HR) were analyzed according to the bleeding scale as shown in Figure 3. Due to age-related differences, the pediatric cohort has been excluded from this analysis. The statistical analysis revealed significant differences between the bleeding scale groups for the MAP in both EAC and middle ear validation. The HR differed statistically significant only in one comparison (EAC between bleeding scale 1 and 3). All other comparisons regarding the HR were statistically not significant.

The type of intervention was an important factor leading to statistically significant increased severity of bleeding in the middle ear. The comorbidities according to the ASA scale had no impact on bleeding (Table 2).

Discussion

This study assesses the occurrence and severity of bleeding during transcanal EES for various indications, as well as its management. Intraoperative bleeding has been considered a major concern of EES, especially when compared to microscopic approaches to the middle ear, where the two-handed technique allows constant suctioning of blood. Due to the one handed surgical technique, the management of bleeding is crucial to maintain the surgical field clean and not to impede with the progress of the operation. The development of optimal strategies is particularly important for beginners in EES, since the management of a possibly narrow and bleeding EAC may be frustrating⁵. In our experience the initial steps during elevation of the TMF are challenging to a novice surgeon and require patience to repeatedly clean the surgical field in order to safely perform the required surgical steps.

According to our results we suggest the injection of diluted epinephrine 1:200'000 (2% with mepivacaine) into the posterior superior part of the EAC skin. As assessed in this study the most common localization of bleeding is in the posterior and superior portion of the EAC, where the main vascular supply runs. Indeed, the bony portion is vascularized by the internal maxillary artery through its anterior tympanic and deep auricular branches, the superficial temporal artery and the posterior auricular artery⁸. Figure 4 illustrates the EAC and middle ear vascularization in a schematic drawing. From an anatomical point of view a retroauricular infiltration could be beneficial to achieve not only a peripheral vasoconstriction inside the EAC but rather an effect on the main trunk of the posterior auricular artery. The same consideration applies for a pre-tragal infiltration for the superficial temporal artery and its anterior auricular branches. However, this question would require proper investigation.

The elevation of the TMF starts thereafter using a monopolar cautery at lowest intensity. This is an important safety issue, as a theoretic risk from current spread for the facial nerve cannot be excluded. Using very low power for mono- and bipolar

coagulation, we did not observe any facial palsy in our cohort. Moreover, the skin is cauterized in a selective (point-shaped) manner in order to prevent retraction of the flap as shown in Figure 2. The incision is thereafter completed with cold instruments. Epinephrine soaked neuro-patties are used to pack sources of bleeding in order to achieve a clean surgical field. In average 3.7 neuro-patties were required per case to perform the elevation of the TMF. This is a very low number and therefore we can consider the effort to achieve a clean surgical field reasonable. Moreover, the injection of diluted epinephrine (1:200'000) and topical application of epinephrine (1:1000) can be considered safe, as previously investigated in functional endoscopic sinus surgery (FESS)^{9,10}. Persistent residual sources of bleeding are treated as required with monopolar or bipolar electro cautery. However it is crucial to use the cautery sparingly in order to avoid retraction of the TMF.

Inside the middle ear cleft, the bleeding is largely depending on the pathology encountered. Especially cholesteatomas with abundant granulation tissue or scar tissue in revision surgery are common sources of bleeding. The most severe bleeding however was observed during removal of highly vascularized glomus tympanicus type A tumors. As the middle ear bears more risk for iatrogenic damage the hemostatic agents were used even more conservative way. The careful application of cottonoids, patience and repeated cleaning of the surgical field is mandatory to safely perform the intervention. However, in cases of a dehiscent facial nerve we do not use epinephrine inside the middle ear. The rationale is not to impede with the neuronal micro-vascularization.

We wish to emphasize, that we did not observe any shift to the microscopic technique due to bleeding in the whole cohort. This fact itself represents a substantial argument to the critical voices concerning the management of bleeding in EES. Even highest bleeding scale scores could be managed with a purely endoscopic technique.

However, we have to consider that difficult cases were operated by experienced surgeons with at least 10 years of experience in EES and extensive prior experience in microscopic ear surgery. Therefore, we clearly conclude that novice surgeons to EES should not perform revision surgery, cases of extended cholesteatomas or middle ear tumor removal to take off with this technique. In our opinion it is important to start with simple tasks such as myringotomy and ventilation tube insertion or type 1 tympanoplasty.

Limitations of the present study are its retrospective design and the Boezaart bleeding scale, which was not primary developed for ear surgery and has been used only once before. Moreover, this subjective grading may be subject to a significant interobserver variability regarding the bleeding score. This issue could be addressed in the present study due to the use of recorded surgical videos for data collection. For cases with unclear bleeding score, the investigators were able to review the procedure several times in order to decide by consent, which grading would be most appropriate.

According to our results (Figure 4) the anesthesiologist plays a crucial role to the success of EES. We observed an association of higher bleeding scores to higher MAP. Adequate hemostasis depends on the anesthesiological management and appropriate preventive measures¹¹. However, controlled hypotension is not without risk: in addition to the adverse effects of certain pharmacologic agents, it may cause tissue hypoxia by reducing microcirculatory autoregulation of vital organs. Therefore, the anesthesiologist has to balance the MAP in order to safely perform a controlled hypotension¹². The anesthesiological management starts with appropriate pre-medication. In our experience the first choice in case of decompensated hypertension is intravenous clonidine 75-150 µg, while the second choice is labetalol 50 mg, followed by additional 10 mg every 10 minutes until reaching an ideal blood

pressure. According to Ramchandani et al. intravenous clonidine premedication is effective to obtain a clean surgical field also in patients undergoing middle ear or nasal surgery, even if presenting a normal blood pressure¹³.

A controlled intraoperative hypotension plays a key role since the patient's baseline mean arterial pressure may be reduced by 30% or kept at 60-70 mmHg.

Anesthesiological strategies for blood pressure control consist in either total intravenous anesthesia (TIVA) with propofol and remifentanil or inhalational anesthesia (IA) with propofol induction followed by sevoflurane 1-2% in association with remifentanil. Another important factor is the management of reflex tachycardia occurring with decreased MAP. Sevoflurane for instants causes a peripheral venous dilation and it is likely to produce a mild tachycardia as a compensatory reflex.

Despite a reduced MAP, the surgical field may not improve significantly, owing to reflex tachycardia maintaining cardiac output high. To address this phenomenon the administration of centrally acting presynaptic alpha-2 agonists (clonidine, dexmedetomidine), beta-blockers (esmolol) or magnesium sulfate have been proposed^{7,11}. Ryu et al. found that magnesium sulphate and remifentanil in combination with sevoflurane provided adequate controlled hypotension and proper surgical conditions for middle ear surgery. Moreover, patients receiving magnesium sulphate had a favorable postoperative course¹⁴. Our experience with standard IA is excellent. Although some authors prefer a TIVA, there are no significant differences in rate of blood loss (in milliliters per hour) or subjective measure of endoscopic visualization at least in FESS^{15,16}. Of course no conclusions may be drawn regarding this subject without a decent comparative study for EES.

In our experience muscle relaxation does not seem to have any influence on the bleeding and is never applied in EES as it interferes with facial nerve monitoring. The ventilation pattern instead, may affect the venous return: Positive end-expiratory

pressure (PEEP) creates a Valsalva effect and in consequence higher bleeding scores and is therefore avoided wherever possible. Another important consideration is not to exaggerate the intraoperative administration of fluids.

Conclusion

The management of bleeding in EES is feasible using widely available hemostatic agents in reasonable frequency. This study gives an instructive overview on how to manage the bleeding in EES. Risk factors for more important bleeding include the type of middle ear pathology and a high MAP. Even highest bleeding scores could be managed in an exclusively endoscopic technique, no shift to the microscopic approach was observed.

Acknowledgements

LA holds a research fellowship by the Bangerter-Rhyner Foundation, Bern, Switzerland and by Karl Storz GmbH, Tuttlingen, Germany. The funders had no role in study design, data collection and analysis, decision to publish or preparation of the manuscript. Therefore the authors declare no conflict of interest.

References

1. Yong M, Mijovic T, Lea J. Endoscopic ear surgery in Canada: a cross-sectional study. *J Otolaryngol Head Neck Surg.* 2016;19;45(1):4.
2. Marchioni D, Soloperto D, Rubini A, Villari D, Genovese E, Artioli F, Presutti L. Endoscopic exclusive transcanal approach to the tympanic cavity cholesteatoma in pediatric patients: our experience. *Int J Pediatr Otorhinolaryngol.* 2015;79(3):316-22.
3. Marchioni D, Alicandri-Ciufelli M, Rubini A, Masotto B, Pavesi G, Presutti L. Exclusive endoscopic transcanal transpromontorial approach: a new perspective for internal auditory canal vestibular schwannoma treatment. *J Neurosurg* 2016 Mar;11:1–8.
4. Bonali M, Anschuetz L, Fermi M, Villari D, Mariani GA, Manzoli L, Caversaccio M, Presutti L. The variants of the retro- and hypotympanum: an endoscopic anatomical study. *Eur Arch Otorhinolaryngol.* 2017 Feb 27. [Epub ahead of print]
5. Pothier D. Starting off with endoscopic ear surgery. In: Presutti L, Marchioni D (eds). *Endoscopic Ear Surgery.* Stuttgart, New York, Delhi, Rio, Thieme; 2015:2- 4.
6. Boezaart AP, van der Merwe J, Coetzee A. Comparison of sodium nitroprusside- and esmolol-induced controlled hypotension for functional endoscopic sinus surgery. *Can J Anaesth* 1995;42:373–376.
7. Tingjie Liu, Minju Qin, Wenxian Li, and Xia Shen. Effects of a Single Dose Dexmedetomidine on Surgical Field Visibility During Middle Ear Microsurgery: A Randomized Study. *Otol Neurotol.* 2016 Jul;37(6):680-4.
8. Gilroy AM, MacPherson BR, Ross LM, Schünke M, Schulte E, Schumacher U (eds). *Atlas of anatomy.* New York, Thieme; 2012.

9. Gunaratne DA, Barham HP, Christensen JM, Bhatia DD, Stamm AC, Harvey RJ. Topical concentrated epinephrine (1:1000) does not cause acute cardiovascular changes during endoscopic sinus surgery. *Int Forum Allergy Rhinol.* 2016 Feb;6(2):135-9.
10. Korkmaz H, Yao WC, Korkmaz M, Bleier BS. Safety and efficacy of concentrated topical epinephrine use in endoscopic endonasal surgery. *Int Forum Allergy Rhinol.* 2015 Dec;5(12):1118-23.
11. Pant H. Hemostasis in Endoscopic Sinus Surgery. *Otolaryngol Clin North Am.* 2016 Jun;49(3):655-76.
12. Liang S, Irwin MG. Review of anesthesia for middle ear surgery. *Anesthesiol Clin.* 2010 Sep;28(3):519-28.
13. Ramchandani S, Lakra AM, Shah PJ, Lalwani J, Sahare KK. Effect of intravenous clonidine premedication for the bloodless surgical field in patients undergoing middle ear or nasal surgery: A comparison of three different doses. *Anesth Essays Res* 2015;9:397-400
14. Ryu JH, Sohn IS, Do SH. Controlled hypotension for middle ear surgery: a comparison between remifentanil and magnesium sulphate. *Br J Anaesth.* 2009 Oct;103(4):490-5.
15. Chaaban MR, Baroody FM, Gottlieb O, Naclerio RM. Blood loss during endoscopic sinus surgery with propofol or sevoflurane: a randomized clinical trial. *JAMA Otolaryngol Head Neck Surg.* 2013 May;139(5):510-4.
16. Al-Bar MH, Ruiz JW, Casiano RR. Does total intravenous anesthesia provide significant blood loss reduction compared to inhalational anesthesia during endoscopic sinus surgery? *Laryngoscope.* 2016 Sep;126(9):1961-2.

Tables

Table 1: Distribution of patient's characteristics. SD: standard deviation, MAP: mean arterial pressure, HR: heart rate, BMI: body mass index, ASA: American society of anesthesiologists, IA: inhalational anesthesia

	Whole cohort N=104	Adult cohort N=88	Pediatric cohort N=16
Mean Age (range)	42 (3-83)	48 (16-83)	10 (3-15)
Female sex	60 (58%)	55 (63%)	5 (31)
Left side	56 (54%)	43 (49%)	13 (81)
Type of surgery			
Type 1 tympanoplasty	14	12	2
Tympanoplasty for cholesteatoma	55	41	14
Stapedotomy	26	26	0
Endoscopic lateral skull base surgery	6	6	0
Middle ear tumor removal	3	3	0
Revision surgery	24 (23%)	17 (19%)	7 (44%)
Bleeding scores and vital signs			
Mean EAC bleeding score (+/-SD)	2.17 (+/- 0.82)	2.13 (+/- 0.83)	2.44 (+/- 0.73)
Mean EAC MAP (+/-SD)	70.6 (+/- 12.9)	70.9 (+/- 13.3)	68.8 (+/- 10.5)
Mean EAC HR (+/-SD)	66.8 (+/- 15.3)	63.0 (+/- 9.6)	87.9 (+/- 22.7)
Mean middle ear bleeding score (+/-SD)	2.00 (+/- 1.16)	1.85 (+/- 1.12)	2.81 (+/- 1.05)
Mean middle ear MAP (+/-SD)	68.3 (+/- 12.2)	68.2 (+/- 12.6)	68.9 (+/- 9.6)
Mean middle ear HR (+/-SD)	64.2 (+/- 14.5)	60.3 (+/- 8.5)	86.0 (+/- 20.7)
Relevant comorbidities			
Hypertension	16	16	0
Diabetes mellitus	5	5	0
Heart/Vessel disease	7	6	1
Lung disease	3	3	0
Thyroid disease	7	7	0
Coagulation abnormalities	1	1	0
BMI > 30 kg/m ²	7	7	0
Acetylsalicylic acid	4	4	0
Anticoagulant	2	2	0
ASA class			
I	61	49	12
II	36	32	4
III	6	6	0
IV	1	1	0
Type of anesthesia			
IA (Sevoflurane/Remifentanyl)	82	67	15
IA (Desflurane/Remifentanyl)	19	18	1
Local anesthesia (only stapedoplasty)	3	3	0

Table 2: Statistical comparison of bleeding scores according to the type of intervention and the ASA class. Note the high bleeding scores during middle ear tumor removal (glomus tympanicus). EAC: external auditory canal, ME: middle ear, ASA: American Society of Anesthesiologists

	Mean bleeding scores (95% CI)		p-value	
	EAC	Middle ear		
Type of intervention			0.196	< 0.0001
Stapedotomy	1.83 (1.41 - 2.26)	0.94 (0.63 - 1.26)		
Type 1 tympanoplasty	2.50 (1.73 - 3.27)	2.00 (1.42 - 2.58)		
Tympanoplasty for cholesteatoma	2.19 (1.97 - 2.40)	2.35 (2.02 - 2.68)		
Middle ear tumor removal	1.67 (0.23 - 3.10)	4.33 (1.47 - 7.20)		
Lateral skull base surgery	2.17 (1.14 - 3.20)	1.50 (0.05 - 2.95)		
Revision surgery	2.33 (1.99 - 2.68)	2.00 (1.59 - 2.41)		
Comorbidities			0.288	0.651
ASA I	2.12 (1.92 - 2.31)	1.89 (1.59 - 2.19)		
ASA II	2.22 (1.92 - 2.53)	2.14 (1.74 - 2.54)		
ASA III/IV	2.43 (1.70 - 3.16)	2.29 (1.41 - 3.17)		

Figure Legends

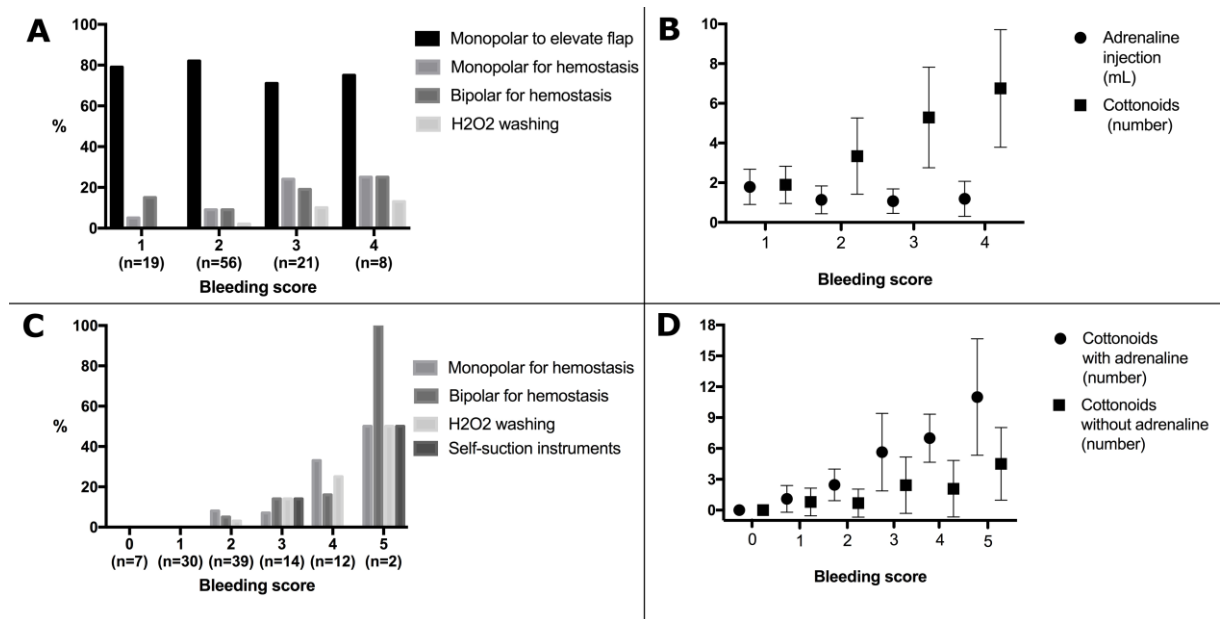


Figure 1: The used hemostatic agents are illustrated according to the bleeding scores. Panel A and B represent data for the external auditory canal, whereas Panel C and D represent data for the middle ear evaluation.

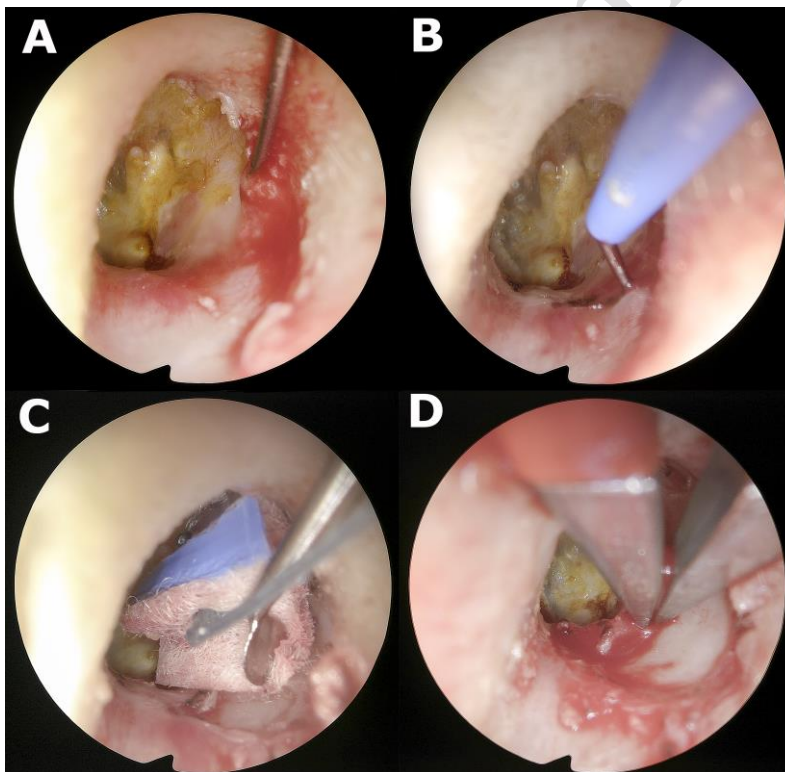


Figure 2: Hemostatic agents used in the external auditory canal. A: Injection of diluted epinephrine postero-superior; B: Monopolar cautery to outline the tympano-

meatal flap; C: cottonoid pledges soaked with epinephrine; D: bipolar cautery to control residual bleeding.

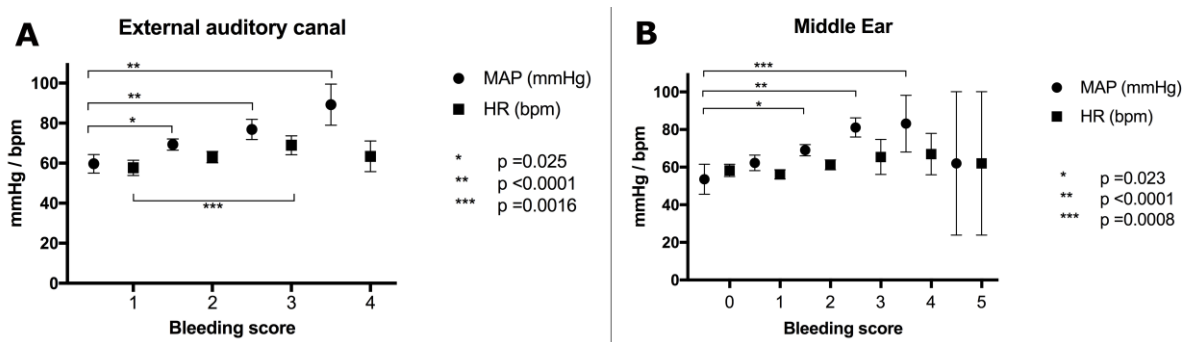


Figure 3: Mean arterial pressure (MAP) and heart rate (HR) are illustrated for the external auditory canal (A) and the middle ear (B). The statistical analysis reveals significant differences between group allocations for the MAP.

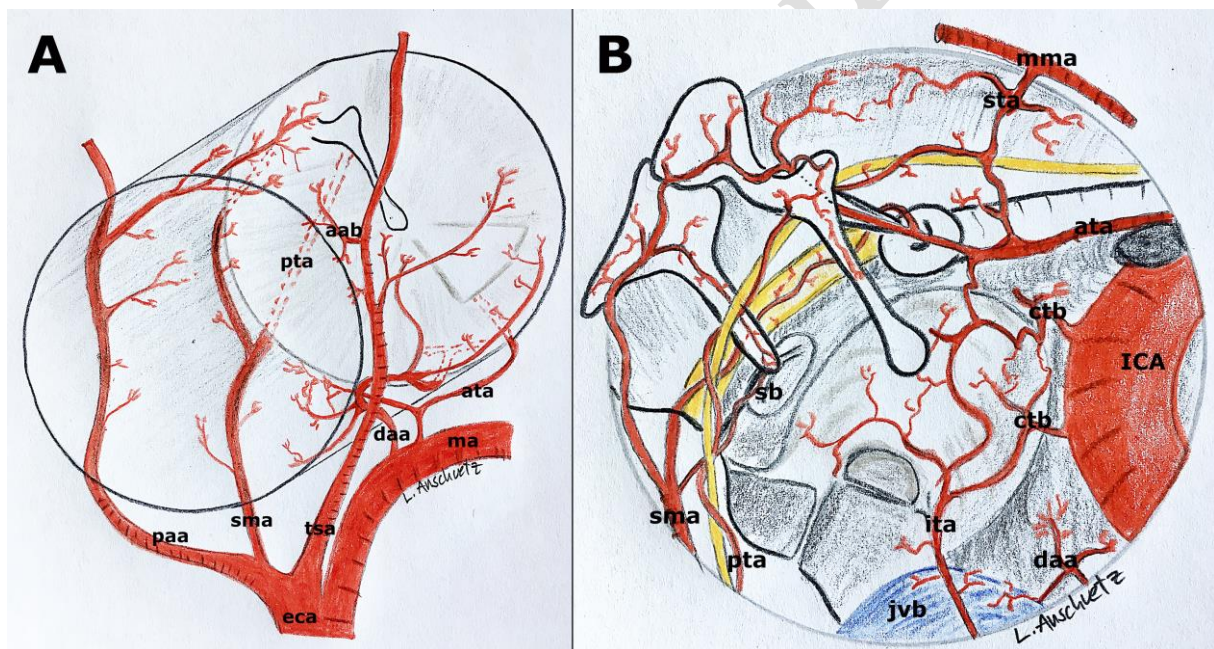


Figure 4: Schematic illustration of the vascular supply for the external auditory canal (A) and the middle ear cleft (B). paa: posterior auricular artery, sma: stylomastoid artery, tsa: temporal superficial artery with aab: anterior auricular branches, ma: maxillary artery, daa: deep auricular artery, eca: external carotid artery, ata: anterior tympanic artery, pta: posterior tympanic artery, ita: inferior tympanic artery, sta: superior tympanic artery, sb: stapedial branch (from sma), ica: internal carotid artery

with ctb: carotid tympanic branches, mma: middle meningeal artery, jvb: jugular vein
bulb

Accepted manuscript