Comments to the Reviewers

A. Reviewer #1:

1. This paper describes in a very well written and structured work an endoscopic anatomical study of the retro- and hypotympanum. With excellent pictures and a suggested new classification of the bridges, crests and ridges in this area.

   Thank you very much for your kind comments and considerations. We feel that the exact knowledge of the anatomy of the retro- and hypotympanum is useful for the surgical treatment of this region.

2. The authors may improve the benefit for readers by the following additions/changes:

   a. Addition of a schematic drawing illustrating the different anatomical structures described in the paper

      We wish to thank reviewer #1 for this excellent suggestion. We added a schematic drawing illustrating the anatomical structures by expanding figure 1.

      New figure 1

   b. Comparison of a microscopic image and an endoscopic view of the same region, since the authors suggest advantages in the endoscopic mode

      Thank you for this consideration. We agree with this suggestion, since we emphasize the advantage of the endoscopic access in our manuscript. Therefore we added a new figure, which compares the microscopic view to the endoscopic view of the retro- and hypotampanum.

      New figure 8

   c. A more in depth discussion of the clinical relevance of these findings and anatomical variants

      This is an excellent suggestion to improve the impact of our work. We addressed the clinical relevance of our findings in the discussion section of our manuscript. Especially, we emphasized the clinical implications in cholesteatoma and cochlear implant surgery.

      Page 10, lines 273-285
      Pages 11-12, lines 308-319
      Page 12, lines 322-328

3. Minor point: Figure 6 & 7 are not mentioned in the text

   Thank you for the precise lecture of our manuscript. We mentioned Figures 6 and 7 in Table 1. To address this issue we added the figures at the appropriate position in the text.

   Page 9, lines 257-258

B. Reviewer #2: This work presents a very nice and detailed overview of the endoscopic middle ear anatomy. Due to the high number of temporal bones examined, the results appear representative and will become very useful to every beginner in endoscopic ear surgery.

Thank you very much for your kind consideration and appreciation of our work. We believe, that the high number of examined temporal bones is an important strength of our study. We agree, that the anatomical knowledge of this region is essential to every beginner in endoscopic ear surgery.

Revised Manuscript

The Variants of the Retro- and Hypotympanum: An Endoscopic Anatomical Study

Abstract

The retro- and hypotympanum are hidden areas of the middle ear only poorly recognized. Nevertheless, this region is of relevant clinical significance, since it is regularly affected by disease such as cholesteatoma. The aim of this study is to explore and describe the anatomical variants of the hypo- and retrotympanum by the means of transcanal endoscopy. We hypothesize a significant variability of this hidden region of the middle ear. Moreover, we believe that the minimal invasive, endoscopic access is suitable since angled scopes may be used to explore the region. To this end a total of 125 middle ears (83 cadaveric dissections, 42 surgical cases) were explored by the means of 3 mm straight and angled scopes. The variants were documented photographically and tabularized. The bony crests ponticulus, subiculum and finiculus were most frequently represented as ridges. The ponticulus showed the highest variability with 38% ridge, 35% bridge and 27% incomplete presentation. The subiculum was bridge-shaped only in 8% of the cases, the finiculus in 17%. The sinus tympani had a normal configuration in 66%. A subcochlear canaliculus was detectable in 50%. The retro- and hypotympanum were classified respectively to the present bony crests and sinus in a novel classification type I to IV. In conclusion we found abundant variability of the bony structures in the retro- and hypotympanum. The endoscopic access is suitable and offers thorough understanding and panoramic views of these hidden areas.

Key words: Middle ear anatomy; sinus tympani; retrotympanum; hypotympanum; endoscopic ear surgery; ponticulus; subiculum; finiculus

Introduction

The retro- and hypotympanum are critical areas of the middle ear, regularly affected by disease especially cholesteatoma [1]. Due to their limited direct access and hidden position in between anatomical structures as the facial nerve (FN), the stapes, the oval and the round window, the jugular vein bulb (JVB), the internal carotid artery (ICA), the pyramidal eminence and the styloid process, they are some of the most challenging regions for surgical treatment. By this reasons this part of the middle ear holds a high risk of residual cholesteatoma after middle ear surgery [2]. The consequence of residual cholesteatomatous tissue may be local recurrence and consecutive erosion of critical middle ear structures [3].

The optimal surgical management of this area is still under debate. The microscopic technique is limited to access these regions even when performing a retrofacial access or an open canal wall down technique [7-9]. The recently introduced minimal invasive endoscopic access to the middle ear may increase the visibility of the retro- and hypotympanum as angled scopes can be used [10-13]. However, exact knowledge on the variability of the retro- and hypotympanic anatomy is still lacking. The aim of this study is to describe and classify the variants of hypo- and retrotympanic structures by the means of transcanal endoscopy. We hypothesize, that the retro- and hypotympanum are subject to more anatomical variability than actually thought. This may have direct impact on further middle ear surgery.

Material and Methods

We conducted from March 2015 to March 2016 cadaveric dissection on 83 human specimens, without any obvious temporal bone pathology. We used two 3 mm diameter, 15 cm length, endoscopes (Karl Storz, Tuttlingen, Germany) with angles of 0 and 45°, a three-CCD camera system and a high-resolution monitor (Karl Storz, Tuttlingen, Germany). The dissection was performed holding the camera in one hand (usually the left) and the instrument in the other. The exploration of the sinus required prior cleaning and removal of eventually present mucosal folds using angled instruments.

Moreover, we reviewed 42 endoscopic ear surgery interventions carried out from January 2015 to March 2016 stored in our database. We included exclusively cases presenting unchanged anatomy of the retro- and hypotympanum. The indications to surgery were tympanic membrane perforations, retraction pockets of the attic, minor attic cholesteatoma or otosclerosis. Ten cases of extended cholesteatoma with arrosion of the bony structures of the retro- and hypotympanum were excluded from this study.

The anatomy was documented photographically and underwent further review by the authors. The final classification was tabularized and summarized. Descriptive statistics were performed using GraphPad Prism®.

Anatomical nomenclature and classification

The retrotympanum is divided by the subiculum in the superior and inferior retrotympanum. The superior part contains the posterior sinus (PS) and sinus tympani (ST), which are divided by the ponticulus. The inferior retrotympanum is represented by the sinus subtympanicus (SST), which contains the round window niche. The finiculus separates the inferior retrotympanum to the hypotympanum (HT)

and marks the anterior boundary of the subcochlear canaliculus (SC) [1,4-6,13]. Figure 1 gives an exemplary endoscopic view and a schematic drawing of the investigated region.

A. Bony crests (Figure 1):

- Ponticulus: connection between the promontory and the pyramidal eminence, classified as bridge, ridge or incomplete
- Subiculum: bony structure arising from the posterior pillar of the round window niche towards the styloid eminence, classified as bridge, ridge or incomplete.
- Finiculus: conjunction of the anterior pillar of the round window niche and the jugular bulb, classified as bridge, ridge or incomplete.

B. Retro- and hypotympanic sinus (Figure 1):

- Posterior sinus: triangular area, which is limited laterally, posteriorly and superiorly by the facial nerve, inferiorly by the ponticulus and anteriorly by the stapes footplate and oval window.
- Sinus tympani: round shaped sinus between the ponticulus and the subiculum, medial to the pyramidal eminence and the facial nerve and lateral to the posterior semicircular canal. The shape of ST is classified according to Marchioni et al. [1] in type A: normal, type B confluent (incomplete ponticulus), type C: partitioned, type D: restricted.
- Sinus subtympanicus: area limited by the subiculum and the finiculus connected with the round window niche anteriorly. The styloid eminence represents the postero-lateral border. The area concamerata and the fustis bone form the floor of the SST.

- Hypotympanum: zone of bony cells limited posteriorly by the finiculus, anteriorly by the Eustachian tube and inferiorly by the jugular wall of the tympanic cavity.
- Subcochlear canaliculus: inconstantly pneumatized bony tunnel connecting the round window chamber with the petrous apex lying below the cochlea, classified by Marchioni et al. [13] as type A: deep tunnel, type B: small tunnel endoscopically not recognizable and type C fused without connection between the area concamerata and the petrous apex. The assessment of the depth of the tunnel is based on a endoscopic and radiologic evaluation. In the present study we limited the assessment of SC to the pure endoscopic perceptibility as type A (detectable) or type B (not detectable).

Results

We analyzed a total of 125 middle ears. The retro- and hypotympanic structures were well identifiable in all cases using the transcanal endoscopic approach without performing canaloplasty.

Description of Anatomical Variants

A. Bony crests (Figure 2):

- Ponticulus: high variability with almost equally represented variants. In most cases we observed a ridge (n=47, 38%) or bridge (n=44, 35%) shape. In 34 cases (27%) the ponticulus was incomplete with consecutive confluence of PS and ST.
- Subiculum: mainly represented in ridge shape (n=73, 58%). In one third of the cases (n=42, 34%) the subiculum was missing creating a unique large

retrotympanic sinus. Only in ten cases (8%) the subiculum was observed as bridge.

- Finiculus: the less variable bony crest with almost two-thirds ridge (n=79, 63%), 25 incomplete (20%) and 21 bridge (17%) representations.

B. Retro- and hypotympanic sinus:

- Sinus tympani: normal shaped (type A) in 82 cases (66%) followed by 33 (26%) of confluent shape (type B) forming a common sinus with PS. Rarely a type C shape with a bony crest inside the ST was observed (n=8, 6%) and only in 2 cases the access to the ST was restricted (type D, 2%) by a very high jugular bulb.
- Subcochlear canaliculus: the tunnel was well perceptible in half of the cases (n=62, 50%) and absent in 54 cases (43%). In 9 cases (7%) the tunnel could not be assessed, because of obliteration of SST (e.g. high jugular bulb). Figure 3 shows exemplarily the two described anatomical situations.

Classification: Chambers of the Retro- and Hypotympanum

The actual classifications of ST [1], SST and subcochlear canaliculus [13] appeared to be somehow insufficient regarding the variability of the entire retro- and hypotympanic space. The region appears to be anatomically coherent due to absent bony crests or bridge variants. To describe the retro- and hypotympanum as one entity we introduced a classification according to the presence of the different sinus forming up to 4 chambers, which were explored during dissection and surgery.

- Type I (Figure 4A): the retro- and hypotympanum is represented by 1 large chamber from the stapes footplate to the ICA. In this rare case all bony crests are missing and one smooth and open sinus is present (n=3, 2%).

- Type II (Figure 4B): the presence of only one bony crest creates two chambers of variable size and shape (n=17, 14%). Three subdivisions may be applied: a) present ponticulus creates the PS and one large anterior sinus; b) present subiculum divides the superior retrotympanum from a confluent SST and HT; c) present finiculus separates a confluent retrotympanum from the HT.
- Type III (Figure 4C): the most frequent observation was the presence of two bony crests, which form three different chambers (n=59, 47%). As for the type II, three subtypes may be applied: a) absent ponticulus with confluent PS and ST; b) missing subiculum with one large confluent ST and SST; c) absent finiculus leads to confluent SST and HT.
- Type IV (Figure 4D): The presence of all bony crests and sinus forms four chambers (n=46, 37%).

The distribution of the encountered situations in terms of present or absent bony crests classified by the described system is shown in Figure 5.

Rare variants and anatomical pearls

The exploration of the middle ear always bears some surprises from an anatomical and therefore also surgical point of view. We observed a couple of rare variants giving an idea on frequency of surgically important conditions (e.g. high JVB or dehiscent FN). These observations are summarized in Table 1 and illustrated in Figures 6 and 7.

Discussion

The endoscopic surgical anatomy of the retro- and hypotympanum has been progressively studied and described in the last years. These studies focus on one

particular region or structure: e.g. the ST [1,5,6], the inferior retrotympanum [4] with the round window region [13], the ponticulus [14] or the subpyramidal space [15]. Due to the presence of bony crests, which may be of bridge configuration, these areas are truly interconnected. In our opinion the retro- and hypotympanum has to be considered as a tightly coherent region of the middle ear. For this purpose we suggest a classification according to the presence of the different bony crests and sinus forming the different chambers of the retro- and hypotympanum. The introduced chambers classification may indeed serve as intraoperative assessment. If the otologic surgeon is aware of the different anatomical subregions and is able to classify the retro- and hypotympanum, he may have thoroughly explored the region. The clinical importance of the described abundant anatomical variability is the possible spread of cholesteatoma matrix underneath the bridges from one region to the other. This happens even without eroding the bone, which separates the different sinus. Moreover, a fragment of matrix may easily hide behind a bony crest or under a bridge and therefore escape to the surgeon's eyes. As previously assessed, ST remains the main site of residual disease after middle ear surgery for cholesteatoma [9,10]. If the retro- and hypotympanum is affected by disease, the endoscopic approach offers prompt recognition of the disease extension due to the wide-angle view of the whole region and the possibility to use angled scopes. Therefore, the use of an endoscope improves the outcome of cholesteatoma surgery by preventing residual disease [11,12]. Our results describe the anatomical variability of the investigated region; this knowledge may therefore help the surgeon to completely clean the region from disease.

Holt [14] observed in 2004 the presence of a ponticulus in 33 of 50 examined temporal bones. He described it as a bony bridge extending between the pyramidal eminence and the promontory. He denies the observation of a ridge formation, but

rather describes a “sheet of bone”. Actually these assumptions can be disproved due to the observation of 38% ridge ponticulus in our study. This incongruence may be explained by the exclusively microscopic technique used by Holt. Comparing the results of Marchioni et al. (2009) with 5.3% bridge ponticulus in their case series of 40 surgical patients [1], we observed a much higher rate of 35% bridge ponticulus in the present study. This may be due to technical advances in endoscopy, the awareness of the observers to the possible variants and the exploration in cadaveric dissection.

Regarding the subiculum Marchioni et al. [4] described in a cohort of 25 surgically treated subjects a distribution of 19 ridges, 2 bridges and a lack of subiculum in 4 patients. In the same study, describing the finiculus they observed 12 ridge, 2 bridge and a lack of finiculus in11 patients. We can consider these results as similar to our observations with a ridge shape being the most frequent presentation of these bony crests. On a larger scale, we found very rarely a bridge-shaped subiculum, while the finiculus was present in 17% of the cases as a bridge. The subcochlear canaliculus was in half of the cases detectable (50%) indicating a connection to the petrous apex. We observed difficulties assessing the actual depth of this tunnel by means of an exclusive endoscopic approach. The classification formerly proposed [13] relies on a radiologic examination, which is in our opinion mandatory to reliably determine the pneumatization of the petrous apex. Clinically, we have to consider that the presence of an extensive cholesteatoma in this region may extend in the petrous apex inferior to the cochlea. As mentioned above, the subcochlear canaliculus may not be visible in some situations. Therefore, the knowledge of the variability and the possible extension into the petrous apex along with a high degree of suspicion are essential during surgery. In cases of cholesteatomatous invasion of the petrous apex an infracochlear approach may be necessary in order to completely eradicate the

disease [16]. Moreover, during cochlear implant surgery a large subcochlear canaliculus may be mistaken for the round window niche, this applies especially in cases of a narrow facial recess. This situation bears the risk of unnecessary additional bone removal around the FN and therefore time loss, or in extremis the positioning of the electrode array into the petrous apex.

The hidden areas of the retro- and hypotympanum are difficult to access and therefore represent a region of risk for residual cholesteatomatous disease after surgical treatment. The extension of the disease into a deep sinus, extending below the facial nerve (ST Type C) demands thorough exploration. Therefore, exact anatomical knowledge and an efficient technique to visualize the middle ear are required. In our experience, the transcanal endoscopic approach is a very useful technical amendment, offering the necessary vision to the surgeon to clean these hidden areas from disease. The superiority of the endoscope to visualize the middle ear compared to the microsope is illustrated in Figure 8. Recently Benett et al. published a comparative work between endoscopic and microscopic technique for the visualization of the middle ear anatomy supporting our observation [17]. We emphasize that the use of angled scopes allows not only the visualization of hidden areas but also the dissection under view.

A recently published cross-sectional study among ENT surgeons in Canada reports growing experience in endoscopic ear surgery [18]. The main instrument among the colleagues remained the microscope but the collective acknowledged the advantage of the endoscopic access in the reduction of residual disease. The feasibility of the endoscopic approach was even described in children [19] and James et al. recently observed reduced residual disease in endoscopic management of cholesteatoma [20]. Our dissection and surgery experience is favorable to the endoscopic

exploration due to the excellent views of the anatomical structures without need of bone removal for access purposes.

Conclusion

The retro- and hypotympanum bear a high anatomical variability. The configuration as bridge variants and variably shaped sinus interconnects the different subregions. To address this, a straightforward classification in type I-IV is proposed, which may be used during intraoperative surgical assessment. The endoscopic access to the retro- and hypotympanum is suitable and offers thorough understanding and panoramic views of the deep and hidden retreats.

Compliance with Ethical Standards

All of the authors have read and approved the manuscript.

Conflict of interest: XX holds a research fellowship by the Bangerter-Rhyner Foundation, Bern, Switzerland and by Karl Storz GmbH, Tuttlingen, Germany. The funders had no role in study design, data collection and analysis, decision to publish or preparation of the manuscript. Therefore, the authors declare no conflict of interest.

Research involving human participants: All procedures performed in this study involving human participants were in accordance with the ethical standards of the institutional, regional and national research committee and with the 1964 Declaration of Helsinki and its later amendments or comparable ethical standards.

Informed consent: For this type of study, formal consent is not required.

References

1. Marchioni D, Mattioli F, Alicandri-Ciufelli M, Presutti L. Transcanal endoscopic approach to the sinus tympani: a clinical report. *Otol Neurotol* 2009;30:758–765.
2. Weiss MH, Parisier SC, Han JC, et al. Surgery for recurrent and residual cholesteatoma. *Laryngoscope* 1992;102:145Y51.
3. Jeng FC, Tsai MH, Brown CJ. Relationship of preoperative findings and ossicular discontinuity in chronic otitis media. *Otol Neurotol* 2003;24:29-32.
4. Marchioni D, Alicandri-Ciufelli M, Piccinini A, Genovese E, Presutti L. Inferior retrotympanum revisited: an endoscopic anatomic study. *Laryngoscope* 2010;120(9):1880–1886
5. Baki FA, El Dine MB, El Said L, et al. Sinus tympani endoscopic anatomy. *Otolaryngol Head Neck Surg* 2002;127:158-62.
6. Proctor B. Surgical anatomy of the posterior tympanum. *Ann Otol Rhinol Laryngol* 1969;78:1026–1040.
7. Pickett BP, Cail WS, Lambert PR. Sinus tympani: anatomic considerations, computed tomography, and a discussion of the retrofacial approach for removal of disease. *Am J Otol* 1995;16:541-50.
8. Pulec JL. Sinus tympani: retrofacial approach for the removal of cholesteatomas. *Ear Nose Throat J* 1996;75:77-88.
9. Pratt LL. Complications associated with the surgical treatment of cholesteatoma. *Laryngoscope* 1984;93:289-91.
10. Presutti L, Marchioni D, Mattioli F, Villari D, Alicandri Ciufelli M. Endoscopic management of acquired cholesteatoma: our experience. *J Otolaryngol* 2008;4:1-7.

11. Thomassin JM, Korchia D, Doris JM. Endoscopic guided otosurgery in the prevention of residual cholesteatomas. *Laryngoscope* 1993;103:939-43.
12. Badr-El-Dine M. Value of ear endoscopy in cholesteatoma surgery. *Otol Neurotol* 2002;23:631-5.
13. Marchioni D, Alicandri-Ciufelli M, Pothier DD, Rubini A, Presutti L. The round window region and contiguous areas: endoscopic anatomy and surgical implications. *Eur Arch Otorhinolaryngol*. 2015;272(5):1103-12.
14. Holt JJ. The ponticulus: an anatomic study. *Otol Neurotol* 2005; 26:1122Y4.
15. Marchioni D, Alicandri-Ciufelli M, Grammatica A, Mattioli F, Presutti L. Pyramidal eminence and subpyramidal space: an endoscopic anatomical study. *Laryngoscope*. 2010 Mar;120(3):557-64.
16. Marchioni D, Alicandri-Ciufelli M, Rubini A, Presutti L. Endoscopic transcanal corridors to the lateral skull base: Initial experiences. *Laryngoscope*. 2015;125 Suppl 5:S1-13.
17. Bennett ML, Zhang D, Labadie RF, Noble JH. Comparison of Middle Ear Visualization With Endoscopy and Microscopy. *Otol Neurotol*. 2016;37(4):362-6.
18. Yong M, Mijovic T, Lea J. Endoscopic ear surgery in Canada: a cross-sectional study. *J Otolaryngol Head Neck Surg*. 2016;19;45(1):4.
19. Marchioni D, Soloperto D, Rubini A, Villari D, Genovese E, Artioli F, Presutti L. Endoscopic exclusive transcanal approach to the tympanic cavity cholesteatoma in pediatric patients: our experience. *Int J Pediatr Otorhinolaryngol.* 2015;79(3):316-22.
20. James AL, Cushing S, Papsin BC. Residual Cholesteatoma After Endoscope-guided Surgery in Children. *Otol Neurotol.* 2016;37(2):196-201.

Figure and Table Legends

Table 1:

Tabular representation of rare anatomical variants found throughout the performed dissection on 125 middle ears.

FN: facial nerve, HT: hypotympanum, JVB: jugular vein bulb, SC: subcochlear canaliculus, SST: sinus subtympanicus, ST: sinus tympani

Table 1: Rare anatomical variants

Description	Clinical signification	n
Superior Retrotympanum		
Dehiscent facial nerve	Possible FN injury during surgery	3
Double bridge ponticulus (Figure 5)	Possible residual cholesteatoma	2
Bridge over oval window	Limited access to the footplate	1
Bony overhang partially covering ST	Possible residual cholesteatoma	2
Fusion of subiculum and finiculus	Anatomical variant	1
Inferior Retrotympanum		
Two additional bridges over SST	Partially restricted access to the round window	1
Abondant pneumatization of SST (Figure 6)	Restricted access to the round window	2
Ossification of round window niche	Hindered cochlear implantation	1
Bony crest with division of SST	Anatomical variant	1
Open window niche with a medial and anterior SC	Anatomical variant	1
Hypotympanum		
Partial fusion of a bridge finiculus with HT	Possible extension of cholesteatoma	4
High/proeminent jugular bulb	Possible JVB laceration during surgery	4

Figure 1:

Right ear. Endoscopic view (panel A) and schematic drawing (panel B) showing the bony crests and sinuses of the retro- and hypotympanum. Note the bridge ponticulus in the drawing.

fn: facial nerve, in: incus, pr: promontory, pe: pyramidal eminence, ps: posterior sinus, p: ponticulus, st: sinus tympani, su: subiculum, sst: sinus subtympanicus, f: finiculus, t: subcochlear tunnel, hy: hypotympanum, ow: oval window, rw: round window region

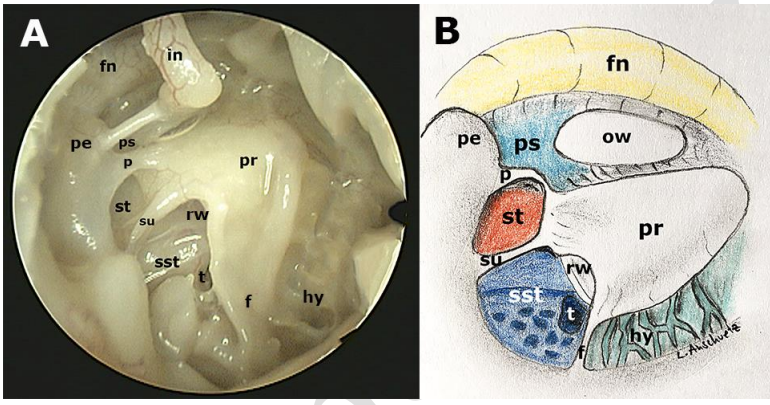

Figure 2:

Statistical distribution of the variability among the bony crests of the retro- and hypotympanum.

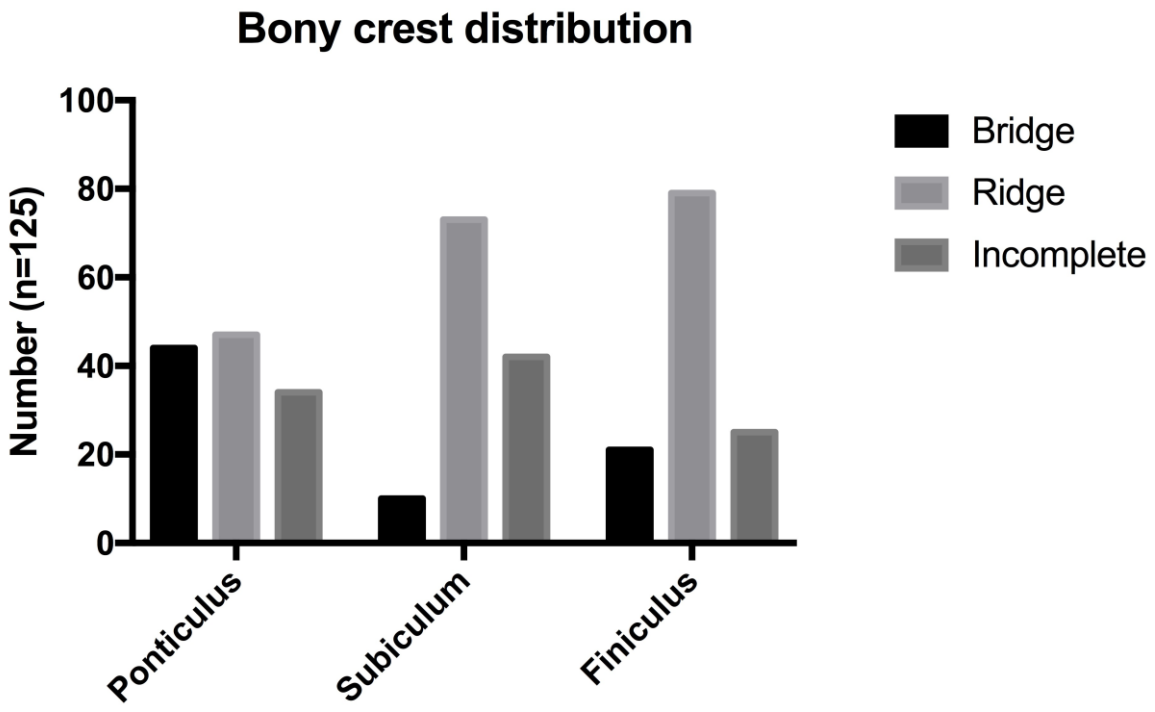

Figure 3:

Classification of the subcochlear canaliculus (SC) based on endoscopic perceptibility. Panel A: Right ear. Type A SC, well perceptible. Black arrow indicates the SC. Panel B: Left ear. Type B SC, absent. Black arrow indicates the SC. Finiculus is only hinted and has an unusual direction.

pr: promontory, teg: round window tegmen, fu: fustis, su: subiculum, f: finiculus, ht: hypotympanum

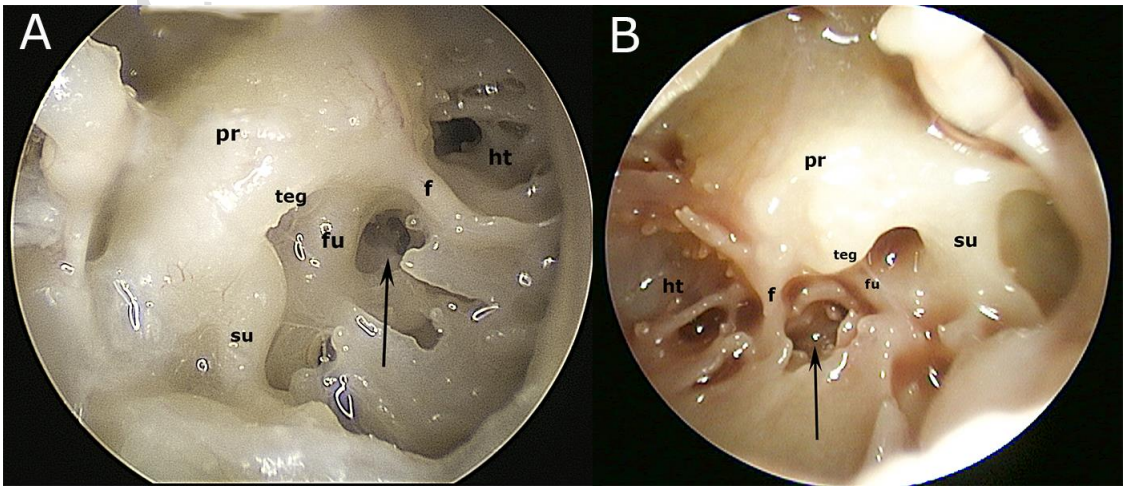

Figure 4:

Endoscopic classification of the retro- and hypotympanum according to the configuration of the different sinuses and bony crests. Panel A: Right ear. Type I: absence of bony crests; only one large chamber from the stapes to ICA. Panel B: Right ear. Type II: one bony crest; two chambers. Panel C: Left ear. Type III: two bony crests; three chambers. An additional bone bridge is present between the promontory and the styloid eminence. Panel D: Left ear. Type IV: three bony crests; four chambers.

ps: posterior sinus, st: sinus tympani, sst: sinus subtympanicus, ht: hypotympanum, ab: additional bone bridge, *: absence of the stapedial tendon. Black lines indicate bony landmarks of the chambers.

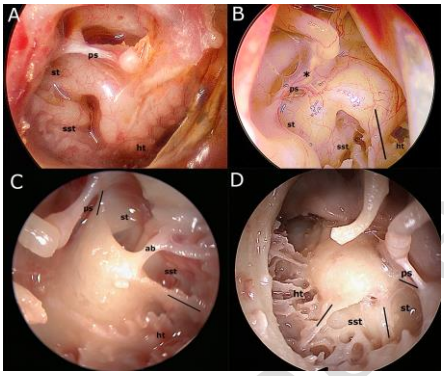

Figure 5:

Frequency of the different types of retro- and hypotympanum observed, according to the introduced classification.

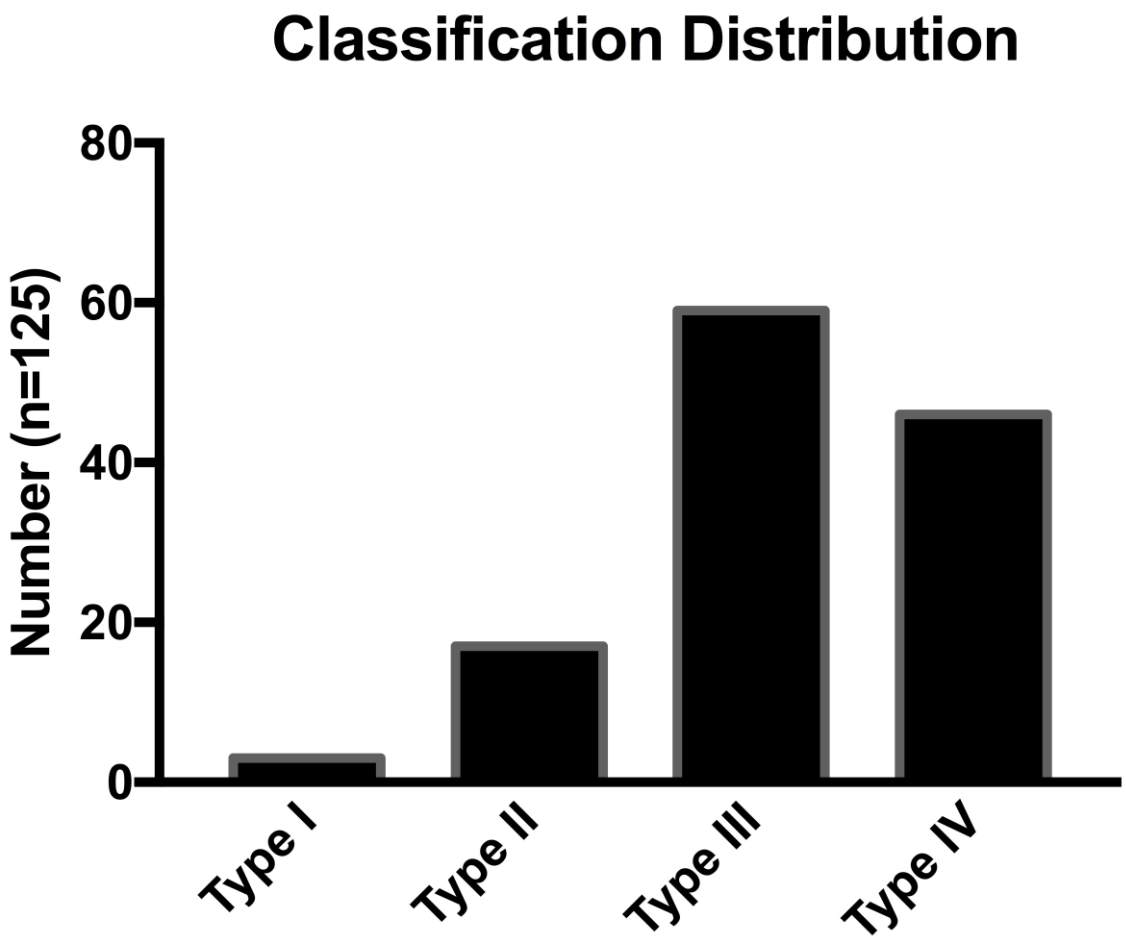

Figure 6:

Left ear. Endoscopic view. Presence of an anatomical pearl: double bridge ponticulus.

pr: promontory, st: stapes, fn: facial nerve, lsc: lateral semicircular canal. Black arrow indicates the ponticulus variant.

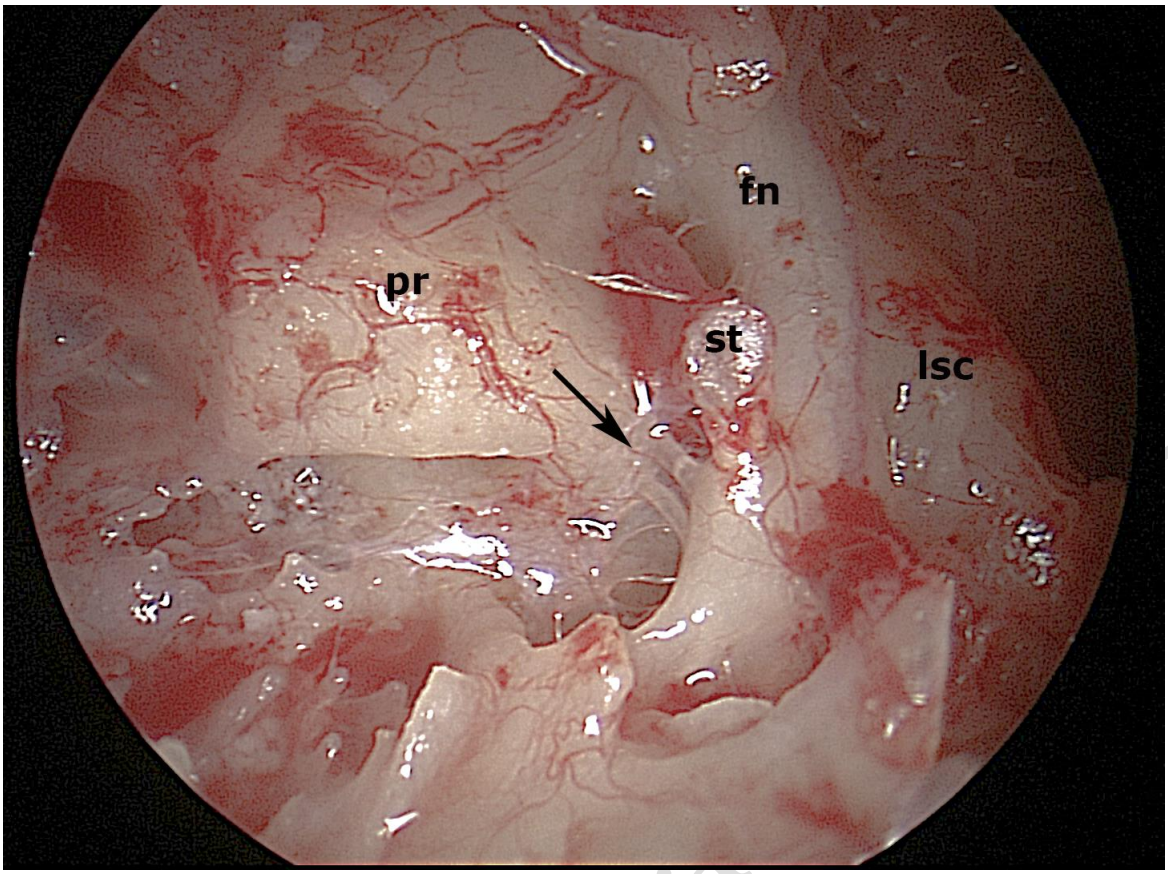

Figure 7:

Left ear. Endoscopic view. Note the abundant pneumatization of the sinus subtympanicus (SST).

ct: chorda tympani, in: incus, pr: promontory, tm: tympanic membrane, sst: sinus subtympanicus, fi: finiculus. Black arrow indicates the SST pneumatization.

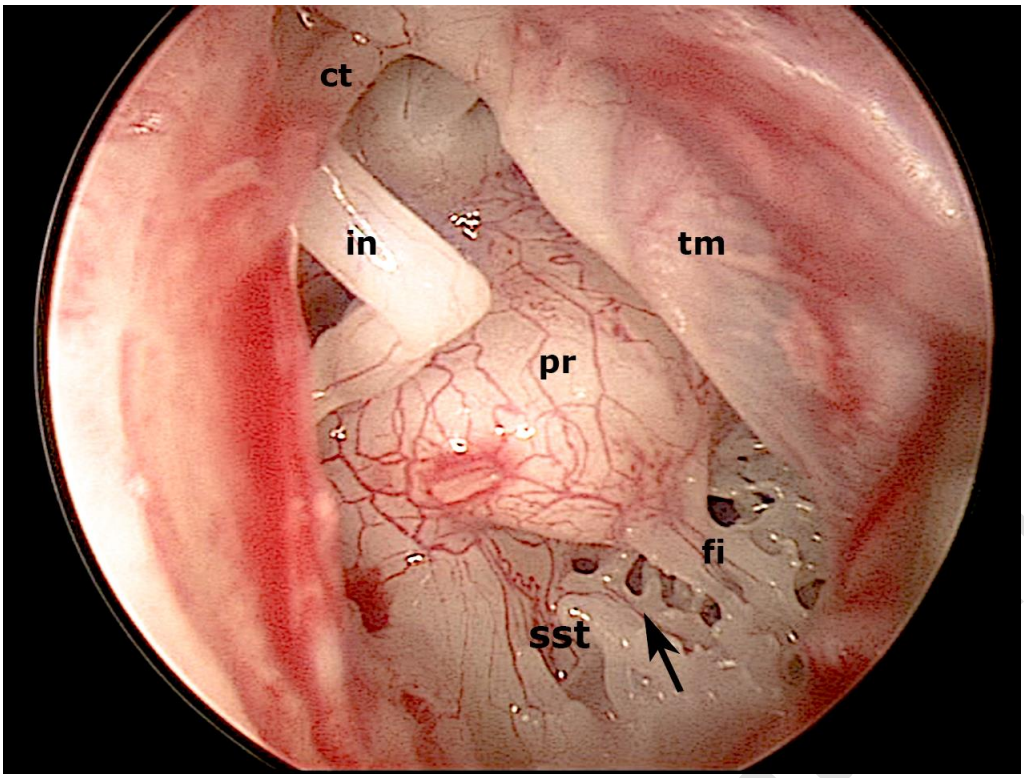

Figure 8:

Right ear. Comparision between microscopic transcanal view (panel A) and transcanal endoscopic view (panel B). The microscopic view does not allow the visualization of the retro and hypotympanum (indicated by black arrow). in: incus, s: stapes, t: stapedial tendon, pr: promontory, sst: sinus subtympanicus, fn: facial nerve, pe: pyramidal eminence, p: ponticulus, st: sinus tympani