J Cancer Res Clin Oncol (2017) 143:2039–2048
DOI 10.1007/s00432-017-2501-8

REVIEW – CLINICAL ONCOLOGY

Sentinel lymph node mapping in endometrial cancer: comparison of fluorescence dye with traditional radiocolloid and blue

Andrea Papadia[1] · Maria Luisa Gasparri[1,2,3] · Alessandro Buda[4] · Michael D. Mueller[1]

Received: 26 July 2017 / Accepted: 10 August 2017 / Published online: 21 August 2017

Abstract Sentinel lymph node (SLN) mapping in endometrial cancer (EMCA) is rapidly gaining acceptance in the clinical community. As compared to a full lymphadenectomy in every patient, to a selective lymphadenectomy after frozen section of uterus in selected patients with intrauterine risk factors or to a strategy in which a lymphadenectomy is always omitted, SLN mapping seems to be a reasonable and oncologically safe middle ground. Various protocols can be used when applying an SLN mapping. In this manuscript we review the characteristics, toxicity and clinical impact of technetium-99m radiocolloid (Tc-99m), of the blue dyes (methylene blue, isosulfan blue and patent blue) and of indocyanine green (ICG). ICG has an excellent toxicity profile, has higher overall and bilateral detection rates as compared to blue dyes and higher bilateral detection rates as compared to a combination of Tc-99m and blue dye. The detrimental effect of BMI on the detection rates is attenuated when ICG is used as a tracer. The ease of use of the ICG SLN mapping is perceived by the patients as a better quality of care delivered. Whenever possible, ICG should be favored over the other tracers for SLN mapping in EMCA patients.

✉ Andrea Papadia
andrea.papadia@insel.ch

[1] Department of Obstetrics and Gynecology, University Hospital of Bern and University of Bern, Effingerstrasse 102, 3010 Bern, Switzerland

[2] Department of Gynecology Obstetrics and Urology, Sapienza University of Rome, Rome, Italy

[3] Surgical and Medical Department of Translational Medicine, "Sapienza" University of Rome, Rome, Italy

[4] Unit of Gynecologic Oncology Surgery, Department of Obstetrics and Gynecology, San Gerardo Hospital, University of Milano-Bicocca, Monza, Italy

Keywords Sentinel lymph node mapping · Endometrial cancer · Cervical cancer · Blue dyes · Indocyanine green · Technetium-99m

Introduction

Sentinel lymph node (SLN) mapping was first described in penile cancer by Cabanas (Cabanas 1977). Since then it has become standard of care in the surgical management of melanomas, breast and vulvar cancer where it has replaced a systematic lymphadenectomy for staging purposes (Morton et al. 2006; Veronesi et al. 2003; Van der Zee et al. 2008; Johann et al. 2008).

In the past decade, a significant amount of research has been performed in the attempt to apply the SLN mapping as opposed to a full lymphadenectomy in patients affected by uterine malignancies. Through the identification of the first lymph node draining the tumor, the SLN mapping has been proven to reduce surgical morbidity and improve detection of metastatic disease at the same time. This is of particular interest in endometrial cancer (EMCA) patients, who are at relatively low risk of having extrauterine spread of the disease, are typically obese and affected by multiple comorbidities (Papadia et al. 2006). The adoption of minimally invasive surgical techniques has led to a reduction in surgical morbidity in these patients; however, complications such as lymphocysts, lower extremity lymphedema still occur as a result of the pelvic and paraaortic lymphadenectomy (Papadia et al. 2004; Walker et al. 2009). Furthermore, two randomized controlled trials have demonstrated that the systematic lymphadenectomy does not have a therapeutic effect in EMCA patients (Benedetti Panici et al. 2008; ASTEC study group 2009). Despite these results, pathological lymph nodal status is of utmost importance in EMCA patients.

Even though the presence of intrauterine risk factors are at times per se considered sufficient to indicate an adjuvant treatment, patients for whom the lymph nodal status is pathologically known and negative are less frequently subjected to adjuvant therapy as compared to EMCA patients with unknown lymph nodal status (Simpkins et al. 2013; Bogani et al. 2014; Sharma et al. 2011).

As opposed to a model in which EMCA patients are triaged to a systematic lymphadenectomy based on uterine pathologic risk factors identified at frozen section analysis, SLN biopsy seems to be a more reliable and less morbid solution (Sala et al. 2014; Papadia et al. 2009; Morotti et al. 2012; Laufer et al. 2013; Sinno et al. 2016; Papadia et al. 2017b). Currently, SLN mapping is not considered standard of care worldwide. According to the National Comprehensive Cancer Network guidelines, it is considered an acceptable alternative to a systematic lymphadenectomy in selected cases since 2014, whereas according to the ESMO–ESGO–ESTRO consensus conference, it should only be offered in the setting of clinical trials (NCCN guidelines 2017; Colombo et al. 2016). Recently, a large multicenter prospective validation trial, the FIRES trial, proved the SLN mapping to be a safe procedure with a false-negative rate that is comparable to the one recorded in breast and vulvar cancer (Rossi et al. 2017). We believe that the results of this trial represent a solid piece of clinical evidence that will help tilt the European guidelines towards the acceptance of this procedure in clinical practice (Papadia et al. 2017a).

When performing an SLN mapping, a variety of tracers with different characteristics can be used. The aim of this review is to compare the tracers adopted for SLN mapping in patients with EMCA.

Tracers

The most commonly used traces for SLN mapping in EMCA patients include technetium-99 radiocolloid (Tc-99m), blue dyes and indocyanine green (ICG), alone or in combination.

Tc-99m

Tc-99m is a metastable isomer that was first isolated in 1938 by Segrè and Seaborg and has become the most commonly used medical radioisotope in various diagnostic procedures since its clinical application in the 1960s (Segrè and Seaborg 1938; Richards et al. 1982). Tc-99m is obtained from a generator and decays by isomeric transition emitting almost only -rays of 140 keV. It has a half-life of approximately 6 h and the complete transition to Tc-99 occurs in 24 h. This short half-life allows for diagnostic procedures by keeping the total patient and staff exposure low.

After an interstitial injection, Tc-99m is taken up and travels in the lymphatic vessels to the SLNs where it tends to remain without moving to the echelon nodes and where it decays emitting -rays until the transition to Tc-99 is completed. The signal is identified by a gamma probe that is introduced through one of the laparoscopic trocars (Fig. 1). Therefore, in a typical laparoscopy in which three ancillary trocars are used, the 12-mm trocar will be occupied by the gamma probe leaving only two 5-mm ancillary trocars for the other laparoscopic instruments. Since Tc-99m does not stain the SLNs with a color and the detection of these relies only on the audiometric signal of the gamma probe that identifies the emitted -rays, a lymphoscintigraphy is performed after interstitial injection to detect the number of SLNs and to locate them (Fig. 2). Alternatively, it has been proposed to perform a SPECT–CT scan. The SPECT–CT fuses the radioactive information obtained via lymphoscintigraphy with the anatomic information obtained with a CT scan. As a result, the radioactive SLNs can be located anatomically

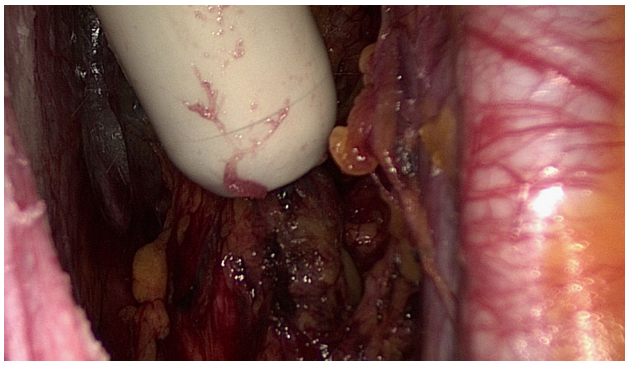

Fig. 1 With the laparoscopic gamma probe the "hot" SLN is localized through an audiometric signal. The probe is inserted in the abdomen through a 12-mm trocar

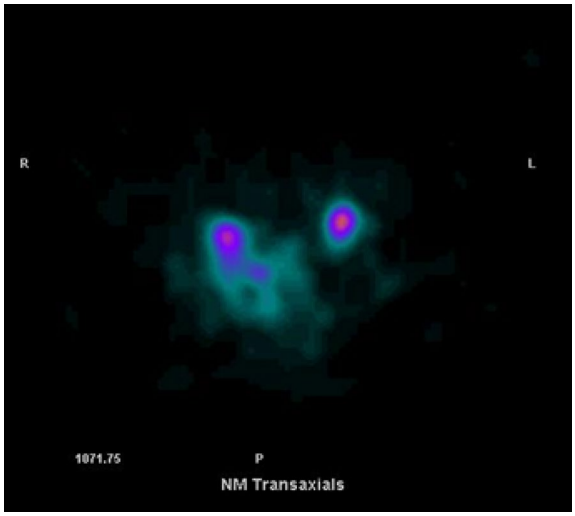

Fig. 2 Lymphoscintigraphy showing bilateral tracer migration after intracervical injection of Tc-99m

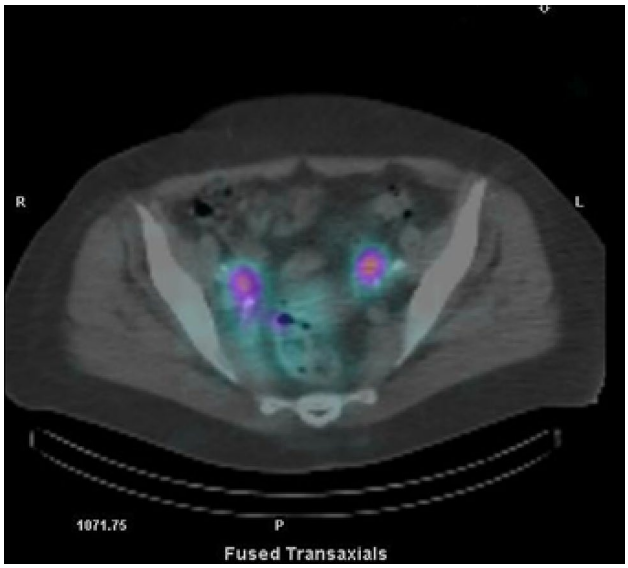

Fig. 3 SPECT–CT showing bilateral tracer migration and anatomic location of the SLNs after intracervical injection of Tc-99m

with a greater precision (Fig. 3). It has been suggested that performing a SPECT–CT after the injection of Tc-99m improves overall and bilateral detection rates of the SLN mapping and helps to identify SLNs located in unusual anatomic sites (Elisei et al. 2017).

Typically, Tc-99m is injected without anesthesia the day prior to surgery in a radio-protected ambulatory setting. One to 3 h after injection a lymphoscintigraphy or a SPECT–CT is performed. Alternatively, the radiotracer is injected 6 h prior to surgery and the preoperative imaging is performed 30 min later. It has also been proposed to inject the tracer intraoperatively after general anesthesia has been induced. In this case preoperative imaging is omitted and the identification of the SLNs relies only on the audiometric signal obtained intraoperatively by the gamma probe.

The injected dose of radioisotope is calculated based on the estimated time that will intercur to the surgery, the longer the interval the higher the dose in order to guarantee that the signal will still be detected. This leaves relatively little room for flexibility in the surgical schedule and if the planned surgery has to be delayed a few hours or to the next day for logistic issues, the decay of TC-99m may compromise the effectiveness of the SLN mapping.

Blue dyes

Blue dyes include methylene blue, isosulfan blue (ISB) and patent blue. Methylene blue was first prepared in 1876 and has been described as the first fully synthetic drug used in medicine (Friedlaender 1888). ISB is a greenish blue color hygroscopic powder that is suspended in sterile water to obtain a 1% solution. Patent blue is a dark bluish synthetic dye used as a food coloring. It is characterized by a very deep color even at a low concentration and fades quickly when exposed to light.

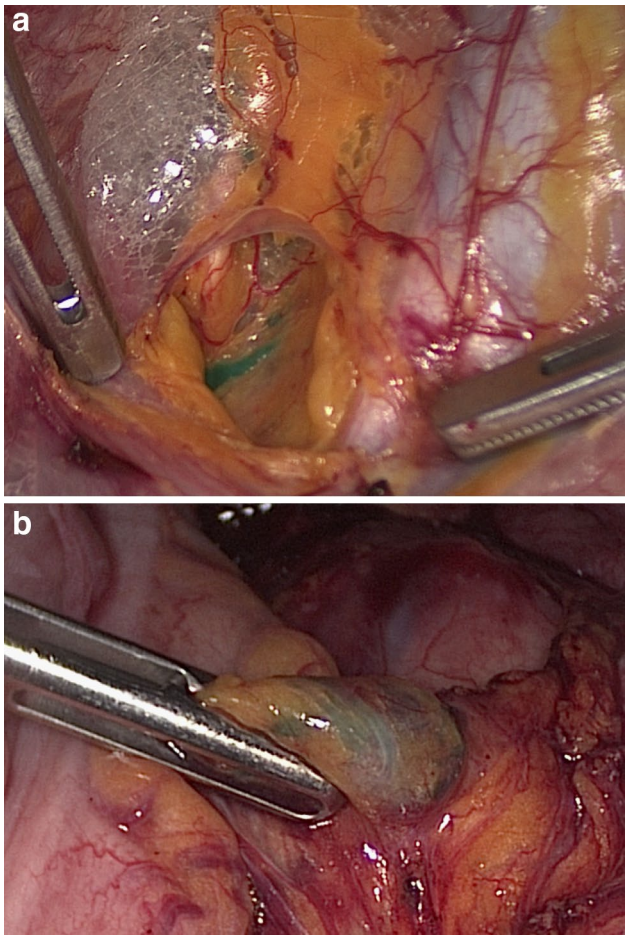

Fig. 4 **a** SLN mapping with *blue dye*. After injection in the cervix the tracer is taken up in the lymphatic vessels. The *bluish* stained lymphatic vessel can easily be visually identified. **b** Through the lymphatic vessels the *blue dye* reaches the SLN within 10 min from injection

Following interstitial administration, these dyes bind to serum proteins, are picked up by the lymphatic vessels and travel to the SLNs which become stained with a blue color in about 5–10 min (Fig. 4a, b). This method is very simple as it relies on a visual identification of the SLNs and does not require any dedicated equipment. After having stained the SLNs, the dyes quickly travel further along the lymphatic system and stain second-echelon non-SLNs. It becomes crucial to identify the SLNs at the beginning of the procedure before the dye fades away or travels to non-SLNs. The accuracy of these three different blue dyes for SLN mapping in breast cancer has been shown to be equivalent (Varghese et al. 2008; Blessing et al. 2002; Golshan et al. 2006).

Indocyanine green (ICG)

ICG was developed by Kodak as a dye to be used in photography in the 1950s. After its FDA approval for intravenous administration in 1956, it has been used in medicine and has been widely adopted in ophthalmology for retinal fluorangiographies. ICG are small particles that show diffuse fluorescence after excitation by near-infrared light (NIR) (700–900 nm) with the aid of dedicated optical systems. Optical systems have been developed by various companies and can be used in laparotomies and in minimally invasive surgeries (both laparoscopic and robotic). ICG binds to plasma proteins and is excreted by the liver. ICG powder is suspended in sterile water to a greenish solution. After elicitation with a NIR light, a strong blue fluorescent signal is emitted (Fig. 5a, b). After interstitial injection, ICG is picked up by the lymphatic system and travels rapidly to the SLNs. Unlike Tc-99m it does not remain confined to the SLNs, but travels further to second-echelon non-SLNs without fading away. It is crucial to start the search of the SLNs rapidly after its administration in order to reduce the risk of sample too many lymph nodes. Similarly as when utilizing a blue dye, the identification of the SLNs is visual via identification of a colored lymph node. Through the elicitation of the fluorescent signal of the ICG tracer, the signal becomes very strong, almost "bully". Its use has also been described via hysteroscopic peritumoral injection (Ditto et al. 2015; Martinelli et al. 2017).

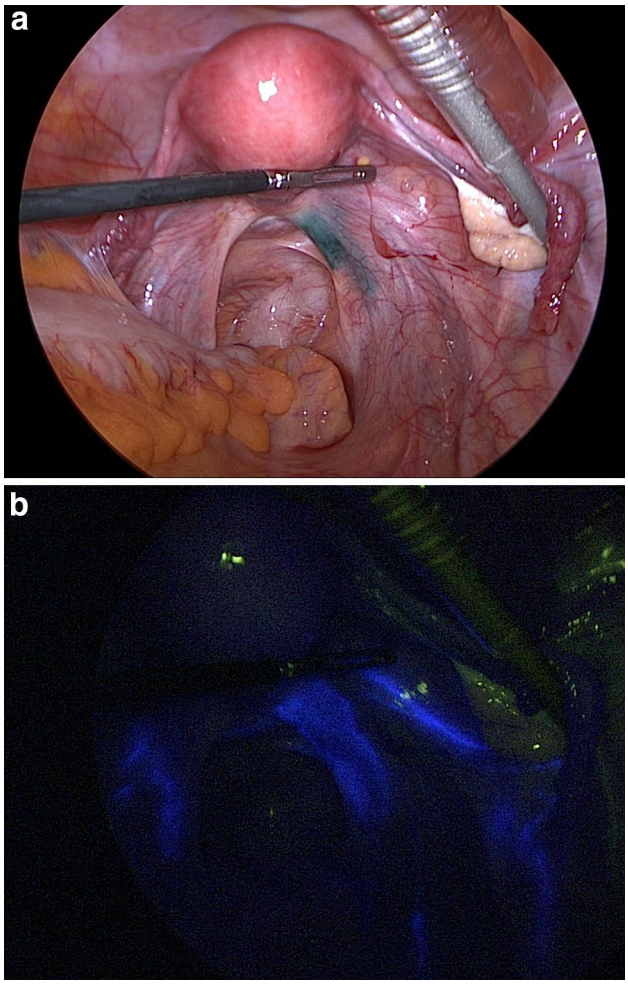

Fig. 5 **a** Laparoscopic view of the pelvis after intracervical injection of ICG and prior to activation of the NIR illumination. **b** Laparoscopic view of the pelvis after intracervical injection and activation of the NIR illumination. The fluorescent signal is strong and can be appreciated through the peritoneum. Both the periurethral and the periuterine lymphatic drainage system can be seen

Learning curves

In EMCA patients undergoing SLN mapping with blue dyes and Tc-99m, high SLN detection rates and low false-negative rates can be achieved after a surgical volume of 30 cases (Khoury-Collado et al. 2009). In our series, having performed more than 20 procedures decreased the number of retrieved SLNs without negatively affecting the false-negative rate, suggesting that after 20 procedures the SLN mapping becomes more precise (Papadia et al., 2016a). From other settings, such as gastric cancer, it seems that the NIR-ICG SLN mapping may be characterized by a somewhat shorter learning curve (Takahashi et al. 2017). It can be speculated that the learning curves for the SLN mapping in EMCA are likely the same regardless of the tracer used. When comparing operating (OR) time and SLN biopsy OR time, these were equivalent in patients undergoing SLN mapping with blue dye or ICG (Eriksson et al. 2017).

Given the paucity of the data in the EMCA literature, in a recent Society of Gynecologic Oncology (SGO) literature review and consensus recommendations, it was suggested to adopt the American Society of Clinical Oncology (ASCO) guidelines for application of the SLN mapping in breast cancer in EMCA as well (Holloway et al. 2017a; Lyman et al. 2005). A full lymphadenectomy should be performed after SLN mapping in the first 20 cases to control for detection rates and false-negative rates. This number should be higher in low-risk patients with a low risk of lymph node metastasis.

Toxicity profile and allergic reactions

The three types of tracers have different toxicity profiles and risks of adverse reactions (Table 1). Although radiation doses vary depending on the dose of Tc-99m injected, overall radiation exposure to the patient is small. Adverse allergic reactions to radiopharmaceuticals are rare with an estimated incidence of 1/100,000 and 6/100,000 (Cordova et al. 1984).

Table 1 Toxicity profile and adverse reactions of the tracers used for SLN mapping

Tracer	Severe allergic reaction	Other toxicity
Tc-99m	1–6/100,000	Radioactive drug
Blue dyes	2%	Discoloration of skin Discoloration of urine Skin necrosis Transient interference with pulse oximetry readings
ICG	0.05%	–

Severe allergic and anaphylactoid reactions to blue dyes are relatively common with a reported incidence of 0.7–1.9% (Albo et al. 2001; Cimmino et al. 2001; Hirsch et al. 1982; Leong et al. 2007; Montgomery et al. 2002). Based on their severity they have been classified in three grades:

- Grade 1: urticaria or blue hives, pruritus, and/or a generalized rash;
- Grade 2: transient hypotension (systolic blood pressure ≥70 mmHg) not requiring vasopressors;
- Grade 3: hypotension (systolic blood pressure <70 mmHg) requiring vasopressor support. Grade 3 reactions are life threatening and typically require an ICU admission.

Additionally, blue dyes commonly cause discoloration of the urine and may transiently interfere with pulse oximetry readings (Kieckbusch et al. 2008; Vieira et al. 2008). Methylene blue can cause a problematic skin necrosis, whereas interference with pulse oximetry reading occurs more often with ISB and patent blue (Masannat et al. 2006; Pinero et al. 2004).

ICG is a very safe tracer and severe allergic reactions to ICG are very uncommon with a reported incidence of 0.05% after intravenous injection (Hope-Ross et al. 1994). ICG contains sodium iodide and, according to the manufacturer, it should be used with caution in patients who have a history of allergy to iodides because of the risk of anaphylaxis. Since iodine is a chemical element that is an essential component of the human body, some authors suggest that ICG can be safely employed in patients with iodine allergy since a type-I allergic reaction (antibody mediated, responsible for anaphylactic shock) can virtually not occur (Krohne et al. 2016). The use of ICG has also be reported in pregnant patients (Papadia et al. 2016c).

Detection rates

Various comparisons have been made among the different tracers with regard to the detection rate. It has been demonstrated that the application of an SLN mapping algorithm in EMCA cancer decreases the false-negative rate from 14.9 to 1.9% (Barlin et al. 2012). This implies the removal of every SLN, of suspicious non-SLNs and the performance of a side-specific lymphadenectomy in case of unilateral mapping. The overall and bilateral detection rates are therefore crucial characteristics of the SLN mapping to safely reduce the extent of the surgery.

In the laparoscopic setting, we were the first group to compare the overall and bilateral detection rates of the SLN mapping with a combination of Tc-99m and patent blue versus NIR-ICG after cervical injection (Imboden et al. 2015). Although this cohort of patients was affected by cervical cancer, the technique of the SLN mapping is the same as for EMCA patients. In our series, the overall detection rate of the two techniques were comparable (93% for the combination of Tc-99m and patent blue vs. 95.5% for ICG, p = ns), whereas the bilateral detection rate was higher for the NIR-ICG SLN mapping (61% for the combination of Tc-99m and patent blue vs. 95.5% for ICG, $p = 0.0201$). These results were confirmed in larger multicentric studies (Buda et al. 2016c; Di Martino et al. 2017). Subsequently, in a series of cervical and EMCA patients operated on via conventional laparoscopy or via laparotomy, Buda et al. demonstrated that NIR-ICG SLN mapping achieved a higher bilateral detection rate as compared to SLN mapping with a combination of Tc-99m and blue dye or blue dye alone [85% for ICG vs. 58% for the combination of Tc-99m and blue dye ($p = 0.003$) vs. 54% for blue dye alone ($p = 0.001$)] (Buda et al. 2016b).

In EMCA patients, in a retrospective validation trial including 75 patients, we recorded an overall and bilateral detection rate of 96.0 and 88.0%, respectively (Papadia et al. 2016b). In a retrospective multicenter study of five European centers including 342 patients with clinical stage I EMCA the overall detection rate of the SLN biopsy was 97.3 and 96.6% for patients undergoing SLN mapping with Tc99-m combined with blue dye and with ICG, respectively (p = ns) (Papadia et al. 2017d). On the contrary, the bilateral detection rate was significantly higher for patients undergoing SLN mapping with ICG as compared to those undergoing SLN mapping with a combination of Tc-99m and blue dye (84.1% for ICG versus 73.5% for the combination of Tc-99m and blue dye; $p = 0.03$).

In the robotic setting, Holloway first reported an improvement in bilateral detection rates, when ICG and ISB were combined for SLN mapping as compared to ISB alone in retrospective series of 35 patients (Holloway et al. 2012). Bilateral SLN detection rate was 97% for the combination of ICG and ISB and 77% for ISB alone. Similarly, Sinno et al. showed a statistically significant increase in bilateral detection rate in patients with EMCA undergoing robotic SLN mapping with ICG or ISB (78.9% for ICG vs. 42.4% for ISB, $p = 0.02$) (Sinno et al. 2014). They subsequently confirmed

their data on a larger scale showing that, on multivariate analysis, tracer choice is an associated with higher bilateral detection rates (Tanner et al. 2015). How et al. recorded overall and bilateral detection rates of Tc-99m, patent blue and ICG in a prospective trial in which 100 EMCA patients were injected in the cervix with the three tracers (How et al. 2015). SLN mapping with ICG yielded higher overall and bilateral detection rates as compared to blue dye (overall detection rate 87% for ICG vs 71% for blue dye, $p = 0.005$; bilateral detection rate 65% for ICG vs 43% for blue dye, $p = 0.002$). On the contrary SLN mapping with ICG and Tc-99m achieved similar results (overall detection rate 87% for ICG vs. 88% for Tc-99m, $p = 0.83$; bilateral detection rate 65% for ICG vs. 71% for Tc-99m, $p = 0.36$). A recent prospective cohort study showed that the combination of blue dye and ICG for SLN mapping in EMCA patients significantly increased overall and bilateral detection rates as compared to ISB alone (overall detection rate: 87.8% for the combination of ICG and ISB vs. 76% for ISB alone; bilateral detection rate: 83.9% for the combination of ICG and ISB vs. 40% for ISB alone, $p < 0.001$) (Holloway et al. 2017b). Finally, Eriksson et al. confirmed higher overall and bilateral detection rates in EMCA patients undergoing NIR-ICG SLN mapping as compared to blue dye SLN mapping (Eriksson et al. 2017). The higher overall and bilateral detection rates reduced the number of additional lymph node sampling from 61% in the patients who were injected blue dyes to 39% in the patients who were injected ICG ($p > 0.001$).

Overall, these results suggest that NIR-ICG SLN mapping has higher bilateral detection rates as compared to those recorded with the combination of Tc-99m and blue dye and have higher overall and bilateral detection rates as compared to blue dye alone. The data are summarized in Table 2. These data have been confirmed by three meta-analyses (Ruscito et al. 2016; Bodurtha et al. 2017; Lin et al. 2017). Given these results, as suggested by Ruscito et al., ICG should be the tracer of choice when performing an SLN mapping in EMCA patients because of its good toxicity profile, its ease of use which does not require the injection in a controlled environment and an image acquisition prior to surgery (Ruscito et al. 2016).

Influence of the BMI on the SLN mapping

The prevalence of obesity is steadily increasing in industrialized countries. Not only is obesity associated with an increased risk of benign and malignant pathologies (under which EMCA), but it is also associated to technically more complicated and morbid medical and surgical treatments (Papadia et al. 2006). Obese women are at higher risk of developing EMCA because of the hyperestrogenic state resulting from the peripheral aromatization of androgens to estrone in the adipose tissue (Ballard-Barbash and Swanson 1996). These hyperestrogenism-induced EMCA are typically well differentiated and have a relatively indolent biological behavior. In these cases, a full lymphadenectomy is often considered an overtreatment. Furthermore, obesity per se is a risk factor for lower limb lymphedema after lymphadenectomy (Morotti et al. 2013). On the other hand, even patients considered to be at low risk are not immune from lymph nodal metastases. Submitting these patients to SLN mapping instead of a full lymphadenectomy based on uterine risk factors identified at frozen section, results in a more accurate identification of the patients with lymph nodal metastases at a lower surgical cost (Papadia et al. 2017a; Sinno et al. 2016).

As previously mentioned, BMI affects surgery through increased OR time, increased estimated blood loss and a greater risk of developing postoperative complications such as wound infections and dehiscences (Papadia et al. 2006). In other surgical settings, there is evidence that even the SLN mapping is negatively affected by an increased BMI (Chagpar et al. 2005; Derossis et al. 2003; Soran et al. 2007). The thick adipose tissue may interfere with the identification of a colorimetric signal. Furthermore, the more extensive dissection required given the

Table 2 Overall and bilateral detection rates recorded in the trials comparing different SLN mapping tracers

Authors	*N*	Overall DR		*p*	Bilateral DR		*p*
		Tc-99m + ISB	ICG		Tc-99m + ISB	ICG	
Papadia et al. (2017c)	342	97.3%	96.6%	ns	84.1%	73.5%	0.03
		ISB	ISB + ICG		ISB	ISB + ICG	
Holloway et al. (2012)	35	na	na		77%	97%	0.02
Holloway et al. 2017b	200	76%	87.8%	ns	40%	83.9%	<0.001
		ISB	ICG		ISB	ICG	
Sinno et al. (2014)	71	77.2%	92.7%	ns	42.4%	78.9%	0.02
Tanner et al. (2015)		na	na				
Eriksson et al. (2016)	472	81%	95%	<0.001	54%	85%	<0.001

Overall DR overall detection rate, *Bilateral DR* bilateral detection rate, *Tc-99m* technetium 99m radiocolloid, *ICG* indocyanine green, *ISB* isosulfan blue

fatty retroperitoneal structures may be responsible for bleeding that may interfere with the mapping.

In EMCA patients undergoing SLN mapping, a BMI >30 kg/m^2 has been identified at multivariate analysis as a factor negatively affecting the bilateral detection rate (Tanner et al. 2015). Interestingly, when ICG was used as a tracer, the detrimental effect of an increased BMI was attenuated as compared to patients in whom ISB was used (Tanner et al. 2015). A subsequent larger retrospective analysis on EMCA patients confirmed the detrimental effect of an increased BMI on the bilateral detection rate recorded and the better overall and bilateral detection rates recorded in obese patients undergoing SLN mapping with NIR-ICG as compare to blue dyes (Eriksson et al. 2016). We speculate that the brightness of the fluorescent signal can overcome, at least to a certain extent, the shielding effect of the adipose tissue on the colorimetric signal of the tracer. These data suggest that ICG should be the tracer of choice when subjecting an obese EMCA patient to an SLN mapping procedure.

Quality of care

Data derived from two prospective validation trials in which the SLN biopsy was followed by a complete lymphadenectomy, the SENTI-ENDO and the FIRES trials, have proven the SLN biopsy to safely replace a complete lymphadenectomy in patients with early stage EMCA in whom the surgical lymph nodal assessment has a staging role (Ballester et al. 2011; Rossi et al. 2017). In these trials, the recorded false-negative rates compare well with those recorded in other settings such as breast or vulvar cancer, where the SLN biopsy has become treatment of choice replacing a full lymphadenectomy (Veronesi et al. 2003; Van der Zee et al. 2008, Mueller MD et al. 2008). Similarly as for breast and vulvar cancer, even in the case of EMCA is the SLN biopsy associated with a reduced morbidity as compared to a full lymphadenectomy (Papadia et al. 2016b). These data suggest that the application of SLN mapping as compared to a full lymphadenectomy will translate in a higher quality of care of the patients.

As far as patient satisfaction, it seems that EMCA patients undergoing SLN mapping with ICG or blue dye perceive it as a better quality of care as compared to a combined Tc-99m and blue dye injection (Buda et al. 2016a). Not having to undergo a preoperative tracer injection with Tc-99m in the Radiation Oncology Department the day prior to surgery is not only a user friendlier technique for the caregiver, but is also perceived as a better quality of care delivered by the patient.

Estimated costs and cost effectiveness

A cost-effectiveness analysis of patients with grade 1 EMCA proved the surgical staging with a full lymphadenectomy to be more cost effective than a strategy in which the surgical staging is tailored based on frozen section of the uterus after hysterectomy or a strategy based on the sole hysterectomy without surgical staging (Cohn et al. 2007). The surgical staging strategy was estimated to be 1500$ cheaper than the strategy in which the staging is tailored based on frozen section of the uterus and approximately 2200$ cheaper than the strategy in which no staging at all is performed. The cost-effectiveness results from the reduced indication, and therefore costs, related to the adjuvant radiation therapy.

In cervical cancer patients, a strategy based on Tc-99m and blue dye combined SLN mapping with ultrastaging was more cost effective than a strategy based on full lymphadenectomy with respect to 5-year progression-free survival and morbidity-free survival (Brar et al. 2017). With regard to the SLN mapping in EMCA, no cost-effectiveness studies have been performed yet.

As far as pure costs goes, the median hospital costs for women undergoing a minimally invasive hysterectomy without nodal assessment for EMCA have been estimated to be 8877$ (IQR $6974–11,352), those for patients undergoing a full lymphadenectomy have been estimated to be 10,256$ (IQR $7807–13,034) and those for patients undergoing an SLN biopsy have been estimated to be 9550$ (IQR $7278–13,124) (Wright et al. 2017). Within the different SLN mapping techniques, the one that relies on the injection of blue dyes is the cheapest as it does not require any specific hardware and since the blue dyes are very cheap. On the other hand, the lower overall and bilateral detection rates recorded with this dye may lead to an increase in side-specific pelvic lymphadenectomies with longer OR time and increased surgical short- and long-term morbidity. A lower cost may therefore not necessarily represent a more cost-effective strategy. When performing a Tc-99m SLN mapping the costs of the tracer, of the injection of the tracer and the costs of a preoperative imaging such as a SPECT–CT have to be considered. These may vary from country to country and from the type of reimbursement involved. The costs related to the NIR-ICG SLN mapping technique depend greatly on the hardware needed to detect the fluorescent signal since the costs of the ICG powder are very low. However, depending on the volume of the center, it is plausible that, after an initial investment, the NIR-ICG SLN mapping may be the most cost-effective strategy.

Table 3 Characteristics of the tracers

	Tc-99m	Blue dyes	ICG
Cost	+	−	−/+
Ease of use	−	+	+
Detection rates	++	+	+++
Comfort for the patient	−	+	+
Need for additional equipment	+	−	+
Allergic reactions	−	++	−

Conclusions

While the complete surgical resection of the tumor is of utmost importance in the treatment of primary and recurrent EMCA, similarly to other gynecological cancers, the role of staging lymphadenectomy has been discussed for decades (Lambrou et al. 2004; Papadia et al. 2015; Bellati et al. 2017, Papadia et al. 2017c, Gasparri et al. 2015, 2016; Papadia and Morotti 2013; Valenzano Menada et al. 2003). In early stage EMCA patients the SLN biopsy as compared to a full lymphadenectomy seems to offer the opportunity to obtain an adequate pathologic information with a reduced surgical morbidity and has been recognized as an accepted alternative to a full lymphadenectomy by the NCCN guidelines (NCCN guidelines 2014). Various tracers, alone or in combination, can be used and their characteristics are summarized in Table 3. Where the hardware is available, NIR-ICG SLN mapping, either laparoscopic or robotic, seems to be superior to SLN mapping with blue dyes, Tc-99m or a combination thereof. It allows for higher bilateral detection rates, performs better in obese patients, is user-friendly and is perceived by the patients as a better quality of care delivered.

Compliance with ethical standards

Funding This study was not funded.

Conflict of interest None of the authors have any conflict of interest to declare.

Ethical approval This article is a review of series already published by peer reviewed journals. It does not contain any human participants or animals. No animals were involved as this is a review of the published literature. No humans were involved as this is a review of the published literature.

References

Albo D, Wayne JD, Hunt KK et al (2001) Anaphylactic reactions to isosulfan blue dye during sentinel lymph node biopsy for breast cancer. Am J Surg 182:393–398

ASTEC study group; Kitchener H, Swart AM et al (2009) Efficacy of systematic pelvic lymphadenectomy in endometrial cancer (MRC ASTEC trial): a randomized study. Lancet 373:125–36

Ballard-Barbash R, Swanson CA (1996) Body weight: estimation of risk for breast and endometrial cancers. Am J Clin Nutr 63:437S–441S

Ballester M, Dubernard G, Lécuru F et al (2011) Detection rate and diagnostic accuracy of sentinel-node biopsy in early stage endometrial cancer: a prospective multicentre study (SENTI-ENDO). Lancet Oncol 12:469–476

Barlin JN, Khoury-Collado F, Kim CH et al (2012) The importance of applying a sentinel lymph node mapping algorithm in endometrial cancer staging: beyond removal of blue nodes. Gynecol Oncol 125:531–535

Bellati F, Papadia A, Gasparri ML et al (2017) Tertiary cytoreduction for recurrent endometrial cancer. Eur J Gynaecol Oncol 38:132–134

Benedetti Panici P, Basile S, Maneschi F et al (2008) Systematic pelvic lymphadenectomy vs. no lymphadenectomy in early-stage endometrial carcinoma: randomized clinical trial. J Natl Cancer Inst 100:1707–1716

Blessing WD, Stolier AJ, Teng SC et al (2002) A comparison of methylene blue and lymphazurin in breast cancer sentinel node mapping. Am J Surg 184:341–345

Bodurtha Smith AJ, Fader AN, Tanner EJ (2017) Sentinel lymph node assessment in endometrial cancer: a systematic review and meta-analysis. An J Obstet Gynecol. 216:459–476

Bogani G, Dowdy SC, Cliby WA et al (2014) Role of pelvic and para-aortic lymphadenectomy in endometrial cancer: current evidence. J Obstet Gynaecol Res 40:301–311

Brar H, Hogen L, Covens A (2017) Cost-effectiveness of sentinel node biopsy and pathological ultrastaging in patients with early-stage cervical cancer. Cancer 123:1751–1759

Buda A, Elisei F, Palazzi S et al (2016a) Quality of care for cervical and endometrial cancer patients: the impact of different techniques of sentinel lymph node mapping on patient satisfaction. Ann Surg Oncol 23:2975–2981

Buda A, Crivellaro C, Elisei F et al (2016b) Impact of indocyanine green for sentinel lymph node mapping in early stage endometrial and cervical cancer: comparison with conventional radiotracer (99m)Tc and/or blue dye. Ann Surg Oncol 23:2183–2191

Buda A, Papadia A, Zapardiel I et al (2016c) From conventional radiotracer Tc-99(m) with blue dye to indocyanine green fluorescence: a comparison of methods towards optimization of sentinel lymph node mapping in early stage cervical cancer for a laparoscopic approach. Ann Surg Oncol 23:2959–2965

Cabanas RM (1977) An approach for the treatment of penile carcinoma. Cancer 39:456–466

Chagpar AB, Martin RC, Scoggins CR et al (2005) Factors predicting failure to identify a sentinel lymph node in breast cancer. Surgery 138:56–63

Cimmino VM, Brown AC, Szocik JF et al (2001) Allergic reactions to isosulfan blue during sentinel node biopsy—a common event. Surgery 130:439–442

Cohn DE, Huh WK, Fowler JM et al (2007) Cost-effectiveness analysis of strategies for the surgical management of grade 1 endometrial adenocarcinoma. Obstet Gynecol 109:1388–1395

Colombo N, Creutzberg C, Amant F et al (2016) ESMOESGO-ESTRO Consensus Conference on Endometrial Cancer: diagnosis, treatment and follow-up. Ann Oncol 27:16–41

Cordova MA, Hladik WB, Rhodes BA (1984) Validation and characterization of adverse reactions to radiopharmaceuticals. Noninvasive Med Imag 1:17–24

Derossis AM, Fey JV, Cody HS, Borgen PI (2003) Obesity influences outcome of sentinel lymph node biopsy in early-stage breast cancer. J Am Coll Surg 197:896–901

Di Martino G, Crivellaro C, De Ponti E et al (2017) Indocyanine green versus radiotracer ± blue dye for sentinel lymph node mapping in >Stage IB1 cervical cancer (>2 cm). J Minim Invasive Gynecol. doi:10.1016/j.jmig.2017.05.011 (**Epub ahead of print**)

Ditto A, Martinelli F, Bogani G et al (2015) Sentinel node mapping using hysteroscopic injection of indocyanine green and laparoscopic near-infrared fluorescence imaging in endometrial cancer staging. J Minim Invas Gynecol 22:132–133

Elisei F, Crivellaro C, Giuliani D et al (2017) Sentinel-node mapping in endometrial cancer patients: comparing SPECT/CT, gamma-probe and dye. Ann Nucl Med 31:93–99

Eriksson AG, Montovano M, Beavis A et al (2016) Impact of obesity on sentinel lymph node mapping in patients with newly diagnosed uterine cancer undergoing robotic surgery. Ann Surg Oncol 23:2522–2528

Eriksson AG, Beavis A, Soslow RA et al (2017) A comparison of the detection of sentinel lymph nodes using indocyanine green and near-infrared fluorescence imaging versus blue dye during robotic surgery in uterine cancer. Int J Gynecol Cancer. 27:743–747

Friedlaender P. (1888) Fortschitte der Theerfabenfabrikation und verwandter Industriezweige, vol 1. Julius Springer, Berlin, pp 247–249

Gasparri ML, Panici PB, Papadia A (2015) Primary chemotherapy versus primary surgery for ovarian cancer. Lancet 386:2142–2143

Gasparri ML, Grandi G, Bolla D et al (2016) Hepatic resection during cytoreductive surgery for primary or recurrent epithelial ovarian cancer. J Cancer Res Clin Oncol 142:1509–1520

Golshan M, Nakhlis F (2006) Can methylene blue only be used in sentinel lymph node biopsy for breast cancer? Breast J 12:428–430

Hirsch JI, Tisnado J, Cho SR, Beachley MC (1982) Use of isosulfan blue for identification of lymphatic vessels: experimental and clinical evaluation. AJR Am J Roentgenol 139:1061–1064

Holloway RW, Bravo RA, Rakowski JA et al (2012) Detection of sentinel lymph nodes in patients with endometrial cancer undergoing robotic-assisted staging: a comparison of colorimetric and fluorescence imaging. Gynecol Oncol 126:25–29

Holloway RW, Abu-Rustum NR, Backes FJ et al (2017a) Sentinel lymph node mapping and staging in endometrial cancer: a society of gynecologic oncology literature review with consensus recommendations. Gynecol Oncol. doi:10.1016/j.ygyno.2017.05.027 (**Epub ahead of print**)

Holloway RW, Ahmad S, Kendrick JE et al (2017b) A prospective cohort study comparing colorimetric and fluorescent imaging for sentinel lymph node mapping in endometrial cancer. Ann Surg Oncol 24:1972. doi:10.1245/s10434-017-5825-3

Hope-Ross M, Yannuzzi LA, Gragoudas ES et al (1994) Adverse reactions due to indocyanine green. Ophthalmology 101:529–533

How J, Gotlieb WH, Press JZ et al (2015) Comparing indocyanine green, technetium, and blue dye for sentinel lymph node mapping in endometrial cancer. Gynecol Oncol 137:436–442

Imboden S, Papadia A, Nauwerk M et al (2015) A comparison of radiocolloid and indocyanine green fluorescence imaging, sentinel lymph node mapping in patients with cervical cancer undergoing laparoscopic surgery. Ann Surg Oncol 22:4198–4203

Johann S, Klaeser B, Krause T, Mueller MD (2008) Comparison of outcome and recurrence-free survival after sentinel lymph node biopsy and lymphadenectomy in vulvar cancer. Gynecol Oncol 110:324–328

Khoury-Collado F, Glaser GE, Zivanovic O et al (2009) Improving sentinel lymph node detection rates in endometrial cancer: how many cases are needed? Gynecol Oncol 115:453–455

Kieckbusch H, Coldewey SM, Hollenhorst J et al (2008) Patent blue sentinel node mapping in cervical cancer patients may lead to decreased pulse oximeter readings and positive methaemoglobin results. Eur J Anaesthesiol 25:365–368

Krohne TU, Allam JP, Novak N, Holz FG (2016) "Iodine allergy": a medical myth with risks for the ophthalmological patient. Ophthalmologe 113:1023–1028

Lambrou NC, Gómez-Marín O, Mirhashemi R et al (2004) Optimal surgical cytoreduction in patients with Stage III and Stage IV endometrial carcinoma: a study of morbidity and survival. Gynecol Oncol 93:653–658

Laufer J, Scasso S, Papadia A et al (2013) Association between tumor diameter and lymphovascular space invasion among women with early-stage endometrial cancer. Int J Gynaecol Obstet 123:142–145

Leong SP, Donegan E, Heffernon W et al (2007) Adverse reactions to isosulfan blue during selective sentinel lymph node dissection in melanoma. Ann Surg Oncol 7:361–366

Lin H, Ding Z, Kota VG et al (2017) Sentinel lymph node mapping in endometrial cancer: a systematic review and meta-analysis. Oncotarget. doi:10.18632/oncotarget.1662 (**Epub ahead of print**) Review

Lyman GH, Giuliano AE, Somerfield MR et al (2005) American society of clinical oncology guideline recommendations for sentinel lymph node biopsy in early-stage breast cancer. J Clin Oncol 23:7703–7720

Martinelli F, Ditto A, Boga et al (2017) Laparoscopic sentinel node mapping in endometrial cancer after hysteroscopic injection of indocyanine green. J Minim Invasive Gynecol 24:89–93

Masannat Y, Shenoy H, Speirs V et al (2006) Properties and characteristics of the dyes injected to assist axillary sentinel node localization in breast surgery. Eur J Surg Oncol 32:381–384

Montgomery LL, Thorne AC, Van Zee KJ et al (2002) Isosulfan blue dye reactions during sentinel lymph node mapping for breast cancer. Anesth Analg 95:385–388

Morotti M, Menada MV, Moioli M et al (2012) Frozen section pathology at time of hysterectomy accurately predicts endometrial cancer in patients with preoperative diagnosis of atypical endometrial hyperplasia. Gynecol Oncol 125:536–540

Morotti M, Menada MV, Boccardo F et al (2013) Lymphedema microsurgical preventive healing approach for primary prevention of lower limb lymphedema after inguinofemoral lymphadenectomy for vulvar cancer. Int J Gynecol Cancer 23:769–774

Morton DL, Thompson JF, Cochran AJ et al (2006) Sentinel-node biopsy or nodal observation in melanoma. N Engl J Med 355:1307–1317

NCCN Clinical Practice Guidelines in Oncology. Uterine Neoplasms. Version 2.2014. http://www.nccn.org/professionals/physician_gls/pdf/uterine.pdf

Papadia A, Morotti M (2013) Diaphragmatic surgery during cytoreduction for primary or recurrent epithelial ovarian cancer: a review of the literature. Arch Gynecol Obstet 287:733–741

Papadia A, Remorgida V, Salom EM, Ragni N (2004) Laparoscopic pelvic and paraaortic lymphadenectomy in gynecologic oncology. J Am Assoc Gynecol Laparosc 11:297–306

Papadia A, Ragni N, Salom EM (2006) The impact of obesity on surgery in gynecological oncology: a review. Int J Gynecol Cancer. 16:944–952

Papadia A, Azioni G, Brusaca B et al (2009) Frozen section underestimates the need for surgical staging in endometrial cancer patients. Int J Gynecol Cancer 19:1570–1573

Papadia A, Bellati F, Ditto A et al (2015) Surgical treatment of recurrent endometrial cancer: time for a paradigm shift. Ann Surg Oncol 22:4204–4210

Papadia A, Imboden S, Gasparri ML et al (2016a) Endometrial and cervical cancer patients with multiple sentinel lymph nodes at laparoscopic ICG mapping: how many are enough? J Cancer Res Clin Oncol 142:1831–1836

Papadia A, Imboden S, Siegenthaler F et al (2016b) Laparoscopic indocyanine green sentinel lymph node mapping in endometrial cancer. Ann Surg Oncol 23:2206–2211

Papadia A, Mohr S, Imboden S et al (2016c) Laparoscopic indocyanine green sentinel lymph node mapping in pregnant cervical cancer patients. J Minim Invasive Gynecol 1(23):270–273

Papadia A, Gasparri ML, Mueller MD (2017a) Is it time to consider the sentinel lymph node mapping the new standard in endometrial cancer? Transl Cancer Res. Accepted for publication. doi:10.21037/tcr.2017.05.10

Papadia A, Gasparri ML, Siegenthaler F et al (2017b) FIGO stage IIIC endometrial cancer identification among patients with complex atypical hyperplasia, grade 1 and 2 endometrioid endometrial cancer: laparoscopic indocyanine green sentinel lymph node mapping versus frozen section of the uterus, why get around the problem? J Cancer Res Clin Oncol 143:491–497

Papadia A, Zapardiel I, Bussi B et al (2017c) Sentinel lymph node mapping in patients with stage I endometrial carcinoma: a focus on bilateral mapping identification by comparing radiotracer Tc99 ^m with blue dye versus indocyanine green fluorescent dye. J Cancer Res Clin Oncol 143:475–480

Papadia A, Nirgianakis K, Gasparri ML et al (2017d) PET/CT guided surgical excision of small abdominal wall metastases in morbidly obese endometrial cancer patients. Minerva Ginecol 69:206–207

Pinero A, Illana J, Garcia-Palenciano C et al (2004) Effect on oximetry of dyes used for sentinel lymph node biopsy. Arch Surg 139:1204–1207

Richards P, Tucker WD, Srivastava SC (1982) Technetium-99m: an historical perspective. Int J Appl Radiat Isotopes 33:793–799

Rossi EC, Kowalski LD, Scalici J et al (2017) A comparison of sentinel lymph node biopsy to lymphadenectomy for endometrial cancer staging (FIRES trial): a multicentre, prospective, cohort study. Lancet Oncol 18:384–392

Ruscito I, Gasparri ML, Braicu EI et al (2016) Sentinel node mapping in cervical and endometrial cancer: indocyanine green versus other conventional dyes—a metaanalysis. Ann Surg Oncol 23:3749–3756

Sala P, Morotti M, Menada MV et al (2014) Intraoperative frozen section risk assessment accurately tailors the surgical staging in patients affected by early-stage endometrial cancer: the application of 2 different risk algorithms. Int J Gynecol Cancer 24:1021–1026

Segrè E, Seaborg GT (1938) Nuclear isomerism in element 43. Phys Rev 54:772

Sharma C, Deutsch I, Lewin SN et al (2011) Lymphadenectomy influences the utilization of adjuvant radiation treatment for endometrial cancer. Am J Obstet Gynecol 205:e1–e9

Simpkins F, Papadia A, Kunos C et al (2013) Patterns of recurrence in stage I endometrioid endometrial adenocarcinoma with lymphovascular space invasion. Int J Gynecol Cancer 23:98–104

Sinno AK, Fader AN, Roche KL et al (2014) A comparison of colorimetric versus fluorometric sentinel lymph node mapping during robotic surgery for endometrial cancer. Gynecol Oncol 134:281–286

Sinno AK, Peijnenburg E, Fader AN et al (2016) Reducing overtreatment: a comparison of lymph node assessment strategies for endometrial cancer. Gynecol Oncol 143:281–286

Soran A, Falk J, Bonaventura M et al (2007) Does failure to visualize a sentinel node on preoperative lymphoscintigraphy predict a greater likelihood of axillary lymph node positivity? J Am Coll Surg 205:66–71

Takahashi N, Nimura H, Fujita T et al (2017) The evident fluorescent signal helps making the identification of the SLN easier. Laparoscopic sentinel node navigation surgery for early gastric cancer: a prospective multicenter trial. Langenbecks Arch Surg 402:27–32

Tanner EJ, Sinno AK, Stone RL et al (2015) Factors associated with successful bilateral sentinel lymph node mapping in endometrial cancer. Gynecol Oncol 138:542–547

Valenzano Menada M, Papadia A, Lorenzi P et al (2003) Breast cancer metastatic to the vulva after local recurrence occurring on a rectus abdominis myocutaneous flap: a case report and review of the literature. Eur J Gynaecol Oncol 24:577–579

Van der Zee AG, Oonk MH, De Hullu JA et al (2008) Sentinel node dissection is safe in the treatment of early-stage vulvar cancer. J Clin Oncol 26:884–889

Varghese P, Abdel-Rahman AT, Akberali S et al (2008) Methylene blue dye—a safe and effective alternative for sentinel lymph node localization. Breast J 14:61–67

Veronesi U, Paganelli G, Viale G (2003) A randomized comparison of sentinel-node biopsy with routine axillary dissection in breast cancer. N Engl J Med 349:546–553

Vieira SC, Sousa RB, Tavares MB et al (2008) Changes in pulse oximetry after patent blue dye injection into the uterine cervix. Ann Surg Oncol 15:2862–2866

Walker JL, Piedmonte MR, Spirtos NM et al (2009) Laparoscopy compared with laparotomy for comprehensive surgical staging of uterine cancer: gynecologic Oncology Group Study LAP2. J Clin Oncol 27:5331–5336

Wright JD, Cham S, Chen L et al (2017) Utilization of sentinel lymph node biopsy for uterine cancer. Am J Obstet Gynecol. 216:594.e1–594.e13