

Short report

Prognostic value of cerebrospinal fluid cytology in pediatric medulloblastoma

R. Miralbell,¹ S. Bieri,⁷ P. Huguenin,² A. Feldges,⁶ A. M. Morin,³ E. Garcia,⁴ H. P. Wagner,² P. Wacker¹ & N. von der Weid⁵ for the Swiss Pediatric Oncology Group

University Hospitals of ¹Geneva, ²Zürich, ³Basel, ⁴Lausanne, ⁵Bern; ⁶Cantonal Hospital of St. Gallen; ⁷Ospedale San Giovanni of Bellinzona, Switzerland

Summary

Background: Although the demonstration of leptomeningeal dissemination is the most important predictor of poor outcome in children with medulloblastoma, there is lack of consensus on the prognostic value of a positive cerebrospinal fluid (CSF) cytology (i.e., stage M1).

Patients and methods: Eighty-six pediatric medulloblastoma patients treated in Switzerland between 1972–1991 were retrospectively studied regarding the influence of M-stage on prognosis. 39 were M0, 13 M1, 15 Mx, 17 M2, and 2 M3.

Results: Five- and 10-year overall survival rates were 76% and 54% for M0, 68% and 50% for Mx, 36% and 25% for M1, and 22% and 22% for M2–3 ($P < 0.001$), respectively. No significant survival differences were observed between M1 and M2–3 patients. Among 26 patients with only postoperative CSF cytologies, seven were positive. Their outcome was similar

to that of six preoperatively staged M1 and significantly different from that of M0 patients ($P = 0.001$). In 14 patients both pre- and postoperative CSF cytology was performed. Total agreement was observed between the pre- and postoperative results (six positive and eight negative). Among the 19 M2–3 patients CSF cytology was positive in eight, negative in five, and unknown in six.

Conclusions: A positive CSF cytology either pre- or postoperatively predicts for a poor outcome, similar to that observed in stage M2–3 patients. A postoperative cytology is likely to be concordant with cytologic results obtained preoperatively, and seems to have the same prognostic significance. A negative cytology, however, does not exclude a more advanced stage.

Key words: cerebrospinal fluid cytology, leptomeningeal metastases, medulloblastoma

Introduction

The presence of leptomeningeal involvement at the time of diagnosis is the most powerful predictor of unfavorable outcome in children treated for medulloblastoma [2–4]. However, although cerebrospinal fluid (CSF) cytology is an important component of the most widely used staging system, the prognostic value of a positive cytology remains controversial. A 1995 report of results from a trial of the International Society of Pediatric Oncology [4] concluded that the presence of leptomeningeal metastases was the only factor related to poor survival, despite the fact that CSF cytology was not taken into account, nor was spinal imaging mandatory to rule out subarachnoidal spread. Moreover, it has been suggested [2, 5] that a positive postoperative CSF cytology may be the result of surgical shedding and is therefore of doubtful prognostic value. The purpose of the present study was to retrospectively assess the prognostic value of CSF cytology at diagnosis in a consecutive series of pediatric medulloblastoma patients treated in Switzerland over a 20-year period.

Patients and methods

Eighty-six children and adolescents with a diagnosis of medulloblastoma were treated at the Swiss University and Cantonal Hospitals during the period 1972 to 1991. All clinical and treatment records were reviewed. Open surgery was carried out in all patients. Resection was considered complete in 30 patients, subtotal in 42 patients, and in 14 cases only a biopsy or partial resection (minor debulking) was undertaken.

Postoperative megavoltage radiotherapy (RT) was delivered to all patients, in the form of craniospinal axis irradiation, followed by a boost to the posterior fossa. The midplane dose prescribed to the whole brain in the beam axis was < 30 Gy in 18 patients (no patient received < 23.4 Gy), 30–35 Gy in 21 patients, and > 35 Gy in 47 patients (no patient received > 45 Gy). The spine was treated with a single posterior field or a pair of two abutting posterior fields including the dural sac from C2–C4 to S2 were used. The prescribed dose was < 30 Gy in 30 patients, 30–35 Gy in 24 patients, and > 35 Gy in 32 patients. The total dose delivered to the posterior fossa at the reference point was < 54 Gy in 27 patients and ≥ 54 Gy in 59 patients.

Adjuvant chemotherapy was given to 62 of the 86 children after radiotherapy according to one of the following protocols: vincristine, procarbazine and prednisone (1972–1981); nitrogen mustard, vincristine, procarbazine and prednisone (MOPP; 1982–1984); vincristine and CCNU (1985–1986); cisplatin and etoposide followed by vincristine and cyclophosphamide (1990–1991). Between 1987 and 1989 a two month schedule of chemotherapy (vincristine, cisplatin, and cyclo-

Table 1. Clinical characteristics for 86 medulloblastoma patients treated from 1972 to 1991.

Feature	Number of patients (%)
Age (in years)	
Median	8.2
Range	1.7–18
Sex	
Male	66 (77)
Female	20 (23)
T-stage (Chang)	
T2	24 (28)
T3	46 (53)
T4	13 (15)
Tx	3 (3)
CSF cytology	
Positive	18 (21)
Negative	47 (55)
Unknown	21 (24)
M-stage (Chang)	
M0	39 (45)
M1	13 (15)
M2	17 (20)
M3	2 (2)
Mx	15 (17)

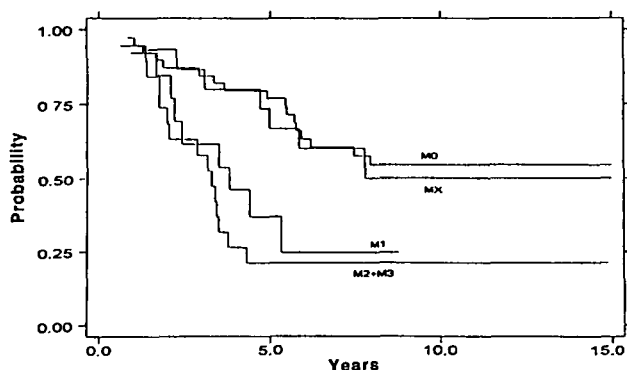


Figure 1. Overall survival curves (Kaplan–Meier) by M-stage at diagnosis: M0 vs. M1 vs. M2–3 vs. Mx.

phosphamide) was 'sandwiched' between surgical resection and the start of RT. Inclusion of patients in adjuvant chemotherapy protocols were unrelated to established clinical risk factors.

The patients' clinical characteristics are summarized in Table 1. Both T-stage and M-stage were assigned retrospectively according to the guidelines of Chang et al. [6]. T-stage was determined by review of operative reports. Disease spread had been investigated using standard radiologic tools considered appropriate at the time of diagnosis (i.e., pneumoencephalogram, radioisotopic brain scan, computerized tomography, magnetic resonance imaging). A systematic search for drop metastases to the spinal theca was not done in all patients. Only 22 patients underwent either myelography and/or spinal MRI (2 of 53 before 1986, and 20 of 33 thereafter).

CSF cytologies were available in 65 patients (76%). Preoperative CSF cytologies were done at the time of ventricular shunting, prior to posterior fossa surgery. Postoperative CSF cytologies were obtained from lumbar punctures performed during the first two weeks after surgery. During the time of this study no general guidelines were in force regarding cytological examination of CSF in pediatric brain tumor patients. The techniques used were therefore those that had been adopted by the institute of pathology in each participating institution. A central pathology review for the purpose of this study was not performed. Fifty-two children were staged exclusively on cytologic

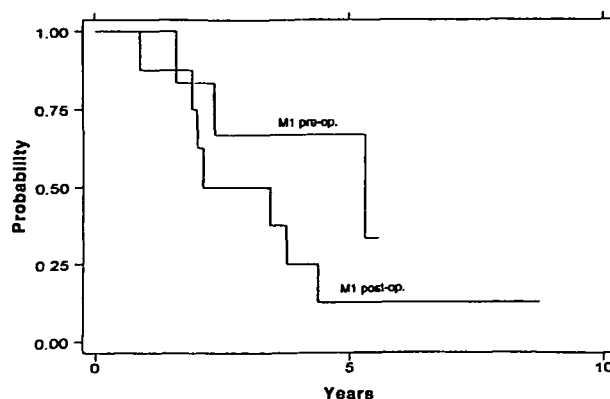


Figure 2. Overall survival curves (Kaplan–Meier) for M1 patients staged either preoperatively or postoperatively.

grounds (M0 if negative; M1 if positive); 12 had only preoperative cytologies, 26 only postoperative cytologies, and 14 both pre- and postoperative cytologies. From 54 patients coded as 'non-metastatic' (M0) in the Swiss pediatric tumor registry, documentation of negative CSF cytology was found in only 39 at the time of review. In summary, 39 patients were M0 (negative cytology); 13 M1 (positive cytology); 17 M2 (gross cerebral or cerebellar subarachnoidal invasion); 2 M3 (gross subarachnoidal spinal seeding); and 15 Mx (cytology unknown).

Overall survival was calculated according to the Kaplan–Meier method. The log-rank test was used to examine the correlation of survival with M-stage (i.e., M0 versus Mx versus M1 versus M2–3) as well as with pertinent subgroups (e.g., pre- versus postoperative positive CSF cytology).

Results

Five- and 10-year overall survival rates were 76% and 54% for stage M0, 36% and 25% for stage M1, 22% and 22% for stages M2–3, and 68% and 50% for stage Mx, respectively ($P < 0.001$, Figure 1). Overall survival did not differ significantly between stage M0 and stage Mx patients ($P = 0.812$), or between stage M1 and stage M2–3 patients ($P = 0.376$). Among 26 children with only postoperative CSF cytologic staging, a positive cytology was observed in seven cases. Their survival was significantly worse than that of M0 patients ($P = 0.001$) and similar to that of six M1 patients whose stage was determined exclusively by preoperative cytology ($P = 0.168$, Figure 2). In 14 patients both pre- and postoperative CSF cytology was performed. Total agreement was observed between the pre- and postoperative results (six positive, eight negative). However, among the 17 M2 patients (gross cerebral or cerebellar subarachnoidal invasion) CSF cytology was positive in only three cases, was negative in eight, and was unknown in six. CSF cytology was positive in both M3 patients.

Discussion

In the present study a positive CSF cytology was in itself strongly predictive of an unfavorable outcome after treatment of pediatric medulloblastoma. The overall

survival of M1 and M2–3 patients was similar, and in both cases significantly different from that of M0 patients. Deutsch [7] reported comparable results in 52 medulloblastoma patients, all of whom had undergone myelography and all but two cytologic analysis of at least one CSF sample taken from a shunt or a spinal puncture site. Failure rates for M0, M1, and M2–3 patients were 25%, 50%, and 60%, respectively. Furthermore, Evans et al. [2] reported on 233 medulloblastoma patients included in a randomized trial of the Childrens Cancer Study Group. In patients staged as M0, CSF cytology or myelography were performed in only 56% and 11%, respectively. Nevertheless, the five-year event-free survival rate in this group of inadequately staged M0 patients was 59%, significantly higher than the 40% rate observed in M1 patients. There were no significant differences in survival rates between M1, M2, and M3 patients. Finally, Merchant et al. [3], reported on 100 medulloblastoma patients who underwent rigorous staging procedures: CSF cytology in 95%, and myelogram or MRI in 94%. Again, CSF cytology was highly predictive of overall and disease-free survival in uni- and multivariate analysis. These results are consistent with the notion that a positive cytology is a powerful prognostic indicator, associated with an outcome similar to that of patients staged as M2 or M3.

The small proportion of M3 patients observed in the present study most likely reflects the infrequent use of spinal imaging prior to 1986. This is in contrast with a much higher availability of CSF cytologic information at diagnosis (76% of children). In Deutsch's report [7] among 18 patients with positive cytologies at diagnosis, 11 had positive myelograms. Thus, one might speculate that a similar proportion of our M1 patients might have been understaged. Although understaging might diminish the prognostic value of an isolated positive CSF cytology, this did not seem to be the case in Deutsch's [7] and Merchant's et al. [3] reports, in which similar low survival rates were observed for M1 vs. M2–3 stages, even when adequate staging procedures were used.

The importance of the timing of the cytologic examination is controversial. Unlike Balhuizen et al. [5], who observed a higher incidence of positive CSF cytologies at postoperative than at preoperative evaluation, in both our study and that of Deutsch [7], a similar proportion of positive pre- and post-operative cytologies was found. Furthermore, among 14 patients in our study in whom pre- and postoperative CSF cytologies were performed, complete agreement was observed between both results. This high level of concordance was not found by Deutsch and Reigel [8], who observed among patients with both pre- and postoperative CSF cytologies that in four patients with positive postoperative cytologies only one was positive, but three negative before surgery. No information was provided, however, regarding the clinical course of the three patients with 'false' positive postoperative

cytologies. In the present study survival of M1 patients staged by lumbar puncture after surgery was not different from that of M1 patients assessed preoperatively (Figure 3), suggesting that a positive CSF cytology correlates with a poor outcome, regardless of the time of assessment. To our knowledge there are no other data in the literature addressing this particular point.

In summary, between 20%–30% of pediatric medulloblastoma patients have a positive CSF cytology. The rate of positivity appears similar whether determined either pre- and postoperatively, and the results are generally (but not always) concordant. Pre- and postoperative positive cytologies both appear to predict for a poor outcome, similar to that associated with stages M2 and M3. However, a negative cytology does not always exclude a more advanced stage, in that cytology was negative in 8 out of 11 evaluable M2 patients in the present study. These data underscore the usefulness of CSF cytology in medulloblastoma staging, but support the continued use of other staging procedures, including spinal imaging.

References

1. Farwell JR, Dohrmann GJ, Flannery JT. Central nervous system tumors in children. *Cancer* 1977; 40: 3123–32.
2. Evans AE, Jenkin RDT, Sposto R et al. The treatment of medulloblastoma. Results of a prospective randomized trial of radiation therapy with and without CCNU, vincristine, and prednisone. *J Neurosurg* 1990; 72: 572–82.
3. Merchant TE, Wang MH, Haida T et al. Medulloblastoma: Long-term results for patients treated with definitive radiation therapy during the computed tomography era. *Int J Radiat Oncol Biol Phys* 1996; 36: 29–35.
4. Bailey CC, Gnekow A, Wellek S et al. Prospective randomised trial of chemotherapy given before radiotherapy in childhood medulloblastoma. International Society of Paediatric Oncology (SIOP) and the (German) Society of Paediatric Oncology (GPO): SIOP II. *Med Pediatr Oncol* 1995; 25: 166–78.
5. Balhuizen JC, Bots GTAM, Schaberg A, Bosman FT. Value of cerebrospinal fluid cytology for the diagnosis of malignancies in the central nervous system. *J Neurosurg* 1978; 48: 747–53.
6. Chang CH, Housepian EM, Herbert CJ Jr. An operative staging system and a megavoltage radiotherapy technique for cerebellar medulloblastoma. *Radiology* 1969; 93: 1351–9.
7. Deutsch M. Medulloblastoma: Staging and treatment outcome. *Int J Radiat Oncol Biol Phys* 1988; 314: 1103–7.
8. Deutsch M, Reigel DH. Myelography and cytology in the treatment of medulloblastoma. *Int J Radiat Oncol Biol Phys* 1981; 7: 721–5.

Received 20 August 1998; accepted 25 November 1998.

Correspondence to:
R. Miralbell, MD
Division de Radio-oncologie
Hôpital Cantonal Universitaire
1211 Genève 14
Switzerland
E-mail: Raymond.Miralbell@hcuge.ch

