

Case report

# Atherosclerotic disruption of the aortic arch during coronary artery bypass operation

Friedrich Stefan Eckstein, Hans-Peter Dinkel, Aristomenis Exadactylos, Thierry-Pierre Carrel\*

*Clinic for Cardiovascular Surgery and Diagnostic Radiology, University Hospital of Berne (Inselspital), CH-3010 Berne, Switzerland*

Received 16 May 2000; received in revised form 27 July 2000; accepted 15 August 2000

## Abstract

A 70-year-old-man presented with a symptomatic three vessel coronary artery disease and was scheduled for myocardial revascularization. During extracorporeal circulation an intrathoracic bleeding occurred and aortic rupture was suspected. An iatrogenic plaque rupture in the concavity of the aortic arch was found due to cannulation attempts. The aortic arch was grafted in the so-called elephant trunk technique. Thereafter bypass grafts were anastomosed to the stenosed coronary arteries. The patient was discharged from hospital after 2 weeks in good condition. © 2000 Elsevier Science B.V. All rights reserved.

*Keywords:* Coronary surgery; Iatrogenic cannulation injuries; Atherosclerotic aortic arch ulcer; Aortic arch replacement; Elephant trunk

## 1. Introduction

We report a case of disruption of the aortic arch due to atherosclerotic ulceration after ascending aortic cannulation for coronary artery bypass grafting. The disruption was triggered after manipulation to an atherosclerotic ulcer after introduction of a long aortic cannula. We describe the intraoperative findings and how this serious complication was managed.

## 2. Patient and methods

A 70-year-old-man presented with a symptomatic three vessel coronary artery disease and was scheduled for myocardial revascularization. Plain chest roentgenogram showed no signs of aortal atherosclerosis. Following median sternotomy the left pleural cavity was opened to harvest left internal thoracic artery while a saphenous vein graft was prepared at the same time. Arterial cannulation was performed with a long arterial cannula (flexible arterial cannula, 24 F, Sarns<sup>®</sup>) with the tip placed in the proximal descending aorta. In this patient insertion of the cannula was not possible in a satisfactory way beyond the aortic arch. After two attempts by the same surgeon the cannula was removed and transoesophageal echocardiography was inserted to exclude an aortic dissection or disruption. A

smaller cannula (22 F, Sarns<sup>®</sup>) was introduced 1.5 cm only in the ascending aorta under echocardiographic control and standard two-stage cannulation technique was used for venous return. Extracorporeal circulation (ECC) was instituted in stable hemodynamic condition. After 5 min of ECC blood pressure dropped and bleeding occurred out of the opened left hemithorax. At that time it was not possible to locate exactly the bleeding but an aortic rupture was suspected. The patient was cooled at a lowest temperature of 18°C. The 4th intercostal space was opened by an additional hemi-clamshell incision for getting better access to a possible disruption of the descending aorta. Immediately before deep hypothermic arrest the supra-aortic vessels were occluded and a linear oblique incision at the beginning of the aortic arch was made. This revealed a plaque rupture in the concavity of the aortic arch. The decision was made to graft the aortic arch in a fashion first described by Borst et al. in 1983 [1], the so-called elephant trunk technique. Only with this technique a stabilization of the atherosclerotic lesion formations in the distal aortic arch and the proximal descending aorta could be obtained. A 24 mm Vascutek prosthesis was invaginated, placed in the descending aorta and fixed below the perforation site. The invaginated part of the vascular prosthesis was pulled out by a stay suture and the supra-aortic vessels were sutured in the prosthesis using one aortic patch containing the three ostia. The prosthesis was finally anastomosed to the distal ascending aorta which was cannulated again to rewarm the patient. The aorta was clamped distally and antegrade cold blood cardioplegia was

\* Corresponding author. Tel.: +41-316-322-375; fax: +41-313-820-279.  
E-mail address: thierry.carrel@insel.ch (T.-P. Carrel).

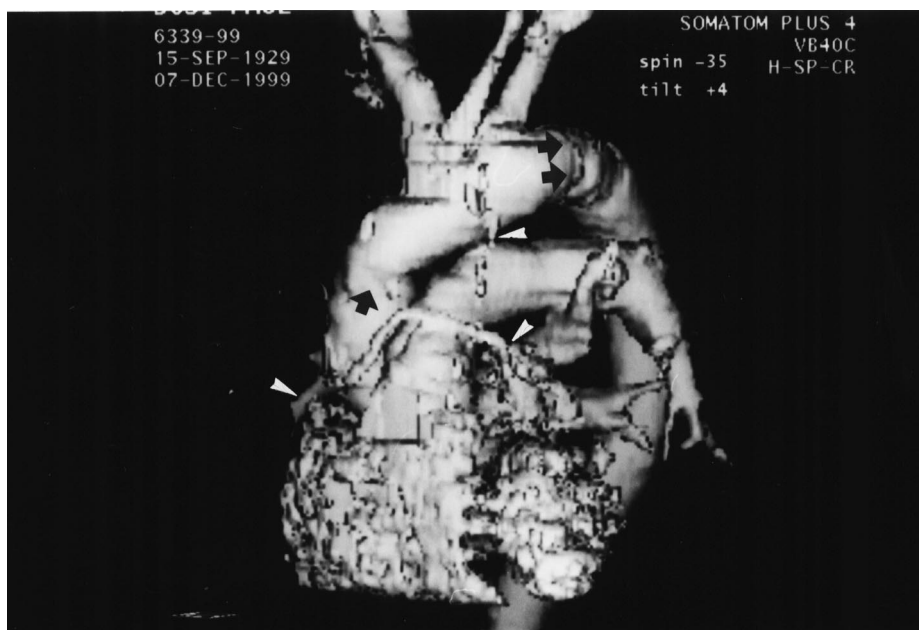


Fig. 1. Postoperative CT scan revealed proximal (arrow) and distal anastomosis with the distal part of the elephant trunk (double arrow) of the homogenous implanted prosthesis as well as the implanted supraaortic vessel patch. Patent coronary ITA and vein (white arrow heads) are additionally visible.

instilled. During the rewarming period two saphenous vein grafts and the left internal thoracic artery were anastomosed to the stenosed coronary arteries. Before removing the aortic clamp hot-shot blood cardioplegia was instilled. The patient was weaned off bypass, transferred in a stable hemodynamic condition and was extubated on the second postoperative day. Postoperative computed tomography (CT) scan was performed to demonstrate the correct position of the implanted aortic graft and the supraaortic vessel patch as well as the patency of the coronary bypass grafts (Fig. 1). The patient was discharged from hospital on postoperative day 14 in good condition.

### 3. Comment

Well-known major complications of aortic cannulation during cardiac surgery are thromboembolic events and aortic dissection.

Disruption of an atherosclerotic ulcer during cardiopulmonary bypass may happen extremely rare. Lack of publications on this topic could be explained by the mostly fatal outcome of these patients. Only few cases of an aortic rupture in combination with coronary artery bypass grafting have been reported so far [2,3], hereby in association with a dissection beginning in the aortic site of the vein anastomosis.

Our 70-year-old patient presented with an atherosclerotic lesion in the concavity of the aortic arch, not uncommon in his age group.

We used the long aortic cannula with tip placed in the proximal descending aorta to avoid flush of aortic debris into the supraaortic branches [4]. Although care was taken during insertion of the long aortic cannula, we believe that initial plaque disruption started at this point. When problems occur in placing an aortic cannula, we routinely introduce a transoesophageal echocardiography probe to exclude aortic dissection and to confirm the correct position of the aortic cannula. When aortic rupture is present, survival is only possible even in the elderly patient by radical operation with total aortic arch replacement in deep hypothermic arrest. This unusual case report shows that total arch replacement in combination with coronary artery bypass grafting is feasible and necessary when seldom intraoperative complications appear during elective cardiac surgery.

### References

- [1] Borst HG, Walterbusch G, Schaps D. Extensive aortic replacement using 'elephant trunk' prosthesis. *Thorac Cardiovasc Surg* 1983;31(1):37–40.
- [2] Chawla SK, Brown L. Successful repair of aortic rupture following coronary artery bypass grafting. *Conn Med* 1982;46(1):1–3.
- [3] Kimbiris D, Dreifus LS, Adam A, Blanco G, Linhart JW. Dissection and rupture of the ascending aorta. Unusual complications of aortocoronary bypass surgery. *Chest* 1975;68(3):313–316.
- [4] Grossi EA, Kanchuger MS, Schwartz DS, McLoughlin DE, LeBoutillier 3rd M, Ribakove GH, Marschall KE, Galloway AC, Colvin SB. Effect of cannula length on aortic arch flow: protection of the atherosclerotic aortic arch. *Ann Thorac Surg* 1995;59(3):710–712.