Original Paper

Cerebrovascular Diseases

Cerebrovasc Dis 2012;34:343–350
DOI: 10.1159/000343227

Received: June 25, 2012
Accepted: September 4, 2012
Published online: November 14, 2012

Plaque Characteristics of Asymptomatic Carotid Stenosis and Risk of Stroke

Marie-Luise Mono[a] Alexander Karameshev[d] Johannes Slotboom[b] Luca Remonda[c] Aekaterini Galimanis[a] Simon Jung[a] Oliver Findling[a] Gian Marco De Marchis[a] Rudolf Luedi[a] Claus Kiefer[b] Carole Stuker[b] Heinrich P. Mattle[a] Gerhard Schroth[b] Marcel Arnold[a] Krassen Nedeltchev[a] Marwan El-Koussy[b]

Departments of [a]Neurology and [b]Diagnostic and Interventional Neuroradiology, Inselspital, University of Bern, Bern, and [c]Department of Neuroradiology, Kantonsspital Aarau, Aarau, Switzerland; [d]Department of Neurology, Medical University of Sofia, Sofia, Bulgaria

Key Words

Asymptomatic carotid stenosis · Plaque components · Vulnerable plaque · Predictive factors · Future cerebrovascular events

Abstract

Background: The optimal treatment of asymptomatic carotid stenosis (ACS) is controversial. To optimize the risk-benefit ratio of carotid artery revascularization, it is crucial to identify ACS patients who are at increased stroke risk. Recent data suggest that plaque vulnerability depends on its composition. Therefore, we assessed plaque composition in ACS to determine predictors for ipsilateral cerebrovascular events. ***Methods:*** 62 patients with 65 ACS ≥50% underwent 3-T MRI of the carotid bifurcation (TOF, special dark-blood weighted noncontrast and contrast-enhanced T_1 and T_2 images) and of the brain. The different plaque components (lipid core, intraplaque hemorrhage, calcification and the status of the fibrous cap) were assessed. Furthermore, the plaque volume and the volume of clinically silent cortical and subcortical infarcts in the territory of the stenosed carotid artery as seen on FLAIR images were determined by using a semi-automated software. Carotid stenosis was considered asymptomatic if there had not been any clinically apparent ischemic events in the corresponding vascular territory within the previous 6 months. During follow-up, information on the occurrence of cerebrovascular events, medical treatment and sonographic changes of the stenosis was collected. ***Results:*** At baseline, 24 ACS (37%) were classified as high grade. A lipid-rich necrotic core was the dominant plaque component in 16 ACS (25%). The plaque volume was higher in ACS with a lipid-rich necrotic core as dominant plaque component (p = 0.002) and in patients with prior stroke/TIA (p = 0.010). After a median follow-up of 18.9 months (interquartile range 3.5–30.1) there were 2 ipsilateral strokes and 3 ipsilateral TIAs. The average annual event rate was 7.7%. A lipid-rich necrotic core (HR 7.21; 95% CI 1.12–46.28; p = 0.037), sonographic progression of the stenosis (HR 7.00; 95% CI 1.13–41.34; p = 0.036), history of stroke (HR 11.03; 95% CI 1.23–99.36; p = 0.032), and the volume of clinically asymptomatic ischemic brain lesions (HR 1.14/cm^3; 95% CI 1.03–1.25; p = 0.008) predicted cerebrovascular events. Patients on statin therapy at follow-up were at lower risk of events (HR 0.17; 95% CI 0.03–1.00; p = 0.05). ***Conclusions:*** In addition to medical history and sonographic

M.-L.M., A.K., K.N. and M.El-K. contributed equally to this work.

KARGER

Fax +41 61 306 12 34
E-Mail karger@karger.ch
www.karger.com

1015–9770/12/0346–0343$38.00/0

Accessible online at:
www.karger.com/ced

Gerhard Schroth, MD
Institute of Diagnostic and Interventional Neuroradiology, Inselspital
Freiburgstrasse 10
CH–3010 Bern (Switzerland)
E-Mail gerhard.schroth@insel.ch

findings, a lipid-rich necrotic core within the plaque turned out as a predictor of cerebrovascular events. Therefore, MR imaging of carotid plaques deserves further attention and might be helpful to improve risk stratification of asymptomatic carotid disease. The identified predictors could be combined in a risk model and tested in larger prospective studies.

Introduction

The optimal treatment of asymptomatic carotid stenosis (ACS) is controversial. Two large randomized trials have demonstrated a benefit from carotid end arterectomy (CEA) in patients with ACS. However, the absolute benefit was small, mostly because the risk of ipsilateral stroke did not exceed 2% per year in medically treated patients [1, 2]. More recent data suggest an even lower annual stroke risk around 1% with best medical treatment [3–5]. To optimize the risk-benefit ratio of carotid artery revascularization (CEA or carotid artery stenting, CAS), it appears crucial to identify ACS patients who are at increased stroke risk.

Recent data suggest that plaque composition influences plaque vulnerability [6, 7].

Plaques with a thin or disrupted fibrous cap, a large lipid-rich necrotic core, inflammatory infiltrates, neovasculature growth and intraplaque hemorrhage (IPH) are considered 'vulnerable' [8, 9]. Some of these plaque components (e.g. disrupted fibrous cap, intraplaque hemorrhages or large lipid core) can accurately be depicted by multisequence MRI [10, 11]. Furthermore, they have frequently been observed on MRI of symptomatic carotid plaques [12–15]. However, the predictive value of carotid plaque components in ACS has been assessed in only two prospective studies [16, 17].

In this study, we depicted the plaque composition in ACS ≥50% by 3-T MRI and followed the patients clinically and with ultrasound. The goal was to identify imaging predictors for ipsilateral cerebrovascular events.

Methods

Study Population

From December 2007 to August 2009, 68 patients with 71 ACS ≥50% as determined by carotid duplex ultrasound [18–20] gave their informed consent to undergo 3-T MRI of the carotid bifurcation and the brain. Carotid stenosis was considered asymptomatic if there were no clinically apparent ischemic events within the previous 6 months in the corresponding carotid territory. Six patients (9%) were excluded due to poor image quality. Sixty-two patients with 65 carotid stenoses ≥50% were included in the present analysis.

The medical treatment at baseline and the following risk factors were assessed: history of coronary artery disease, atrial fibrillation, stroke or transient ischemic attack (TIA) outside the territory of the ACS, stroke or TIA within the territory of the stenosed carotid artery if they had occurred more than 6 months ago, hypertension (treated hypertension or systolic blood pressure >140 mm Hg or diastolic blood pressure >90 mm Hg measured on two different occasions), diabetes mellitus (symptoms of diabetes plus random blood glucose concentrations >11 mmol/l or fasting glucose >7 mmol/l), current cigarette smoking, and hypercholesterolemia (treated or total venous plasma cholesterol concentration >5 mmol/l).

Carotid stenosis was categorized into high- (>70%) or moderate-grade (50–69%) stenosis according to widely used sonographic criteria [18–20]. The ethics committee of the canton of Bern approved the study protocol and all patients gave written informed consent to participate.

Imaging Protocol of the Carotid Bifurcation, Image Analysis and Volumetry of the Carotid Plaque

The carotid artery was imaged using a 3-T MRI system (Magnetom TrioTim syngo, VB15, Siemens, Erlangen, Germany) with a four-channel phased array surface coil (Machnet BV, Eelde, The Netherlands). A coronal sequence was used to localize the carotid bifurcation and its plaque distribution and was followed by an axial 3D multislab time of flight (TOF) angiography (TR/TE 22/3.86 ms, FOV read 200 mm, FOV phase 83.3%, slice thickness 0.65 mm, averages 1). This was followed by three pulse-triggered, double inversion recovery, turbo spin echo dark-blood sequences in order to avoid artifacts from the inflowing blood: (1) nonfat saturated T_1-weighted images (WI) (TR/TE 400/ 8.6 ms, 10 slices, slice thickness 3 mm, FOV read 150 mm, FOV phase 100%, averages 2); (2) fat-saturated sequence T_2WI (TR/TE 700/52.0 ms, 10 slices, slice thickness 3 mm, FOV read 150 mm, FOV phase 100%, averages 3), and (3) contrast-enhanced (CE) fat-saturated T_1WI after intravenous gadolinium (TR/TE 400/8.6 ms, 10 slices, slice thickness 3 mm, FOV read 150 mm, FOV phase 100%, averages 2). With a zero-filled Fourier transform applied to all sequences, a voxel size of 0.5 × 0.5 × 3.0 mm was achieved. All images were reviewed by 3 readers (M.-L.M., A.K., M.El-K.) in consensus in a randomized order. The readers were blinded to clinical details. The carotid bifurcation was used as a landmark for matching the 4 different sequences at each slice location. Plaque components were characterized according to previously published criteria based on relative tissue signal intensities in comparison to the adjacent sternocleidomastoid muscle [10, 11, 21–24]. Details of the criteria were as follows: calcifications were of hypointense signal intensity in all sequences; the signal intensity of the lipid-rich necrotic core with IPH depended on the age of the hemorrhage: IPH type I (fresh) was hyperintense in TOF and T_1WI and hypo-/isointense in T_2WI and CE-T_1WI, whereas IPH type II (recent) was hyperintense in all sequences (fig. 1a); the lipid-rich necrotic core without IPH was isointense in TOF, hyperintense in T_1WI, of variable intensity on T_2WI and hypointense in CE-T_1WI (fig. 1b). The dominant component of the plaque was determined by visual assessment. The status of the fibrous cap was dichotomized into two groups: the group with thick and intact caps and

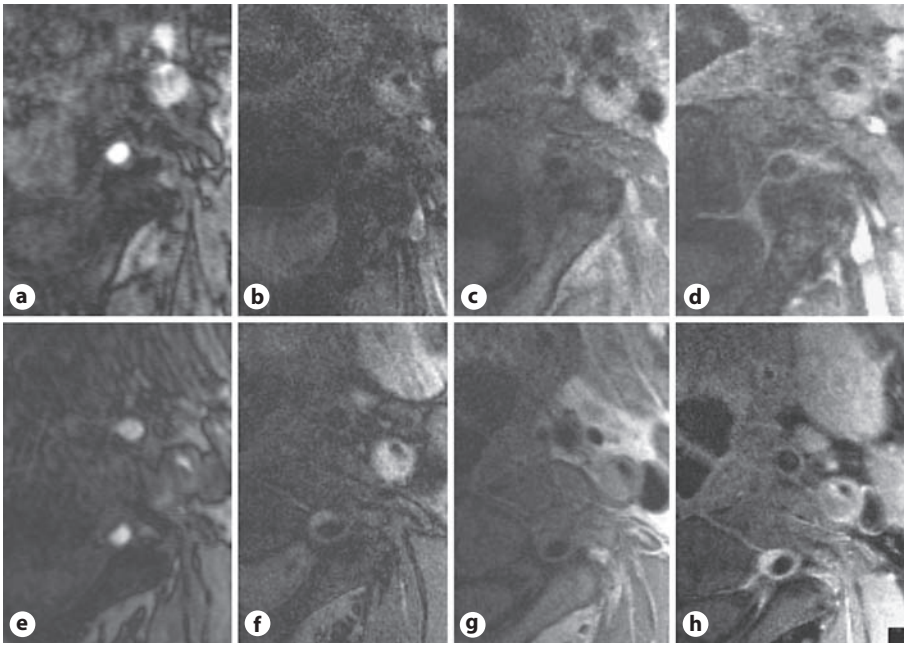

Fig. 1. MRI appearance of a lipid-rich necrotic core with (**a**) or without (**b**) intraplaque hemorrhage on TOF, T_2-weighted and pre- and postcontrast T_1-weighted images. The lipid-rich necrotic core with subacute intraplaque hemorrhage appears hyperintense in all sequences: TOF images (**a**); T_2-weighted images (**b**), T_1-weighted precontrast images (**c**); T_1-weighted postcontrast images (**d**). The lipid-rich necrotic core without hemorrhages appears isointense in TOF images (**e**), hyperintense in T_2-weighted images (**f**), hyperintense in T_1-weighted precontrast images (**g**) and hypointense in T_1-weighted postcontrast images (**h**).

the group with thin or disrupted caps. A thick fibrous cap was characterized by a uniform dark band adjacent to the lumen on TOF images that showed strong enhancement on CE-T_1WI and a smooth luminal surface on all images. In thin fibrous caps, the dark band adjacent to the lumen on TOF was missing and there was no enhancement adjacent to the lumen on CE-T_1WI, but a smooth luminal surface on all images. The fibrous cap was considered ruptured when the dark band adjacent to the lumen was missing or discontinuous on TOF images, the signal at the site of the presumed rupture was hyperintense on TOF images and the surface was irregular on the images of all sequences.

For the volumetric measurement of the carotid plaque, the sequence with the most detailed appearance of the plaque shape on visual assessment was used. The luminal and adventitial boundary of the vessel was detected and outlined using custom-designed software for image processing written in JAVA [25]. The software allowed quantification of the cross-sectional areas as well as the volumes of the imaged plaques. Each slice was assessed separately and any visualized plaque was measured with the software semi-automatically.

MRI Imaging Protocol of the Brain, Image Analysis and Volumetry of the Cerebral Ischemic Lesion Load

Diffusion-weighted echo planar images, fluid attenuated inversion recovery (FLAIR) and T_2-weighted turbo spin echo images and TOF MR angiograms of the intracranial arteries were obtained. Using the same software and principle as for the volumetry of the carotid plaque, the volume of cortical/subcortical infarcts in the territory of the corresponding carotid stenosis was quantified on FLAIR images. Cortical infarcts were defined as focal atrophy of the cortex and the underlying white matter with signal intensity similar to cerebrospinal fluid surrounded by a hyperintense rim. Subcortical infarcts were defined as hypointense lesion with signal intensity of cerebrospinal fluid with or without a hyperintense rim [26]. The reviewer was blinded to the patient's history.

Follow-Up

Follow-up information was complete for 60 patients (97%). Only 2 patients (3%) who moved abroad were lost. Forty-nine patients (79%) were routinely followed-up at our neurovascular ultrasound unit every 6 months with clinical and ultrasound examination and were surveyed on the occurrence of cerebrovascular events and the current medical treatment. Ultrasound progression of the carotid stenosis was defined as an increase of the degree of the stenosis from moderate to high grade. To gather information on occurrence of cerebrovascular events and the current medical treatment in the 11 patients without ultrasound follow-up examination, a structured telephone interview was used.

According to a scientific statement of the American Heart Association and American Stroke Association stroke council, a TIA was defined as a transient episode of focal neurologic dysfunction without evidence of acute infarction on brain imaging. Ischemic stroke was defined as a focal neurological deficit with evidence of acute infarction on CT or MRI [27]. If a cerebrovascular event was suspected, all available medical records related to the event were collected.

During follow-up, 21 patients (34%) underwent carotid intervention (CEA in 28% and CAS in 6%). Patients who underwent carotid intervention were more likely to have a high-grade stenosis at baseline ($p = 0.008$) or to show a progression of the carotid stenosis during follow-up ($p = 0.031$). These patients were included in our analysis for the time they were treated medically.

Statistical Analysis

Continuous variables were expressed as mean $\pm$ 1 SD or median/interquartile ranges depending on the skew of the distribution. The χ^2 test for contingency tables was used to compare

nominal variables and the Mann-Whitney test to compare continuous variables. Statistical significance was assumed at $p < 0.05$. Actuarial analysis of freedom from cerebrovascular events was calculated according to the Kaplan-Meier method. Average annual event rates were determined by using the formula $1-(1-P)^{1/n}$, where P equals the cumulative event rate at n years of follow-up. The log-rank test was used for univariate analyses of independent risk factors for the occurrence of cerebrovascular events. Meaningful multivariate analyses could not be performed because of the limited number of cerebrovascular events during follow-up.

Results

Demographic and Baseline Characteristics

Demographic and baseline characteristics of 62 patients with 65 asymptomatic ≥50% carotid stenoses are summarized in tables 1 and 2. Twenty patients (32%) had experienced a prior stroke outside the territory of the ACS or within its territory more than 6 months ago. At baseline, 58 patients (94%) were taking antithrombotics and 48 patients (77%) statins. Twenty-four ACS (37%) were classified as high grade. The fibrous cap was thin or disrupted in 42 ACS (65%). A lipid-rich necrotic core was the dominant plaque component in 16 ACS (25%). The plaque volume was higher in ACS with a lipid-rich necrotic core as dominant plaque component ($p = 0.002$) and in patients with prior stroke/TIA ($p = 0.010$). Neither the degree of the ACS nor other baseline characteristics were associated with the volume of the carotid plaque or the volume of cortical/subcortical ischemic lesions on FLAIR images in the ACS territory.

Follow-Up

Median time of follow-up was 18.9 months (interquartile range 3.53–30.10). At the end of follow-up, all patients were on antithrombotic treatment and 51 patients (82%) on statins. A follow-up sonographic examination of the ACS was performed in 49 patients (79%). The carotid stenosis was unchanged in 43 patients (66%), showed regression in 1 (2%) and progression in 7 (11%). Carotid plaques with a lipid-rich necrotic core as dominant plaque component showed more frequently a progressive stenosis compared to plaques without a lipid-rich necrotic core ($p = 0.033$). Neither the presence of IPH within the lipid-rich necrotic core nor the state of the fibrous cap were significantly associated with ipsilateral cerebrovascular events during follow-up. Patients without statins at follow-up were at higher risk for progression of their carotid disease ($p = 0.009$).

Table 1. Demographic and baseline clinical characteristics of 62 patients with 65 asymptomatic carotid stenoses of ≥50%

Characteristics	n (%)
Mean age ± SD, years	68.7 ± 8.6
Women	16 (26)
Vascular risk factors	
Arterial hypertension	52 (84)
Smoking	10 (16)
Diabetes mellitus	15 (24)
Hypercholesterolemia	54 (87)
Coronary artery disease	16 (26)
Atrial fibrillation	4 (7)
Current medical treatment	
Antithrombotic treatment	58 (94)
Antihypertensive treatment	52 (84)
Statin therapy	48 (77)
Prior stroke/TIA	20 (32)
Contralateral stenosis/occlusion	
50–70%	2 (3)
>70%	1 (2)
Occlusion	7 (11)

Table 2. Baseline characteristics of 65 asymptomatic carotid stenoses of ≥50%

Characteristics	
High-grade carotid stenosis (≥ 70%), n (%)	24 (37)
Lipid-rich necrotic core as dominant plaque component, n (%)	16 (25)
Lipid-rich necrotic core without intraplaque hemorrhage	7 (11)
Lipid-rich necrotic core with intraplaque hemorrhage	9 (14)
Thick fibrous cap, n (%)	23 (35)
Thin or disrupted fibrous cap, n (%)	42 (65)
Plaque volume, cm^3	
Median (interquartile range)	0.39 (0.23-0.56)
Volume of cortical/subcortical ischemic lesions on FLAIR images, cm^3	
Median (interquartile range)	0.23 (0.05-0.72)

Cerebrovascular Events during Follow-Up

Five cerebrovascular events (3 TIAs and 2 strokes) occurred during a median follow-up of 18.9 months, all of them ipsilaterally to the carotid artery stenosis. The average annual rate of stroke and TIA was 7.7% and that of stroke 2.6%. Among all baseline characteristics listed in tables 1 and 2, a lipid-rich necrotic core as dominant plaque component (HR 7.21; 95% CI 1.12–46.28; p =

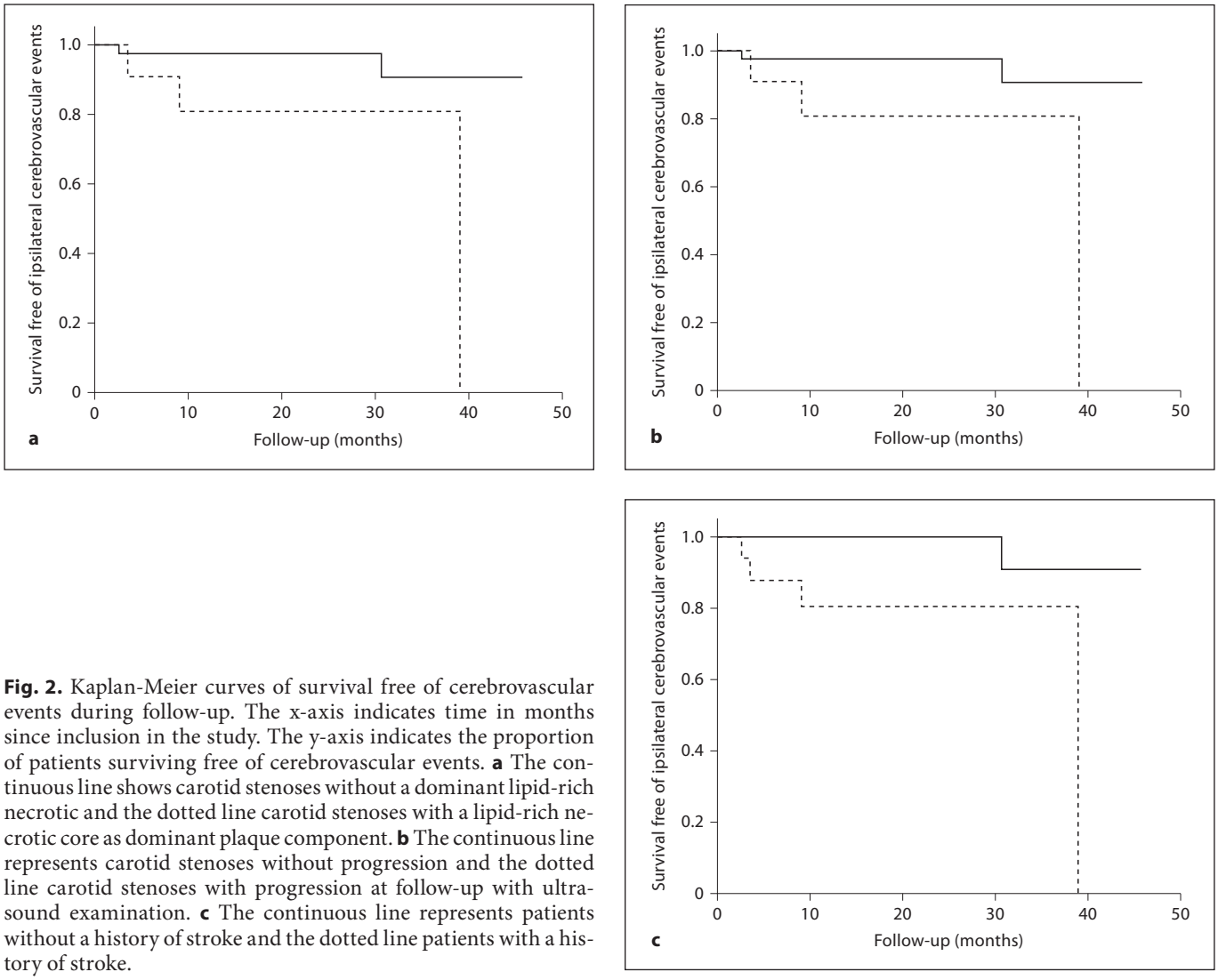

Fig. 2. Kaplan-Meier curves of survival free of cerebrovascular events during follow-up. The x-axis indicates time in months since inclusion in the study. The y-axis indicates the proportion of patients surviving free of cerebrovascular events. **a** The continuous line shows carotid stenoses without a dominant lipid-rich necrotic and the dotted line carotid stenoses with a lipid-rich necrotic core as dominant plaque component. **b** The continuous line represents carotid stenoses without progression and the dotted line carotid stenoses with progression at follow-up with ultrasound examination. **c** The continuous line represents patients without a history of stroke and the dotted line patients with a history of stroke.

0.037), the progression of the carotid stenosis (HR 7.00; 95% CI 1.13–41.34; p = 0.036), history of stroke (HR 11.03; 95% CI 1.23–99.36; p = 0.032) and the volume of cortical/subcortical ischemic lesions (HR 1.14/cm^3; 95% CI 1.03–1.25; p = 0.008) on FLAIR images were risk factors for ipsilateral cerebrovascular events during follow-up (table 3; fig. 2). Patients on statins at follow-up were at lower risk of clinical events (HR 0.17; 95% CI 0.03–1.00; p = 0.05).

Discussion

The main findings of our study are that medical history, baseline MR characteristics and sonographic follow-up have a predictive value for TIA and stroke in patients with ACS. A history of stroke, progression of stenosis as assessed by ultrasound, a large lipid-rich necrotic core within the plaque as dominant plaque component as seen on MRI, and the volume of clinically silent ischemic brain lesions in the territory of the ACS turned out to be predictors of TIA and stroke, while statins decreased this risk.

The degree of carotid stenosis is probably the most important predictor of stroke risk [28, 29]. However, in ACS the overall incidence of TIA and stroke is generally low and in clinical medicine it would be desirable to know additional factors in an individual patient to assess his risk more accurately. Accumulating evidence demonstrates that plaque composition determines its vulnerability and therefore also the risk for stroke. With the ad-

Table 3. Risk factors for ipsilateral cerebrovascular events during follow-up

Variable	HR	95% CI	p
Dominant lipid-rich necrotic core	7.20	1.12–46.28	0.037
Progression of carotid stenosis	7.00	1.13–43.38	0.036
Volume of cortical/subcortical ischemic lesions on FLAIR images per cm^3	1.14	1.03–1.25	0.008
Prior stroke/TIA	11.03	1.23–99.36	0.032
Statin therapy at follow-up	0.17	0.03–1.00	0.05

vent of high-resolution MRI of the carotid plaques a new promising diagnostic approach opens up [10, 11].

To date, only two MRI studies have assessed the plaque components and their predictive value for ipsilateral TIA and stroke in ACS. One study enrolled 98 male with 50–70% ACS. The presence of fresh or recent IPH within the plaque was associated with subsequent cerebrovascular events. Six of 36 patients with IPH suffered cerebrovascular events during follow-up of 24.9 months compared to none of 62 patients without IPH [16]. Another study reported on 154 subjects with 50–79% ACS. During a mean follow-up of 38.2 months 12 cerebrovascular events were observed. Subjects with MRI evidence of fresh or recent IPH, a thin or disrupted fibrous cap and a large lipid-rich necrotic core within the plaque were at increased risk for cerebrovascular events [17]. These findings are largely similar to the results of our series. Plaques with a lipid-rich necrotic core (lipid core with or without IPH) as dominant plaque component had a sevenfold increased TIA or stroke risk in our ACS patients. Both IPH and a lipid core are features of a so-called 'vulnerable plaque', and its relevance has been consistently demonstrated in symptomatic carotid stenosis [8, 9, 12, 14, 15]. In contrast to the results of Takaya et al. [17], a thin or disrupted fibrous cap was not associated with future cerebrovascular events in our study. As atherosclerosis is a dynamic process, changes of plaque composition over time may lead to regression from a vulnerable to a stable or progression from a stable to a vulnerable plaque [30–32]. This dynamism affects also, and perhaps in particular, the fibrous cap as an important marker of plaque vulnerability. However, MRI of the carotid plaque only offers a snapshot of the status of the fibrous cap at the time of investigation, which may explain the missing correlation of plaques with thin/disrupted fibrous cap and future cerebrovascular events in our study. Serial MRI examinations would be helpful to overcome this limitation and to improve prediction of cerebrovascular event in asymptomatic carotid stenosis.

The progression of the carotid stenosis as assessed by ultrasound at follow-up examinations was an additional strong predictor for ischemic events in our study. This was also the case in a prospective study of 1,065 patients with ACS: stenosis progression was associated with a twofold risk of ipsilateral stroke during a 3-year follow-up [33].

Among baseline clinical characteristics, a history of stroke was associated with an eleven-fold increased TIA and stroke risk. A history of stroke was found to increase this risk also in other studies, i.e. approximately 3-fold in two large registries [29, 34].

Furthermore, the volume of clinically silent ischemic brain lesions on FLAIR images also predicted the risk of clinically apparent events, albeit less strongly than other factors. In the Asymptomatic Carotid Stenosis and Risk of Stroke (ACSRS) study, the subgroup of patients with >60% ACS and CT scan evidence of silent infarction had a twofold increased risk of cerebrovascular events compared to patients with no silent infarcts on CT ($p = 0.032$) [35].

Statins at follow-up had a small but significant effect in preventing cerebrovascular events. In addition, patients without statins were more likely to show progression of their ACS. The beneficial effect of statins on size and composition of carotid plaques has been demonstrated in many previous studies [36]. Accordingly, the 10-year results of the ACST-1 trial showed that patients on statin therapy were at lower risk of stroke, independent of randomization to CEA or best medial treatment [4].

The annual stroke rate of 2.6% in our study was somewhat higher than the usually reported 1 to 2% in ACS. The high prevalence of cardiovascular risk factors might explain this slightly elevated rate, especially the high rate of history of stroke. It might also be a chance finding due to the relatively small sample size. Both, the small sample size and the high prevalence of cardiovascular risk factors in our study render comparisons with other studies dif-

ficult [1, 2, 5]. Furthermore, the sample size of our study was too small to allow a meaningful multivariate analysis. However, the results of the univariate analysis were highly significant for the presence of a lipid-rich necrotic core, history of stroke/TIA and progression of the carotid stenosis, so that a multivariate analysis would probably not have changed these results.

Conclusions

Clinical, sonographic and MR characteristics were identified as predictors of cerebrovascular events in our study. A lipid-rich necrotic core as dominant plaque component, history of stroke/TIA and progression of the carotid stenosis in sonographic follow-up examinations were strong predictors of cerebrovascular events in patients with ≥50% ACS. Determination of plaque components by 3-T MRI deserves further attention and might be helpful to improve risk stratification of asymptomatic carotid disease. The identified predictors could be combined in a risk model and tested in a larger prospective study. The identification of reliable predictors for clinically apparent cerebrovascular events would considerably improve the management of patients with ACS.

Acknowledgement

We thank Pietro Ballinari for statistical advice.

The study was funded by a grant of the Swiss Heart Foundation.

Dr. Marwan El Koussy is funded by the Swiss National Science Foundation, grant number SPUM 33CM30-124114 *Impact of qualitative MR perfusion imaging of patients with carotid artery disease.*

Disclosure Statement

None declared.

References

1 Executive Committee for the Asymptomatic Carotid Atherosclerosis Study: Endarterectomy for asymptomatic carotid artery stenosis. JAMA 1995;273:1421–1428.

2 Halliday A, Mansfield A, Marro J, Peto C, Peto R, Potter J, Thomas D: Prevention of disabling and fatal strokes by successful carotid endarterectomy in patients without recent neurological symptoms: randomised controlled trial. Lancet 2004;363:1491–1502.

3 Abbott AL: Medical (nonsurgical) intervention alone is now best for prevention of stroke associated with asymptomatic severe carotid stenosis: results of a systematic review and analysis. Stroke 2009;40:e573–e583.

4 Halliday A, Harrison M, Hayter E, Kong X, Mansfield A, Marro J, Pan H, Peto R, Potter J, Rahimi K, Rau A, Robertson S, Streifler J, Thomas D: 10-year stroke prevention after successful carotid endarterectomy for asymptomatic stenosis (ACST-1): a multicentre randomised trial. Lancet 2010;376:1074–1084.

5 Marquardt L, Geraghty OC, Mehta Z, Rothwell PM: Low risk of ipsilateral stroke in patients with asymptomatic carotid stenosis on best medical treatment: a prospective, population-based study. Stroke 2010;41:e11–e17.

6 Fisher M, Paganini-Hill A, Martin A, Cosgrove M, Toole JF, Barnett HJ, Norris J: Carotid plaque pathology: thrombosis, ulceration, and stroke pathogenesis. Stroke 2005;36:253–257.

7 Seeger JM, Barratt E, Lawson GA, Klingman N: The relationship between carotid plaque composition, plaque morphology, and neurologic symptoms. J Surg Res 1995;58:330–336.

8 Redgrave JN, Lovett JK, Rothwell PM: Histological features of symptomatic carotid plaques in relation to age and smoking: the Oxford Plaque study. Stroke 2010;41:2288–2294.

9 Spagnoli LG, Mauriello A, Sangiorgi G, Fratoni S, Bonanno E, Schwartz RS, Piepgras DG, Pistolese R, Ippoliti A, Holmes DR Jr: Extracranial thrombotically active carotid plaque as a risk factor for ischemic stroke. JAMA 2004;292:1845–1852.

10 Oppenheim C, Naggara O, Touze E, Lacour JC, Schmitt E, Bonneville F, Crozier S, Guegan-Massardier E, Gerardin E, Leclerc X, Neau JP, Sirol M, Toussaint JF, Mas JL, Meder JF: High-resolution MR imaging of the cervical arterial wall: What the radiologist needs to know. Radiographics 2009;29:1413–1431.

11 Saam T, Hatsukami TS, Takaya N, Chu B, Underhill H, Kerwin WS, Cai J, Ferguson MS, Yuan C: The vulnerable, or high-risk, atherosclerotic plaque: noninvasive MR imaging for characterization and assessment. Radiology 2007;244:64–77.

12 Demarco JK, Ota H, Underhill HR, Zhu DC, Reeves MJ, Potchen MJ, Majid A, Collar A, Talsma JA, Potru S, Oikawa M, Dong L, Zhao X, Yarnykh VL, Yuan C: MR carotid plaque imaging and contrast-enhanced MR angiography identifies lesions associated with recent ipsilateral thromboembolic symptoms: an in vivo study at 3T. AJNR Am J Neuroradiol 2010;31:1395–1402.

13 Gao T, Zhang Z, Yu W, Wang Y: Atherosclerotic carotid vulnerable plaque and subsequent stroke: a high-resolution MRI study. Cerebrovasc Dis 2009;27:345–352.

14 Saam T, Cai J, Ma L, Cai YQ, Ferguson MS, Polissar NL, Hatsukami TS, Yuan C: Comparison of symptomatic and asymptomatic atherosclerotic carotid plaque features with in vivo MR imaging. Radiology 2006;240:464–472.

15 Sadat U, Weerakkody RA, Bowden DJ, Young VE, Graves MJ, Li ZY, Tang TY, Gaunt ME, Hayes PD, Gillard JH: Utility of high resolution MR imaging to assess carotid plaque morphology: a comparison of acute symptomatic, recently symptomatic and asymptomatic patients with carotid artery disease. Atherosclerosis 2009;207:434–439.

16 Singh N, Moody AR, Gladstone DJ, Leung G, Ravikumar R, Zhan J, Maggisano R: Moderate carotid artery stenosis: MR imaging-depicted intraplaque hemorrhage predicts risk of cerebrovascular ischemic events in asymptomatic men. Radiology 2009;252:502–508.

17 Takaya N, Yuan C, Chu B, Saam T, Underhill H, Cai J, Tran N, Polissar NL, Isaac C, Ferguson MS, Garden GA, Cramer SC, Maravilla KR, Hashimoto B, Hatsukami TS: Association between carotid plaque characteristics and subsequent ischemic cerebrovascular events: a prospective assessment with mri-initial results. Stroke 2006;37:818–823.
18 Alexandrov AV, Bladin CF, Maggisano R, Norris JW: Measuring carotid stenosis. Time for a reappraisal. Stroke 1993;24:1292–1296.
19 Schulte-Altedorneburg G, Clevert DA: Color duplex sonography of extracranial brain-supplying arteries. Radiologe 2009;49:1016–1023.
20 Staikov IN, Nedeltchev K, Arnold M, Remonda L, Schroth G, Sturzenegger M, Herrmann C, Rivoir A, Mattle HP: Duplex sonographic criteria for measuring carotid stenoses. J Clin Ultrasound 2002;30:275–281.
21 Cai J, Hatsukami TS, Ferguson MS, Kerwin WS, Saam T, Chu B, Takaya N, Polissar NL, Yuan C: In vivo quantitative measurement of intact fibrous cap and lipid-rich necrotic core size in atherosclerotic carotid plaque: comparison of high-resolution, contrast-enhanced magnetic resonance imaging and histology. Circulation 2005;112:3437–3444.
22 Cai JM, Hatsukami TS, Ferguson MS, Small R, Polissar NL, Yuan C: Classification of human carotid atherosclerotic lesions with in vivo multicontrast magnetic resonance imaging. Circulation 2002;106:1368–1373.
23 Chu B, Kampschulte A, Ferguson MS, Kerwin WS, Yarnykh VL, O'Brien KD, Polissar NL, Hatsukami TS, Yuan C: Hemorrhage in the atherosclerotic carotid plaque: a high-resolution MRI study. Stroke 2004;35:1079–1084.
24 Mitsumori LM, Hatsukami TS, Ferguson MS, Kerwin WS, Cai J, Yuan C: In vivo accuracy of multisequence MR imaging for identifying unstable fibrous caps in advanced human carotid plaques. J Magn Reson Imaging 2003;17:410–420.
25 Slotboom J, Schaer R, Ozdoba C, Reinert M, Vajtai I, El-Koussy M, Kiefer C, Zbinden M, Schroth G, Wiest R: A novel method for analyzing DSCE-images with an application to tumor grading. Invest Radiol 2008;43:843–853.
26 Ouhlous M, Flach HZ, de Weert TT, Hendriks JM, van Sambeek MR, Dippel DW, Pattynama PM, van der Lugt A: Carotid plaque composition and cerebral infarction: Mr imaging study. AJNR Am J Neuroradiol 2005;26:1044–1049.
27 Easton JD, Saver JL, Albers GW, Alberts MJ, Chaturvedi S, Feldmann E, Hatsukami TS, Higashida RT, Johnston SC, Kidwell CS, Lutsep HL, Miller E, Sacco RL: Definition and evaluation of transient ischemic attack: a scientific statement for healthcare professionals from the American heart association/American stroke association stroke council; council on cardiovascular surgery and anesthesia; council on cardiovascular radiology and intervention; council on cardiovascular nursing; and the interdisciplinary council on peripheral vascular disease. The American Academy of Neurology affirms the value of this statement as an educational tool for neurologists. Stroke 2009;40:2276–2293.
28 North American Symptomatic Carotid Endarterectomy Trial collaborators: Beneficial effect of carotid endarterectomy in symptomatic patients with high-grade carotid stenosis. N Engl J Med 1991;325:445–453.
29 Nicolaides AN, Kakkos SK, Kyriacou E, Griffin M, Sabetai M, Thomas DJ, Tegos T, Geroulakos G, Labropoulos N, Dore CJ, Morris TP, Naylor R, Abbott AL: Asymptomatic internal carotid artery stenosis and cerebrovascular risk stratification. J Vasc Surg 2010;52:1486–1496, e1481–e1485.
30 Peeters W, Hellings WE, de Kleijn DP, de Vries JP, Moll FL, Vink A, Pasterkamp G: Carotid atherosclerotic plaques stabilize after stroke: insights into the natural process of atherosclerotic plaque stabilization. Arterioscler Thromb Vasc Biol 2009;29:128–133.
31 Ross R: Atherosclerosis – an inflammatory disease. N Engl J Med 1999;340:115–126.
32 Stary HC: Natural history and histological classification of atherosclerotic lesions: an update. Arterioscler Thromb Vasc Biol 2000;20:1177–1178.
33 Sabeti S, Schlager O, Exner M, Mlekusch W, Amighi J, Dick P, Maurer G, Huber K, Koppensteiner R, Wagner O, Minar E, Schillinger M: Progression of carotid stenosis detected by duplex ultrasonography predicts adverse outcomes in cardiovascular high-risk patients. Stroke 2007;38:2887–2894.
34 Aichner FT, Topakian R, Alberts MJ, Bhatt DL, Haring HP, Hill MD, Montalescot G, Goto S, Touze E, Mas JL, Steg PG, Rother J: High cardiovascular event rates in patients with asymptomatic carotid stenosis. The Reach Registry. Eur J Neurol 2009;16:902–908.
35 Kakkos SK, Sabetai M, Tegos T, Stevens J, Thomas D, Griffin M, Geroulakos G, Nicolaides AN: Silent embolic infarcts on computed tomography brain scans and risk of ipsilateral hemispheric events in patients with asymptomatic internal carotid artery stenosis. J Vasc Surg 2009;49:902–909.
36 Makris GC, Lavida A, Nicolaides AN, Geroulakos G: The effect of statins on carotid plaque morphology: an LDL-associated action or one more pleiotropic effect of statins? Atherosclerosis 2010;213:8–20.