

A clinical comparison of the rate of maxillary canine retraction into healed and recent extraction sites—a pilot study

Rudolf Häsler, George Schmid, Bengt Ingervall and Urs Gebauer

Department of Orthodontics, University of Bern, Switzerland

SUMMARY The rate of movement of the maxillary canines into the healed or recent extraction alveolus of the first premolar was measured in 22 patients aged 10–27 years. On one side of the dental arch, the first premolar was extracted. After a median time of 86 days, the contralateral first premolar was extracted and the distalization of both canines started using Gjessing canine retraction springs. The experiment was ended when one of the two canines had been sufficiently distalized. Recordings of the positions of the canines at the beginning of the study, at the start of the distalization and at the end were made from dental casts and standardized intraoral radiographs.

The canine on the recent extraction side moved faster than that on the healed side, but also tipped somewhat more. The reasons for the increased tipping and the faster movement are discussed.

Introduction

Retraction of the maxillary canines after first premolar extractions is a very common orthodontic task in cases of crowding or for the correction of a large overjet. Spontaneous movement of the canine into the extraction site is the basis of the so-called serial extraction described by Hotz (1947), Kjellgren (1947), Dewel (1959), and Berg and Gebauer (1982). In most cases, however, the canine is retracted actively with a removable or a fixed appliance. The technique and efficiency of tooth movement with sliding mechanics have been studied by Drescher *et al.* (1989, 1990, 1991), Schumacher *et al.* (1990) and Kucher *et al.* (1993), among others. The segmented arch approach for canine retraction has attracted much interest since the advantage of this approach was pointed out by Burstone (1962). Various designs of canine retraction springs have been described and their suitability and efficacy tested (Burstone and Koenig, 1976; Burstone, 1982; Gjessing, 1985; Ziegler and Ingervall, 1989; Bourauel *et al.*, 1994; Eden and Waters, 1994).

These studies have contributed to a better understanding of the biomechanics of canine

retraction. Much is, however, unknown regarding the biological factors influencing the procedure. One such factor is the variation in the structure of the bone into which the canine is moved. In the case of tooth extraction, the character of this bone can, to some extent, be influenced by the orthodontist. The tooth can be moved into an extraction site where healing has been allowed to take place or the tooth movement can start immediately after extraction and proceed into the new or forming bone of the extraction alveolus. Bauer (1969) and Murphey (1970) reported from animal experiments that tooth movement was faster into a healed than into a recent extraction site. However, no clinical report comparing tooth movement into a healed and a recent extraction site has been found. The aim of the present investigation was to compare in humans the rate of maxillary canine retraction into an extraction site where healing had taken place with that of a recent extraction site.

Subjects and methods

Twenty-two subjects aged 10 years, 2 months to 26 years, 6 months (median age 13 years, 7

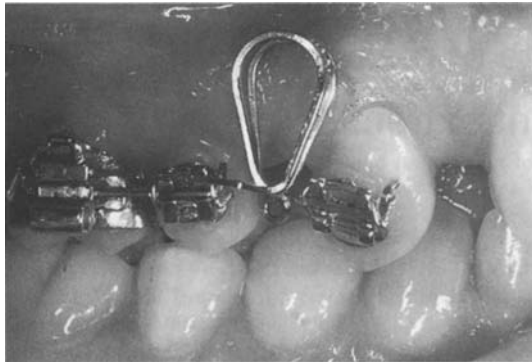


Figure 1 The Gjessing canine retraction spring as used in the present investigation.

months) were included in the study. Only one subject was older than 16 years. The subjects were treated at the Orthodontic Clinic, University of Bern, for maxillary crowding and/or an enlarged overjet. Their treatment plan included extraction of the maxillary first premolars and distalization of the maxillary canines. Subsequently, the maxillary incisors were to be aligned, and where indicated an enlarged overjet corrected.

For comparison of the position of the canine with regard to rotation, dental casts of a sample of individuals with ideal occlusion (see Dahlquist *et al.*, 1996) were used. This series comprised 15 boys and 19 girls, aged 12–18 years (median 14 years).

Treatment procedure

By random determination, the maxillary first premolar on one side of the dental arch was extracted (in 11 patients on the right side and in 11 patients on the left side). Impressions for dental casts and an intraoral radiograph were made on the day of extraction or up to 23 days thereafter (median 8 days); time T1.

The contralateral first maxillary premolar was extracted 52–151 days (median 86 days) after the extraction on the other side. Impressions for dental casts and radiographs were made 0–21 days (median 7 days) after the second extraction; time T2.

At T1, both maxillary first molars were banded and a Goshgarian transpalatal arch (GAC, Central Islip, NY, USA) was placed in order to stabilize the molars.

At T2, brackets (Unitek, Monrovia, CA, USA) were bonded to the maxillary canines and second premolars. The second premolars and the first molars were connected with a passive stainless steel segmented arch wire of dimension 0.019×0.025 inches. At the same time, the patient was given a high-pull headgear (Forestadent, Pforzheim, Germany) and instructed to wear it at least 12 hours per day and night. The force applied was 300–400 g per side. Also at time T2, distalization of both maxillary canines was started with a Gjessing canine retraction spring (Gjessing, 1985) (Figure 1). The spring (Rocky Mountain Orthodontics, Denver, CO, USA) was activated as described by Gjessing (1994), delivering a force of approximately 100 g. Care was taken to achieve the same degree of activation on both sides of the dental arch, as far as possible. Contrary to common practice, the retraction spring was inserted in a 0.018×0.025 inch auxiliary tube on the molar band without engagement of the second premolar, the reason being that the premolar bracket was occupied by the segmented arch.

During the phase of canine retraction, the patients were seen every 4–5 weeks for checking and reactivation of the springs, when necessary.

Final recordings (time T3) were made when the canine on one side of the dental arch was sufficiently distalized, i.e. when the space between the canine and the second premolar was closed and/or the canine was in a Class I relationship and enough space was gained in the anterior segment of the dental arch. This occurred 56–266 days (median 131 days) after the start of the distalization. An overview of the time spans and recordings is given in Figure 2.

During maxillary therapy, treatment was also initiated in the mandible. In 17 patients two lower premolars were extracted and a multi-banded appliance inserted. In one case a mandibular incisor was extracted and four cases were treated without extraction of mandibular teeth. Intermaxillary forces were not used during the period covered by the investigation.

Recordings

Impressions for dental casts were made at times T1, T2 and T3. At time T1, an intraoral radiograph of the region of the extraction was

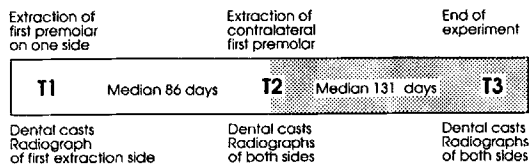


Figure 2 Overview of the time spans and recordings of the study.

taken. At times T2 and T3, radiographs of both sides of the dental arch were taken. In order to obtain as consistent projections as possible on the radiographs, custom-made acrylic bite blocks were used. The bite blocks included a holder for the 3×4 film (Kodak ultra-speed) and had impressions of the occlusal surfaces of the posterior teeth. The bite blocks were connected to the X-ray tube with the rigid arm of the Rinn system (Rinn Corp., Elgin, IL, USA). The same individual bite blocks were used throughout the investigation.

Analysis of records

The dental casts were used for the measurement of the displacement of the maxillary canines and first molars by the treatment. Measurements on the casts were made with the method of Gebauer (1977). With this method, x - and y -coordinates of reference points are read with a measuring microscope (magnification $\times 7$) connected to a computer which calculates the distances and angles of the displacement. The raphe line, defined by distinct points in the anterior and posterior parts of the palate, identical on the three casts, was used as the y -axis of the coordinate system. The x -axis was defined by the median end of a distinct posterior rugae (Figure 3). The origin was arbitrarily located 30 mm posterior of this ruga point. The mesial and the distal anatomical contact points of the canine as well as the mesial contact point of the first molar were used as reference points on the teeth (Figure 3). The changes in y -coordinate of the distal contact point of the canine and that of the mesial contact point of the molar were used to calculate the antero-posterior displacement of these teeth. The angle between a line connecting the mesial and distal contact points of the canine and the y -axis was calculated in order to evaluate

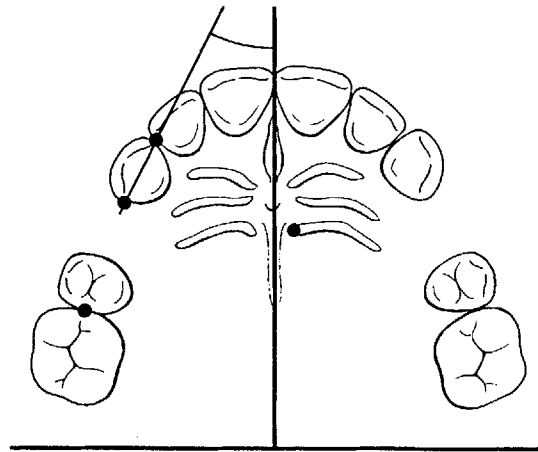


Figure 3 Coordinate system and reference points used in the measurement. The figure also shows the angle measured for the determination of the rotation of the canine.

the position of the canine with regard to rotation at the different times.

The radiographs were used for the measurement of antero-posterior tipping of the canine during retraction. The individual radiographs were enlarged five times with a projector (Focomat®, Leitz, Wetzlar, Germany). The outlines of all visible teeth, except unerupted third molars, the cemento-enamel junctions, the interproximal alveolar borders, the empty alveolus of the extracted first premolar as well as eye-catching osseous structures, particularly the inferior border of the maxillary sinus, were traced on paper. Teeth visible on the radiographs were the canine, the second premolar and the molars. The long axis of the canine was drawn on the tracings. The axis was defined individually depending on which structures were best reproduced on all three radiographs of a set. In most cases, the axis was drawn from the cemento-enamel junction (CEJ) on the distal outline of the tooth to a point close to the apex (always designated at the same distance from the CEJ, but unique for each canine). The tracings from the different times were superimposed to best fit and the difference in angle of the canine axis measured to the nearest half degree with a protractor.

The angle between the long axes of the canine and of the second premolar was also measured

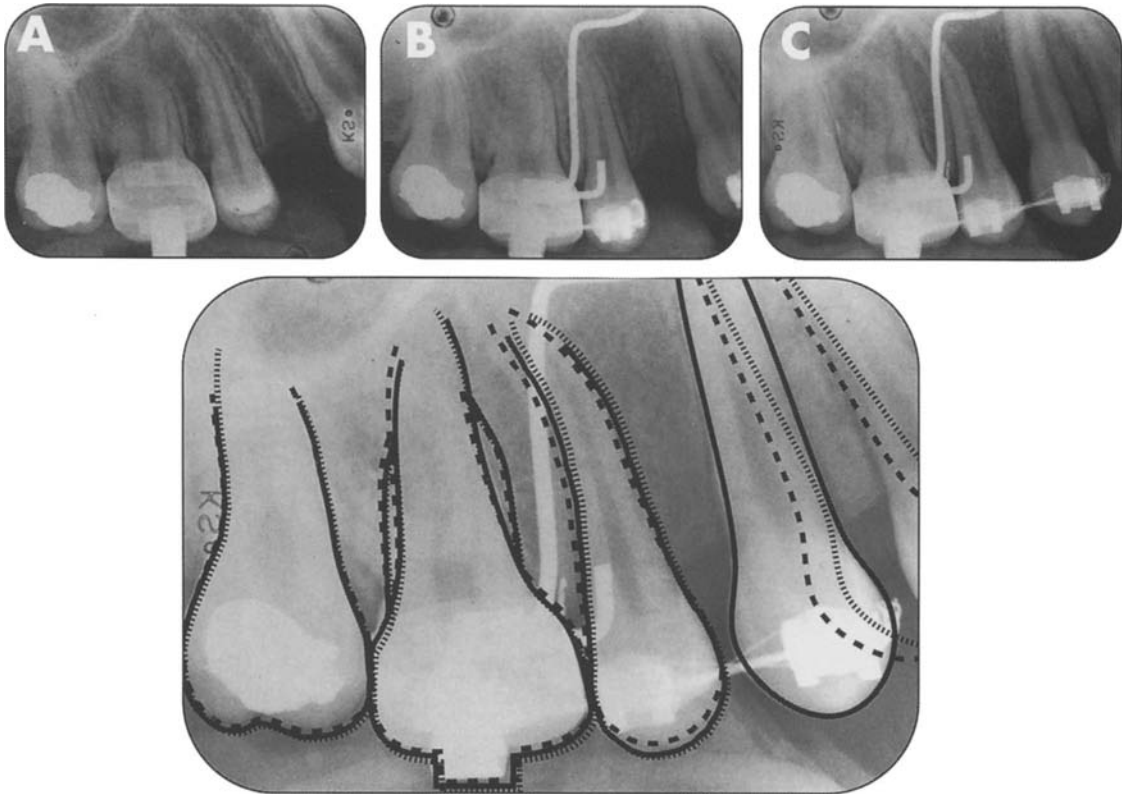


Figure 4 Radiographs of the healed side of one case at times T1 (A), T2 (B) and T3 (C). The figure also shows a tracing of the canine positions at the three times with the radiographs superimposed on the stable structures. In this case, the extraction alveolus was engaged to 3/4.

on the tracings. For this measurement, the long axes were determined from the mesio-distal centres of the pulp chambers. The angle was measured with a protractor to the nearest degree.

In addition, the type of distal movement of the canine in the interval T2–T3 was also determined from the superimposed tracings. The movement was classified as uncontrolled tipping (the apex moving mesially), controlled tipping (the apex remaining stationary) or parallel. The engagement of the extraction alveolus by the canine at the end of the treatment (time T3) was also judged on the tracings. This was done on the mesial contour of the alveolus starting from the alveolar crest and was recorded in quarters of the total alveolar length (Figure 4). If the canine had crossed the full length of the alveolus, this was recorded as 4/4. If a canine had tipped distally and crossed the mesial contour of only the upper

half of the alveolus, this was recorded as 2/4, for example. When necessary, the length of the alveolus was divided into sixths with subsequent recalculation into quarters.

The judgement of the type of movement and of engagement of the alveolus was undertaken independently by two examiners. When the recordings differed (in 7 of 44 cases for the type of movement and in 3 cases for alveolar engagement), the decision was made by a third examiner.

Errors of the method

The errors of the recording methods were evaluated from duplicate determinations of 15 randomly selected cases. The movements of the canine and the first molar on the healed and recent extraction side (selected at random) in these 15 cases during the period of observation

Table 1 Median and range of antero-posterior movements of the canine and the first molar and of change in axial inclination of the canine during the different phases of the study.

	Healed side		Recent extraction		Significance of difference
	Median	Range	Median	Range	
Change in <i>y</i> -coordinate of					
First molar					
T1-T2	-0.39	-1.86 - 1.27	-0.21	-1.37 - 2.01	NS
T2-T3	-1.48	-3.20 - 0.86	-1.43	-3.69 - -0.08	NS
T1-T3	-1.56	-3.70 - 0.41	-1.53	-3.69 - -0.07	NS
Canine					
T1-T2	1.07	-0.33 - 2.72	0.69	-0.94 - 2.16	*
T2-T3	2.85	0.80 - 4.67	4.24	1.65 - 5.87	***
T1-T3	3.92	1.53 - 6.09	4.60	3.07 - 7.43	**
Change in axial inclination of canine†					
T1-T2	3.75	0.00 - 19.00			
T2-T3	14.25	-3.00 - 21.25	15.75	-2.50 - 28.00	*
T1-T3	18.25	1.00 - 28.00			

†A minus sign means mesial tipping of the crown of the canine.
* $0.01 < P < 0.05$; ** $0.001 < P < 0.01$; *** $P < 0.001$.

(interval T1-T3) were measured a second time from new markings of the coordinate system and the reference points on the casts. The duplicate determinations were thus made on 15 pairs of casts. Systematic differences between the duplicate determinations were tested with Wilcoxon's matched-pairs, signed-ranks test. Accidental errors (*si*) between the duplicate determinations were calculated with the formula:

$$si = \sqrt{\frac{\sum d^2}{2n}}$$

where *d* is the difference between the two recordings.

The accidental error for the determination of the change in antero-posterior position (change of *y*-coordinate) of the molar was 0.56 mm and for the canine 0.64 mm. The accidental error for the determination of the angle between the mesio-distal axis of the canine and the *y*-axis (rotation) was 3.49 degrees. No significant systematic differences were found.

The change in axial inclination of the canine during distalization (time T2-T3) was measured on new tracings of 15 pairs of radiographs. The measurements differed only slightly (mean

difference 0.08 degree, $0.01 < P < 0.05$) between the first and the second determinations. The accidental error for the determination of the change in axial inclination was 1.3 degrees. The accidental error for the measurement of the angle between the canine and the second premolar was 1.1 degrees, with no significant systematic difference.

Statistical methods

Differences between the paired observations were tested with Wilcoxon's matched-pairs, signed-ranks test. Relationships between variables were evaluated by Spearman rank correlations.

Results

The antero-posterior movements of the canine and the first molar on the healed side (side of early premolar extraction) and on the recent extraction side (side of late premolar extraction) during the phases of observation (T1-T2) and distalization (T2-T3), as well as during the total period covered by the study (T1-T3), are given in Table 1.

On average, the first molar moved slightly mesially during the phases of observation

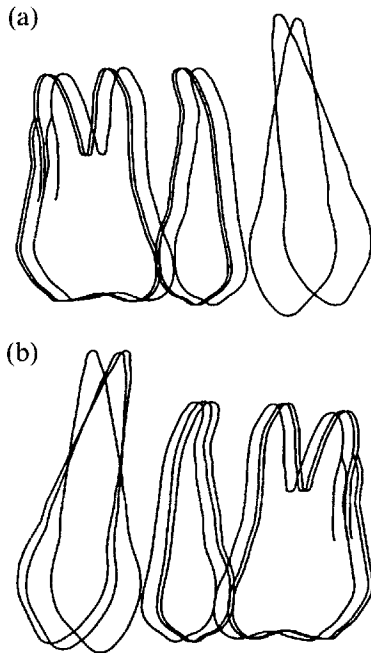


Figure 5 Composite tracings of the median positions of the teeth on the recent extraction side (a) at times T2 and T3 (canine) and T1, T2 and T3 (premolar and molar) and on the healed side (b) at times T1, T2 and T3. The tracings were constructed from the measurements made on the casts and radiographs.

(T1–T2) and during distalization of the canines (T2–T3). In addition, there was overall movement (T1–T3), but no significant difference between the healed and recent extraction sides (Table 1).

During the period of observation (T1–T2), the canine on the healed side on average moved more posteriorly than that on the side with no extraction. At T1, the canine on the healed side was inclined mesially with a median value of 14 degrees relative to the second premolar (angle between the long axes of the teeth). During the time span T1–T2, the canine on the healed side uprighted 4 degrees (median value) relative to the second premolar. The uprighting was not significantly correlated with the original inclination of the canine, nor was there any correlation between the distal movement of the canine in the time span T1–T2 as measured on the casts and the inclination of the canine at T1.

During the active retraction period (T2–T3), the canine on the recent extraction side was

distalized significantly more than that on the healed side (median difference 1.14 mm, range –0.22 to 2.84 mm). The faster movement of the canine on the recent extraction side during the distalization period (T2–T3) resulted in a larger total movement (T1–T3) of the canine on this side in spite of the fact that during the period of observation (T1–T2) the canine on the healed side, on average, moved more distally than the canine on the side where no extraction had been undertaken. The median difference between the two sides for the total time span (T1–T3) was 0.75 mm (range –1.18 to 2.67 mm). Tracings of the median movements of the teeth on the recent and healed extraction sides are shown in Figure 5.

During the period of distalization, the canine tipped distally significantly more on the recent extraction side than on the healed side (Table 1); median difference 4.88 degrees, range –9.75 to 19.50 degrees. There was, however, no significant difference between the two sides in the angle between the canine and the second premolar at time T3. The median angle was 2.5 degrees on the recent extraction side and 3.5 degrees on the healed side. The variation was considerable, with a range from –8 to 17 degrees on the recent extraction side and from –13 to 23 degrees on the healed side (a positive sign means divergence of the roots).

The type of tooth movement did not differ significantly between the two sides. Uncontrolled tipping occurred in 5 and 4 cases, controlled tipping in 9 and 9 cases, and parallel movement in 8 and 9 cases on the recent extraction and healed sides, respectively.

There was a small, significant difference ($0.01 < P < 0.05$) between the two sides in the engagement of the extraction alveolus at time T3. On the recent extraction side, the canine engaged somewhat more than the upper half of the alveolus (mean 2.5/4) and on the healed side the upper 3/4 (mean 2.9/4). Radiographs of a healed extraction site are shown in Figure 4.

The difference between the recent and healed extraction sides with regard to distalization and tipping of the canine as well as engagement of the extraction alveolus was not significantly correlated with the age of the subjects.

In five cases, the canines on both sides of the dental arch moved parallel during the distalization (time T2–T3). Nine of these canines engaged the extraction socket in its full length and one to 3/4. In all of these cases, the canine on the recent extraction side moved faster than that on the healed side. The difference was significant ($0.01 < P < 0.05$), with a mean of 3.7 mm on the recent extraction side and 1.8 mm on the healed side.

The rotation of the canine at the different times (T1, T2 and T3) was evaluated by comparing the positions of the canines relative to the ideal canine position, as recorded in the sample of ideal occlusion. In that group, the mesio-distal axis of the canine formed an angle of 32.2 degrees to the median raphe. The difference from the ideal value was calculated for the individual canines at times T1, T2 and T3. The median difference at time T1 was 7.3 and 4.9 degrees, at time T2 5.8 and 2.7 degrees, and at time T3 9.9 and 11.5 degrees on the healed and recent extraction sides, respectively. These values did not differ significantly between the healed and recent extraction sides.

Discussion

The stability of median rugae points as reference structures has been verified by van der Linden (1978), Ziegler and Ingervall (1989) and recently by Almeida *et al.* (1995). The stability is certainly sufficient over a short time span, as in the present study. The errors in the identification and recording of the reference points on the dental casts were small and of the same magnitude as in previous studies in which the method was used (Ziegler and Ingervall, 1989; Dahlquist *et al.*, 1996). The error for the recording of the inclination of the canine on the radiographs was also small.

In this study, the canine retraction spring of Gjessing was inserted in the second tube of the molar band and was not engaged in the bracket of the second premolar as prescribed by Gjessing (1985). The proper use of the retractor, i.e. engagement in the brackets of the canine, the second premolar and in the main tube of the molar band, may require the alignment of these

elements before the retractor can be placed. It was desirable to start the canine retraction into the fresh extraction site at time T2 without having to allow a period of varying duration for alignment. A passive stabilizing arch between the second premolar and the first molar could be fitted without problems in all cases, and the retractor inserted between the canine and the molar even in cases where the three teeth were not aligned. Because of the unorthodox way of using the Gjessing retractor, this study cannot be used as an indicator of the efficacy of this spring; nor was that the intention. Because of the long span between the canine and the molar tube, the effective anti-tipping and anti-rotation moments are much smaller than needed. The tipping per millimetre of distalization was therefore considerably greater than that found in a previous study of the retractor (Ziegler and Ingervall, 1989).

A higher rate of tooth movement into a recent compared with a healed extraction site was found. This is at variance with the roentgenological and histological observations in the animal experiments of Bauer (1969) and of Murphey (1970). However, the authors based their conclusions on the study of only five animals with a maximum observation time of 6 weeks. Furthermore, a heavy force (200 g) was used to distalize the mandibular second premolar of the monkeys. In the present study, as mentioned, the biomechanical system was not ideal because in most of the cases no parallel movement of the canines was achieved. Movement of the canines into the full length of the extraction alveolus was achieved for only 12 of the 44 canines. At least the upper half of the extraction alveolus was involved in the tissue reaction of the moving canine in 35 cases, however. Also, if a parallel canine movement had occurred in all cases, a pure test of the rate of tooth movement into healed or still incompletely calcified bone tissue would not have been possible, because the root of the canine is longer than that of the first premolar. Therefore, the character of the bone surrounding the apex of the canine would have been the same on both sides.

According to the data of Amler *et al.* (1960)

from humans, the healing of an extraction alveolus is a rapid process. They found that two-thirds of the alveolus (starting from the base of the socket) was filled with bone trabeculae by the 38th day after the extraction. The radiopacity of the alveolus increased progressively after the 38th day until a maximum was reached at approximately 100 days after the extraction. The radiopacity of the socket content was then almost identical to that of the surrounding alveolar process. This was confirmed here, where, as a rule, no or only minor signs of the previous extraction alveolus were discernible at times T2 and T3.

For practical reasons, the interval between times T1 and T2 differed between the subjects. It may, however, be assumed that the alveolus of the first extraction had healed when the contralateral premolar was extracted and the active distalization started. This must at least have been the case when the moving canine of the first extraction side reached the border of the alveolus. The variation between the individuals in the interval T2–T3 was determined by the rate of tooth movement and the varying need for distalization. In all cases, however, the duration of the active distalization was the same on the healed and recent extraction sides.

Although this study is not optimal with regard to the biomechanics of the force system and there are variations in observation times, often unavoidable in clinical studies, some conclusions seem to be justified. Thus, the rate of tooth movement seems to be higher when a tooth is moved into a recent extraction site compared with movement into an area where the extraction was performed well ahead. From a clinical point of view, a high rate of tooth movement is desirable but it may also imply hazards. The force system, calibrated in laboratory experiments, may then not function as intended. In the case of the Gjessing retractor, for example, the spring is constructed with a moment-to-force ratio of 10 with regard to distalization. This is based on the assumption that the centre of resistance of the tooth is located 10 mm below the bracket. If, however, the character of the bone is denser around the apex than in the marginal area, the centre of resistance of the tooth might be located

further apically. This, in turn, would require a higher moment-to-force ratio than the spring actually has. The insufficient moment-to-force ratio would result in more tipping of the tooth than intended. This is what might have happened in our experiment, where we found more tipping on the recent side than on the healed extraction side. On the other hand, the increased tipping on the side of recent extraction might simply be the effect of the increased movement on this side, because in most cases the movement was accompanied by tipping. In any case, caution is indicated with regard to activation when a tooth is moved into a fresh extraction site.

The reasons for the faster tooth movement on the recent extraction side can only be speculated upon because no histological examination was carried out. Possible reasons may be less calcified bone, which would resorb faster in the recent extraction alveolus, or the presence of more cells with a potential for bone resorption.

Address for correspondence

Professor Bengt Ingervall
Klinik für Kieferorthopädie
Freiburgstrasse 7
CH-3010 Bern
Switzerland

References

- Almeida M A, Philips C, Kula K, Tulloch C 1995 Stability of the palatal rugae as landmarks for analysis of dental casts. *Angle Orthodontist* 65: 43–48
- Amler M H, Johnson P L, Salman I 1960 Histological and histochemical investigation of human alveolar socket healing in undisturbed extraction wounds. *Journal of the American Dental Association* 61: 33–44
- Bauer Jr W J 1969 The rate of orthodontic retraction into extraction wounds undergoing various stages of healing: A radiographic study. MS Thesis, St Louis University, USA
- Berg R, Gebauer U 1982 Spontaneous changes in the mandibular arch following first premolar extractions. *European Journal of Orthodontics* 4: 93–98
- Bourauel C, Drescher D, Strasser J, Hoederath H 1994 Untersuchung der Kraftsysteme verschiedener Eckzahnretraktoren für die Segmentbogentechnik—Eine experimentelle Studie. *Kieferorthopädie* 8: 195–208
- Burstone C J 1962 The rationale of the segmented arch. *American Journal of Orthodontics* 48: 805–822
- Burstone C J 1982 The segmented arch approach to space closure. *American Journal of Orthodontics* 82: 361–378

- Burstone C J, Koenig H 1976 Optimizing anterior and canine retraction. *American Journal of Orthodontics* 70: 1-20
- Dahlquist A, Gebauer U, Ingervall B 1996 The effect of a transpalatal arch for the correction of first molar rotation. *European Journal of Orthodontics* 18: 257-267
- Dewel B F 1959 A critical analysis of serial extraction in orthodontic treatment. *American Journal of Orthodontics* 45: 424-455
- Drescher D, Bourauel Ch, Schumacher H A 1989 Frictional forces between bracket and arch wire. *American Journal of Orthodontics and Dentofacial Orthopedics* 96: 397-404
- Drescher D, Bourauel C, Schumacher H A 1990 Optimization of arch guided tooth movement by the use of uprighting springs. *European Journal of Orthodontics* 12: 346-353
- Drescher D, Bourauel Ch, Schumacher H A 1991 Optimierung der bogengeführten Zahnbewegung durch Powerhooks. *Praktische Kieferorthopädie* 5: 200-208
- Eden J D, Waters N E 1994 An investigation into the characteristics of the PG canine retraction spring. *American Journal of Orthodontics and Dentofacial Orthopedics* 105: 49-60
- Gebauer U 1977 Elektronische Mess- und Rechenanlage zur arcogrammetrischen Modelldiagnostik und zum Auswerten von Fernröntgenbildern. *Schweizerische Monatsschrift für Zahnheilkunde* 87: 1170-1180
- Gjessing P 1985 Biomechanical design and clinical evaluation of a new canine-retraction spring. *American Journal of Orthodontics* 87: 353-362
- Gjessing P 1994 A universal retraction spring. *Journal of Clinical Orthodontics* 18: 222-242
- Hotz R 1947 Active supervision of the teeth by extraction. *Transactions of the European Orthodontic Society* pp. 34-47
- Kjellgren B 1947 Serial extractions as a corrective procedure in dental orthopedic therapy. *Transactions of the European Orthodontic Society* pp. 134-160
- Kucher G, Weiland F J, Bantleon H P 1993 Modified lingual lever arm technique. *Journal of Clinical Orthodontics* 27: 18-22
- Murphey W H 1970 Oxytetracycline microfluorescent comparison of orthodontic retraction into recent and healed extraction sites. *American Journal of Orthodontics* 58: 215-239
- Schumacher H-A, Bourauel C, Drescher D 1990 Der Einfluss der Ligatur auf die Friktion zwischen Bracket und Bogen. *Fortschritte der Kieferorthopädie* 51: 106-116
- Van der Linden F P G M 1978 Changes in the position of posterior teeth in relation to ruga points. *American Journal of Orthodontics* 74: 142-161
- Ziegler P, Ingervall B 1989 A clinical study of maxillary canine retraction with a retraction spring and with sliding mechanics. *American Journal of Orthodontics and Dentofacial Orthopedics* 95: 99-106