

Minimally invasive video-endoscopic sympathectomy by use of a transaxillary single port approach

D. Lardinois^{a,*}, H.B. Ris^b

^aDivision of Thoracic Surgery, University Hospital, Inselspital, Bern, Switzerland

^bDepartment of Surgery, University Hospital, CHUV, Lausanne, Switzerland

Received 10 July 2001; received in revised form 9 September 2001; accepted 10 October 2001

Abstract

Objectives: This is a prospective study to evaluate the long-term outcome and the value of a transaxillary single port thoracic sympathectomy by use of a modified paediatric cystoresectoscope in a consecutive series of patients with facial blushing and/or hyperhidrosis. **Materials and methods:** All patients who underwent a thoracic transection of the sympathetic chain from T2 to T5 by use of a 7-mm single port approach and a modified urologic electroresectoscope between 1996 and 1998 were prospectively analysed regarding post-operative morbidity and outcome (clinical evaluation, visual analogue scale) in order to validate this technique. **Results:** 37 patients (18 men, 19 women) with an age ranging from 18 to 67 years (mean 34 years) underwent 74 bilateral video-assisted thoracic sympathectomies. The indications for sympathectomy included facial blushing in 32%, hyperhidrosis in 52%, or both in 16% of the patients. Ninety-five percent of the patients were discharged from the hospital on the next day, the 30-day mortality was zero, and there was no conversion to an open procedure. A severe complication with crossed emboli and motor aphasia was noted. A unilateral transient Horner's syndrome was observed in two patients. Three-month follow-up revealed an excellent cosmetic and functional result, with no residual pain. Complete relief of symptoms was observed in 89% and in 100% of the patients with facial blushing and palmar hyperhidrosis, respectively, after a follow-up of 34.5 months. Recurrence of the symptoms after initial regression was noted in 5.7% of the patients 3 years after surgery. Compensatory sweating of the lower extremities was significantly increased in patients with hyperhidrosis and facial blushing; however, sweating of the trunk was only increased in patients with hyperhidrosis. Improvement of quality of life was observed in 94.6% of the patients. **Conclusions:** Single port thoracoscopic sympathectomy by use of a modified paediatric cystoresectoscope and transection from T2 to T5 gives an excellent cosmetic and functional outcome, with better results in patients with hyperhidrosis. © 2002 Elsevier Science B.V. All rights reserved.

Keywords: Single port sympathectomy; Paediatric cystoresectoscope; Facial blushing; Hyperhidrosis; Long-term clinical outcome

1. Introduction

Primary hyperhidrosis of the upper limbs and facial blushing are distressing and often socially disabling conditions. Video-assisted thoracoscopic (VATS) sympathectomy has already been proved to be a simple, safe, reliable, and cost-effective therapy in patients with primary hyperhidrosis and/or facial blushing, offering long-term relief of symptoms [1,2]. This technique has replaced the open transthoracic approach, since it is associated with lesser sequelae. However, different approaches have been proposed and compared. The present study was performed to assess in a prospective manner the long-term outcome, the efficacy and

the value of simultaneous bilateral thoracic sympathectomy using a modified transurethral electroresectoscope inserted through a single 7 mm transaxillary thoracoport.

2. Materials and methods

All patients who underwent a bilateral thoracic VATS-sympathectomy for hyperhidrosis and facial blushing between 1996 and 1998 were prospectively enrolled in this study. All patients were referred with disabling hyperhidrosis or facial blushing which severely interfered with their work or social activities.

A chest X-ray was performed prior to surgery to exclude pleural symphysis suggesting the presence of adhesions. General anaesthesia and one lung ventilation with a double-lumen endotracheal tube was used. The patient's position on the operating table was a half-sitting position

* Corresponding author. Division of Thoracic Surgery, University Hospital of Zurich, CH 8090 Zurich, Switzerland. Tel.: +41-1-255-8802; fax: +41-1-255-8805.

E-mail address: didier.lardinois@chi.usz.ch (D. Lardinois).

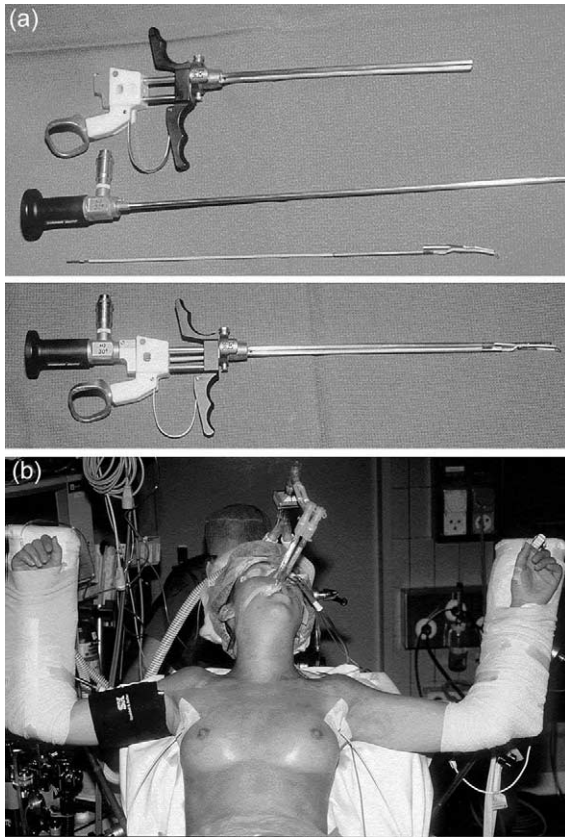


Fig. 1. (a) Identification and transsection of the sympathetic chain by use of a paediatric urologic cystoresectoscope. (b) Operation setting for VATS-sympathectomy allowing to perform a bilateral intervention by the same positioning of the patient and the screen.

with both arms abducted to 90°. After exclusion of the lung, a single, 1-cm long incision was performed in the axilla posterior to the pectoral muscle. A 7-mm trocar was inserted in the third intercostal space and a modified paediatric urologic 0° cysto-resectoscope was introduced (Fig. 1a). The dorsal sympathetic chain was identified running along the neck of the ribs close to the costovertebral junctions. The first rib was always identified either by direct vision or by palpation under visual control in some patients with adiposity. The sympathetic chain was divided over the ribs II–V. The sympathetic trunk was first coagulated with low current to avoid painful neuroma formation and then cut with diathermy. The interconnecting fibres (rami communicanti) were also coagulated and severed by cutting and dissecting the periosteum of the ribs over a distance of 3 cm, and vessels of the intercostal space were spared. The surgical procedure was completed by reinsufflation of the collapsed lung under direct vision, insertion of a 8 F thoracic catheter through the same operative incision, and closure of the wound only with one cutaneous suture. The entire procedure was then repeated on the opposite side without changing the position of the patient or the operation setting (Fig. 1b).

The operative time, hospital stay, complications, and recurrences were recorded. Outcome was assessed by a clin-

ical evaluation 3 months after surgery. The results were evaluated by questionnaire and symptoms assessed by a ten-grade visual analogue scale (VAS) from 0 (absence of symptom) to 10 (worst possible symptom). Statistical analysis was performed by use of a non-parametric test (Wilcoxon signed rank test). A *P* value less than 0.05 was considered as statistically significant.

3. Results

Thirty-seven consecutive patients including 18 men and 19 women with a mean age of 34 years (18–67 years), underwent 74 bilateral endoscopic thoracic sympathectomies between 1996 and 1998 at the University Hospital of Bern. Sixty-five percent of the patients had undergone medical therapy with topical agents, β -blocking drugs, or psychotherapy prior to operation without improvement of the symptoms.

The indications for sympathectomy consisted of facial blushing, hyperhidrosis, or both in 32, 52, and 16% of the patients, respectively. The average operation time of the bilateral procedure was 42 min, ranging from 35 to 60 min. After the intervention, the hands of all operated upper limbs were warm and dry. In one patient, the presence of apical pleural adhesions required the introduction of a second trocar but no conversion to an open procedure was required in any patient.

Pleural drainages were removed after a mean time of 6 h. Ninety-five percent (35/37) of the patients were discharged from the hospital the next day. Two patients required hospitalisation for 2 and 10 days, respectively, one due to a persistent right mantle pneumothorax and the other due to cerebral emboli (crossed emboli in patent foramen ovale).

Complications were observed in 5/37 (13%) of the patients, including intraoperative bleeding (2.6%), postoperative pneumothorax (2.6%), cerebral emboli (2.6%), and transient Horner's syndrome (5.2%). The bleeding was secondary to the injury of a paravertebral vein and required the insertion of a second port and the application of an endo-clip but no transfusion was required. The patient with the pneumothorax was discharged from the hospital on the second day after surgery with a right mantle pneumothorax. A chest X-ray control 2 days later showed no progression and the patient recovered without any drainage. In the two patients with unilateral Horner's syndrome, clinical signs were transient and disappeared 14 and 18 weeks after the operation, respectively. A severe complication was observed in a 49-year-old woman with facial blushing. She developed motor aphasia postoperatively, due to multiple pulmonary thromboembolism and cerebrovascular insult related to open foramen ovale (crossed embolism). Anticoagulation was initiated and the patient was transferred in a neurology rehabilitation centre. Six months later, sequelae of aphasia were still present.

Three months follow-up was performed in 36/37 (97.3%) and revealed an uneventful wound healing in all patients

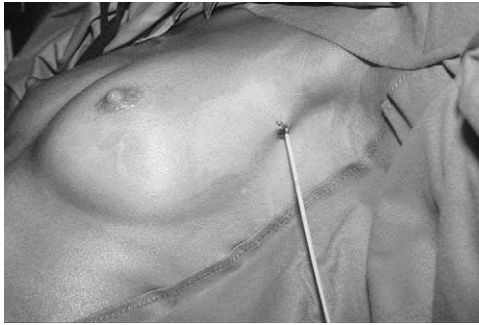

Fig. 2. Postoperative result after one port thoracic sympathectomy by use of a paediatric urologic cystoresectoscope.

with an excellent cosmetic result (Fig. 2). The shoulder girdle function was symmetrical in all patients and no residual pain syndrome was noted.

Answers to the questionnaire were obtained in 97.3% of the operated patients after a mean follow-up of 34.5 months after surgery. The mean follow-up in patients with facial blushing was 30 months (24–58 months) and in patients with hyperhidrosis 34.6 months (24–60 months).

Table 1 shows the impact of sympathectomy on clinical symptoms of the patients:

(a) In the 18 patients with *facial blushing*, all but two patients described sustained relief of symptoms after the operation. There was no influence of age, sex, or follow-up time ($P = 0.4$) on the degree of relief of symptoms. Compensatory sweating of the trunk and lower part of the body occurred in 8/18 (44%) and 12/18 (67%) of the patients, respectively. None of these patients considered these side effects as significant. Overall satisfaction was obtained in 17/18 (94.5%) but one patient with worsening of the symptoms was not satisfied with the results and regretted the operation. Improvement in the life style of the patients was noted in 17/18 (94.5%) of the patients after a mean follow-up of 30 months. In one patient with facial blushing (5.5%), after initial complete regression,

Table 1
Relief of symptoms by thoracic sympathectomy, assessed by a visual analogue scale (0, no symptom; 10, worst possible symptom; mean \pm SEM) after a follow-up of 34.5 months

	Preoperative	Follow-up	P-value
<i>Facial blushing</i>			
Blushing	9.1 \pm 1.7	4.0 \pm 2.3	$P < 0.0005$
Cardiac palpitations	4.5 \pm 1.4	1.2 \pm 0.8	$P < 0.008$
Anxiety	4.2 \pm 2.5	2.2 \pm 1.1	$P < 0.04$
Compensatory trunk sweating	3.0 \pm 0.5	4.5 \pm 1.1	$P = 0.3$
Compensatory feet sweating	2.6 \pm 0.7	5.9 \pm 1.2	$P < 0.004$
<i>Hyperhidrosis</i>			
Palmar sweating	7.1 \pm 2.4	0.2 \pm 0.7	$P < 0.0001$
Axillary sweating	5.3 \pm 2.7	3.5 \pm 1.4	$P < 0.02$
Compensatory trunk sweating	3.7 \pm 1.2	5.4 \pm 2.3	$P < 0.004$
Compensatory feet sweating	3.7 \pm 1.5	5.9 \pm 2.5	$P < 0.008$

moderate blushing on the left hemiface was noted 8 weeks after sympathectomy in stressful situations. A second patient described a worsening of blushing 6 months after operation, although the upper limbs were dry and warm.

(b) In the patients with *hyperhidrosis* (25 patients), a decrease in palmar sweating was observed in all patients but axillary sweating was reduced in only 15/25 (60%) of the patients. Compensatory sweating of the trunk and lower extremities was noted in 18/25 (72%) and 15/25 (60%) of the patients, respectively. Improved life style was observed in 24/25 (96%) of the patients. One patient (4%), however, was not satisfied, due to compensatory sweating in the lower part of the body. Gustatory sweating was observed in 11/37 (30%) of the patients.

After a mean follow-up of 34.5 months, no patient with hyperhidrosis presented recurrent symptoms. Recurrent symptoms of the whole series of patients were noted in 5.4% (2/37) of the patients.

All patients but one (thromboembolism) returned to work after a median time of 5 days with a range from 1 to 14 days. Postoperative analgesics were necessary for less than 1 week in 90% of the patients.

4. Discussion

Thoracic sympathectomy is a valid treatment option in patients suffering from facial blushing, palmar or axillary hyperhidrosis, and peripheral vascular disease, such as secondary Raynaud's disease [1,2]. Different surgical techniques have been reported, among which thoracoscopic sympathectomy is considered to be the least invasive technique [3–7]. However, several thoracoscopic techniques have been described with different access sites and depending on whether the chain is resected or just divided over the ribs [8].

We reported our experience with a video-assisted minimally invasive technique with a single 7-mm port access, using a modified paediatric cysto-resectoscope in a consecutive series of 37 patients. The patients were in a half-sitting dorsal decubitus position with abducted arms, allowing a simultaneous bilateral approach in the same position which saves operation time. The technique with a modified transurethral electroresectoscope has already been described by Drott et al. [9]. However, the port site was located caudal to the mid portion of the clavicle in their patients. Our technique with a transaxillary single approach may provide better cosmetic effects and less pain, and gives indeed an excellent visualisation of the sympathetic chain up to the first rib. The endoscopic transaxillary access has already been reported [2,3,10] but it usually requires several ports which might adversely influence the outcome regarding discomfort and pain. Clinical assessment 3 months after surgery in our series revealed an uneventful wound healing and an excellent functional and cosmetic result in all patients. Although some authors have advocated the use of 2- and 3-mm trocars, no discomfort and neuralgia sequelae were encountered in our series.

Complications occurred in 6.5% of the sympathectomies, which is comparable to other reports [11], but no conversion to open surgery was required in our series. The development of a residual mantle pneumothorax after endoscopic thoracic operations is a well-known complication and is not specific to this procedure per se [1,11,14]. Horner's syndrome was observed in 2.7% of the procedures, which corresponds to the data in the literature [11], but the symptomatology was transient in both patients, with complete recovery after 14 and 18 weeks, respectively. Both transient Horner's syndromes were probably related to thermic injury of the stellate ganglion during division of the chain on the second rib. Using cut instead of caustic may reduce this complication if our technique is applied. To maximally reduce the occurrence of this complication, a proper identification of the first rib is mandatory [12]. Pulmonary embolism and intraoperative cerebral damage have already been described following sympathectomy [8,9,13]. In our patient suffering from this severe postoperative complication, no findings were observed during operation, which could explain the event. A history of deep venous thrombosis was mentioned but the patient was not under anticoagulation therapy prior to surgery. We suspected a persistent foramen ovale to be the cause of crossed emboli.

The optimal amount of sympathetic denervation is yet unclear because of the great anatomic variability of the sympathetic chain [14]. A few authors have advocated a limited section of the sympathetic chain (T2–T3) in palmar hyperhidrosis and additional transection of T4 in axillary hyperhidrosis [6,15]. Yilmaz et al. recommended in addition excision of the lower 1/3 of the stellate ganglion for facial blushing and an extended resection (T2–T5) in patients with hyperhidrosis [3,11]. However, most authors actually perform transection of the chain from T2 to T4 for optimal sympathetic denervation [11]. In our technique, we did not perform resection of the ganglions but a division of the sympathetic chain on the ribs, cranial and caudal to the sympathetic ganglions. We think that to obtain a complete denervation from second to fourth ganglions, the chain has also to be transected on the fifth rib, since the fourth sympathetic ganglion is located between the fourth and fifth ribs. This procedure could reduce recurrence of the disease without increasing morbidity.

After a mean follow-up of 34.5 months, overall recurrence was noted in 2/37 (5.4%) of the patients. This is comparable to the literature indicating a recurrence rate ranging from 4 to 8% [1,6]. This is also seen after resection of the sympathetic chain [16]. Recurrence is often observed in the first 6–12 months after sympathectomy [1,4]. One patient had a recurrence of facial and neck blushing only on the left side. In this patient, the left sympathetic chain had been only divided from T2 to T4 and not to T5, due to a hindrance of the chain by the aortic arch. Other authors have also observed recurrence of facial, neck, and upper chest blushing if the division of the chain is limited to T2 and T3.

All patients with hyperhidrosis were free of symptoms 3 years after the operation.

In conclusion, our results suggest that single port thoracoscopic sympathectomy offers excellent, cosmetic, and functional results and avoids chest wall sequelae, which are sometimes seen after two to three port techniques. The division of the sympathetic trunk gives equal results than partial resection of the chain, with better results obtained in patients with palmar hyperhidrosis as compared to facial blushing.

References

- [1] Krasna MJ, Demmy TL, McKenna RJ, Mack MJ. Thoracoscopic sympathectomy: the U.S. experience. *Eur J Surg* 1998;580:19–21.
- [2] Telaranta T. Treatment of social phobia by endoscopic thoracic sympathectomy. *Eur J Surg* 1998;580:27–32.
- [3] Yilmaz EN, Dur AHM, Cuesta MA, Rauwerda JA. Endoscopic versus transaxillary thoracic sympathectomy for primary axillary and palmar hyperhidrosis and/or facial blushing: 5-year-experience. *Eur J Cardiothorac Surg* 1996;10:168–172.
- [4] Goh PMY, Cheah WK, de Costa M, Sim EKW. Needlescopic thoracic sympathectomy: treatment for palmar hyperhidrosis. *Ann Thorac Surg* 2000;70:240–242.
- [5] Massad M, LoCicero J, Matano J, Oba J, Greene R, Gilbert J, Hartz R. Endoscopic thoracic sympathectomy: evaluation of pulsatile laser, non-pulsatile laser, and radiofrequency-generated thermocoagulation. *Lasers Surg Med* 1991;11:18–25.
- [6] Raposio E, Filippi F, Nordström R, Santi P. Endoscopic transthoracic dorsal sympathectomy for the treatment of upper extremity hyperhidrosis: a new minimally invasive approach. *Plast Reconstr Surg* 1992;102:1629–1632.
- [7] Kesler KA, Brooks-Brunn JA, Campbell RL, Brown JW. Thoracoscopic sympathectomy for hyperhidrosis palmaris: a periareolar approach. *Ann Thorac Surg* 2000;70:314–317.
- [8] Rex LO, Drott C, Claes G, Göthberg G, Dalman P. The Borås experience of endoscopic thoracic sympathectomy for palmar, axillary, facial hyperhidrosis and facial blushing. *Eur J Surg* 1998;580(Suppl):23–26.
- [9] Drott C, Claes G, Olsson-Rex L, Dalman P, Fahlén T, Göthberg G. Successful treatment of facial blushing by endoscopic transthoracic sympathectomy. *Br J Dermatol* 1998;138:639–643.
- [10] Sugiyama S, Ikeya T, Hara H, Ichiki K, Yanagi K, Doki Y, Tsuda M, Misaki T. Dorsal sympathectomy for palmar hyperhidrosis by the thin thoracoscope. *Kyobu Geka* 1998;51:1087–1089.
- [11] Herbst F, Plas EG, Fugger R, Fritsch A. Endoscopic thoracic sympathectomy for primary hyperhidrosis of the upper limbs. A critical analysis and long-term results of 480 operations. *Ann Surg* 1994;220:86–90.
- [12] Wong CW. Transthoracic video endoscopic electrocautery of sympathetic ganglia for hyperhidrosis palmaris: special reference to localization of the first and second ribs. *Surg Neurol* 1997;47:224–229.
- [13] Cameron AEP. Complications of endoscopic sympathectomy. *Eur J Surg* 1998;580:33–35.
- [14] Drott C, Claes G, Göthberg G, Paszkowski P. Cardiac effects of endoscopic electrocautery of the upper thoracic sympathetic chain. *Eur J Surg* 1994;572:65–70.
- [15] Bonjer HJ, Hamming JF, du Bois NAJJ, van Urk H. Advantages of limited thoracoscopic sympathectomy. *Surg Endosc* 1996;10:721–723.
- [16] Dumont P, Hamm A, Skrobala D, Robin P, Toumieux B. Bilateral thoracoscopy for sympathectomy in the treatment of hyperhidrosis. *Eur J Cardiovasc Surg* 1997;11:774–775.