

Case report

Embolization of a ruptured intercostal artery aneurysm in type I neurofibromatosis

Beat Kipfer^{a,*}, Didier Lardinois^b, Jürgen Triller^c, Thierry Carrel^a

^aDepartment of Cardiovascular Surgery, University Hospital, Freiburgstrasse 10, CH-3010 Bern, Switzerland

^bDepartment of Thoracic Surgery, University Hospital, Freiburgstrasse 10, CH-3010 Bern, Switzerland

^cDepartment of Radiology, University Hospital, Freiburgstrasse 10, CH-3010 Bern, Switzerland

Received 19 September 2000; received in revised form 31 January 2001; accepted 21 February 2001

Abstract

We present the case of a female with history of a ruptured lumbar aneurysm years ago. She was known to have neurofibromatosis type I with the typical clinical signs. The patient was transferred to us with a hemothorax and an aortic lesion was suspected on the outside CT scan. Reevaluation of the investigation raised suspicion of a ruptured intercostal artery aneurysm, which was consequently demonstrated on angiography. The aneurysm was embolized and the patient recovered uneventful. We will discuss the optimal therapy for vessel lesions in neurofibromatosis type I. © 2001 Elsevier Science B.V. All rights reserved.

Keywords: Neurofibromatosis; Intercostal artery aneurysm; Embolization

1. Introduction

Neurofibromatosis is an autosomal dominant disease with eight distinct subtypes [1]. Type I and type II are the most common subtypes. The gene responsible for neurofibromatosis type I (NF I) is located near the centromere in the long arm of chromosome 17. The incidence of this common genetic disorder is 1 in 2500–3000. The characteristic findings are multiple café-au-lait spots (six or more lesions), axillary freckling or Crowe's sign, numerous fibromas and Lisch nodules or hamartomas [2]. Lisch nodules are the most common clinical feature, seen in 94% of children older than 6 years, and 97–100% of post pubertal patients with peripheral neurofibromatosis. Characteristic dermal fibromas and subcutaneous neurofibromas generally appear in late childhood or adolescence. The neurofibromas are hamartous in nature and of multicellular origin, composed mostly of Schwann cells, but also containing fibroblasts, mast cells and macrophages. In addition to these cutaneous signs, pheochromocytomas, intracranial tumors, Schwann cell tumors and syringomyelia are seen frequently. Children and young adults with neurofibromatosis may present vascular lesions predominantly in the abdominal aorta, the renal arteries, the internal carotid arteries and vertebral arteries [3]. In this age

group, neurofibromatosis is the most common genetically determined renovascular disorder resulting from fibromuscular dysplasia of the media [4]. Arterial lesions may include compression due to an extrinsic tumour, intramural thickening and saccular or fusiform aneurysm due to vascular dysplasia.

We report a case of a ruptured intercostal artery aneurysm with hemothorax treated successfully with embolization.

2. Case presentation

A 42-year-old female presenting with the phenotype of NF I was operated 6 years ago in another hospital because of a ruptured lumbar artery aneurysm. Surgery consisted in replacement of the infrarenal aorta with a PTFE graft after local repair had to be abandoned because of excessive bleeding.

The patient recovered well and had gained full activity; no further investigation was performed. Recently, she was admitted to an outside hospital complaining of chest pain since several days and an unexplained loss of consciousness. Chest X-ray revealed a right hemothorax. Computed tomography (CT) scan raised the suspicion of an aortic lesion. The patient was transferred in stable hemodynamic condition but with a hemoglobin value of 90 g/l.

Reviewing the outside CT scan, the thoracic aorta was

* Corresponding author. Tel.: +41-31-6328332; fax: +41-31-6322919.

E-mail address: beat.kipfer@insel.ch (B. Kipfer).

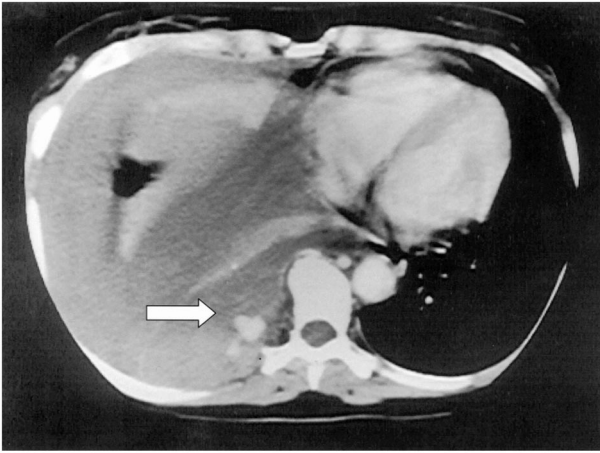


Fig. 1. Thoracic CT-scan revealing the spot of contrast medium suggesting an aneurysm.

without any pathological findings. However, there was a spot of contrast medium surrounded by a capsule in the hemothorax on the right side (Fig. 1). Because of the previous history of a lumbar aneurysm, an aortography was performed: this investigation demonstrated a ruptured aneurysm of an intercostal artery (Fig. 2). In view of the previous difficulties in aneurysmal repair, an endovascular procedure was selected. The aneurysm was successfully embolized with several fibred platinum coils (Vortex[®] fibred platinum coil-18, Boston Scientific/Target, Galway, Ireland) which allowed to block the arterial feeding from both sides. A chest drainage was placed in the right pleural cavity after the intervention. However, several days after initial bleeding, the hemothorax was already organized. Because of impaired oxygenation, the patient underwent two days later successful thoracoscopic evacuation and

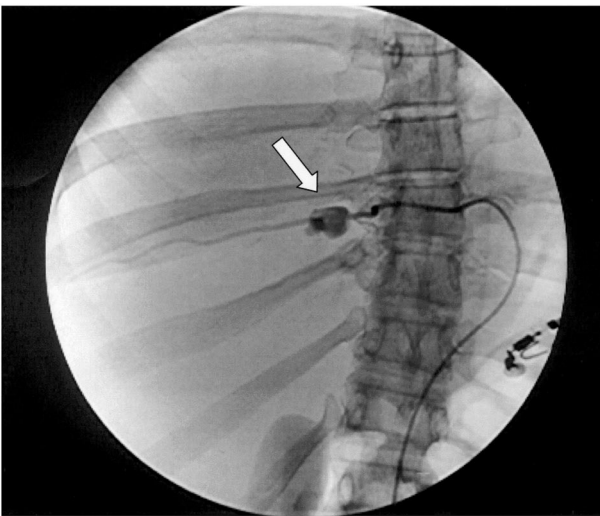

Fig. 2. Selective angiography demonstrating the intercostal aneurysm (arrow).

decortication. During this intervention, the embolized aneurysm was identified.

The patient was discharged without complications but she denied to have any further investigations.

3. Discussion

The typical arterial lesions encountered in neurofibromatosis type I are compression of a major vessel due to an intramural tumour and saccular or fusiform aneurysm due to vascular dysplasia. In large arteries, the main pathology is due to proliferation of intramuscular Schwann cells followed by secondary fibrosis whereas in smaller arteries, mesodermal dysplasia with stenosis, post-stenotic dilatation or aneurismal degeneration may be the main pathogenetic mechanism [2]. The variety of the underlying pathologic process is responsible for the different clinical presentations of the vascular lesions, the most frequent one being stenosis of the renal artery [5].

It has been suggested that all patients with type I neurofibromatosis have some degree of vasculopathy and post-mortem examinations frequently show arterial thickening, stenosis and aneurysms [6]. Since the majority of these lesions may be clinically silent, vascular involvement in type I neurofibromatosis has been underestimated in the past and is frequently diagnosed in emergency situations. Previous reports have emphasized that the treatment of such lesions may be surgical resection or endovascular occlusion of the vessel since reconstructive procedures are hazardous due to the fragility of the vascular wall [7–9]. In the present case contrast CT scan immediately allowed to suspect a bleeding artery in the right pleural cavity and angiographies precisely defined the vessel which was embolized successfully during the same procedure: this allowed immediate endovascular treatment once diagnosis was established.

In conclusion, patients with type I neurofibromatosis not rarely suffer from potentially dangerous vascular lesions and should be investigated by CT – scan or angiographies even in the absence of symptoms. Aneurysmal lesions may be best treated by endovascular occlusion since surgical reconstruction may be challenging because of the fragility of the vascular wall.

References

- [1] Xu G, O'Connell P, Viskochil D. The neurofibromatosis type I gene encodes a protein related to GAP. *Cell* 1990;62:599–608.
- [2] Riccardi V. Von Recklinghausen neurofibromatosis. *N Engl J Med* 1981;305:1617–1627.
- [3] Sharma A. Renal artery aneurysm, hypertension and neurofibromatosis. *J R Soc Med* 1991;84(6):373–374.
- [4] Huppman J, Gahton V, Bowers V, Mills J. Neurofibromatosis and arterial aneurysms. *Am Surg* 1996;62(4):311–314.
- [5] Riccardi V. Neurofibromatosis: past, present, and future. *N Engl J Med* 1991;324:1283–1285.

- [6] Riccardi V. Neurofibromatosis: phenotype, natural history, and pathogenesis. The Johns Hopkins University Press 1992:124–127.
- [7] Saitoh S, Matsuda S. Aneurysm of the major vessels in neurofibromatosis. *Arch Orthop Trauma Surg* 1998;117(1/2):110–113.
- [8] Teitelbaum G, Hurvitz R, Esrig B. Hemothorax in type I neurofibromatosis. *Ann Thorac Surg* 1998;66(2):569–571.
- [9] Hassen-Khodja R, Declémy S, Batt M, Castanet J, Perrin C, Ortonne J. Visceral artery aneurysms in Von Recklinghausen's neurofibromatosis. *J Vasc Surg* 1997;25(3):572–575.