

Pulmonary function testing after operative stabilisation of the chest wall for flail chest[☆]

D. Lardinois^a, T. Krueger^b, M. Dusmet^b, N. Ghisletta^a, M. Gugger^c, H.-B. Ris^{b,*}

^aDivision of Thoracic Surgery, University Hospital of Berne, Berne, Switzerland

^bDepartment of Surgery, University Hospital of Lausanne, Lausanne, Switzerland

^cDivision of Pulmonary Medicine, University Hospital of Berne, Berne, Switzerland

Received 4 October 2000; received in revised form 19 May 2001; accepted 22 May 2001

Abstract

Objective: This is a prospective evaluation of chest wall integrity and pulmonary function in patients with operative stabilisation for flail chest injuries. **Methods:** From 1990 to 1999, 66 patients (56 men, 10 women; mean age 52.6 years) with antero-lateral flail chest (≥ 4 ribs fractured at ≥ 2 sites) underwent surgical stabilisation using reconstruction plates. Clinical assessment and pulmonary function testing were performed at 6 months following surgery. **Results:** Fifty-five (83%) patients had various combinations of injuries of the thorax, head, abdomen and extremities. Sixty-three (95.5%) patients underwent unilateral and 3 (4.5%) patients bilateral stabilisation with a median delay of 2.8 days (range 0–21 days) from admission. The 30-day mortality was 11% (seven of 66 patients). Immediate postoperative extubation was feasible in 31 of 66 patients (47%) and extubation within 7 days following stabilisation in 56 of 66 patients (85%). No plate dislocation was observed during the follow-up. The shoulder girdle function was intact in 51 of 57 patients (90%). Chest wall complaints were noted in 6 of 57 (11%) patients, requiring removal of implants in three cases. All patients returned to work within a mean period of 8 (range 3–16) weeks following discharge. Pulmonary function testing ($n = 50$) at 6 months after the operation revealed a significant difference of predicted vs. recorded vital capacity (VC) and forced expiratory volume in 1 s (FEV1) ($P = 0.04$ and $P = 0.0001$, respectively; Wilcoxon signed-rank test). The median ratio of the recorded and predicted total lung capacity (TLC) was shown to be significantly higher than 0.85 ($P = 0.0002$; Wilcoxon signed-rank test), indicating prevention of pulmonary restriction. **Conclusion:** Antero-lateral flail chest injuries accompanied by respiratory insufficiency can be effectively stabilised using reconstruction plates. Early restoration of the chest wall integrity and respiratory pump function may be cost effective through the prevention of prolonged mechanical ventilation and restriction-related working incapacity. © 2001 Elsevier Science B.V. All rights reserved.

Keywords: Chest trauma; Flail chest; Stabilisation; Lung function testing

1. Introduction

Blunt chest wall trauma is a major cause of morbidity and mortality, especially in the presence of flail chest, as defined as more than four ribs fractured at more than two sites. Severe flail chest is associated with respiration pump failure, leading to retention of secretions, atelectasis, pneumonia, empyema and respiratory insufficiency [1] as well as late restriction [2]. Chest wall instability may be treated conservatively with appropriate analgesia and clearing of bronchial secretions [3]. However, the treatment of severe flail chest when respiratory failure develops despite aggressive conservative management remains controversial.

Some authors advocate prolonged intubation and mechanical respiration (internal fixation) while others favour external stabilisation by operative reposition and osteosynthesis of the broken ribs, claiming that operative stabilisation of unstable chest wall segments markedly reduces the duration of ventilatory support, the intensive care unit stay and morbidity, especially in cases of flail chest without underlying pulmonary contusion. In previous reports, we have prospectively assessed the outcome of patients requiring osteosynthesis for flail chest with respect to the morbidity and duration of mechanical ventilation [4,5]. The current study was designed to assess pulmonary function in all patients who underwent operative fixation of a flail chest in order to assess the impact of the procedure on the prevention of posttraumatic chest wall and pulmonary restriction.

[☆] Presented at the 14th Annual Meeting of the European Association for Cardio-thoracic Surgery, Frankfurt, Germany, October 7–11, 2000.

* Corresponding author. Tel.: +41-21-314-2408; fax: +41-21-314-2358.
E-mail address: hris@chuv.hospvd.ch (H.-B. Ris).

2. Patients and methods

The outcome of all patients who underwent osteosynthesis of a severe flail chest between 1990 and 1999 was prospectively assessed. Indications for surgical fixation were: (1) non-intubated patients with respiratory failure despite continuous peridural analgesia and aggressive clearance of bronchial secretions ($n = 28$); (2) patients with extended antero-lateral flail chest and progressive dislocation of the fractured ribs ($n = 15$) (Fig. 1); (3) intubated patients who did not require prolonged intubation in the absence of severe pulmonary contusion or cerebral injuries, in order to reduce the use of mechanical ventilation when the patient failed to wean ($n = 21$) and (4) patients who required a thoracotomy due to associated intrathoracic injury ($n = 2$).

Osteosynthesis was performed through a lateral approach. The latissimus dorsi muscle was divided and the serratus anterior muscle was dissected and divided at its insertion on the chest wall. The fractured ribs were exposed and care was taken not to strip the periosteum from the ribs. Standard 3.5 mm reconstruction plates and cancellous screws (Synthes A0[®], Stratec Medico AG, Oberdorf, Switzerland) were used. The fractures were stabilised with a minimum of two anchoring screws on each side of the fracture line. The plates were shaped while the lung was ventilated by use of high tidal volumes in order to prevent operation-related restriction (Fig. 2). The most dislocated ribs were osteosynthesised. The first two ribs were never stabilised to avoid injury of the subclavian vessels and the brachial plexus. In patients with an associated fracture of the clavicle, an osteosynthesis of the clavicle was performed to preserve shoulder girdle function. The postoperative course of all patients was prospectively assessed. The patients were examined clinically and pulmonary function tests were performed 6 months after the operation. The clinical evaluation included a subjective assessment of residual pain or discomfort of the chest wall and shoulder girdle, the extent of return to normal physical and professional activities, and

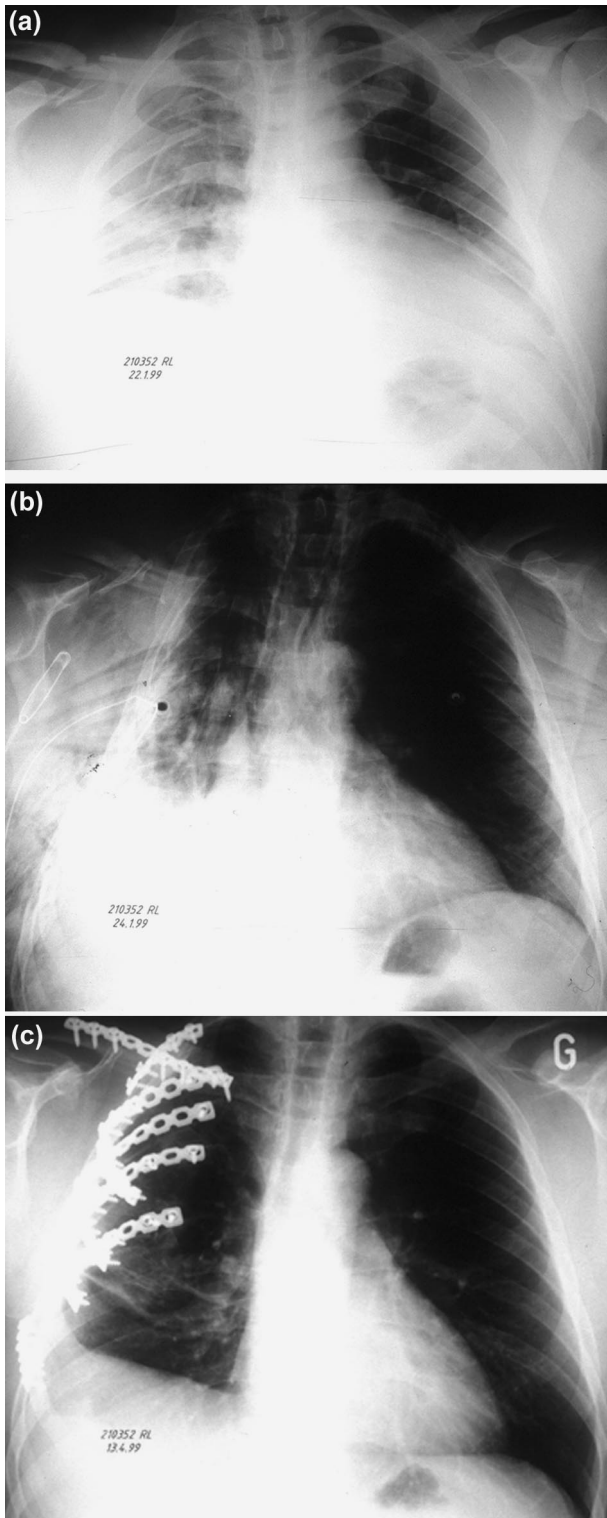


Fig. 1. Chest X-rays of a patient with flail chest: (a) at admission, conservative therapy with peridural analgesia and physiotherapy; (b) 2 days after admission, massive shrinkage of the chest wall, respiratory insufficiency requiring intubation; (c) 3 months following operative stabilisation.

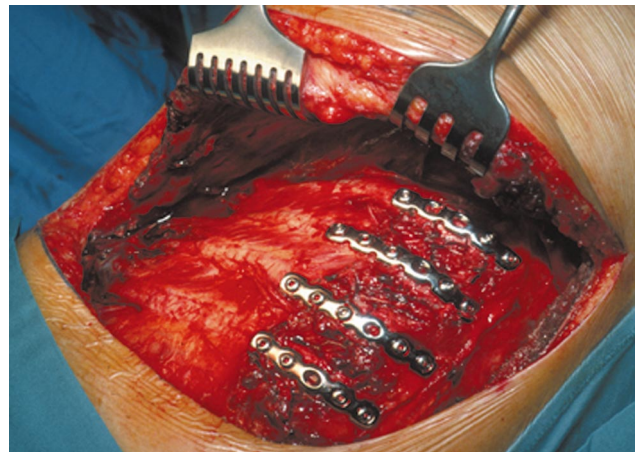


Fig. 2. Surgical stabilisation using reconstruction plates.

was followed by examination of the chest wall and shoulder girdle function. Pulmonary function tests at 6 months included spirometry, spiroergometry and arterial blood gas analysis. Statistical analysis was performed by use of the Wilcoxon signed-rank test in order to compare the predictive and recorded vital capacity (VC), forced expiratory volume in 1 s (FEV1) and total lung capacity (TLC). TLC-predicted values were calculated according to standard references based on age and height defined by the European Coal and Steel Company (Table 1) [6]. Restriction was defined as a measured postoperative TLC, which was less than 85% of the predicted value for the patient.

3. Results

Between 1990 and 1999, 732 patients with flail chest were admitted at our institution. Sixty-six patients underwent surgical chest wall stabilisation. Ten were women (15%) and 56 were men (85%), with a mean age at operation of 52.6 years, ranging from 21 to 82 years. Forty patients (61%) had motor vehicle accidents, 15 (23%) were injured at work, six (9%) during sports activities, and five patients (7%) fell at home. Associated injuries were observed in 55 patients (83%) and consisted of orthopaedic lesions in 42 patients (64%), head injuries in 31 (47%), and abdominal lesions in 19 (29%). The orthopaedic injuries included lesions of shoulder and upper extremities in 27 patients (41%), pelvis and lower extremities in 18 (27%) and to the spine in 16 (24%). Associated injuries to blood vessels and nerves were observed in two (3%) and three patients (4.5%), respectively. The two patients with associated intrathoracic injury presented with a massive right hemothorax and were hemodynamically unstable. A right postero-lateral thoracotomy was performed and diaphragmatic injury was diagnosed. The inferior phrenic artery was ligated and the diaphragm was repaired. Chest wall stabilisation was performed in the same session. The postoperative course was uneventful in both patients.

Table 1
Determination of TLC-predicted value^a

Male	Female
Vital capacity	
≤ 25 years	≤ 25 years
$0.06103H - 0.02825A - 4.654$	$0.04664H - 0.02425A - 3.284$
> 25 years	> 25 years
$0.06103H - 0.028A - 4.654$	$0.04664H - 0.024A - 3.284$
Residual volume	
≤ 25 years	≤ 25 years
$0.0131H + 0.02225A - 1.232$	$0.01812H + 0.01625A - 2.003$
> 25 years	> 25 years
$0.0131H + 0.022A - 1.232$	$0.01812H + 0.016A - 2.003$

^a TLC pred. = VC (vital capacity) pred. + RV (residual volume) pred. Standard values for adults according to the European Coal and Steel Company (1983). H, height (cm); A, age (years).

Associated hemothorax and pneumothorax were found in 62 patients (94%) and 57 patients (86%) on the chest X-ray at admission. CT scan revealed an associated lung contusion in 53 patients (80%). Twenty-three patients (35%) were intubated before or upon admission, due to respiratory insufficiency, associated cerebral injuries or hypovolemic shock. The flail chest was unilateral in 91% (60 of 66 patients) and bilateral in 9% of the patients (6 of 66 patients). The mean number of fractured ribs was 6, ranging from 4 to 11. Three patients presented with bilateral antero-lateral instability, which was stabilised through a transverse submammary approach. In three other patients presenting with bilateral flail chest, fixation of the chest wall was performed on the side with antero-lateral instability while the contralateral side with postero-lateral instability was treated conservatively. The median time from admission to stabilisation of the chest wall was 2.8 days (range 0–21 days). The mean operating time was 145 min, ranging from 60 to 200 min. Immediate postoperative extubation was feasible in 31 patients (47%). The median duration of postoperative intubation was 2.1 days, ranging from 0.5 to 26 days. The median hospital stay was 17.4 days, with a range of 8–60 days. Forty-six patients (70%) received continuous peridural analgesia for up to 10 days. The patients were transferred from the intensive care unit (ICU) to the ward after an average of 6.8 days (range 1–48 days). The overall 30-day mortality was 11% (7 of 66 patients). Four patients died of adult respiratory distress syndrome (ARDS) and multiorgan failure, due to persistent pneumonia. These patients underwent delayed operative stabilisation, after mechanical ventilation for up to 3 weeks had failed to achieve adequate consolidation of the unstable chest wall. Two other patients died from cerebral haemorrhage and infarction, respectively, and one from refractory arrhythmia subsequent to a severe cardiac contusion. Postoperative complications were observed in 12 patients (18%). These included atelectasis and pneumonia of the ipsilateral lung in five, acalculous cholecystitis in three, myocardial infarction in two, and wound infection in two patients. All five patients with postoperative pneumonia recovered after treatment by bronchoscopy, mini-tracheotomy and antibiotics. Cholecystectomy was performed in the three patients with acalculous cholecystitis. The two patients with myocardial infarction underwent successful fibrinolysis. Two patients developed superficial wound infections 10 and 13 days after chest wall stabilisation, which required re-operation and wound debridement. In both cases, extended contusion of overlying soft tissues was found at the time of the initial operation. Removal of the plates and screws was not necessary and healing was achieved with drainage and antibiotics.

Six months follow-up was obtained in 57 of 59 surviving patients (97%) and revealed uneventful healing in all patients, including the two patients who had superficial wound infections. Attenuated sensitivity of the anterior chest wall was noted in four patients (7%). Six patients (11%) suffered from persistent pain in the operative site,

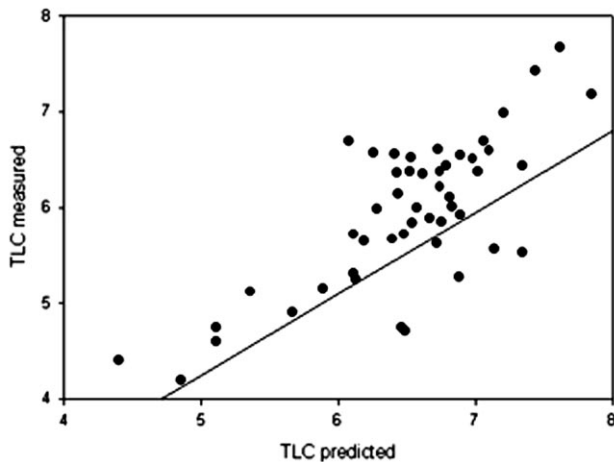


Fig. 3. Predicted and measured value of total lung capacity in litres 6 months after chest wall stabilisation ($n = 50$). The line represents the 85% of value of the predicted TLC.

which was improved in three patients following complete removal of all plates and screws. Shoulder girdle function was symmetrical in 51 patients (90%), whereas in six patients abduction of the ipsilateral shoulder was limited to 100° . These patients also had associated injuries of the ipsilateral shoulder girdle or brachial plexus. No chest wall deformity was observed in any patient. Radiological evaluation at follow-up showed no dislocation of plates in any of the patients, however, an asymptomatic dislocation of one and two screws was seen in two patients, respectively. All patients returned to work after a mean period of 8 weeks (range 3–16 weeks) following discharge. Pulmonary function testing 6 months following surgery was performed in 50 out of 57 surviving patients (88%). Pulmonary function revealed normal values in 26 patients (52%), an obstruction pattern in 11 (22%) and mixed obstruction and restriction in 8 (16%).

Based on the assumption that pulmonary restriction would be reflected by a TLC value of less than 85% of the predicted value, the ratio of the recorded and predicted TLC for all patients was calculated. By use of a non-parametric rank test, the ratio was shown to be significantly higher than 0.85 ($P = 0.0002$) (Fig. 3). A restriction as defined as a recorded TLC less than 85% of the predicted value was found in five patients (10%). All five of these patients were working full-time without complaints.

4. Discussion

Flail chest is observed in about 10% of patients with chest trauma and has a mortality rate of 10–15% [1]. This high mortality rate is partly due to the high prevalence of associated life-threatening extra-thoracic injuries [1]. However, the principle cause of death consists of pneumonia and sepsis with prolonged intubation. A bilateral flail chest and age greater than 50 years are aggravating factors [4].

Conservative therapy with aggressive chest physiotherapy (including bronchoscopy to aid the clearance of bronchial secretions) and optimal pain control is the mainstay of conventional therapy for flail chest [7]. If respiratory failure occurs, intubation and prolonged ventilation are often required [7]. Tracheotomy is often performed early to aid weaning and to prevent the tracheal complications of prolonged ventilation. Continuous epidural analgesia has proven to be beneficial for optimal pain control and can decrease both the duration of the ICU and overall hospital stay [8]. It has been shown to be superior to other forms of pain management in this situation [9].

In patients with cerebral injuries and extensive lung contusion, endotracheal intubation is mandatory [3]. The purpose of respiratory support in flail chest is to reduce atelectasis and the resulting shunt and to facilitate removal of secretions from the airways [5]. It can be performed with continuous positive airway pressure or with intermittent mandatory ventilation plus positive end-respiratory pressure. Furthermore, mechanical ventilation provides an internal pneumatic stabilisation of the flail chest until fibrous stabilisation is achieved. However, prolonged mechanical ventilation can be associated with a high prevalence of complications, including chest infection, septicaemia and barotrauma [10]. Gregoretti et al. [11] showed that ventilatory assistance via a mini-tracheotomy could reduce some of the side effects of prolonged tracheal intubation. Finally, Tzelepis et al. [12] showed that the distortion of the chest wall imposed by ventilators may increase the work of breathing and may actually contribute to difficulties in weaning the patient from the ventilator.

Chest wall stabilisation has been used to shorten the period of intubation in order to reduce the morbidity due to prolonged mechanical ventilation as well as the ICU stay in selected patients [5,10,13]. However, surgical management of flail chest is highly controversial. There are no prospective randomised trials comparing conservative and surgical management of flail chest. The goal of this prospective study was to analyse pulmonary lung function after surgical chest wall stabilisation and to determine if osteosynthesis reduces the incidence of residual restriction.

The first group of patients consisted of young patients with flail chest and severe chest wall dislocation. Despite peridural analgesia, pain control was difficult to achieve and the patients could not clear their secretions by coughing. Chest X-rays showed progressive chest wall shrinkage with reduction of the volume of the ipsilateral chest cavity. This has already been described as a valid indication for chest wall stabilisation [14]. Patients with antero-lateral dislocations are particularly prone to develop late restriction and pseudarthrosis leading to partial or complete professional incapacity.

Chest wall stabilisation was performed with standard 3.5 mm thick reconstruction plates as used for pelvic stabilisation. Numerous other types of implants have been advocated but none of them have provided reliable and durable

stable osteosynthesis [13,15]. These plates have already been shown to be very efficient for chest wall stabilisation. They are long enough to cover a substantial length of the ribs and to allow a minimal anchorage of two (or ideally three) screws on either side of the fracture site. They can easily be conformed to the shape of the individual ribs in an ideal position, which is provided by expansion of the underlying lung during mechanical ventilation [4,5,16]. No dislocation of plates was observed in our series. The two patients with screw dislocation presented with severe osteoporosis and the screws had been placed antero-laterally within cartilage.

Lung contusion was observed on preoperative CT scans in 80% of the patients. It has been demonstrated that extensive lung contusion increases the incidence of pneumonia and the need for prolonged mechanical ventilation [17]. Therefore, extensive and slowly resolving contusion is a relative contraindication for flail chest stabilisation because these patients require prolonged intubation and will not benefit from the advantages of early chest wall stabilisation [18,19]. In our series, most of the patients had well less than 30% of non-functional lung tissue and could therefore be extubated early after chest wall stabilisation. Six patients who presented with an extensive lung contusion and flail chest were operated on secondarily because persistent paradoxical movements of the chest wall prevented weaning from the respirator.

The overall 30-day mortality was 11%. This compares favourably to reported mortality rates of 15–30% [1]. Death in patients with flail chest is often due to pneumonia, sepsis and the development of an ARDS [20]. In our series, pneumonia progressing to ARDS in association with multi-organ failure was also a major cause of death. All four patients who died from ARDS were elderly patients who had prolonged intubation. They developed pneumonia with sepsis. Delayed chest wall stabilisation was performed but patients could still not be weaned from the ventilator. This would support the opinion that early chest wall stabilisation may be especially indicated in elderly patients with flail chest to prevent the complications of long-term mechanical ventilation [5,13].

Ten percent of the patients complained of residual chest wall discomfort at the 6-month follow-up visit. This was due either to chronic pain or to an impression of rigidity of the chest wall. It is difficult to determine to what extent this is due to the initial trauma of the soft tissues, muscles and chest wall or to the operation itself. It could be demonstrated in these patients that complaints were not related to functional impairment, since their pulmonary function was normal, i.e. without restriction. Our results suggest that chest wall stabilisation with reconstruction plates does not lead to impaired postoperative pulmonary function. However, Kishikawa et al. [21] observed that pulmonary function could fully recover within 6 months of injury in patients without extensive lung contusion despite a residual deformity of the chest wall caused by flail chest. Nonethe-

less, our results suggest that operative stabilisation in patients without major lung contusion may provide better cosmetic results and considerable savings due to a reduction on the use of ICU and general hospital resources as compared to conservative therapy in selected cases while preserving both pulmonary function and of the quality of life.

In conclusion, we think that surgical chest wall stabilisation has a place in the multimodal therapy of flail chest. The best indication for early operative chest wall stabilisation is the presence of antero-lateral flail chest and respiratory failure without severe pulmonary contusion, especially in the elderly. This can provide an important reduction in the duration of ventilatory support as well as the preservation of chest wall mechanics and lung function. Secondary stabilisation is recommended in patients with pulmonary contusion showing persistent instability of the chest wall, which prevents weaning from the ventilator. Finally non-intubated patients with deteriorating pulmonary function in the setting of a flail chest benefit from stabilisation in terms of respiratory dynamics, better clearance of secretions through efficient cough and improved pain control.

References

- [1] Ciraulo DL, Elliott D, Mitchell KA, Rodriguez A. Flail chest as a marker for significant injuries. *J Am Coll Surg* 1994;178:466–470.
- [2] Lee RB, Bass SM, Morris Jr. JA, MacKenzie EJ. Three or more rib fractures as an indicator for transfer to a Level I trauma center: a population-based study. *J Trauma* 1990;30:689–694.
- [3] Lewis Jr. FL, Thomas AN, Schlobohm RM. Control of respiratory therapy in flail chest. *Ann Thorac Surg* 1975;20:170–176.
- [4] Reber P, Ris HB, Inderbitzi R, Stark B, Nachbur B. Osteosynthesis of the injured chest wall. Use of the AO (Arbeitsgemeinschaft für Osteosynthese) technique. *Scand J Thorac Cardiovasc Surg* 1993;27:137–142.
- [5] Mouton W, Lardinois D, Furrer M, Regli B, Ris HB. Long-term follow-up of patients with operative stabilisation of a flail chest. *Thorac Cardiovasc Surg* 1997;45:242–244.
- [6] ECSC. Bulletin européen de physiopathologie respiratoire 1983;19(Suppl 5).
- [7] Gabram SG, Schwartz RJ, Jacobs LM, Lawrence D, Murphy MA, Morrow JS, Hopkins JS, Knauff RF. Clinical management of blunt trauma patients with unilateral rib fractures: a randomized trial. *World J Surg* 1995;19:388–393.
- [8] Luchette FA, Radafshar SM, Kaiser R, Flynn W, Hassett JM. Prospective evaluation of epidural versus intrapleural catheters for analgesia in chest wall trauma. *J Trauma* 1994;36:865–869 (discussion p. 869–70).
- [9] Mackersie RC, Shackford SR, Hoyt DB, Karagianes TG. Continuous epidural fentanyl analgesia: ventilatory function improvement with routine use in treatment of blunt chest injury. *J Trauma* 1987;27:1207–1212.
- [10] Ahmed Z, Mohyuddin Z. Management of flail chest injury: internal fixation versus endotracheal intubation and ventilation. *J Thorac Cardiovasc Surg* 1995;110:1676–1680.
- [11] Gregoretti C, Foti G, Beltrame F, Giugiaro PM, Biolino P, Burbi L, Turello M, Agostini F, Bernardino M, Musto P. Pressure control ventilation and minitracheotomy in treating severe flail chest trauma. *Intensive Care Med* 1995;21:1054–1056.

- [12] Tzelepis GE, McCool FD, Hoppin Jr FG. Chest wall distortion in patients with flail chest. *Am Rev Respir Dis* 1989;140:31–37.
- [13] Paris F, Tarazona V, Blasco E, Canto A, Casillas M, Pastor J, Paris M, Montero R. Surgical stabilization of traumatic flail chest. *Thorax* 1975;30:521–527.
- [14] Haasler GB. Open fixation of flail chest after blunt trauma. *Ann Thorac Surg* 1990;49:993–995.
- [15] Borrelly J, Grosdidier G, Wack B. Our 5-year experience with the use of a new material for thoracic osteosynthesis: the sliding staple-splint. *Ann Chir* 1985;39:465–470.
- [16] Oyarzun JR, Bush AP, McCormick JR, Bolanowski PJ. Use of 3.5-mm acetabular reconstruction plates for internal fixation of flail chest injuries. *Ann Thorac Surg* 1998;65:1471–1474.
- [17] Voggenreiter G, Neudeck F, Aufmkolk M, Obertacke U, Schmit-Neuerburg KP. Treatment outcome of surgical thoracic wall stabilization of the unstable thorax with and without lung contusion. *Unfallchirurg* 1996;99:425–434.
- [18] Voggenreiter G, Neudeck F, Aufmkolk M, Obertacke U, Schmit-Neuerburg KP. Operative chest wall stabilization in flail chest – outcomes of patients with or without pulmonary contusion. *J Am Coll Surg* 1998;187:130–138.
- [19] Richardson JD, Adams L, Flint LM. Selective management of flail chest and pulmonary contusion. *Ann Surg* 1982;196:481–487.
- [20] McRitchie DI, Matthews JG, Fink MP. Pneumonia in patients with multiple trauma. *Clin Chest Med* 1995;16:135–146.
- [21] Kishikawa M, Yoshioka T, Shimazu T, Sugimoto H, Sugimoto T. Pulmonary contusion causes long-term respiratory dysfunction with decreased functional residual capacity. *J Trauma* 1991;31:1203–1208 (discussion p. 1208–10).

Appendix A. Conference discussion

Dr Rea (Padova, Italy): We know that many patients with chest trauma have a big problem with lung contusion. I'm not sure that many patients need intubation for chest flail but maybe need intubation for pulmonary contusion. What is your policy? Did you operate on all patients with chest flail?

Dr Lardinois: No, we have operated about 10% of the patients with severe antero-lateral flail chest. Preoperative CT scan showed lung contusion in 80% of the patients, but most of these patients had less than 30% of non-functional lung tissue and could benefit from an early extubation. We have only operated 6 patients (9%) with extended lung contusion. In these patients, persistent paradoxical movements prevented weaning from the respirator and a prolonged intubation was mandatory.

Dr Wihlm (Strasbourg, France): First of all, you didn't indicate the causes of this flail chest etiology. The speed is limited in Switzerland. They are very strongly limited to 120 kilometers per hour on the motorways and the police are everywhere. I'm surprised that you have so many cases. Could you tell us if it's only traffic cases or whatever?

Dr Lardinois: 60.6% of the patients had motor vehicle accidents, about 30% of the patients were injured at work, and about 9% were injured during sports activities.

Dr Wihlm: How long has the series been? Is it a historic series?

Dr Lardinois: The study was performed during 10 years, from 1990 to 1999.

Dr Wihlm: What is the average time before the patient comes into the ICU and you operate on him? Did you operate immediately? What is the average time you are waiting on their ventilation?

Dr Lardinois: The median delay from admission to operation was 2.8 days. We have only stabilized two patients immediately after admission because a thoracotomy was mandatory, due to a massive hemothorax. Otherwise, the operation was performed as a deferred emergency in patients who did not require prolonged intubation but failed to wean. In the patients without intubation at admission, a peridural analgesia was usually performed. If the patients were unable to cough and to mobilise their secretions despite optimal analgesia or if a progressive shrinkage of the volume of the chest cavity was observed on successive chest X-rays, we proposed to operate these patients after a few days to prevent and to avoid pneumonia, especially in the elderly.

Dr Klepetko (Vienna, Austria): I just want to add a question on the indication for the stabilization. You have explained it for those patients who were not intubated. But for the other group, the patients who were already intubated, how do you judge in them? Do you try to go into some process of weaning, and, if you see that it doesn't work immediately, proceed with the operative procedure, or do you not do any attempts at all to wean the patients? In addition, does the number of ribs involved clearly have an impact on your judgment or not?

Dr Lardinois: In the patients intubated at admission, if a prolonged intubation for conditions such as cerebral injuries or extended lung contusion was not required, we always tried to wean these patients from the ventilator. A stabilization of the chest wall was performed only in the patients who failed to wean after 2 or 3 days to avoid complications of a prolonged intubation. The mean number of fractured ribs was 6, ranging from 4 to 11.

Dr Ris: As co-author, I would like to make a comment. We have presented a very selected patient group. Out of about 300 to 400 patients a year with serial rib fractures, there were maybe 50 patients with flail chest and only about 10 per year were stabilized by osteosynthesis. This technique has been reserved for severe flail chest, with completely unstable or impacted chest wall, and in fact in these patients we believe that operative stabilization might be a good alternative in order to prevent a three-week period of intubation. Of course, we do not stabilize all flail chests, but only those with marked instability or impactation, usually localized antero-laterally. However, these patients do profit from operations since the other solution would be a three-week period of intubation. We have seen that even after three weeks intubation, not all of these chest walls were stable, depending on the degree of soft tissue damage.