

Heinz Sager · Dean Konjević · Marijan Grubešić
Zdravko Janicki · Krešimir Severin · Relja Beck

***Stichorchis subtriquetrus* in European beaver from Croatia: first report**

Received: 22 September 2004 / Accepted: 9 December 2004 / Published online: 27 January 2005
© Springer-Verlag 2005

Abstract Since 1996, European beavers (*Castor fiber*) have been reintroduced from Germany to Croatia. However, little is known about the health status of the established population. Necropsy of a 2-year-old female European beaver, which died from a car accident, revealed 28 adult trematodes in the preserved fragments of the colon and in the peritoneal cavity. All of them were identified as *Stichorchis subtriquetrus*. The typical location of these parasites is the large intestine, and the finding of several specimens in the peritoneal cavity can be explained by the severe trauma. We assume that the trematode was introduced to Croatia along with the beavers. Furthermore, it is very probable that the life cycle can be completed as the intermediate hosts are part of the local fauna. This is the first record of *S. subtriquetrus* in Croatia.

Keywords European beaver · *Stichorchis subtriquetrus* · Trauma · Introduction

Introduction

Following complete eradication, the European beaver (*Castor fiber* L.) was successfully reintroduced from Germany to Croatian hunting grounds in the period from 1996 to 1998 (Grubešić 2004). A first group of 85 individuals was released in carefully selected habitats near the cities Legrad and Čazma, and gained full protection by the law (Hunting Act 1994). Proper management (project “Beaver in Croatia”) and public support of the project resulted in population growth to an estimated 200 individuals. However, the increasing population requires new habitats. Nowadays, traffic collisions are the main cause of beaver mortality in Croatia.

Despite the increasing number of beavers in Croatia, there are no reports on their health condition or parasitic infestation. In this paper, we present the finding of *Stichorchis subtriquetrus* in a beaver.

Materials and methods

In April 2004, an approximately 2-year-old female beaver was killed by a car accident near the village Grubišno polje. The carcass was immediately transported to the Faculty of Veterinary Medicine, Zagreb. Necropsy revealed a large number of *Paramphistomum*-like trematodes in the colon and the peritoneal cavity. All helminths were collected and stored in 10% formalin. Stored samples were delivered to the Institute of Parasitology at the University of Bern for species determination.

The parasites were characterized morphologically and stained with aceto alum carmine (Bona 1974). Due to the preceding formalin fixation, the procedure was modified, i.e. after staining and dehydration, the specimens were stored in clove oil for 2 weeks, while they were compressed between two glass plates.

H. Sager (✉)
Institute of Parasitology, University of Bern, Bern,
3001, Switzerland
E-mail: heinz.sager@ipa.unibe.ch
Tel.: +41-31-6312475

D. Konjević · Z. Janicki · K. Severin
Chair for Game Biology, Pathology and Breeding,
The Faculty of Veterinary Medicine,
University of Zagreb, Heinzelova 55,
10 000 Zagreb, Croatia

M. Grubešić
Department of Forest Protection and Wildlife Management,
Forestry Faculty, University of Zagreb,
Svetošimunska 25, 10 000 Zagreb, Croatia

R. Beck
Department of Parasitology,
The Faculty of Veterinary Medicine,
University of Zagreb, Heinzelova 55, 10 000 Zagreb, Croatia

Results and discussion

Necropsy revealed 28 adult helminths that were located inside the preserved fragments of the colon and in the peritoneal cavity (Fig. 1). Other organs appeared normal. All recovered helminths (Fig. 2) were macroscopically identified as trematodes. Further characterization by direct microscopy and aceto alum carmine staining led to the identification of *S. subtriquetrus* (Trematoda—Paramphistomata—Paramphistomatidae; Erickson 1944).

This parasite is specific for both the European (*C. fiber*) and the Canadian beaver (*C. canadensis*), and typically occurs in the caecum (Skrjabin 1949; McKown et al. 1995; Koubková et al. 2002). In the case of severe infestation (more than 150 individuals), adult parasites can also be found in the host's colon, and can cause progressive weight loss, anaemia, intoxication or even death (Skrjabin 1949; McKown et al. 1995). However, stichorchosis usually does not cause any clinical signs. The additional recovery of parasites from the peritoneal cavity of the examined beaver carcass can be explained by the severe trauma and loss of intestinal integrity caused by the car accident.

Beavers are exclusively herbivorous, ingesting large quantities of aquatic macrophytes (McMaster and McMaster 2001), which increases the risk of infestation with *S. subtriquetrus*. Therefore, the prevalence of this parasite in beavers can be more than 90% (Drozd et al. 2004).

As *S. subtriquetrus* exhibits high host specificity, predominantly depending on beavers (Koubková et al. 2002), we believe that it was introduced to Croatian fauna in the course of the beaver recovery project. Because suitable intermediate hosts, i.e. aquatic snails (*Lymnaea ovata*, *Planorbis vortex*, *Bythinia tentaculata*) or the terrestrial snail *Succinea putris* (Skrjabin 1949), are present in Croatia, it is concluded that *S. subtriquetrus* can complete its life cycle and can be maintained in Croatian beavers. This statement is supported by the fact that the estimated age of the female beaver was

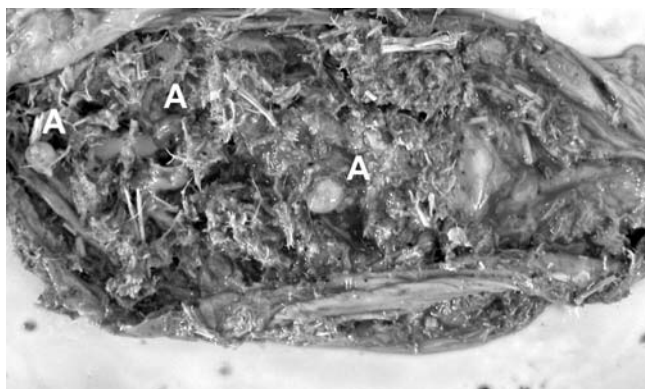


Fig. 1 Preserved colon fragment. The adult stages of *Stichorchis subtriquetrus* (A) are found in the intestinal content

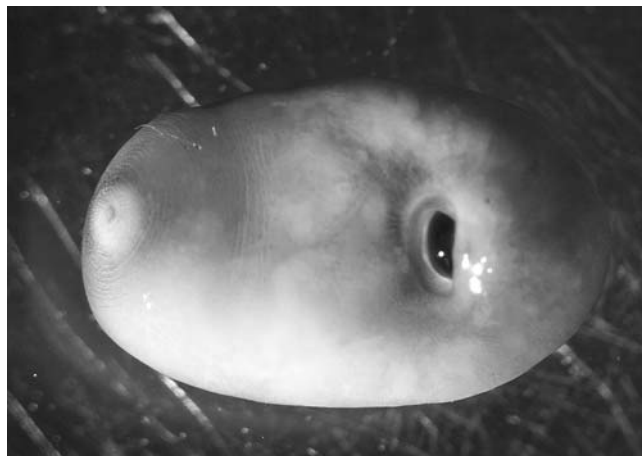


Fig. 2 *S. subtriquetrus*—closer view of ventral surface

2 years, meaning that she was born in Croatia. On the other hand, there is no record on the potential role of nutria (*Myocastor coypus*) or muskrat (*Ondatra zibethica*), which occupy the same habitats as beavers, in the epidemiology of stichorchosis in Croatia.

In the context of beaver protection and management in Croatia, further research on the presence and epidemiology of its parasites would be very helpful.

References

- Bona FV (1974) Skinning of cestodes of large sizes for whole mounts. Technical note. *Parasitologia* 16:257–259
- Drozd J, Demiaszkiewicz AW, Lachowicz J (2004) Endoparasites of the beaver *Castor fiber* (L.) in northeast Poland. *Helminthologia* 41:99–101
- Erickson AB (1944) Parasites of beavers with a note on *Paramphistomum castori* (Kofoid and Park, 1937) a synonym of *Stichorchis subtriquetrus*. *Am Midl Natl* 31:625–630
- Grubešić M (2004) Beaver (*Castor fiber* L.). In: Mustapić Z (ed) *Hunting* (in Croatian). Croatian Hunting Association, Zagreb, pp 107–109
- Hunting Act (1994) The Official Gazette of the Republic of Croatia No. 10/94 (in Croatian)
- Koubková B, Baruš V, Koubek P (2002) *Stichorchis subtriquetrus* (Digenea: Cladorchiidae)—back to the fauna of the Czech Republic after 200 years. *Helminthologia* 39:155–158
- McKown RD, Veatch JK, Robel RJ, Upton SJ (1995) Endoparasites of beaver (*Castor canadensis*) from Kansas. *Hemintol Soc Wash* 62:89–93
- McMaster RT, McMaster ND (2001) Composition, structure and dynamics of vegetation in fifteen beaver-impacted wetlands in western Massachusetts. *Rhodora* 103:293–320
- Skrjabin KI (1949) Trematodes of animals and humans—Osnovy trematodologii, vol 3 (in Russian). Academy of Science USSR, Moscow, Leningrad