



The suprapubic approach for laparoscopic appendectomy

O. Kollmar, K. Z'graggen, M. K. Schilling, B. M. Buchholz, M. W. Büchler

Department of Visceral and Transplantation Surgery, University of Bern Inselspital, 3010 Bern, Switzerland

Received: 7 February 2001/Accepted: 23 May 2001/ Online Publication: 4 December 2001

Abstract

Background: Because it produces superior cosmetic results, patients prefer laparoscopic appendectomy over open appendectomy. We developed two alternative laparoscopic routes of access to the abdominal cavity for appendectomy that use suprapubic incisions placed below the line of pubic hair. We then compared the results for these three different modes of access.

Methods: Operative characteristics, morbidity, outcome, and patient preference regarding three different approaches to laparoscopic appendectomy were compared in a retrospective study. In addition, a group of 24 healthy women were surveyed by questionnaire about their preferred technique and expected cosmetic results.

Results: Between January 1997 and August 2000, 149 patients underwent laparoscopic appendectomy and were assigned to undergo one of the three techniques. Operative results, morbidity, and hospital stay were similar. Twenty-five percent of patients submitted to technique 1 (no suprapubic trocars) were satisfied with their method, vs 54% of patients with technique 2 (one suprapubic port, angled working trocars) and 100% of patients with technique 3 (two suprapubic parallel trocars). Almost all patients (92% of those who had technique 1 and 100% of those who had techniques 2 and 3) chose the standard laparoscopic access as the cosmetically least attractive method. All of the healthy controls we interviewed preferred technique 3.

Conclusion: The placement of suprapubic trocars improves the surgeon's working position during laparoscopic appendectomy. A laparoscopic approach using two suprapubic trocars yields the best cosmetic results in the opinion of the majority of patients and healthy interviewees.

Key words: Appendicitis — Appendectomy — Laparoscopy — Cosmetic results — Ergonomics

Appendicitis is the second most common cause of acute abdominal pain requiring surgery [21, 25]. Since laparoscopic appendectomy was first described by Kurt Semm [25], the technique has been modified several times [3, 16, 24, 25]. Eventhough laparoscopic appendectomy has failed to gain unequivocal acceptance among general surgeons, it is well accepted at most centers [14]. Arguments against the laparoscopic technique include higher costs due to the need for disposable equipment, a longer operating time, and a higher incidence of complications, including appendix stump insufficiency and intraabdominal fluid collections [7]. However, the technique can be performed safely [3], and it has the advantages of producing minimal surgical trauma and making it possible to explore, irrigate, and clean the entire abdominal cavity [4, 17]. When a normal appendix is found, coexisting pathologies can be assessed [22]. Patients suffer less surgical trauma and thus require less analgesia during the postoperative course [20], they have an earlier passage of stool, and they resume normal activities earlier [6] with improved cosmetic results.

Laparoscopic appendectomy is most commonly performed through three ports. For special indications, one- or two-puncture techniques have been developed [11, 15], only occasionally does a fourth trocar need to be inserted. With standard technique, the video laparoscope is inserted through a periumbilical incision. Then a 12-mm port is placed through the left lower quadrant just lateral to the rectus muscle and a 5-mm port is placed in the right lower quadrant (technique 1). We have developed two alternative methods to position the trocars (techniques 2 and 3). The goal was to improve the posture of the surgeon in ergonomic terms while at the same time producing better cosmetic results for the patients.

Patients and methods

Between January 1997 and August 2000, 169 patients with clinical suspicion of acute appendicitis underwent laparoscopic appendectomy,

Correspondence to: K. Z'graggen

Table 1. Patient characteristics, operation time, and hospital stay according to operative technique

	Technique 1	Technique 2	Technique 3	Conversion ^a
No. of patients	98	27	24	20
Female / male	73 / 25	19 / 8	17 / 7	13 / 7
Age (yr)	28.3 ± 11.6	30.0 ± 10.2	31.2 ± 11.9	43.3 ± 18.5
Operating time (min)	62.4 ± 23.9	59.0 ± 22.4	48.1 ± 17.0 ^b	121 ± 48.3
Hospital stay (d)	3.7 ± 1.5	3.5 ± 1.2	3.8 ± 1.6	7.9 ± 3.4 ^c

^a Patients undergoing conversion to an open procedure are listed as a separate group. They are not included in the statistical analysis

^b p 3D 0.018 (T3 vs T1) and p 3D 0.013 (T3 vs T2)

^c p < 0.001 (T1–T3 vs conversion)

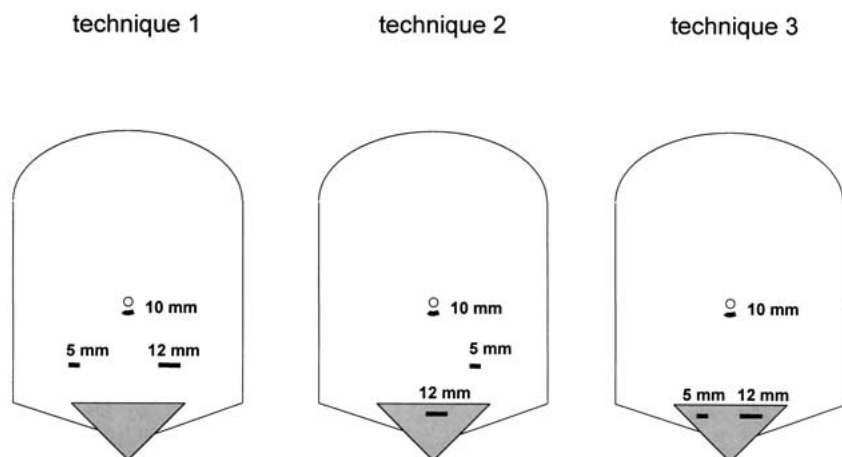


Fig. 1. Three different modes of access to the abdominal cavity (techniques 1, 2, and 3).

which in our department is done primarily in women. Twenty of these procedures were converted to an open technique. The remaining 149 patients were assigned to undergo one of three techniques for laparoscopic appendectomy according to the surgeon's preference (Table 1). Each technique was performed by at least three different surgeons.

The data were then analyzed retrospectively. Operative characteristics, postoperative complications, outcome, and the patients' ratings of the cosmetic preferability of the three techniques of laparoscopic appendectomy were compared. Patients were followed with a questionnaire for long-term complications and to determine their opinions of the three. Questions concerning cosmetic outcome and preference of trocar placement were identical to those given to the control group. Since we perform laparoscopic appendectomy predominantly in younger women, a group of 24 healthy women (age range 18–30 years) was surveyed with a standardized questionnaire concerning cosmetic preferences only. The group consisted of study nurses. Two of the 24 had previously had an appendectomy—one by an open procedure and the other by the laparoscopic approach in another surgical department (technique 1). The same basic information on possible trocar locations without stating technical advantages/disadvantages was given to the interviewees by one of the authors. Questionnaires were then filled out individually and mailed to the corresponding author (techniques 1–3).

Surgical technique

The operations were carried out under general anesthesia. Pneumoperitoneum was induced by the Hasson technique through a periumbilical incision. After introduction of the video laparoscope, patients were placed in a Trendelenburg position, tilted to the left, and the epigastric vessels were identified. Two additional working trocars were introduced under laparoscopic control. Choice of positions for the working trocars (i.e., technique 1, 2, or 3) was by surgeon's preference (Fig. 1).

The appendix was skeletonized by bipolar coagulation or clips and transected with an Endo-GIA (Johnson & Johnson, Cincinnati, OH, USA). It was then extracted with an Endo-Bag via the 12-mm operating port. In patients with a perityphlitic abscess or purulent fluid collec-

tions, the abdominal cavity was rinsed and a drain was placed through the right incision for 1–3 days postoperatively. After removal of the instruments and desufflation of the pneumoperitoneum, the fascia below the umbilicus and the three small cutaneous incisions were closed.

Statistical analysis

Patient characteristics, operating time, hospital stay, postoperative complications, and patient outcome were recorded in a database and analyzed retrospectively. Patients were followed for long-term complications with a questionnaire. They were also evaluated to determine their overall satisfaction with the procedure and its cosmetic result.

Data are given as mean ± standard deviation (SD) and analyzed using the Mann-Whitney U test. A p value of <0.05 was considered statistically significant.

Results

A laparoscopic approach to appendectomy was possible in 149 patients (88%)—109 female (73%) and 40 male (27%)—with a mean age of 29.1 ± 11.5 years. Seventeen cases (10%) were converted to open appendectomy and three (2%) to a median laparotomy. Indications for the conversion to an open technique included perforated appendicitis with intraabdominal abscess (eight cases), an abscess in the psoas muscle, a carcinoid of the appendix, and a pseudomyxoma peritonei (one case each).

Patient characteristics are listed in Table 1. The operating time was shortest in group T3 (48.1 ± 17.0 min) because one of the surgeons using technique 3 was particularly skilled and produced very low operation times. The difference in operation time for group T3 vs group

Table 2. Etiologies of patients undergoing laparoscopic appendectomy

Postoperative and histological diagnosis	Cases (n, %)	T1	T2	T3
Subacute appendicitis	11 (7)	7	2	2
Acute gangrenous appendicitis	74 (50)	47	13	14
Perforated appendicitis (partly with fibrino-purulent peritonitis and/or perityphlitic changes)	20 (13)	12	6	2
Other etiologies and normal appendix	44 (30)	32	6	6

Table 3. Morbidity and mortality after laparoscopic appendectomy

	Technique 1	Technique 2	Technique 3
Morbidity			
Wound infection	4	1	1
Hematoma of the rectus muscle	—	1	—
Retrocecal haematoma	1	—	—
Retrocecal abscess	1	—	—
Intraabdominal abscess	1	—	—
Total morbidity	7.1%	7.4%	4.2%
Mortality	0	0	0

Table 4. Cosmetic results and preference of technique in patients undergoing laparoscopic appendectomy and in healthy female controls

	Technique 1 (T1)	Technique 2 (T2)	Technique 3 (T3)	Interviewed controls
No. of patients	98	27	24	24
Female / male	73 / 25	19 / 8	17 / 7	24 / 0
Age (yr)	28.3 ± 11.6	30.0 ± 10.2	31.2 ± 11.9	21.3
Satisfaction with personal outcome	93%	93%	96%	—
Preference for (own) method	25%	54%	100%	T3 (100%)
Cosmetically least attractive method	T1 (92%)	T1 (100%)	T1 (100%)	T1 (100%)

T1 (62.4 ± 23.9 min, $p = 0.018$) and T3 vs group T2 (59.0 ± 22.4 min, $p = 0.013$) was significant. The length of hospital stay did not differ among groups T1, T2, and T3, but it was significantly longer in the group of patients who were converted to an open procedure ($p \pm 0.001$).

The histological diagnosis (Table 2) included 11 cases (7%) of subacute appendicitis; 74 cases (50%) of acute gangrenous appendicitis, partly with fibrino-purulent peritonitis; 20 cases (13%) of perforated appendicitis, partly with fibrino-purulent peritonitis and/or perityphlitic changes; and 44 cases (30%) of normal appendix. Of these 44 patients, 22 (15% of 149) had additional pathologies, including eight cases of adnexitis, one case of tuboovarian abscess, eight cases of ruptured ovarian cysts (one additional with endometriosis), and one case of endometriosis. Three patients had mesenteric lymphadenitis and one patient had sigmoid diverticulitis. In 11 patients with perforated appendicitis (Table 2) and one with a tubo-ovarian abscess, an abdominal drain was placed in the right iliac fossa and left for 1–3 days postoperatively. Drain volumes were 50–250 ml.

Ten patients (7%) had suffered postoperative complications (Table 3), including three cases of wound infection and three cases of wound hematoma (five of these six complications occurred at the periumbilical incision), as well as one case of a hematoma of the right rectus muscle caused by a working trocar. Three patients (2%) required relaparoscopy, with drainage of

one retrocecal hematoma, one retrocecal abscess, and one intraabdominal abscess causing small bowel obstruction. Most of these complications were seen in group T1, but there was no significant difference in comparison with groups T2 and T3. Hospital mortality was nil.

Although overall satisfaction with the operation was high in all groups, the results of the follow-up questionnaire (Table 4) showed a significant difference among them in terms of the cosmetic result. Twenty-five of patients in group T1, 54% of patients in group T2, and 100% of patients in group T3 preferred their own method and would recommend it to others. With few exceptions, patients (92% in group T1, 100% in group T2, and 100% in group T3) found technique 1, which was the one most commonly performed, the least attractive. Moreover, 100% of healthy female interviewees preferred technique 3 and described technique 1 as the cosmetically least attractive method.

Discussion

One argument in favor of laparoscopic appendectomy is its use of several mini incisions for cosmetic reasons instead of a standard 3–5-cm McBurney access, which is sufficient in the presence of a normal appendix position. In cases where the appendix position is unusual, in obese

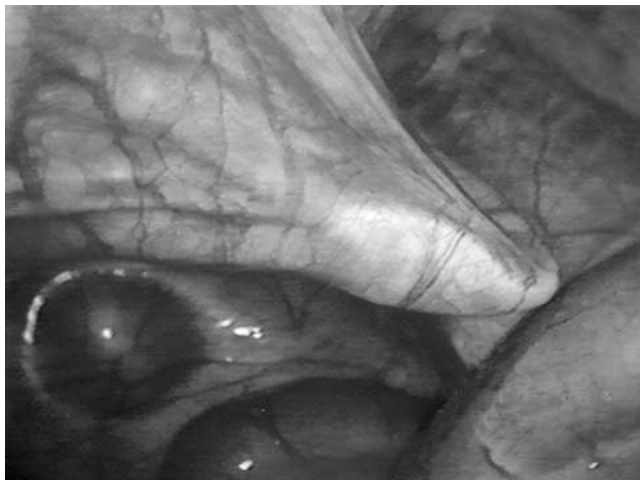


Fig. 2. Intraoperative view showing the placement of a suprapubic working trocar and demonstrating the typical tenting of the suprapubic peritoneum during its insertion.

patients, and when additional pathologies are found, a larger incision or a different access to the abdomen is needed [3]. During laparoscopy, all anatomical variants of the appendix can be visualized and the entire abdominal cavity can be explored for further pathologies.

Laparoscopy can increase diagnostic accuracy, especially in younger women, who frequently present with other causes of acute abdominal pain, such as adnexitis, ovarian cyst complications, endometriosis, and extra-uterine pregnancies [2, 18, 21, 22, 27]. Laparoscopy therefore increases the diagnostic accuracy of 67–90% [1, 5] reported for open appendectomy while also producing better cosmetic result [13].

The two-handed techniques presented here (techniques 1–3) can be performed by a single surgeon with the aid of one assistant. The standard technique (technique 1) is to use a video laparoscope through a periumbilical incision and two working trocars in the left lower and right lower quadrants. One disadvantage of this technique is that it requires the surgeon to stand in an ergonomically unfavorable position with one arm crossed over the patient's body. However, this problematical posture can be avoided by choosing different trocar positions. To maximize the surgeon's efficiency, an adequate distance needs to be maintained between the two working trocars so that the instruments will not become crowded and entangled [10, 19]. To improve ergonomics, we developed two techniques that allow a more parallel position of the surgeon's arms during the operation and an inferior approach to the cecum. Inferior access to the cecum by the instruments makes its mobilization easier and facilitates access to a retrocecal appendix.

Technique 2 places both working trocars at an angle of $\sim 60^\circ$ and therefore allows the surgeon to operate in an ergonomically favorable position [8, 9]. Technique 3, with an angle of $\leq 30^\circ$ requires some adjustment if the surgeon is positioned on the left side of the patient. However, we found that some of the difficulties with this technique can be avoided if the surgeon stands between the patient's legs (French position).

With the two alternative techniques (techniques 2 and 3), at least one trocar—preferably the 12-mm trocar for the stapler [26]—can be inserted below the line of pubic hair. This improves on the cosmetic result achieved with the standard laparoscopic approach. If two trocars are placed suprapubically, as in technique 3, a visible scar can be avoided altogether if the port for the video laparoscope is placed in the umbilicus. This, of course, gives an even better cosmetic result. In our series, the excellence of the outcome was verified through questionnaires sent to the patients and a control group of young healthy females (the demographic group that typically undergoes laparoscopic appendectomy in our department). Although almost all of our patients were satisfied with their cosmetic outcome, they still said that they would prefer technique 3, with no visible scars, if given the choice. The conventional method (technique 1) was rated as cosmetically less appealing and almost unanimously regarded as the least attractive alternative.

The placement of all trocars can result in a local hematoma of the abdominal wall, as occurred in one of our patients, but with careful transillumination this complication can be avoided. Insertion of suprapubic working trocars can be difficult because the suprapubic peritoneum is unusually flexible and typically results in tenting of the peritoneum before the trocar tip penetrates into the abdominal cavity (Fig. 2). Urinary bladder lacerations can be avoided with the routine use of urinary catheters; we did not encounter this complication in any of our patients.

Morbidity was comparable to that reported in the literature [12, 15, 28], and none of the techniques was associated with an increase in morbidity. Infectious complications occurred in 5% of our patients—six cases (4%) of wound infection and one case each (1.3%) of an intraabdominal and a retrocecal abscess. Relaparoscopy was performed in three of 149 cases (2%), including one patient with of a retrocecal hematoma. Although we drained the abdominal cavity in the majority of patients with perforated appendicitis, the intraabdominal complications were diagnosed by an abdominal CT scan and not on the basis of the volume or quality of drain fluid.

In summary, all three techniques are safe and achieve results that are comparable with those reported in the literature. Techniques 2 and 3 improve on the cosmetic results produced by technique 1. Patients and healthy controls overwhelmingly preferred a technique that leaves no visible scars. Because technique 2 is ergonomically more favorable than technique 1, we have started to use technique 2 as the standard mode of access for laparoscopic appendectomy, but we also recommend technique 3 for cases where a perfect cosmetic result is desired.

References

1. Chang FC, Hogle HH, Welling DR (1973) The fate of the negative appendix. *Am J Surg* 126: 752–754
2. Connor TJ, Garcha IS, Ramshaw BJ, Mitchell CW, Wilson JP, Mason EM, Duncan TD, Dozier FA, Lucas GW (1995) Diagnostic laparoscopy for suspected appendicitis. *Am Surg* 61: 187–189

3. Croce E, Olmi S, Azzola M, Russo R (1999) Laparoscopic appendectomy and minilaparoscopic approach: a retrospective review after 8-year's experience. *Surg Laparosc Surg* 3: 285–292
4. Cuschieri A (1997) Appendectomy: laparoscopic or open? *Surg Endosc* 11: 319–320
5. Deutsch AA, Shani N, Reiss R (1983) Are some appendectomies unnecessary? An analysis of 319 white appendices. *J R Coll Surg Edinb* 28: 35–40
6. Frazee RC, Roberts JW, Symmonds RE, Snyder SK, Hendricks JC, Smith RW, Custer MD, Harrison JB (1994) A prospective randomized trial comparing open versus laparoscopic appendectomy. *Ann Surg* 219: 725–728
7. Golub R, Siddiqui F, Pohl D (1998) Laparoscopic versus open appendectomy: a metaanalysis. *J Am Coll Surg* 186: 545–553
8. Hanna GB, Cuschieri A (1999) Influence of the optical axis-to-target view angle on endoscopic task performance. *Surg Endosc* 13: 371–375
9. Hanna GB, Shimi S, Cuschieri A (1997) Optimal port locations for endoscopic intracorporeal knotting. *Surg Endosc* 11: 397–401
10. Hugh TB, Kelly MD, Li B (1992) Laparoscopic anatomy of the cystic artery. *Am J Surg* 163: 593–595
11. Inoue H, Takeshita K, Endo M (1994) Single-port laparoscopy-assisted appendectomy under local pneumoperitoneum condition. *Surg Endosc* 8: 714–716
12. Klingler A, Henle KP, Beller S, Rechner J, Zerz A, Wetscher GJ, Szinicz G (1998) Laparoscopic appendectomy does not change the incidence of postoperative infectious complications. *Am J Surg* 175: 232–235
13. Lau WY, Fan ST, Yiu TF, Chu KW, Wong SH (1984) Negative findings at appendectomy. *Am J Surg* 148: 375–378
14. Memon MA (1997) Laparoscopic appendectomy: current status. *Ann R Coll Surg Engl* 79: 393–402
15. Ng PC (1997) One-puncture laparoscopic appendectomy. *Surg Laparosc Endosc* 7: 22–24
16. Nowzaradan Y, Barnes JP (1993) Current techniques in laparoscopic appendectomy. *Surg Laparosc Endosc* 3: 470–476
17. Nowzaradan Y, Westmoreland J, McCarver CT, Harris RJ (1991) Laparoscopic appendectomy for acute appendicitis: indications and current use. *J Laparoendosc Surg* 1: 247–257
18. Olsen JB, Myren CJ, Haahr PE (1993) Randomized study of the value of laparoscopy before appendectomy. *Br J Surg* 80: 922–923
19. Oppenheimer P, Weghorst S, Williams L, Ali A, Cain J, MacFarlane M, Sinanan M (2000) Laparoscopic surgical simulator and port placement study. *Stud Health Technol Inform* 70: 233–235
20. Ortega AE, Hunter JG, Peters JH, Swanstrom LL, Schirmer B (1995) A prospective, randomized comparison of laparoscopic appendectomy with open appendectomy. *Am J Surg* 169: 208–212
21. Pier A, Gotz F, Bacher C, Ibald R (1993) Laparoscopic appendectomy. *World J Surg* 17: 29–33
22. Schirmer BD, Schmiege RE, Dix J, Edge SB, Hanks JB (1993) Laparoscopic versus traditional appendectomy for suspected appendicitis. *Am J Surg* 165: 670–675
23. Schreiber JH (1987) Early experience with laparoscopic appendectomy in women. *Surg Endosc* 1: 211–216
24. Scott-Conner CE, Hall TJ, Anglin BL, Muakkassa FF (1992) Laparoscopic appendectomy: initial experience in a teaching program. *Ann Surg* 215: 660–667
25. Semm K (1983) Endoscopic appendectomy. *Endoscopy* 15: 59–64
26. Wagner M, Aronsky D, Tschudi J, Metzger A, Klaiber C (1996) Laparoscopic stapler appendectomy: a prospective study of 267 consecutive cases. *Surg Endosc* 10: 895–899
27. Welch NT, Hinder RA, Fitzgibbons RJ (1991) Laparoscopic incidental appendectomy. *Surg Laparosc Endosc* 1: 116–118
28. Zund M (1997) Status and outcome of laparoscopic appendectomy—results of a prospective study of 600 consecutive appendectomies. *Ther Umsch* 54: 505–509