

# Alveolar Echinococcosis of the Liver in an Adult with Human Immunodeficiency Virus Type-1 Infection

W. Zingg, E.C. Renner-Schneiter, C. Pauli-Magnus, E.L. Renner, J. van Overbeck, E. Schläpfer, M. Weber, R. Weber, M. Opravil, B. Gottstein, R.F. Speck, and the Swiss HIV Cohort Study\*

## Abstract

We describe a patient with human immunodeficiency virus type-1 (HIV) infection and alveolar echinococcosis (AE) with a focus on two messages.

Despite being severely immunocompromised over years the patient exhibited a long-term asymptomatic course of AE. This is in clear contrast to reports describing accelerated courses of AE in immunocompromised patients.

The patient had therapeutic mebendazole drug levels with only 1/10 of the normal drug dose. He was co-treated with protease inhibitors for his HIV infection. These drugs are known as strong inhibitors of cytochrome P450 3A4 (CYP3A4)-dependent metabolism. We speculate that benzimidazoles and protease inhibitors interfere at the CYP3A4-level.

The first report of co-infection of HIV and accelerated AE was in a young girl with an extremely low CD4 cell count and an abrogated lymphoproliferative responsiveness to parasite antigen stimulation. Since the CD4 cell count in our patient remained in the range of 27–150 cells/ $\mu$ l, we speculate that there was a critical threshold of immunosuppression for constraining AE. Initial treatment with albendazole for AE added to the current highly active antiretroviral treatment (HAART), and suppressive toxoplasmosis therapy became complicated by pancytopenia. After full recovery of the bone marrow, mebendazole was introduced with a new HAART and the previously prescribed toxoplasmosis maintenance therapy. Surprisingly, efficient mebendazole levels were achieved with an uncommonly low dose. These observations suggest that the benzimidazoles, albendazole and mebendazole, may interact with protease inhibitors, which are known for their strong inhibition of the CYP3A4.

Infection 2004; 32: 299–302  
DOI 10.1007/s15010-004-3134-9

\*The members of the Swiss HIV Cohort Study are: S. Bachmann, M. Battegay, E. Bernasconi, H. Bucher, Ph. Bürgisser, S. Cattacin, M. Egger, P. Erb, W. Fierz, M. Fischer, M. Flepp, P. Francioli, H.J. Furrer, M. Gorgievski, H. Günthard, B. Hirschel, L. Kaiser, C. Kind, T. Klimkait, B. Ledergerber, U. Lauper, M. Opravil, G. Pantaleo, L. Perrin, J.-C. Piffaretti, M. Rickenbach, C. Rudin, J. Schüpbach, R. Speck, A. Telenti, A. Trkola, P. Vernazza, R. Weber, S. Yerly.

## Introduction

Alveolar echinococcosis (AE) is caused by the fox tapeworm *Echinococcus multilocularis* (EM). Red foxes, and to a lesser extent domestic dogs and cats are the definitive natural hosts for EM, permissive to the whole replication cycle [1]. Man, infected by fecal-oral transmission, acts as an accidental intermediate host. The replication cycle cannot be completed and thus, the infection is not contagious. The incubation period is 5–15 years from infection to the development of clinical symptoms [2]. In about 88% of cases AE remains restricted to the liver and adjacent organs. In advanced stages it may disseminate to other organs such as lungs, kidneys, the central nervous system, or other sites. Clinical symptoms like unspecific abdominal pain and jaundice usually arise from the tumor-like, invasive growth of metacestodes in the liver. Lethality of natural AE reaches 94–100% within 10–15 years after diagnosis in untreated or inadequately treated human patients [3]. Nowadays, the lethality rate is much lower due to diagnosis of smaller AE lesions at an earlier stage and improved treatment strategies combining surgery and chemotherapy with benzimidazoles [4].

**W. Zingg, J. van Overbeck, E. Schläpfer, R. Weber, M. Opravil, R.F. Speck**  
(corresponding author)

Division of Infectious Diseases and Hospital Epidemiology, Dept. of Internal Medicine, University Hospital of Zurich, CH-8091 Zurich, Switzerland; Phone: (+41/1) 255 3775, Fax: -3291, e-mail: roberto.speck@usz.ch.

**B. Gottstein**

Institute of Parasitology, University of Bern, Switzerland

**E.C. Renner-Schneiter, E.L. Renner**

Division of Gastroenterology and Hepatology, Dept. of Internal Medicine, University Hospital of Zurich, Switzerland

**M. Weber**

Dept. of Surgery, University Hospital Zurich, Zurich, Switzerland

**C. Pauli-Magnus**

Division of Clinical Pharmacology and Toxicology, Dept. of Internal Medicine, University Hospital of Zurich, Zurich, Switzerland

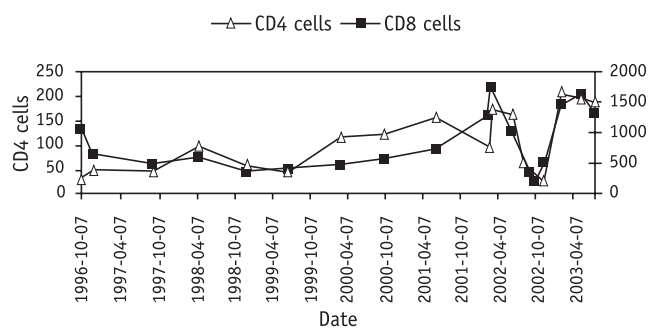
Received: September 5, 2003 • Accepted: September 23, 2003

The immunopathogenesis is still poorly understood. Case reports of a 6-year-old girl and several liver transplant recipients suggest rapid disease progression in immunocompromised patients [5–7]. Mice treated with cyclosporin A to induce experimental immunodeficiency and T cell-deficient athymic nude mice both showed accelerated AE [8, 9] when compared to immunocompetent wild-type animals. Data from other mouse experiments also pointed to a key role of the T helper type-1 responses [10].

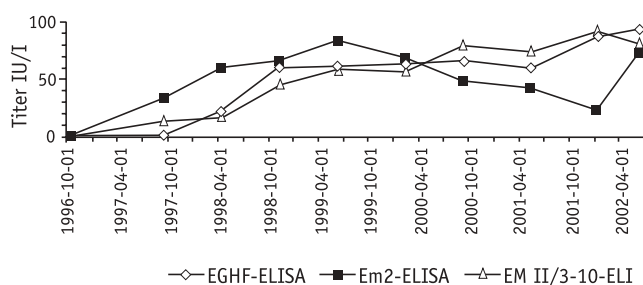
As outlined above, immunosuppression is suggested to be a poor prognostic factor for AE. In contrast, we present a case of an HIV-infected male patient with a strikingly long asymptomatic course of AE while being severely immunosuppressed.

### Case Report

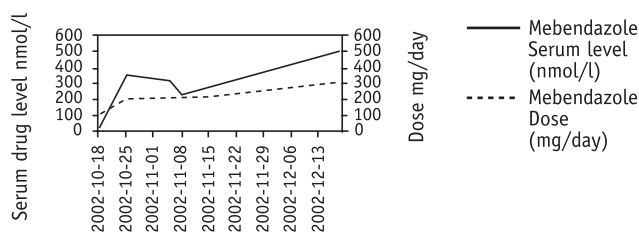
In this 40-year-old male patient, HIV infection was diagnosed in 1988 at the age of 26 years. In 1994 he suffered from a *Pneumocystis jirovecii* (formerly *Pneumocystis carinii*) pneumonia and disseminated tuberculosis, and in 1996 from cerebral toxoplasmosis. In the same year, the patient was started on antiretroviral therapy (HAART) with zidovudine (300 mg bid), lamivudine (150 mg bid), and ritonavir (600 mg bid). Therapy led to the complete suppression of HIV RNA within 11 months, whereas recovery of the CD4+ T cells was slow and their count remained in the range of 27 to 156 cells/ $\mu$ l over the next years (Figure 1A). In September 2001, HAART was discontinued because it was implicated in causing parotitis enlargement. In November 2001, the patient suffered from severe bacterial pleuropneumonia with *Streptococcus oralis*. The CD4+ T cells dropped to 28 cells/ $\mu$ l in the context of this acute event. HAART was reinitiated with zidovudine (300 mg bid), lamivudine (150 mg bid) and nelfinavir (1,250 mg bid). In February 2002, a CT scan was performed because of dull percussion on the right side of the back, revealing pleural thickening and an irregularly shaped tumor (10.5  $\times$  8  $\times$  9 cm) in the liver with central calcifications. This tumor compressed the right portal vein and the middle hepatic vein as shown 3 months later (Figure 2B). Based on this CT morphology, AE was suspected. Serology including EGHF-ELISA, Em2-ELISA (affinity purified EM Em2antigen) and EM-II/3-10-ELISA (recombinant cytoovillin-like protein of EM) were all positive confirming the diagnosis of AE [11]. The patient did not have pets but he had the habit of collecting green onions from forests in a region of known AE infected foxes. A lymphocyte proliferation assay, performed as previously described [12], provided a positive response as shown by a stimulation index of 9.1 (indices > 4.0 are considered positive). Radical surgery was not possible because of the location of the tumor and the patient was started on chemotherapy with albendazole (400 mg bid). Within 2 weeks after the initiation of antihelminthic therapy, marked pancytopenia (hemoglobin of 5.8 mg/dl, thrombocytopenia of 13 g/l and neutropenia of 0.33 g/l) developed. Zidovudine (300 mg bid), lamivudine (150 mg bid), nelfinavir (1,250 mg bid) and toxoplasmosis maintenance therapy (pyrimethamine/sulfamethoxazole) were stopped because of their potential contribution to pancytopenia. Full recovery of the bone marrow occurred within 10 weeks. Thereafter, HAART was changed to stavudine (40 mg bid), abacavir (300 mg bid), and lopinavir/ritonavir (400/100 mg bid), which are less likely to cause myelosuppression. Instead of albendazole, antihelminthic therapy was continued with mebendazole, another benzimidazole. Since a pharmacokinetic interaction was suspected to have contributed to the development of severe pancytopenia, mebendazole



**Figure 1a.** CD4 and CD8 cell counts from 1996 to 2003 while under HAART. While HAART resulted in undetectable HIV RNA, only a modest recovery of the CD4 cell count was noted over the observation period. The CD4 cell count was lowest during the time of pleuropneumonia and interruption of HAART.



**Figure 1b.** Serology markers for echinococcosis over the past 6 years. EGHF-ELISA is a screening test for *Echinococcus granulosus* and *Echinococcus multilocularis*. Em2-ELISA (affinity purified *E. multilocularis* Em2antigen) is specific for *E. multilocularis*. EM II/3-10-ELISA (recombinant cytoovillin-like protein of EM) can be considered as a marker for “viability” of *E. multilocularis*. In this HIV-infected patient, the simultaneous rise of all serologic markers of AE points to the progressive disease of AE and the viability of *E. multilocularis*.



**Figure 1c.** Therapeutic drug monitoring of mebendazole in this HIV-infected patient while co-treated with lopinavir 400 mg bid. The initial mebendazole dose of 50 mg was increased to 100 mg bid to get appropriate serum drug levels of 300 nmol/l and more. This dose, however, had to be adjusted to 150 mg bid because the drug levels dropped below 300 nmol/l over time. The actual mebendazole dose is still 150 mg bid.

plasma levels were carefully monitored after the therapy was initiated. Initial dose requirements were 1/20 of those normally used to achieve therapeutic plasma concentrations (Figure 1C). Therapeutic mebendazole plasma levels were reached after 6 weeks at a dose of 150 mg bid instead of the generally required 500–1,500 mg bid. No hematological abnormalities were observed. Six months later, an abdominal CT scan showed no disease progression. The patient continued to be asymptomatic.

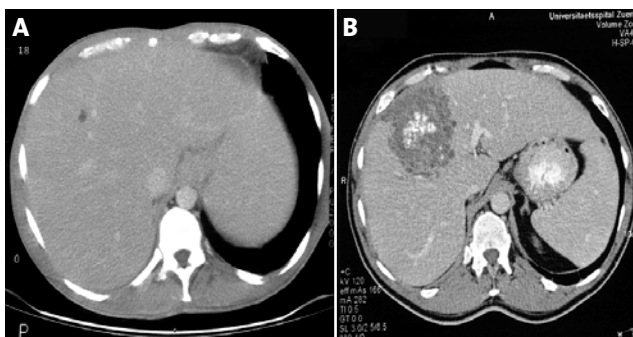
A review of a CT scan from 1994 showed a cystic lesion of 3 mm in diameter in the liver suggestive of AE (Figure 2A). Retrospective analyses of stored serum samples retrieved from the repository of the Swiss HIV Cohort Study showed negative serology in 1996, but from 1997 on antibodies against EM became positive and showed a trend towards higher titers until 2002 (Figure 1B).

### Discussion

We present the second published case of coinfection with AE and HIV. Strikingly, the course of AE in this HIV-positive patient was asymptomatic and remained so over 8 years. The CD4 cell count was very low during the entire period. Retrospectively, the first sign suggesting AE was a small cyst-like lesion in the abdominal CT scan in 1994. Serology at that time was negative, either because the patient was not yet infected or, more likely, was due to a delay in seroconversion upon low CD4 cell count at that time. Shortly after initiation of HAART, a moderate increase in the CD4 cell count was noted, including seroconversion and subsequently persisting seropositivity. Overall the course of AE in this HIV-positive patient, with an estimated average metacestode mass increase of 45 ml per year, ranged within standard course variabilities of AE in immunocompetent patients, where a volumetrically determined range of 4–220 ml annual size increase in non-treated AE patients has been reported [13]. Therefore the present findings are in contrast to the first report of coinfection of HIV and AE [5]. Thus, HIV infection alone did not seem to predispose to a rapid AE progression in this adult.

The main difference between the 6-year-old girl [5] and our patient is the humoral and cellular immune status at diagnosis. The girl proved to be seronegative at diagnosis and exhibited no response in the lymphocyte proliferation assay, whereas both tests were positive in our patient. This might be explained by the fact that at the time of diagnosis the girl showed an immune status with absent CD4 cells and thus was no longer able to react to infection, whereas our patient with reduced humoral and cell-mediated immunity was still competent to respond to the invading parasite.

Two weeks after the initiation of albendazole, our patient developed severe pancytopenia. Suspecting additive myelosuppression due to a pharmacodynamic drug interaction, all drugs were stopped. After full recovery, the anti-retroviral therapy was modified avoiding drugs with known bone marrow toxicity. Mebendazole instead of albendazole was given. Surprisingly, the patient showed adequate serum drug levels with minimal doses of mebendazole, 150 mg bid instead of the usual 500–2,000 mg tid (Figure 1C).



**Figure 2A.** CT scan of the liver done in 1994 and 2002. **A.** The liver CT scan from 1994 shows a small cyst-like structure in liver segment IV with a diameter of 5 mm without calcifications. Retrospectively, this lesion is highly suggestive of AE. **B.** The liver CT scan from 2002 reveals a hypodense lesion of 10 cm in diameter in segment IVa and IVb. The lesion is not well demarcated and has central calcifications.

Recent *in vitro* data in human liver microsomes indicated that the major route of albendazole biotransformation is oxidative metabolism via cytochrome P450 3A4 (CYP3A4) [14]. As albendazole is not a substrate of the drug efflux transporter MDR1-P-glycoprotein [15], extensive intestinal CYP3A4-dependent metabolism is a likely mechanism underlying poor oral bioavailability of albendazole.

Protease inhibitors such as nelfinavir and ritonavir are strong inhibitors of CYP3A4-dependent metabolism, while cytochrome P450 inhibition is not described for any of the other drugs taken by the patient. In the case of ritonavir, this property is used therapeutically to increase systemic exposure of drugs with low oral bioavailability such as lopinavir, through inhibition of intestinal and hepatic first pass metabolism [16]. Although formal proof through measurement of albendazole plasma levels is lacking, it can be speculated that inhibition of albendazole first pass metabolism by nelfinavir has significantly increased albendazole plasma levels. Given the dose-dependent myelosuppressive properties of albendazole, this pharmacokinetic interaction might be even more important for the development of pancytopenia than the additive myelosuppressive effect of the other drugs.

A significant pharmacokinetic interaction between benzimidazoles and HIV protease inhibitors is further supported by the finding of a significantly reduced dose requirement of mebendazole, which replaced albendazole in the latter course of the patient's history. Mebendazole is a structural analogue of albendazole. Similar to albendazole, mebendazole has a poor oral bioavailability and undergoes extensive intestinal and hepatic metabolism. Although the direct contribution of different CYP450 isoforms to mebendazole metabolism has not been studied in detail, cimetidine, a potent non-specific cytochrome P-450 inhibitor was shown to significantly increase mebendazole plasma levels [17]. Low oral bioavailability (2–10%) makes me-

bendazole particularly prone to drug interaction, which is in line with an initial dose requirement of 1/20 of the normal therapeutic dose under concomitant treatment with ritonavir/lopinavir. As ritonavir is known to induce CYP3A4 under long-term therapy, mebendazole dose requirements increased steadily, to finally reach a dose of 1/13 of that usually given.

In summary, we describe the case of an HIV-infected patient presenting with a long asymptomatic course of AE despite his being severely immunocompromised. In reviewing the favorable course of this disease, it is noteworthy that the patient exhibited both a positive serology and cellular responsiveness to parasite antigens at the time of diagnosis. Co-medication of protease inhibitors with mebendazole in this patient revealed a serious drug interaction of this drug with nelfinavir and ritonavir, which has not been described so far. Since we did not measure albendazole serum concentrations, there is no proof that the same drug interaction applies for all benzimidazoles. Although the mechanisms of this interaction remain to be fully established, physicians should be aware of this potentially life-threatening interaction and carefully monitor albendazole and mebendazole plasma levels under co-medication with CYP3A4-inhibiting drugs such as protease inhibitors, azole fungicides, or macrolide antibiotics.

### Acknowledgment

This study has been performed within the framework of the Swiss HIV Cohort Study, supported by the Swiss National Science Foundation (grant no. 3345-062041) and SNSF grant no. 31-63615.00.

### References

1. Ammann RW, Eckert J: *Echinococcus* and hydatid disease. In: Thompson, RCA, Lymberg AJ (eds): CAB International, Wallingford, UK 1995, pp 463–466.
2. Eckert J, Jacquier P, Raeber PA: Echinokokkose des Menschen in der Schweiz 1984–1992. *Schweiz Med Wochenschr* 1995; 125: 1989–1998.
3. Ammann RW, J Eckert: Cestodes: *Echinococcus*. In: Weinstock JV (ed): Parasitic diseases of the liver and intestines. Saunders, Philadelphia 1996, pp 655–689.
4. Pawlowski ZS, Eckert J, Vuitton DA, Ammann RW, Kern P, Craig PS, Dar KF, De Rosa F, Filice C, Gottstein B, Grimm F, Macpherson CNL, Sato N, Todorov T, Uchino J, von Simmer W, Wen H: Echinococcosis in humans: clinical aspects, diagnosis and treatment. In: Eckert J (ed): WHO/OIE manual on echinococcosis in humans and animals. WHO/OIE, Paris 2001, pp 20–71.
5. Sailer M, Soelder B, Allerberger F, Zaknun D, Feichtinger H, Gottstein B: Alveolar echinococcosis of the liver in a six-year-old girl with acquired immunodeficiency syndrome. *J Pediatr* 1997; 130: 320–323.
6. Koch S, Bresson-Hadni S, Miguet JP, Crumbach JP, Gillet M, Mantion GA, Heyd B, Vuitton DA, Minello A, Kurtz S: Experience of liver transplantation for incurable alveolar echinococcosis: a 45-case European collaborative report. *Transplantation* 2003; 75: 856–863.
7. Bresson-Hadni S, Koch S, Beurton I, Vuitton DA, Bartholomot B, Hrusovsky S, Heyd B, Lenys D, Minello A, Becker MC, Vanlemmens C, Mantion GA, Miguet JP: Primary disease recurrence after liver transplantation for alveolar echinococcosis: long-term evaluation in 15 patients. *Hepatology* 1999; 30: 857–864.
8. Liance M, Bresson-Hadni S, Vuitton DA, Lenys D, Carbillet JP, Houin R: Effects of cyclosporin A on the course of murine alveolar echinococcosis and on specific cellular and humoral immune responses against *Echinococcus multilocularis*. *Int J Parasitol* 1992; 22: 23–28.
9. Playford MC, Kamiya M: Immune response to *Echinococcus multilocularis* infection in the mouse model: a review. *Jpn J Vet Res* 1992; 40: 113–130.
10. Emery I, Liance M, Leclerc C: Secondary *Echinococcus multilocularis* infection in A/J mice: delayed metacestode development is associated with Th1 cytokine production. *Parasite Immunol* 1997; 19: 493–503.
11. Gottstein B, Jacquier P, Bresson-Hadni S, Eckert J: Improved primary immunodiagnosis of alveolar echinococcosis in humans by an enzyme-linked immunosorbent assay using the Em2plus antigen. *J Clin Microbiol* 1993; 31: 373–376.
12. Gottstein B, Mesarina B, Tanner I, Ammann RW, Eckert J, Wilson JF, Lanier A, Parkinson A: Specific cellular and humoral immune responses in patients with different long-term courses of alveolar echinococcosis. *Am J Trop Med Hyg* 1991; 45: 734–742.
13. Luder PJ, Robotti G, Meister FP, Bircher J: High oral doses of mebendazole interfere with growth of larval *Echinococcus multilocularis* lesions. *J Hepatol* 1985; 1: 369–377.
14. Rawden HC, Kokwaro GO, Ward SA, Edwards G: Relative contribution of cytochromes P-450 and flavin-containing monooxygenases to the metabolism of albendazole by human liver microsomes. *Br J Clin Pharmacol* 2000; 49: 313–322.
15. Merino G, Alvarez AI, Prieto JG, Kim RB: The anthelmintic agent albendazole does not interact with p-glycoprotein. *Drug Metab Dispos* 2002; 30: 365–369.
16. Kumar GN, Dykstra J, Roberts EM, Jayanti VK, Hickman D, Uchic J, Yao Y, Surber B, Thomas S, Granneman GR: Potent inhibition of the cytochrome P-450 3A-mediated human liver microsomal metabolism of a novel HIV protease inhibitor by ritonavir: a positive drug-drug interaction. *Drug Metab Dispos* 1999; 27: 902–908.
17. Schipper HG, Koopmans RP, Nagy J, Butter JJ, Kager PA, Van Boxtel CJ: Effect of dose increase or cimetidine co-administration on albendazole bioavailability. *Am J Trop Med Hyg* 2000; 63: 270–273.