European Archives of Oto-Rhino-Laryngology
https://doi.org/10.1007/s00405-018-5183-1

RHINOLOGY

Blunt nasal trauma in children: a frequent diagnostic challenge

Urs Borner[1] · Lukas Anschuetz[1] · Nadine Kaiser[2] · Alexander Rieke[3] · Patrick Dubach[1,4] · Marco Caversaccio[1]

Received: 24 September 2018 / Accepted: 22 October 2018

Abstract

Objective The clinical challenge in blunt nasal trauma in children, is to identify cases requiring specialized care among frequently encountered banalities, whilst trying to minimize the exposure to diagnostic procedures. We aim to evaluate the related diagnostic and therapeutic pathways and its outcome during follow-up.

Methods This retrospective cohort study includes children up to 16 years presenting at the emergency department with blunt nasal trauma of our tertiary reference center.

Results The incidence of blunt nasal injuries was estimated 1750 cases in 7 years. A total of 459 consecutive cases with suspected complications were enrolled. Univariate comparison between age groups revealed a statistically significant diminution of downfall related injuries with growing up, whereas blows (including violence) significantly increased with age ($p < 0.001$ each). The logistic regression model identified male sex as an independent risk factor for soft tissue lesions (OR 1.699, $p = 0.017$) and for frontobasal fractures (OR 2.415, $p = 0.050$). Age was not identified to play a significant role regarding localization of injuries. Delayed septorhinoplasties became necessary in 2 cases only (0.4%). The logistic regression model identified nasal bone fracture (OR 17.038, $p < 0.001$) and mandibular fracture (OR 4.753, $p = 0.004$) as independent risk factor for a surgical intervention.

Conclusions Blunt trauma to the nose is frequent in children. Trauma mechanisms differ significantly between age groups, whereas localization and concomitant injuries do not. Male sex was identified as an independent risk factor for soft tissue lesions and frontobasal fractures. In our experience, initial triage by the pediatric department with consecutive involvement of the ENT specialists in case of suspected complications is safe and effective and may help to reduce unnecessary diagnostic procedures/irradiation to the young patients.

Keywords Pediatric nose trauma · Complications · Outcome · Treatment · Nasal fracture · Closed reposition

Introduction

Children are frequently subject to blunt trauma to the nose of various etiologies. Most accidents are banal and do not require an emergency consultation or any diagnostic or therapeutic intervention. Associated midfacial fractures are rare [1]. Whilst management of high energy trauma injuries usually includes a computed tomography (CT) scan, some complicated sequelae related to minor trauma may be difficult to identify [2]. In this way, missed accompanying fractures or even severe soft tissue injuries developing without bone fractures such as septal hematoma may have deleterious consequences on the further development and function of the nose [3, 4]. The clinical challenge in this context, especially in children, is to identify lesions requiring specialized care which are not obvious, whilst reducing the exposure to diagnostic procedures for the affected children.

Urs Borner and Lukas Anschuetz are equally contributing first authors.

✉ Lukas Anschuetz
anschuetz.lukas@gmail.com

1 Department of Otorhinolaryngology, Head and Neck Surgery, Inselspital, University Hospital and University of Bern, Bern, Switzerland

2 Department of Pediatric Surgery, Inselspital, Bern University Hospital, University of Bern, Bern, Switzerland

3 Department of Radiology, Kantonsspital Graubuenden, Chur, Switzerland

4 Department of Otorhinolaryngology, Head and Neck Surgery, Burgerspital Solothurn, Solothurn, Switzerland

Published online: 31 October 2018

Pediatric craniomaxillofacial trauma is, according to a large retrospective cohort study with 3385 cases, most often related to play (58.2%), sport (31.8%), traffic accidents (5.0%) and acts of violence (3.9%) [5]. Moreover, an increased risk for fractures and soft tissue injuries related to traffic accidents was observed. In general, boys are more often subject to facial trauma. Additionally, the authors described a high incidence of dentoalveolar trauma [5]. Another study on 291 cases identified calvarian fractures in 54% and in 37% fractures of the upper and middle facial third. Concomitant injuries were observed in 32% of cases, mostly concussions of the brain [6].

However, little is known in literature about traumatic lesions of the nose. Due to the prominent position of the nose in the face, trauma mechanisms may be different. Moreover, nose deformities may have an impact on quality of life due to cosmetic and functional issues, even if caused by minor trauma. Some lesions may initially even not be visible or develop consecutively, as for instants septal hematoma, eventually leading to septal abscess with destruction of the septal cartilage. Though, children require a careful and systematic assessment in case of blunt trauma to the nose.

The aim of this study is to determine the frequency, characteristics and complications of blunt nasal trauma in children. Moreover, we wish to describe and discuss diagnostic and therapeutic pathways in the management of complicated nasal trauma.

Patients and methods

Ethical approval

Our institutional review board granted approval to conduct the present study (KEK-BE 2017-02122). Formal informed consent was not required to conduct this type of study.

Data collection

This retrospective cohort study includes all children up to the age of 16 years with suspected complications of nasal injury seen in the pediatrics emergency room of our tertiary referral center, over a time period of 7 years. Initially, during a representative observation period of 6 months all blunt trauma cases were analyzed ($n=125$). The total incidence of blunt nose trauma was thereafter estimated for the whole observation time ($n=1750$).

All cases ($n=459$) with suspected complications undergoing a radiological assessment or referral to an ENT specialist were enrolled in the present study. Medical records, imaging studies and follow-up visits were reviewed. Banalities not requiring further diagnostic or therapeutic interventions and with uneventful healing process were not further analyzed. However, all cases of post-traumatic complications initially deemed "simple" were included in the study.

Detailed results were calculated by dividing the whole cohort into four age groups: 0–4 years (group 1, $n=72$), 5–8 years (group 2, $n=83$), 9–12 years (group 3, $n=82$), 13–16 years (group 4, $n=222$).

Statistical analysis

Descriptive statistics were performed using GraphPad Prism. Statistical comparison between age groups were assessed using Chi-square tests with alpha set to 0.05. A logistic regression model was calculated to identify possible risk factors for surgical management.

Results

The overall incidence of blunt nasal injuries was estimated on 1750 cases in 7 years or 250 cases per year. A total of 459 consecutive cases with suspected complications (fracture, soft tissue lesion, intracranial complication, new onset of symptoms during follow up) were enrolled in the present study. Of those, 407 patients underwent radiological assessment (147 plain X-rays, 260 CT-scans). The mean age was 10.8 years (range 0–16 years) and we observed a predominance of male sex (62%; boys:girls 1.6:1). The distribution of males was different regarding the age groups: group 1 (0–4 years): 46%, group 2 (5–8 years): 58%, group 3 (9–12 years): 57% and group 4 (13–16 years): 71%.

Trauma mechanisms were identified as follows: impact/blows 31%, downfall 29%, traffic accidents 22%, sport related injuries 11% and other 6%. The distribution among age groups is graphically illustrated in Fig. 1. Univariate comparison between age groups revealed a statistically significant diminution of downfall related injuries with growing up, whereas blows (including violence) significantly increased with age ($p<0.001$ each).

The patterns of injuries of blunt trauma to the nose requiring a diagnostic and/or therapeutic intervention were (multiple possible): facial contusion ($n=170$, 37%), soft tissue lesions ($n=161$, 35%), nasal bone fracture ($n=159$, 34%), midfacial fractures ($n=136$, 29%), sinus fractures ($n=78$, 17%), frontobasal fractures ($n=32$, 7%) and septal hematoma ($n=4$, 0.9%). The distribution related to the age groups is illustrated in Fig. 2. We observed no statistically significant association between age groups. The analysis of injuries according to trauma mechanisms is summarized in Table 1. The logistic regression model identified male sex as an independent risk factor for soft tissue lesion (OR 1.699, $p=0.017$) and for frontobasal fractures (OR 2.415, $p=0.050$). Age was not identified to play a significant role regarding localization of injuries.

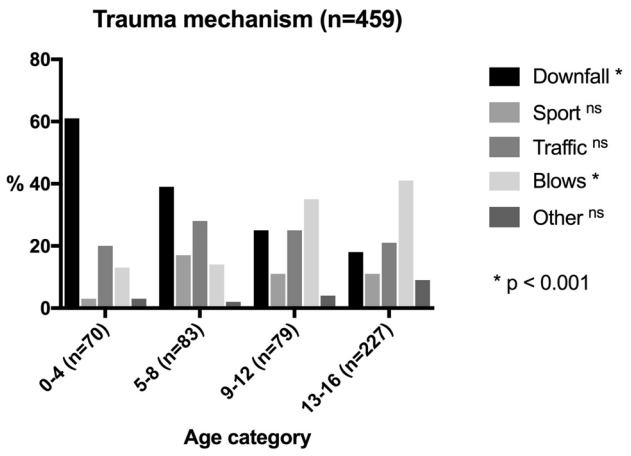

Fig. 1 Distribution of trauma mechanisms per age groups. Significant differences between age groups are highlighted (*). *Ns* no significant difference among age groups

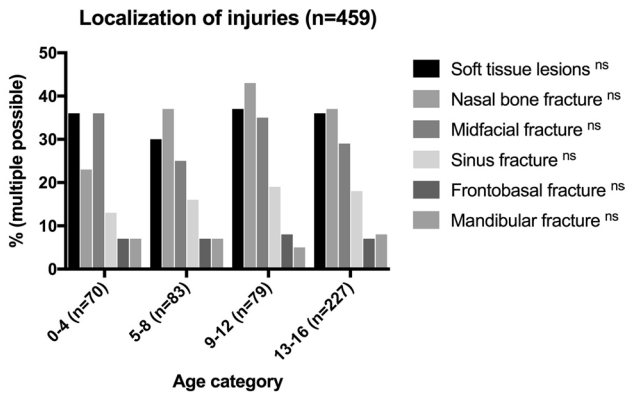

Fig. 2 Distribution of injury localization among age groups. For each trauma multiple injury localizations were assessed. *Ns* no significant difference among age groups

A total of 136 children required a surgical intervention related to the trauma. The most frequent intervention was closed reposition of nasal bone fracture ($n = 88$, 19% of the whole cohort). We observed a statistically significant increase in closed repositions with age. Surgical treatment due to septal hematoma was significantly more frequent in kids aged 0–4 years compared to the older age groups. Delayed septorhinoplasties became necessary in two cases only (0.4%) during the study period. The surgical therapy is summarized in Fig. 3. The logistic regression model identified nasal bone fracture (OR 17.038, $p < 0.001$) and mandibular fracture (OR 4.753, $p = 0.004$) as independent risk factor for a surgical intervention as illustrated in Table 2. No differences regarding the need for surgery among different trauma mechanisms was observed (data not shown).

Discussion

In this large cohort study on blunt nasal trauma in children we report trauma mechanisms, patterns of resulting injuries and required treatment. In line with previous literature on midfacial trauma, [5, 7] we observed a predominance of male sex, especially in age group 4. Moreover, almost half the cohort was made up of age group 4, which is believed to be related to a distinct tendency towards risk behavior, especially in men. In the same line we interpret the finding of male sex as an independent risk factor for frontobasal fractures, which are usually related to a high impact trauma. According to our analysis, this observation may also be explained by a statistically significant increase in injuries resulting from blows (including violence), where adolescent men are more frequently involved [8].

In parallel we observed a statistically significant decrease of injuries resulting from falls with growing up, which is the most common mechanism of trauma among children aged 0–4 years. In this age class, postural and gait stability are still developing, therefore, falls are the consequence of ongoing motor development. Most of these accidents result only in minor trauma without need for a medical consultation nor treatment [9].

However, in a large epidemiologic study with 21,533 children hospitalized for facial trauma, an increase in injuries related to falls was observed, with an associated mortality

Table 1 Analysis of localization of fractures (multiple possible) and trauma mechanism and multivariate linear regression analysis of age and gender regarding localization of injuries

	Soft tissue lesion	Nasal bone fracture	Midfacial fracture	Sinus fracture	Frontobasal fracture	Mandibular fracture
Downfall	23%	34%	16%	10%	6%	4%
Sport	54%	23%	36%	31%	8%	10%
Traffic	52%	21%	28%	27%	13%	15%
Blow	25%	21%	20%	14%	2%	3%
Other	24%	47%	17%	10%	14%	3%
Male sex	OR 1.699, $p = 0.017$	OR 0.888, $p = 0.579$	OR 1.581, $p = 0.066$	OR 1.701, $p = 0.059$	OR 2.415, $p = 0.050$	OR 1.458, $p = 0.368$
Age	OR 1.000, $p = 0.982$	OR 1.015, $p = 0.521$	OR 1.028, $p = 0.296$	OR 1.022, $p = 0.467$	OR 1.015, $p = 0.723$	OR 1.019, $p = 0.654$

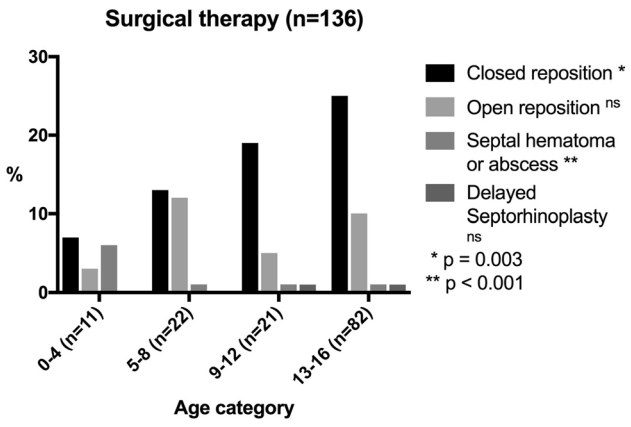

Fig. 3 Surgical therapy was necessary in 136 children. The distribution of the different interventions is shown by age groups. Significant differences between age groups are highlighted (*/**). *Ns* no significant difference among age groups

Table 2 Multivariate linear regression model comparing cases requiring surgery versus cases with conservative management by type of lesion

	Odds ratio	95% confidence interval	*p* value
Male sex	0.842	0.498–1.421	0.52
Age	1.047	0.984–1.112	0.145
Soft tissue lesion	2.547	0.927–6.995	0.07
Nasal bone fracture	17.038	9.281–31.268	< 0.001
Midfacial fracture	1.427	0.547–3.728	0.468
Sinus fracture	1.209	0.491–2.977	0.68
Frontobasal fracture	1.42	0.499–4.035	0.51
Mandibular fracture	4.753	1.659–13.618	0.004

of 2% [10]. Therefore, the prevention of falls has to be kept in mind by parents and professionals in child care and education. The information provided by this study regarding trauma mechanisms may be important for future preventive measures as they may be adapted to the concerned age group. Since any fall may result in a traumatic head injury, there is an ongoing debate, whether every downfall should be prevented. However, we have to keep in mind, that physical activity and, therefore, falls as consequence of inattention and immaturity are necessary for a healthy development of the kids and, therefore, not every injury may (or should) be prevented [11].

Interestingly, injuries related to sport and traffic accidents do not show statistically significant differences among the age groups in our cohort. This is in contrast to Bede et al., who observed an increase in sport and traffic related injuries with age [12]. Regarding the prevention of traffic accidents, Switzerland runs every year with beginning of school an extensive preventive campaign. The observed differences in traffic related trauma may be related to these preventive measures. Similar to our observation the authors also described a diminution of falls with growing up [12]. Another study identified fire arm injuries, motor vehicle accidents and violence as more frequent causes in older adolescence [13]. However, we have to note, that this study included patients up to 21 years of age, whereas our study population was younger than 16 years.

A special situation in the context of blunt trauma of the nose is septal hematoma and abscess. In our cohort, we observed a total of five cases (two hematomas and three abscesses), which were triaged as simple cases and discharged without specialist consultation. The two cases of hematoma consulted with a latency of 5 and 7 days after the initial trauma with a painful nasal obstruction and underwent surgical therapy. Three children presented after 7 and 10 days (two cases) after the trauma with septal abscesses with blocked nose and local pain. The formation of an abscess in our population was around the 7th day, while in the literature shorter latencies around 4.8 days are described [14]. It is thought, that abscess formation is a consequence of septal hematoma. However, the time needed of conversion from a hematoma to an abscess is unknown. Moreover, spontaneous or infectious etiologies have been reported [15, 16]. Moreover, delayed septal hematoma and abscess formation without obvious nasal bone fracture have been reported [17]. All our cases underwent immediate surgical drainage, which can be considered as the standard therapy [14–18]. Due to the possibility of late onset septal hematoma or abscess, it is important to adequately inform the patients about red flags such as de novo development of pain, blocked nose or fever after a symptom free interval of some days following blunt nose trauma. Moreover, we observed septal hematoma and abscess formation only in younger children. This may be related to anatomical particularities such as a more flexible nasal bone scaffold, eventually leading to increased shear pressures on septal vessels.

Multivariate analysis revealed nasal bone fracture as a main risk factor for a surgical intervention. The explanation of this observation may be the relatively uncomplicated treatment of dislocated nasal bone fracture. In fact, a closed reposition of the nasal bone is an easy way of restoring nasal roof symmetry. Closed repositions show a good efficacy with up to 81% of satisfaction regarding nasal symmetry among patients and parents [19]. A recent analysis in adults revealed, that the most frequent residual deformities are convex, especially in bilateral nasal bone fractures [20]. Even if not completely reduced, a nasal bone fracture may additionally improve in the 3 months following surgery by spontaneous rearrangement [21]. Although we did not specifically analyze the subjective outcome in our cohort, we observed only two delayed septorhinoplasties during the study period. Of course, this low number may underestimate

the real necessity for aesthetic of functional septorhinoplasties related to childhood nasal trauma.

In adults, the efficacy and safety of closed reductions has been postulated even in local anesthesia [22]. We observed, that in a cooperative adolescent patient, this type of intervention may be performed in local anesthesia with minimal morbidity as well. In our series, the youngest patient undergoing closed reposition in local anesthesia was 13 years old. However, in our experience the management should be discussed with the patient and the parents during an informative preoperative consultation offering both options: local versus general anesthesia.

There is an ongoing debate on the use of radiological imaging studies to detect nasal fractures, especially in children, where the exposure to ionizing radiation should be avoided wherever possible [23]. This is especially true in head imaging, as reported in a large cohort study by Chen et al. where one additional brain malignancy was suggested after 4000 brain CTs (40 mSv per scan). The estimated risk was one brain tumor per 10,000 patients less than 10 years old in the 10 years following CT exposure (10 mGy scan) [24]. Despite this knowledge, CT is increasingly used as reported by Oikarinen et al., up to 20% of scans of the paranasal sinuses are unnecessary, regarding the head this number goes up to 36% [25]. We also observed a high number of radiological imaging studies ($n = 214$) performed without prior specialist consultation and without therapeutic consequences as illustrated in Fig. 4. In some of these cases, plain X-ray was performed by private practitioners before referral to pediatrics. In our opinion, this number of useless irradiation can be reduced by prior specialist consultation in case of suspected complications. We have to keep in mind, that due to the inclusion criteria in our study we enrolled all children undergoing radiological imaging, resulting in a high prevalence of X-rays and CTs performed in the cohort. In this context, most of the CT scans have been performed to rule out intracranial hemorrhage. Moreover, if applied to the estimated cohort of 1750 cases, only 8.4% underwent a plane X-ray and 14.9% underwent a CT.

The challenge remains the depiction of complications associated to blunt nasal trauma without performing imaging for banalities. It is well known, that plane X-ray in the context of facial trauma in children is difficult to interpret and should not be performed anymore. Especially the state of art assessment of associated midfacial fractures is not feasible and, therefore, a CT is mandatory if serious complications of nasal trauma are suspected [26]. In the future digital volume tomography (DVT) may play a more important role, since the irradiation exposure is diminished compared to a conventional CT.

In our experience, in low impact trauma and with a proper clinical assessment, fractures of the nasal bone can be reduced without prior imaging with ionizing irradiation. In this context, the use of ultrasonography (US) to detect nasal bone fractures is deemed to be useful [27]. Although US is highly operator depended, it may be repeated without any deleterious consequences for the future development and health of the patient. Therefore, Tamada et al. recently

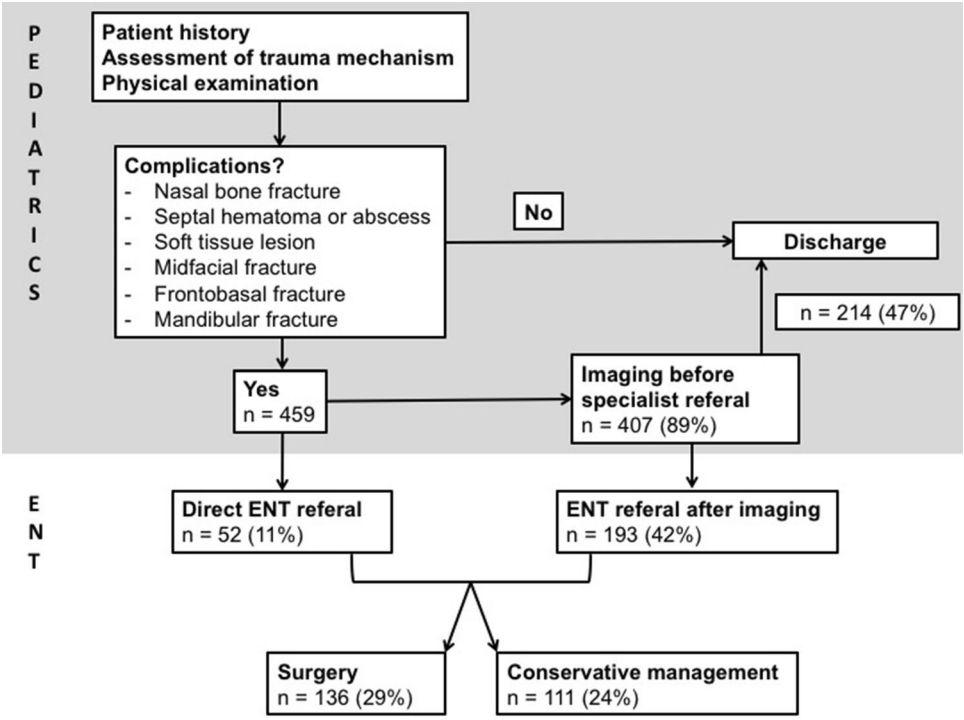

Fig. 4 Flowchart of study cohort. Note the high prevalence of radiologic imaging before ENT (ear nose troath) specialist consultation. Here, we identify some potential to reduce irradiation for the young patients

proposed an algorithm including repetitive US for pediatric nasal bone fractures. The algorithm was able to detect the majority of fractures [28]. Moreover, US would be an appropriate modality to assess intraoperative success of closed nasal bone reposition.

Conclusion

We identified statistically significant differences among trauma mechanisms between age groups, which is important for the planning of preventive measures. Moreover, we identified male sex as an independent risk factor for soft tissue lesions and frontobasal fractures. We observed a relatively high number of unnecessary radiological assessments prior to specialist consultation.

In our experience, initial triage by the pediatric department with consecutive involvement of the ENT specialists in case of suspected complications is safe and effective and may help to reduce unnecessary diagnostic procedures/irradiation to the young patients.

Compliance with ethical standards

Conflict of interest The authors declare no conflict of interest.

Research involving human and/or animal participants All procedures performed in this study involving human participants were in accordance with the ethical standards of the institutional, regional and national research committee and with the 1964 Declaration of Helsinki and its later amendments or comparable ethical standards.

Informed consent For this type of study, formal consent is not required.

References

1. Iizuka T, Thorén H, Annino DJ Jr, Hallikainen D, Lindqvist C (1995) Midfacial fractures in pediatric patients. Frequency, characteristics, and causes. Arch Otolaryngol Head Neck Surg 121(12):1366–1371
2. Simon B, Letourneau P, Vitorino E, McCall J (2001) Pediatric minor head trauma: indications for computed tomographic scanning revisited. J Trauma 51(2):231–237 **(discussion 237–8)**
3. Dispenza F, Saraniti C, Sciandra D, Kulamarva G, Dispenza C (2009) Management of naso-septal deformity in childhood: long-term results. Auris Nasus Larynx 36(6):665–670
4. Alvarez H, Osorio J, De Diego JI, Prim MP, De La Torre C, Gavilan J (2000) Sequelae after nasal septum injuries in children. Auris Nasus Larynx 27(4):339–342
5. Gassner R, Tuli T, Hächl O, Moreira R, Ulmer H (2004) Craniomaxillofacial trauma in children: a review of 3,385 cases with 6,060 injuries in 10 years. J Oral Maxillofac Surg 62(4):399–407
6. Eggensperger Wymann NM, Hölzle A, Zachariou Z, Iizuka T (2008) Pediatric craniofacial trauma. J Oral Maxillofac Surg 66(1):58–64 **(Review)**
7. Belechri M, Petridou E, Kedikoglou S, Trichopoulos D, Sports Injuries European Union Group (2001) Sports injuries among children in six European union countries. Eur J Epidemiol 17(11):1005–1012
8. Hoppe IC, Kordahi AM, Paik AM, Lee ES, Granick MS (2014) Age and sex-related differences in 431 pediatric facial fractures at a level 1 trauma center. J Craniomaxillofac Surg 42(7):1408–1411
9. Vyas RM, Dickinson BP, Wasson KL, Roostaeian J, Bradley JP (2008) Pediatric facial fractures: current national incidence, distribution, and health care resource use. J Craniofac Surg 19(2):339–349 **(discussion 350)**
10. Soleimani T, Greathouse ST, Bell TM, Fernandez SI, O'Neil J, Flores RL, Tholpady SS (2015) Epidemiology and cause-specific outcomes of facial fracture in hospitalized children. J Craniomaxillofac Surg 43(10):1979–1985
11. Brussoni M, Olsen LL, Pike I, Sleet DA (2012) Risky play and children's safety: balancing priorities for optimal child development. Int J Environ Res Public Health 9(9):3134–48
12. Bede SY, Ismael WK, Al-Assaf D (2016) Patterns of pediatric maxillofacial injuries. J Craniofac Surg 27(3):e271–e275
13. Allareddy V, Itty A, Maiorini E, Lee MK, Rampa S, Allareddy V, Nalliah RP (2014) Emergency department visits with facial fractures among children and adolescents: an analysis of profile and predictors of causes of injuries. J Oral Maxillofac Surg 72(9):1756–1765
14. Dispenza C, Saraniti C, Dispenza F, Caramanna C, Salzano FA (2004) Management of nasal septal abscess in childhood: our experience. Int J Pediatr Otorhinolaryngol 68(11):1417–1421
15. Tien DA, Krakovitz P, Anne S (2016) Nasal septal abscess in association with pediatric acute rhinosinusitis. Int J Pediatr Otorhinolaryngol 91:27–29
16. Cai Y, Saqi A, Haddad J Jr (2017) Spontaneous nasal septal abscess presenting as a soft tissue mass in a child. J Emerg Med 52(4):e129–e132
17. Dubach P, Aebi C, Caversaccio M (2008) Late-onset posttraumatic septal hematoma and abscess formation in a six-year-old Tamil girl-case report and literature review. Rhinology 46:342–343
18. Ambrus PS, Eavey RD, Baker AS, Wilson WR, Kelly JH (1981) Management of nasal septal abscess. Laryngoscope 91(4):575–582
19. Liu C, Legocki AT, Mader NS, Scott AR (2015) Nasal fractures in children and adolescents: mechanisms of injury and efficacy of closed reduction. Int J Pediatr Otorhinolaryngol 79(12):2238–2242
20. Nishioka H, Kondoh S, Yuzuriha S (2018) Convex bone deformity after closed reduction of nasal bone fracture. J Plast Reconstr Aesthet Surg 71(1):85–89
21. Lim H, Kang KR, Koh SH, Jung SW, Jung S (2017) Postoperative changes after closed reduction of nasal fracture. J Craniofac Surg 28(7):1649–1653
22. Ridder GJ, Boedeker CC, Fradis M, Schipper J (2002) Technique and timing for closed reduction of isolated nasal fractures: a retrospective study. Ear Nose Throat J 81(1):49–54
23. Brenner D, Elliston C, Hall E, Berdon W (2001) Estimated risks of radiation-induced fatal cancer from pediatric CT. AJR 176(2):289–296
24. Chen JX, Kachniarz B, Gilani S, Shin JJ (2014) Risk of malignancy associated with head and neck CT in children: a systematic review. Otolaryngol Head Neck Surg 151(4):554–566
25. Oikarinen H, Meriläinen S, Pääkkö E, Karttunen A, Nieminen MT, Tervonen O (2009) Unjustified CT examinations in young patients. Eur Radiol 19(5):1161–1165
26. Alcalá-Galiano A, Arribas-García IJ, Martín-Pérez MA, Romance A, Montalvo-Moreno JJ, Juncos JM (2008) Pediatric

facial fractures: children are not just small adults. Radiographics 28(2):441–61
27. Gürkov R, Clevert D, Krause E (2008) Sonography versus plain X rays in diagnosis of nasal fractures. Am J Rhinol 22(6):613–616. **[Erratum in: Am J Rhinol. 2009 Mar–Apr; 23(2):238]**
28. Tamada I, Mori T, Inoue N, Shido H, Aoki M, Nakamura Y, Kamogawa R (2017) An algorithmic approach using ultrasonography in the diagnosis of pediatric nasal bone fracture. J Craniofac Surg 28(1):84–87