Virchows Archiv (2018) 473:219–228
https://doi.org/10.1007/s00428-018-2369-2

ORIGINAL ARTICLE

Restoration of an academic historical gross pathology collection—refreshed impact on current medical teaching?

Philip Eichhorn[1] · Udo Andraschke[2] · Fritz Dross[3] · Carol I. Geppert[1] · Arndt Hartmann[1] · Tilman T. Rau[1,4]

Received: 25 January 2018 / Revised: 7 April 2018 / Accepted: 29 April 2018 / Published online: 10 May 2018

Abstract

The declaration of Leiden pronounces the demand to conserve pathological-anatomical collections as cultural heritage. Likewise, the Institute of Pathology of the Friedrich-Alexander-University Erlangen-Nuremberg owns macroscopic pathological-anatomical specimens reaching back over 150 years. The purpose of this work is to examine the impact, meaning, and perception of such historical preparations during the current medical curriculum. Additionally, the experiences from the renovation process can be used as a template for other institutes. All preparations were documented, photographed, and catalogued in an electronic database. During a restoration period, a series of didactically suitable specimens were professionally restored. Hereby, the help of a special course of interested students was admitted. In a second step, the specimens were integrated into the regular teaching of students in macroscopic pathology. An evaluation was carried out on two student cohorts with and without historical specimens by means of a questionnaire with 23 items and two free text fields. In total, 1261 specimens were registered covering diseases from almost the complete human body with a strong representation of the cardiovascular, urinary, gastrointestinal, and central nervous systems. Hereby, exceptional rare and untreated cases with medical relevance could be found and stepwise implemented into the curriculum. The student evaluation positively addressed that the courses became livelier and interactive. Furthermore, a more comprehensive overview and a better understanding of the macroscopic pathology were appreciated. However, more self-study time with the specimen was demanded. The authenticity of historical specimens contrasts with the tendency to carry out virtual "online" didactic methods. The stereoscopic view on often untreated and, therefore, unbiased cases enhances a skill-oriented deeper understanding of diseases. In conclusion, historical specimens regain interest and even didactic value, especially in an era of declining autopsy rates.

Keywords Macroscopy · Skill-oriented teaching · Historical collection · Survey · Autopsy

Introduction

In February 2012, an international conference on "cultures of anatomical collections" took place at the University of Leiden. The more than 130 highly decorated participants ranged from pathologists, anatomists, historians, cultural scientists, photographers, and artists. In an official declaration, they addressed central key issues for this incredibly rich but often neglected cultural heritage [21]. According to them, academic collections are often rendered inaccessible, are replaced by somehow newer teaching methods, are deprioritized, and, therefore, are exposed to permanent damage. Hence, they urged medical faculties to take all necessary measures to protect and preserve these collections of academic, medical, institutional, scientific, and cultural value.

The Institute of Pathology at the Friedrich-Alexander-University Erlangen-Nuremberg owns a literal smorgasbord of liquid-fixed specimens with only hand-written specifications

Electronic supplementary material The online version of this article (https://doi.org/10.1007/s00428-018-2369-2) contains supplementary material, which is available to authorized users.

✉ Tilman T. Rau
Tilman.Rau@pathology.unibe.ch

[1] Institute of Pathology, Friedrich-Alexander-University Erlangen-Nuremberg, Krankenhausstrasse 8, 91054 Erlangen, Germany

[2] Central Curator of Academic Collections, Friedrich-Alexander-University Erlangen-Nuremberg, Schlossplatz 4, 91054 Erlangen, Germany

[3] Institute of History and Ethics of Medicine, Friedrich-Alexander-University Erlangen-Nuremberg, Glückstrasse 10, 91054 Erlangen, Germany

[4] Institute of Pathology, University Bern, Murtenstrasse 31, CH 3008 Bern, Switzerland

exactly falling under these considerations. To meet the raised obligations, we ask in a first step, whether and where a surplus for pathology as an autonomous modern academic discipline can be achieved during occupation with such historical specimens. Three elements may be of particular importance: the visibility of the collection as an institutional ornament, the basis for current research projects, and the educational value for medical students and residents.

Indeed, the web presence of pathological collections is given worldwide. It is best fulfilled where the specimens are incorporated into museums. Well-known international examples are the Hunterian Museum by the Royal College of Physicians in Glasgow, the Narrenturm in Vienna, or the Vrolik Museum in Amsterdam [33]. How strongly medical museums influenced pathology as a discipline is highlighted in the seal of the International Academy of Pathology (IAP). Beside the microscope, the globe and the lamp of wisdom the lettering "IAMM 1906" is illustrated, which refers to the International Association of Medical Museums founded by Maude Abbott from McGill University in Montreal in 1906. The IAMM was the direct predecessor to the IAP launched in 1955 [9]. Some roots or remnants of medical museums can still be found in many academic institutions. As a consequence, more and more institutes of pathology present their collections or related projects, e.g., within larger networks of academic collections [39, 41].

All these visible institutions transport insight to human pathology to a broad public, and they set standards (e.g., for ethics of human remains in museum collections or preservation techniques and can serve as partners for smaller institutions). In our case, the Berlin Museum of Medical History provided excellent technical support.

Pathological collections were and still are the basis for current research projects. Publications for the scientific audience are often designated to certain collections [2, 4, 22, 26, 31, 34–36]. Additionally, re-classifications of ancient diagnoses can enhance the reflections about current entities. This was, for example, performed on the historical collection of epithelioid cell-rich lymphomas of the Kiel Lymph Node Registry [15]. Furthermore, the accessibility to modern immunohistochemical or molecular techniques on historical long-term preserved fixed tissues [17] are tested in terms of biobanking. Hence, actuality of historical collections is given as a research tool for particular questions.

Our main focus ends up in the third aspect—the possible didactic suitability for gross pathology. Using illustrative material during medical teaching is a crucial necessity, but for pathology challenged by the decline of autopsy rates worldwide [12]. With our didactic project, we wanted to completely index and substructure the historical pathology collection of the Friedrich-Alexander University Erlangen-Nuremberg, restore relevant specimens, integrate the historical collections into the current curriculum, and assess feedback of the students with and without historical specimens.

Materials and methods

Index of the historical collection

In a first step, we defined the elements for a complete catalog of the 1261 existing historical specimens. We created 32 separate items (Fig. 1) to cover historical, medical, didactical, preservational, or taxonomical aspects in a structured and searchable way. Herein, standardized photography from three perspectives with a chromaticity diagram was essentially integrated.

Provenance research

Identification of any possible identifiers as labels on the glass vials was documented. The majority of cases were directly or potentially assigned to definite patients' histories, which are still accessible in collaboration with the archive of the Friedrich-Alexander-University Erlangen-Nuremberg. Hereby, chances to identify the specimen not primarily assigned exist as well. A screening for possible contexts of injustice was performed during indexing all specimens, which is a must especially for a German historical collection of human remains. Additionally, the time points of construction were analyzed and linked to the pathologists in charge for each period. Individual and more detailed object histories were created during the later mentioned voluntary course together with the students. Additionally, an interdisciplinary approach together with historians and the curator of the Friedrich-Alexander-University Erlangen-Nuremberg was initiated to further deepen the knowledge about the specimens' provenance.

Restoration process

In total, 325 specimens were selected for the restoration process. The stepwise procedure is exemplarily depicted in Supplemental information 1. According to archival data, the specimens were mainly fixated in Kaiserling's solution (Table 1). The strong discoloration of the specimen and the liquid's turbidity over the years indicated that only complete substitution of the fixatives would be appropriate. In collaboration with the preparators of the Virchow's collection in Berlin, we decided to use Jore's II solution as a water-based and cheap permanent storage solution (Table 1). This was in advantage to formalin, which would become corrosive over time due to its oxidation to formic acid, or alcoholic solutions, which would result in further color bleaching. In some cases, color enhancing could be achieved with Romhányi's solution (Table 1).

Two-step embedding in medical education

The first step consisted of a voluntary course providing credits ("Wahlpflichtkurs") offered to interested students to take a practical part in the work of the preparators. They selected

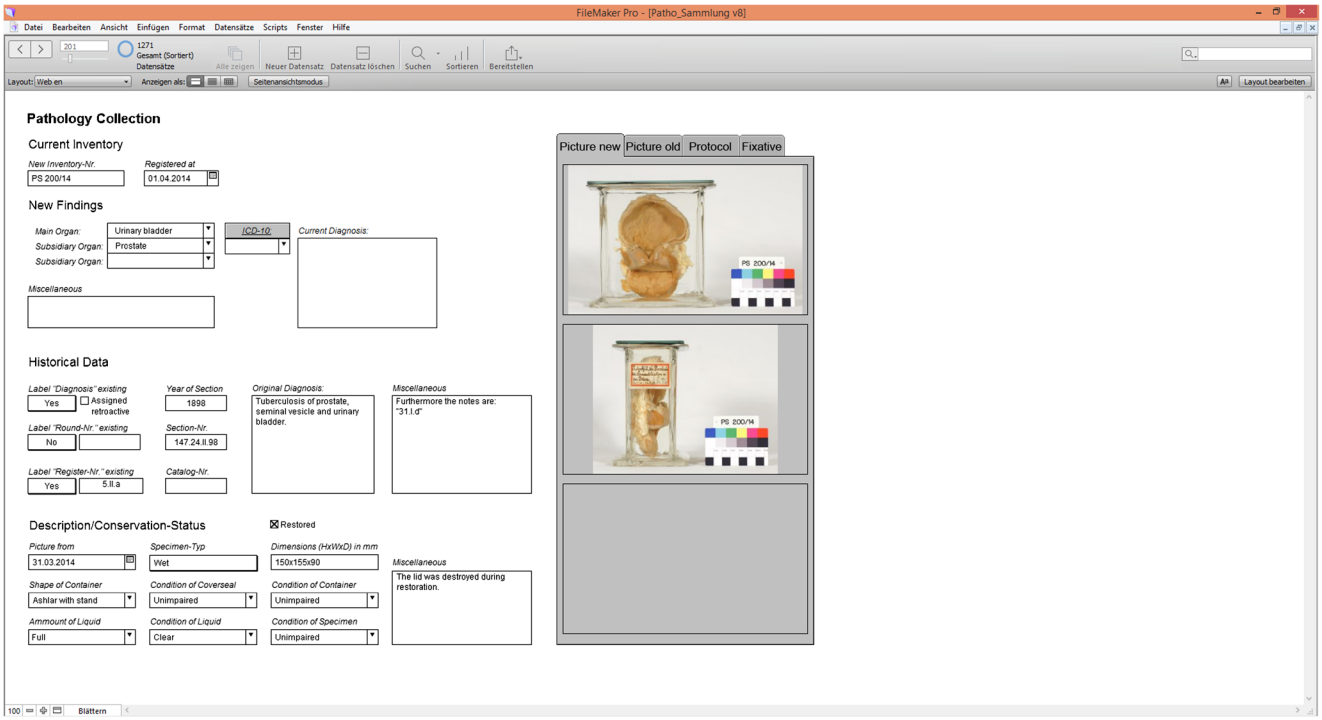

Fig. 1 Overview of the database surface. Elements were grouped into different perspectives (e.g., historical dimensions, conservational aspects, and current registration). Standardized photography was integrated with simple methods (e.g., chromaticity diagram for color calibration [asterisk])

specimens of interest and were instructed, in an accompanied seminar, to review the aforementioned multi-dimensional perspectives on the specimens. This way, corporate statements between the lecturers and students were achieved regarding the suitability for the regular medical curriculum. In a second step, the historical specimens enabled a restructuring of the third year macroscopy course by subject matter and historical specimens were regularly presented in the lessons to enquire pathological alterations in different organs.

Evaluation

In a structured survey, we asked the students 23 questions in multiple-choice format and two open questions before and after the integration of historical specimens in the classes. According to established academic didactic evaluation parameters, we considered validity, reliability, and objectivity as crucial points of the survey design and respected the standards of the German Society of Evaluation (DeGEval) [5]. In detail, we gathered information from the students, the lecturers, the course, and the use of the multi-media demonstration materials followed by a possibility for open remarks. The possible answers were constructed 5-scaled to allow an intermediate position as well as an additional opt-out solution.

Statistics

Results from the survey were corrected for the ordinal data set—excluding the unspecified or neglected data points given by the students. Histograms were used to compare the two independent

Table 1 Distribution of the organ systems across the collection

Solution	*Kaiserling's*	*Jore's I*	*Romhányi's*	*Jore's II*	*BMM's*
Function	Fixative	Fixative	Fixative	Preservative	Preservative
Composition	1000 ml distilled water 200 ml concentrated formaldehyde solution 50 g potassium acetate 25 g potassium nitrate	1000 ml distilled water 50 ml concentrated formaldehyde solution 50 g Carlsbad salt 50 g Chloral hydrate	1000 ml distilled water 30 ml concentrated formaldehyde solution 7 ml concentrated pyridine 5 g potassium nitrate 20 g Sodium dithionite	1000 ml distilled water 600 ml glycerine 300 g sodium acetate	1000 ml distilled water 55.10 ml concentrated formaldehyde solution 100 g potassium acetate 83.3 ml glycerine 10 g Sodium dithionite
Modification				1 g Phenol	

groups with and without historical specimens in its shape of distribution. Afterwards, non-parametrical Mann-Whitney *U* tests were performed. *P* values < 0.05 were regarded as statistical significant. SPSS 21 (IBM, USA, NY) was used for analysis.

supplemental information 1) were long washing periods, careful trimming of fungal decay (if present), and use of Jore's II solution as a permanent fixative (due to its inflammable and noncorrosive character in contrast to alcohol and formalin, respectively).

Results

Imminent endangerment of the historical specimen

An overview of the condition of the complete collection is outlined in Fig. 2. The highest risk for liquid-fixed specimens represents evaporation, as this might alter the composition of the fixatives. Hence, fissuring of the glasses and broken seals might desiccate the specimen permanently. Restoration of such cases was almost impossible, but still, the substitution with fresh fixatives might stop further decay. Obfuscation of the fixatives alone might be caused by oxidation over time and dissoluble tissue-immanent tints. These changes were considered moderate (Fig. 2c), as they were completely reversible. Essential steps of a successful restoration process (in detail as

Medical relevance of the samples in overview and particularity

The legendary "red rust-dust lung" of Friedrich Albrecht Zenker was the prototype of pneumoconiosis, on which he coined this term in 1867 and casually co-founded the discipline of occupational medicine (Fig. 3a, b) [40]. Beside such exceptional specimens, other rare tumors and conditions are seen like cholecystoduodenal fistula in long-term cholecystolithiasis (Fig. 3c, d). Untreated cases are the rule, which give a good impression about the course of cancerous or infectious diseases (e.g., tuberculosis) (Fig. 3e, f). The distribution of all specimens to certain organ systems is presented in Table 2 and can cover a wide spectrum of tumorous, infectious, metabolic, or developmental pathologies.



Fig. 2 Specimen of a so-called "gelatinous" colorectal carcinoma before (**a**) and after (**b**) restoration. The obstruction of the bowel in this 14-year-old boy with subsequent megacolon and peritoneal effusions is only appreciable after substitution of the fixatives of the primarily moderately endangered sample. Histology was accessible during this preparation due to minuscule tissue trimming of floating edges and revealed a signet ring cell carcinoma opening the didactics about hereditary colon cancer in class. Limited resources led to the choice of didactic suitable specimens. However, a shift from strongly endangered to intact samples (**c**) could be achieved. Unfortunately, some of the restored specimens showed obfuscation after a few weeks impairing its perfect perception again to a moderate level

Overview of provenance aspects and timelines of their generation

The transfer of standard present-day ethical considerations (e.g., consenting of the patient or his/her relatives) can hardly be applied to former times with different socio-cultural practices. Interdisciplinary scientific communities have elaborated solutions for these scenarios. Essentially, the provenance of the human remains has to be illuminated. Up to 62.5% of the specimens can be linked to patient histories still available in the archives of the university. Vice versa, data given in the archive also bore the chance to identify some of the remaining preparations. Particularly for a German collection, whose generation time included the dark period of the Nazi regime, but also for other conditions (e.g., executions, war, and accidents) contexts of injustice have to be excluded. Among the identifiable objects, 10.1% were constructed during the relevant periods of both world wars, but none of the maintained objects displayed an evident circumstance of an academic misconduct during the cataloguing process. Beyond this summarized view, the individual history of each specimen has to be followed for a more precise provenance research. This was covered with every step towards an opened presentation (e.g., students' teaching or even public audiences) with an utmost transparent object history.

Aesthetics, clarity, and craftsmanship of the preparation techniques

The main difference with regard to actual grossing techniques was the non-destructive processing, but demonstrating approach. Sectioning of the organs consisted of sagittal, longitudinal, fenestrating, oblique, or transversal sectioning to pronounce the pathological finding (Fig. 4). Cavernous organs like the heart, stomach, and bladder were obviously replenished during fixation to maintain their form. Arrangement in the glasses consisted of stitching to blackened carriers for better contrasts, clamping with oblique glass layers, and highlighting with arrows or needles. Very particular preparations used the updrift to stretch specimens by use of corks and sinkers (Fig. 4a, b).

Challenges of historical taxonomy

Of note, an update of the historical taxonomy before implementation into current teaching was necessary. Terms like "gelatinous adenocarcinoma" were translated to mucinous colorectal carcinoma or a "chronic gastric catarrh" would most likely be translated into reactive gastropathy or type C gastritis. Some terms like "carcinogenous scirrhus" could not be solved with macroscopy alone, but could give ideas about the history of terminology as well as the history of nosology and medical thought in general, which helps to explain current terms like liver cirrhosis.

Didactic suitability and change effect to medical courses

From the teachers' point of view, the historical specimens provided an additional didactic approach besides that of PowerPoint presentations, fresh specimens from the surgical theater or the blackboard. This was especially true with skill-oriented techniques (e.g., applied anatomical knowledge) where descriptions of relevant macroscopic findings could be exercised. To gather knowledge from the students' point of view, a structured evaluation was performed. Students from the course without historical specimens ($n = 126$, 76% of the class) and students of the class from the course with historical specimens ($n = 147$, 82% of the class) gave their feedback.

Both cohorts were comparable in terms of own interest and invested time of the students in the course. Regarding the perception of the lecturers, the students connoted significantly ($p < 0.01$) the challenges of intensified scheduling time, course contents, and the focus on the students' needs. These represented expected changes for the launch of a new didactic method. Best values could be achieved for the improvement of the structure of the course. Topics were significantly better defined and coordinated with the use of historical specimens ($p < 0.001$). The richness of the different didactic materials was positively addressed by both cohorts and was further quantified. Interestingly, the distribution of the used types of media was approximately put in thirds or fourths, insofar as fresh specimens, power point presentation, and the blackboard were complemented with the historical specimens as a fourth option. Fresh specimens—directly derived from the surgical theater (or autopsies)—are favored by the students. However, the suitability of the historical specimens to train skills in macroscopic pathology strongly exceeded power point presentations and the blackboard. In such a way, the votes for the most useful techniques for diagnosis assessment were 45% for fresh specimen, followed by 31% for historical specimens, 19% for Power Point presentation, and 4% for the blackboard. The choice of selected preparations for didactic purposes was improved substantially with the ancient items. Hence, not only frequent and relevant diseases were presented, but also rare entities leading to a significantly broader spectrum of diseases and a general improvement of the scope of the course ($p < 0.001$). Of note, the pace of the course was addressed to be higher with historical specimens ($p = 0.003$) and the students were stimulated to ask for more time for self-reliant training.

Thus, the historical specimens changed the teaching quality in many facets. Even more detailed, the free text answers showed a deeper interest to the subject and a stronger demand for self-study time with the historical objects.

Discussion

The use of illustrative material for academic didactics is linked to the roots of universities themselves. Pathological-anatomical preparations in students' courses and immediate teaching of pathology on the human body reach long back in history even to hallmarks like the foundation of our discipline by Giovanni Battista Morgagni in 1761 [13]. With the development of fixation techniques by Kaiserling and Jores in parallel in 1896, the possibilities for pathological collections improved substantially [19]. The notion was to preserve human pathology over time, but exposed it to social, legal, ethical, economical, and technical

◀ **Fig. 3** Three attributes to the historical specimen can be found. Exceptional (**a**, **b**) samples of the disease-defining iron dust lung, which Friedrich Albert Zenker head of the Institute of Pathology in Erlangen published in 1867. He could overcome Virchow's idea of endogenous black lung pigment by the simple observation of red dusts creating red lungs and let him coin the term "pneumonokoniosis"; and hence, somehow, cofound the medical discipline of occupational medicine. Rare (**c**, **d**) conditions like the fistula of a gallstone to the duodenum can be hard to understand for medical students. Especially when they are confronted with the symptomatic triad of a radiologic concrement, aerobilie, and a mechanical ileus. By means of applied pathological anatomy on such elaborated specimens, these conditions are easily explained. Untreated (**e**, **f**) specimen like this tuberculosis of the pericard with a thick pannus coating the serous walls and the surface of the heart shows a possible natural end-stage of this disease. Tuberculosis still represents a worldwide burden with severe mortality. Antibiotics, chemotherapies, and other remedies might trivialize the inherent aggressive pathology of a wide spectrum of diseases even in autopsies nowadays

changes as well. Today, the existence and perception of such pathological collections have tremendously altered. The recent claims of the declaration of Leiden on "human anatomy/anatomical collections" are pronounced, but no information for concrete handling and dealing with such historical specimens is provided. With our study, we want to share our experiences of successful restoration and reimplementation of a historical collection to the curriculum. Ideally, it might be a first template in terms of a user guide to re-establish a capacity to act in other institutes of pathology.

The main sources for pathological collections are the decades of intense autopsy practice before the distribution of photography and other presentation techniques. Today, the decline of the non-forensic clinical autopsy is a worldwide phenomenon. In a meta-analysis covering data from several European countries, Australia, Jamaica, and the USA, relentless reduction rates between at least 9.0 and 31.1% are outlined [6]. Detailed reports from single centers parallel these concerns [3, 7, 27, 38] and even proclaim an almost extinction of this medical ancillary tool for many reasons [6, 23, 32, 37, 38].

Table 2 Distribution of the organ systems across the collection

Organ	*Number*	*Percentage*
Cardiopulmonary system	232	18%
Urology	219	17%
Gastrointestinal system	184	15%
Neurology	154	12%
Skeleton, muscles, and skin	120	19%
Gynecology	74	6%
Lymphatic system, spleen and bone marrow	65	5%
Ear, neck, and throat	58	5%
Other	20	2%
Not recognizable	135	11%

Regarding this, we like others to notice tremendous educational consequences from the lack of illustrational material derived from autopsies for pathology [1, 6]. In our example, the curriculum of the medical faculty at the Friedrich-Alexander-University Erlangen-Nuremberg foresees a skill-oriented "grossing" course for undergraduate students in their third year. The inevitable shift from organs derived from autopsy to ones from surgery subtly altered the concept of the lesson. To name some major aspects of an aggravated didactic quality, we realized difficulties in matching the spontaneous entrance of surgical specimens to the gradually organized timetable and arrangement of pathological topics. Redundancy became heavily evident and the lecturers pronounced a need for a didactic collection of macroscopic specimens. Additionally, most of the surgical specimens had an oncological background and omitted infectious, metabolic and cardiovascular diseases. Hence, teaching pathology in an academic context lost its claim as a universal tenet of diseases of all kinds. Luckily, the heritage of the Institute of Pathology comprises a remarkable historical collection of macroscopic specimens in liquid fixatives, which we tried to resuscitate for teaching as a possible compensation.

Having access to an institutional academic pathology collection was an advantage, but raised uncertainties about practical handling and restoring. Particularly, there exists only sparse literature about this topic beyond the historic original publications some of them in this journal [18]. In 1989, Kessler summarized in a German publication for preparators very detailed information about the chemical processes and optimized results of coloring, which can be underlined by our own experience [19]. It remains essential to understand the fixation process of the tissue for a long-term exhibit as a two-step approach. The initial fixation with Kaiserling's, Jore's I, or Romhányi's solution was invented for the generation of fresh specimen and can logically not be undone. However, a reapplication of these first step solutions can be tried to enhance the so-called "natural colouring", which indeed is a chemical reaction exerted on the main natural color media of the human body, i.e., hemoglobin and myoglobin. Either the oxidation of Fe2+ bonds is prevented or transformed into a more stable red appearing Fe3+ bond [19]. After a facultative short rinsing in alcohol or isopropanol—again for more brilliant color effects—the permanent storage is best performed in Jore's II solution. For a fungicide effect, phenol can be added or a formaldehyde containing solution tried, which several years ago was introduced in the Berlin Museum of Medical History in a much lower concentration to shrink the risk of glass impairment (BMM's, Table 1). Hence, the second solution is rather a preservative than a fixative. Another essential message is that capillary forces help to save much more specimen especially in half-full glassware than expected from their first aspect. The complete replacement of the liquids is recommended to ensure the right chemical compositions. The development of alternative fixatives in recent years focused on the molecular accessibility and histology rather than macroscopic appearance,

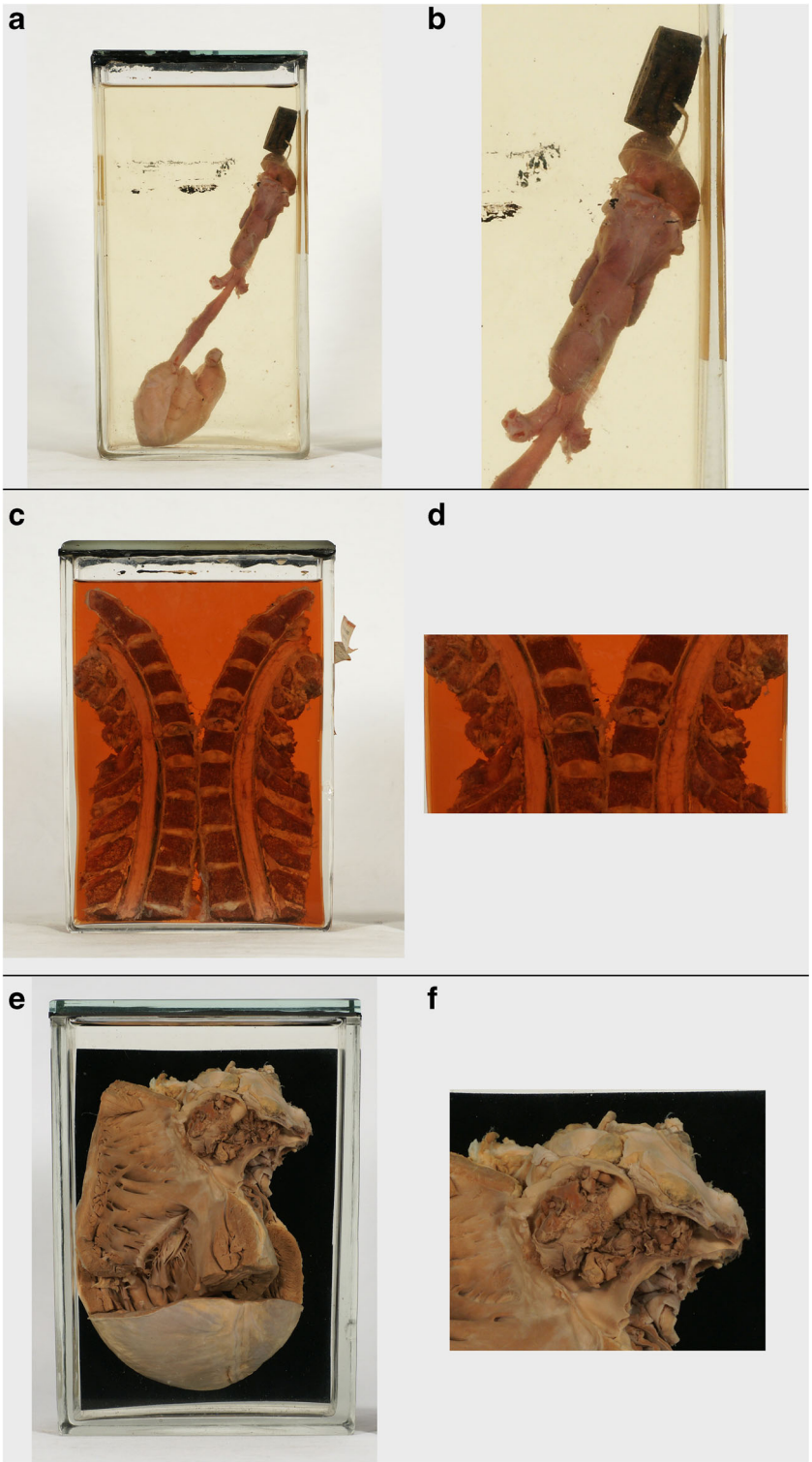

Fig. 4 Virtuosity of the non-dissecting gross specimen preparation can be appreciated in many specimens. The first case shows a tracheo-esophageal fistula (**a**, **b**) of a newborn that suffocated as a consequence. The mounting of the specimen is achieved by a lead weight put into the stomach and a cork stitched to the upper trachea. This way, a three-dimensional view from every direction is guaranteed. Simple sagittal dissecting of the spinal column and cord (**c**) and in detail (**d**) gives the clinical history of a header into shallow water a deep impression. The ulcero-polypous endocarditis of the pulmonary valve of this heart (**e**, **f**) was so clear in structure and form that it could be implemented as a picture in the regular multiple-choice examination of the students

e.g., RNA later or PAXgene [25], but might consider macroscopy or even the haptic appearance as well [16, 20].

The established detailed catalog helped to concretize the concept of the collection towards didactics. The collection highlights that nearly every organ system is represented with a wide spectrum of diseases in each. During restoration, the confrontation with provenance questions, aesthetics, preparation techniques, current terminology, and educational objectives were challenges that could be met in an institute of pathology in collaboration with external partners and students. Those of the voluntary course deepened their comprehension aside from their renovated preparations, sensitized themselves to patients' histories, and

remarkably matured in their attitudes as doctors-to-be. Of note, the introduction of historical specimens into the regular "grossing seminar" of medical undergraduate students was highly appreciated and outperformed beamer presentations. Hence, real preparations can appeal to students and strengthen the on-campus teaching as an irreplaceable activity.

Of course, historical specimens can be regarded as "vintage" didactics. Indeed, eLearning has reached pathologists and their students massively with virtual microscopy courses [14], growing quotes of online courses and technically elaborated tools. This digital transformation also evokes criticisms about distance education and the vanishing role of universities [8], possibly transforming the students into pure autodidacts. A balance can be found in the gaining role of outcome or competency-based education [10, 11, 28]. This targets skills, attitudes, problem-solving behaviors, and interactions with colleagues and can even be brought to examination with tools like the mini-clinical evaluation exercise (mini-CEX) [29], objective structured clinical examination (OSCE) [40], or direct observation of procedural skills (DOPS) [30]. In this setting, historical specimens could find an appropriate slot in modern pathological teaching [5, 24].

Furthermore, the historical specimens transport insight to non-destructive preparation techniques that could be used on the limited amount of autopsies for permanent didactic material. A comprehensive combination of minimal histological examination (biopsies) with overt presentation of macroscopic pathological findings could form the basis for new specimen starting today. The preparators' work would profit from using non-destructive work pieces as historical templates. Additionally, the experiences with different fixatives could even maintain the haptic experience (e.g., with saturated salt solutions) [12, 16, 20].

The expenditures for the project were manageable. Neither the manpower nor the costs of fixatives were critical factors. Rather, the time to conceptualize the study, the high interest of the preparators in ancient manual techniques and the support from experienced partners facilitated the workflow. In conclusion, opportunities to save historical collections exist even for single institutes of pathology.

Acknowledgements We want to thank Anthony Simpson for initial preparation assistance during the pilot phase of the project and Ute Meinel for perfecting, maintaining, and documenting the preparation protocols as well as students' teaching. Winfried Neuhuber as head of the Anatomical Institute I merits thanks for the interim housing of the historical specimens and space for the restoration processes. Navena Widulin and Thomas Schnalke from the Berlin Museum of Medical History provided excellent support and information for all restoration steps. The project was funded as one out of nine projects of the nationwide "SammLehr" initiative of the Mercator Foundation, which was opened to didactic academic collections of all kinds. Further funding was achieved by the local "fund for teaching expenses" and the "Universitätsbund" of the Friedrich-Alexander-University Erlangen-Nuremberg.

Authors' contributions TTR, FD, and UA conceived the study design. PE performed registration and standardized photography of all historical specimens. TTR conceptualized the voluntary course. CIG and AH organized the implementation to the regular curriculum. UA and FD helped for historical, ethical, and museal issues. TTR and PE performed the student survey and the statistics. All authors were part of the writing process and approved the last version of the manuscript. The Corresponding author has the right to grant on behalf of all authors and does grant on behalf of all authors.

Compliance with ethical standards

Dealing with human remains in academic and historical collections is a challenge also in terms of ethical issues. We followed the recommendations of the German Museums League and the working group of academic collections. This covers considerations about the logically unavailable direct or indirect consent from relatives, the not negotiable need for provenance research—a must not only for German collections before World War II—and requirements for appropriate custody, presentation, and audience.

Conflicts of interest All authors declare no support from any organization for the submitted work; no financial relationships with any organizations that might have an interest in the submitted work in the previous 3 years; no other relationships or activities that could appear to have influenced the submitted work.

References

1. Bamber AR, Quince TA (2015) The value of postmortem experience in undergraduate medical education: current perspectives. Adv Med Educ Pract 6:159–170. https://doi.org/10.2147/AMEP.S46669
2. Barbian LT, Sledzik PS, Nelson AM (2000) Case studies in pathology from the National Museum of Health and Medicine, Armed Forces Institute of Pathology. Ann Diagn Pathol 4:170–173
3. Bieri U, Moch H, Dehler S, Korol D, Rohrmann S (2015) Changes in autopsy rates among cancer patients and their impact on cancer statistics from a public health point of view: a longitudinal study from 1980 to 2010 with data from Cancer Registry Zurich. Virchows Arch 466: 637–643. https://doi.org/10.1007/s00428-015-1734-7
4. Bogerts B (1988) The brains of the Vogt collection. Arch Gen Psychiatry 45:774
5. Burton JL (2003) The autopsy in modern undergraduate medical education: a qualitative study of uses and curriculum considerations. Med Educ 37:1073–1081
6. Burton JL, Underwood J (2007) Clinical, educational, and epidemiological value of autopsy. Lancet 369:1471–1480. https://doi.org/10.1016/S0140-6736(07)60376-6
7. Chariot P, Witt K, Pautot V, Porcher R, Thomas G, Zafrani ES, Lemaire F (2000) Declining autopsy rate in a French hospital: physician's attitudes to the autopsy and use of autopsy material in research publications. Arch Pathol Lab Med 124:739–745. https://doi.org/10.1043/0003-9985(2000)124<0739:DARIAF>2.0.CO;2
8. Croy MJ (1998) Distance education, individualization, and the demise of the university. Technol Soc 20:317–326
9. Earle KM (1981) The International Academy of Pathology and the United States - Canadian division the first seventy-five years, 1906-1981. http://www.iapcentral.org/home/history. Accessed 04/07/2018
10. Folberg R, Antonioli DA, Alexander CB (2002) Competency-based residency training in pathology: challenges and opportunities. Hum Pathol 33:3–6
11. Ford J, Pambrun C (2015) Exit competencies in pathology and laboratory medicine for graduating medical students: the Canadian approach. Hum Pathol 46:637–642. https://doi.org/10.1016/j.humpath.2015.01.016

12. Frommer M, Raik E (2011) Is the autopsy dead? Med Educ 45:511–512. https://doi.org/10.1111/j.1365-2923.2011.03965.x
13. Ghosh SK (2017) Giovanni Battista Morgagni (1682-1771): father of pathologic anatomy and pioneer of modern medicine. Anat Sci Int 92:305–312. https://doi.org/10.1007/s12565-016-0373-7
14. Hamilton PW, Wang Y, McCullough SJ (2012) Virtual microscopy and digital pathology in training and education. APMIS 120:305–315. https://doi.org/10.1111/j.1600-0463.2011.02869.x
15. Hartmann S, Agostinelli C, Klapper W, Korkolopoulou P, Koch K, Marafioti T, Piccaluga PP, Patsouris E, Pileri S, Hansmann ML (2011) Revising the historical collection of epithelioid cell-rich lymphomas of the Kiel Lymph Node Registry: what is Lennert's lymphoma nowadays? Histopathology 59:1173–1182. https://doi.org/10.1111/j.1365-2559.2011.04069.x
16. Hayashi S, Naito M, Kawata S, Qu N, Hatayama N, Hirai S, Itoh M (2016) History and future of human cadaver preservation for surgical training: from formalin to saturated salt solution method. Anat Sci Int 91:1–7. https://doi.org/10.1007/s12565-015-0299-5
17. Huhns M, Ropenack P, Erbersdobler A (2015) Molecular and immunohistochemical characterization of historical long-term preserved fixed tissues from different human organs. PLoS One 10: e0135297. https://doi.org/10.1371/journal.pone.0135297
18. Kaiserling C (1922) Rückblicke auf Theorie und Praxis der farbigen Konservierung. Virchows Arch 237:467–474
19. Kessler R (1989) Farberhaltende Fixations- und Konservierungstechnik für Feuchtpräparate Der Präparator 35:161-170
20. Klopfleisch R, von Deetzen M, Weiss AT, Weigner J, Weigner F, Plendl J, Gruber AD (2013) Weigners fixative-an alternative to formalin fixation for histology with improved preservation of nucleic acids. Vet Pathol 50:191–199. https://doi.org/10.1177/0300985812441031
21. Knoeff H, Richardson R (2012) Leiden declaration on human anatomy/anatomical collections. Cultures of anatomical collections, Leiden, University, pp.
22. Kovari E, Hof PR, Bouras C (2011) The Geneva brain collection. Ann N Y Acad Sci 1225(Suppl 1):E131–E146. https://doi.org/10.1111/j.1749-6632.2011.06008.x
23. Lugli A, Anabitarte M, Beer JH (1999) Effect of simple interventions on necropsy rate when active informed consent is required. Lancet 354:1391
24. Marshall R, Cartwright N, Mattick K (2004) Teaching and learning pathology: a critical review of the English literature. Med Educ 38: 302–313
25. Mathieson W, Marcon N, Antunes L, Ashford DA, Betsou F, Frasquilho SG, Kofanova OA, McKay SC, Pericleous S, Smith C, Unger KM, Zeller C, Thomas GA (2016) A Critical Evaluation of the PAXgene Tissue Fixation System: Morphology, Immunohistochemistry, Molecular Biology, and Proteomics. Am J Clin Pathol 146:25–40. https://doi.org/10.1093/ajcp/aqw023
26. Melato M, Rizzardi C, Silvestri F (2002) The Pathology museum of Trieste. From medical arachaeology to revitalization. Pathologica 94:130–135
27. Moch H (2011) Documentation of the diagnostic quality of hospitals: evaluation of autopsy reports. Pathologe 32(Suppl 2):282–286. https://doi.org/10.1007/s00292-011-1521-4
28. Morcke AM, Dornan T, Eika B (2013) Outcome (competency) based education: an exploration of its origins, theoretical basis, and empirical evidence. Adv Health Sci Educ Theory Pract 18: 851–863. https://doi.org/10.1007/s10459-012-9405-9
29. Morgagni GB (1767) De Sedibus et causis morborum per anatomen indagatis libri quinque. Leiden
30. Morris MC, Gallagher TK, Ridgway PF (2012) Tools used to assess medical students competence in procedural skills at the end of a primary medical degree: a systematic review. Med Educ Online 17. https://doi.org/10.3402/meo.v17i0.18398
31. Nesi G, Santi R, Taddei GL (2007) Historical outline of the Museum of Pathological Anatomy in Florence. Med Secoli 19:295–303
32. Oluwasola OA, Fawole OI, Otegbayo AJ, Ogun GO, Adebamowo CA, Bamigboye AE (2009) The autopsy: knowledge, attitude, and perceptions of doctors and relatives of the deceased. Arch Pathol Lab Med 133:78–82. https://doi.org/10.1043/1543-2165-133.1.78
33. Paluchowski P, Gulczynski J, Szarszewski A, Siek B, Halasz J, Izycka-Swieszewska E (2016) Insight into the history of anatomopathological museums - Part 1. From casual assemblages to scientific collections. Pol J Pathol 67:207–215. https://doi.org/10.5114/pjp.2016.63771
34. Panzer S, Carli A, Zink AR, Piombino-Mascali D (2012) The anatomical collection of Giovan Battista Rini (1795-1856): a paleoradiological investigation. Clin Anat 25:299–307. https://doi.org/10.1002/ca.21240
35. Patzak B, Winter E, Feigl W (2013) Lorenz Biermayer and the developement of the Pathologic-anatomical Collection in the Fools Tower. Wien Med Wochenschr 163:310–315. https://doi.org/10.1007/s10354-013-0211-7
36. Ruhli FJ, Hotz G, Boni T (2003) Brief communication: the Galler Collection: a little-known historic Swiss bone pathology reference series. Am J Phys Anthropol 121:15–18. https://doi.org/10.1002/ajpa.10219
37. Tsitsikas DA, Brothwell M, Chin Aleong JA, Lister AT (2011) The attitudes of relatives to autopsy: a misconception. J Clin Pathol 64: 412–414. https://doi.org/10.1136/jcp.2010.086645
38. Turnbull A, Osborn M, Nicholas N (2015) Hospital autopsy: endangered or extinct? J Clin Pathol 68:601–604. https://doi.org/10.1136/jclinpath-2014-202700
39. Weber C (2017) Wissenschaftliche Sammlungen [Scientific collections]. https://portal.wissenschaftliche-sammlungen.de/discover/collection?lq=&q=&afk=subject&afv=Pathologie. Accessed 04/07/2018
40. Zenker FA (1867) Ueber Staubinhalationskrankheiten der Lungen. Deutsches Archiv für Klinische Medizin:116–172
41. Zwijnenberg R (2018) Cultures of Collecting: The Leiden Anatomical Collections in Context. https://www.universiteitleiden.nl/en/research/research-projects/humanities/cultures-of-collecting-the-leiden-anatomical-collections-in-context#tab-1. Accessed 04/07/2018