European Archives of Oto-Rhino-Laryngology (2018) 275:889–894
https://doi.org/10.1007/s00405-018-4905-8

OTOLOGY

Middle ear microvascularization: an "in vivo" endoscopic anatomical study

Matteo Alicandri-Ciufelli[1,3] · Pierre Guarino[1] · Filippo Fabbri[1] · Elio Maria Cunsolo[1] · Livio Presutti[1] · Lukas Anschuetz[1,2]

Received: 3 December 2017 / Accepted: 7 February 2018 / Published online: 10 February 2018

Abstract

Purpose To describe the in vivo vascularization of middle ear by an endoscopic point of view, particularly focusing on the medial wall of tympanic cavity and incudostapedial region (ISR).

Study design Case series with surgical videos review and anatomical description.

Methods 48 videos from exclusive endoscopic middle ear surgery performed at the University Hospital of Modena from November 2015 to July 2017 were reviewed. Data about anatomy of vessels, and blood flow direction (BFD) were collected in an appropriate database for further analyses.

Results 48 cases were included in the present study. In 18/48 patients (37,5%), a clearly identifiable inferior tympanic artery (ITA) was present, running just anteriorly to the round window (RW), with a superior BFD (65% of cases) from the hypotympanic region toward the epitympanum. Some promontorial variants were described in 67% of cases and the most common finding was a mucosal vascular network with a multidirectional BFD. On the ISR, an incudostapedial artery (ISA) was detected in 65% of cases with BFD going from the long process of the incus (LPI) toward the pyramidal eminence in the majority of cases.

Conclusion The vascular anatomy and BFD of the medial wall of the tympanic cavity can be easily studied in transcanal endoscopy. ITA (with a superior BFD in most cases) and ISA (with a main BFD from the incus to the stapes) are the most constant identifiable vessels.

Keywords Middle ear vascularization · Middle ear anatomy · Endoscopic ear surgery · Blood flow · Inferior tympanic artery · Incudostapedial joint · Incudostapedial artery · Promontory

Introduction

The exclusive endoscopic middle ear surgery has been playing increasingly a key role for several diseases in the last decade [1]. In many field of otologic surgery, even in pediatric patients [2] or approaches to the lateral skull base [3], the endoscope has become a valuable tool. The greatest advantage of this technique is the enhanced visibility of the anatomy and pathology, in reason of the wide-angled views, and the possibility to use angled scopes to explore hidden recesses such as the retro- and hypotympanum [4].

However, due to the one-handed technique, the management of bleeding is crucial to this surgical procedure [5].

In physiological conditions, the tympanic mucosa is extremely thin and transparent. This allows a direct in vivo detection of the vessels blood flow direction (BFD) during transcanal endoscopic approaches to the middle ear. As a matter of fact, when closely viewing some anatomical structures with the right magnification and focus, the movement of red particles inside the vessels can be regularly observed through an endoscope. This is particularly true for the promontorial region and at the incudostapedial joint. It is unclear if those particles are red blood cells or rouleaux,

✉ Pierre Guarino
pierreguarino@hotmail.com

1 Department of Otorhinolaryngology, Head and Neck Surgery, University Hospital of Modena, Via del Pozzo 71, 41125 Modena, Italy

2 Department of Otorhinolaryngology, Head and Neck Surgery, Inselspital, University Hospital and University of Bern, Bern, Switzerland

3 Department of Neurosurgery, New Civil Hospital Sant'Agostino-Estense, Baggiovara, Modena, MO, Italy

which usually result from the erythrocyte aggregation in a face-to face linear fashion at stasis or low shear rates. In any case, vessels BFD can be easily studied under physiological conditions.

While the most important existing studies in the literature described ex vivo investigations, this study was focused on in vivo evaluations by an endoscopic assessment of the vascular anatomy of the medial wall of the tympanic cavity and the incudostapedial region. A detailed knowledge of the vascularization patterns may potentially have implications even in terms of surgical attitude.

Materials and methods

Videos from 48 exclusive endoscopic middle ear surgeries performed at the University Hospital of Modena from November 2015 to July 2017 were reviewed. Videos in which vascularization was not clearly visible were excluded: this could verify for inflammation, or lack of adequate focus/magnification of the region studied during routine surgical practice. Data about anatomy of vessels and BFD were collected in an appropriate database for further analyses.

Results

48 cases were included in present study: 24 cases of stapedotomy (50%), including 5/24 revision procedures; seven cases of myringoplasty (15%); six cases of explorative tympanotomy (12,5%); five cases of tympanoplasty (10,5%), including one revision surgery; three cases of transcanal endoscopic removal of acoustic neuroma (6%); two cases of transcanal endoscopic removal of glomus tympanicus type A (4%); one case of endoscopic facial nerve decompression (2%). The main data from this study are summarized in Table 1.

In all included cases, it was possible to clearly visualize the medial wall of the tympanic cavity and the incudostapedial joint region by exclusive endoscopic approach, using 0° optics. 22/48 cases (46%) were left ear and 26/48 (54%) were the right one. In 18/48 patients (37.5%), a clearly identifiable inferior tympanic artery (ITA) was present, just anteriorly to the round window (RW) (Fig. 1). ITA BFD was clearly identifiable in 17/18 patients (94.5%), while it was not detectable in 1/18 (5.5%) because of the inflammatory state of the mucosa. 11/17 (65%) had an superior direction, from the hypotympanic region toward the epitympanum. 6/17 (35%) had an opposite inferior direction.

In 32/48 patients (67%), some promontorial variants were also described: a mucosal web in 21/32 patients with multidirectional BFD; a transverse vessel in 7/32 patients (BDF toward the oval window in 1/7, toward the Eustachian tube region in 1/7, toward the anterior pillar of the RW in 2/7, toward the protympanum in 2/7, toward the sinus tympani in 1/7); two parallel vessels were found in 1/32 patients with BFD toward the protympanum; a vessel perpendicular to the RW was found in 1/32 patients and a handle-shaped vessel with a superior convexity above the RW in association with a vessel perpendicular to the RW

Table 1 Middle ear vessels anatomy including variants and blood flow directions

Region	Promontorial	Incudostapedial
Main vessel	ITA	ISA
BFD of main vessel	↑(65%) ↓(35%)	↑(20%) ↓(80%)
Variants	Mucosal network (66%), BFD: multidirectional	Mucosal network (14%), BFD: multidirectional
	Transverse vessel (22%), BFD:	Oblique vessel on the LPI (29%), BFD: ↑
	Oval window (14%)	
	Eustachian tube (14%)	
	Anterior pillar of the RW (29%)	Vessel on the pyramidal eminence (14%), BFD: ↓
	Protympanum (29%)	
	Sinus tympani (14%)	Two parallel vessels on the stapedial tendon (14%), BFD: ↑ + ↓
	Two parallel vessels (3%), BFD: protymoanum	
	Vessel perpendicular to the RW (3%), BFD: ↓	Vessel on the LPI (29%), BFD: ↑
	Handle-shaped vessel with a superior convexity + vessel perpendicular to the RW (3%), BFD: ← + ↓	
	Transverse + vertical vessel posteriorly to the RW (3%), BFD: oval window + ↑	

ITA inferior tymoanic artery, *ISA* incudostapedial artery, *BFD* blood flow direction, *RW* round window, ↑ superior, ↓ inferior, ← posterior, *LPI* long process of the incus

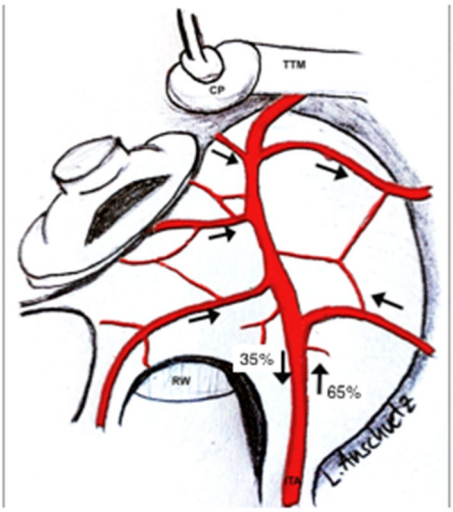

Fig. 1 ITA pathway and BFD. ITA usually runs from the hypotympanic region toward the epitympanum; black arrows show BFD results. *TTM* tensor tympani muscle, *CP* coclearíform process, *RW* round window, *ITA* inferior tympanic artery

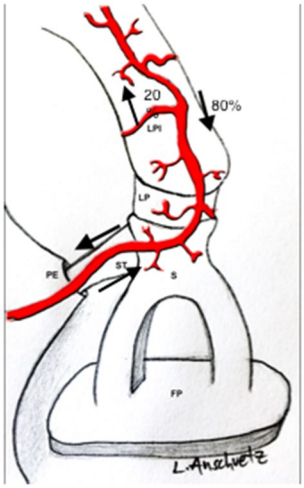

Fig. 2 ISA pathway and BFD. Schematic illustration of the ISA running from the LPI toward the pyramidal eminence after passing through the stapedial tendon; black arrows indicate BFD results. *LPI* long process of the incus, *LP* lenticular process, *ST* stapedial tendon, *S* stapes, *FP* footplate, *PE* pyramidal eminence, *BFD* blood flow direction

was found in 1/32 (in both cases, the BFD was directed inferiorly); a transverse vessel in association with a vertical vessel posteriorly to the RW in 1/32 (BFD going inferiorly and posteriorly).

Regarding the vascularization of the incudostapedial region (ISR), a vessel going from the long process of the incus (LPI) to the stapedial tendon (ST)/pyramidal eminence (PE) was identified in 31/48 patients (65%). Due to the position and anatomic relationship of that vessel, it was named incudostapedial artery (ISA) (Figs. 2, 3). ISA BFD was identifiable in 30/31 patients (97%), while it was not detectable in 1/31 patients (3%) because of the inflammatory status of the mucosa. In 24/30 patients (80%), the ISA BFD was from the incus toward the stepedial tendon/PE. On the contrary, 6/30 patients (20%) had an opposite direction. In one patient undergone to stapes surgery with a present ISA with an inferior BFD, a superior flow on the stapedial tendon was observed after the curettage of the posterior wall of the external auditory canal.

Some variants of the ISR vascularization were identified in 7/48 patients (15%): a multidirectional mucosal web in 1/7 (14%); an oblique vessel on the LPI in 2/7 (29%); a small vessel on the PE in 1/7 (14%); two parallel vessels both along the ST in 1/7 (14%); a vessel on the LPI in 2/7 (29%).

The BFD among the ISR variants was: superiorly for the two cases with an oblique vessel on the LPI; inferiorly for the small vessel on the PE; a vessel superiorly in association with a vessel inferiorly for the two parallel vessels along the ST; superiorly in the two cases of a vessel on the LPI.

None of the 48 patients showed a persistent stapedial artery.

Discussion

Several studies in the literature dealt with the issue of middle ear and ossicular chian vascularization [6–10], but the most influential one has been made by Nager and Nager in 1953 [11]. They traced blood vessels with a microscope, through serial histologic sections of 110 series of human temporal bone, providing, for each of the arteries of middle ear, a detailed description of the course, anastomoses, and branches, with particular regard to the blood supply of the auditory ossicles. According to them, the arteries

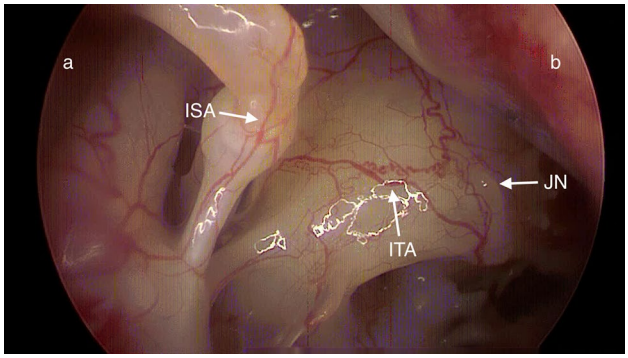

Fig. 3 Intraoperative panoramic view of the tympanic cavity. a: incudostapedial region with intraoperative finding of ISA; b: promontorial region with intraoperative finding of ITA and Jacobson's nerve. *ISA* incudostapedial artery, *ITA* inferior tympanic artery, *JN* Jacobson's nerve

which supply the middle ear are: (1) the carotico-tympanic branches, from the vertical portion of the internal carotid artery, (2) the inferior tympanic artery (ITA), branch of the ascending pharyngeal artery, (3) the stylomastoid artery (SMA), from the posterior auricular artery, (4) the superficial petrosal artery (SPA), from the middle meningeal artery, (5) the superior tympanic artery (STA), also from the middle meningeal artery, (6) the subarcuate artery, a branch of the meatal segment of anterior inferior cerebellar artery (AICA), (7) the anterior tympanic artery (ATA) and the (8) deep auricular artery, from the internal maxillary artery, and (9) the eustachian tube artery [11]. (Fig. 4).

They also stated that the anterior tympanic artery (ATA), deriving from the maxillary artery, after passing through the petro-tympanic fissure, plays a key role, giving off three branches: anterior branch of the ATA, posterior branch of the ATA, and a branch that they named as ossicular artery. This vessel, apparently never recognized before, seems to be the most important source of blood supply to the incus and malleus, splitting in malleolar artery and incudal artery.

Lindeman et al. on the contrary, stated that the incus could be supplied through many larger and smaller vessels that penetrate the corticalis in the body of the incus or also by small vessels penetrating the bone in its more peripheral regions from the mucous membrane [6].

The middle ear arteries anastomose extensively each other, both by continuity of their main stems and by way of the mucosal networks to which they contribute to. In particular, some areas of middle ear seem to be supplied by these mucosal networks rather than by a single artery [11].

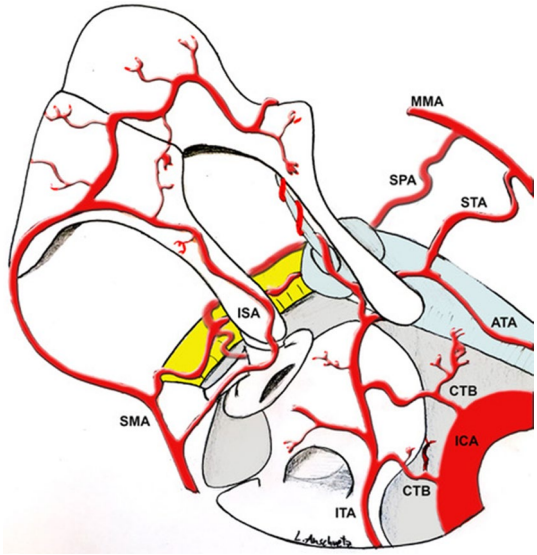

Fig. 4 Vascularization of the middle ear. *ITA* inferior tympanic artery, *ICA* internal carotid artery, *CTB* carotico-tympanic branches, *ATA* anterior tympanic artery, *STA* superior tympanic artery, *MMA* middle meningeal artery, *SMA* stylomastoid artery, *ISA* incudostapedial artery, *SPA* superficial petrosal artery

Another remarkable contribution was made by Anson et al. about the venous supply of the ISR employing specimen from a newborn with mild otitis media: thanks to the inflammatory condition, the venules had an increase of their naturally greater diameter and outnumbered the arterioles [7].

The promontorial region is mainly supplied by branches of the carotico-tympanic artery or arteries and branches of the ITA, which ascends anteriorly to the round window, often accompanied by the nerve of Jacobson.

The ossicular artery mainly has a nutritious role for the inner ossicular structure of the incus through the incudal artery, which branches off it as mentioned above. Sometimes, it may enter the incus at the anterior-lateral surface of the root of the long process. Instead, the mucosal network over the incus and the incudostapedial joint is usually supplied by other vessels from the posterior branch of the ATA. Nutritive foramina of the incus were also described by Gerlinger et al. in a recent anatomical paper [10].

The STA descends in the promontorial sulcus to join the ITA artery about at the level of the oval window, where it gives a branch to the anterior crus of the stapes.

The principal supply to the region of the posterior crus is a small artery that emerges from the descending main branch of the superficial petrosal artery which courses in the facial canal between its wall and the trunk of the facial nerve. This vessel could leave the main descending branch of the SPA either in the last portion of its horizontal course or in the upper third of the vertical portion of the facial canal. Then, after supplying the footplate, it passes along the convex surface of the posterior crus to contribute to the vascular network over the incudostapedial articulation and send a branch into the bone of the neck and head of the stapes. The main descending branch of the SPA then terminates by anatomosing with the SMA [11].

Based on our results, although some promontorial variants, ITA could be considered a quite constant vessel. Comparing our results with those of Nager and Nager [11], we can state that there is a good correlation with the anatomical characteristics of that vessel. In fact, when present, it is placed in a sinusoidal, tendentially vertical direction, anteriorly to the round window.

As for the BFD, we expected it to be steadily up, while in 35% of the cases, it was inferiorly oriented. It has not been clearly seen with our method an anastomosis with the branches of STA anteriorly to the oval window, but it has been extensively described in the literature that vascularization of the tympanic cavity is provided by so many mucosal networks rather than single vessels. Regarding the promontorial variants, transverse vessels may be the carotico-tympanic artery or arteries. The transverse

vessels described in the promontorial variants only in 22% of cases, it is unclear if they are variants of the ITA itself or the carotico-tympanic artery or arteries, which cross the mucosa of the promontory after the origin from the vertical section of the ICA. The STA has never been clearly identified with the method in use. Mucosal networks were the most frequent promontorial variant (66% of cases), alone or in association with ITA, and showed a multidirectional BFD.

Due to the growing evidence in the literature of necrosis of the lenticular process of the incus following stapes surgery, Alberti (1963) carried out a two-in-one study (latex injection into the middle ear arteries in 4 stillborn fetuses and histological sections of 25 adult incuses) to prove the suggestion that the stylomastoid artery branches running along the stapedial tendon are pivotal in the blood supply of the ISR. Although several matching points, he stated that Nager and Nager did not focus on the vascular ramifications to the lenticular process of the incus or the capsule of the ISJ. He noticed an anastomosis between the vessels which supply the stapes and the descending vessels of the incus on the incudal side of the ISJ. Furthermore, he found that the stapes are supplied by two groups of vessels: (1) branches from the ATA to the footplate and crura anteriorly, the plexus surrounding the facial nerve posteriorly; (2) two constant vessels arising from the arterial plexus of the facial nerve that pass along the stapedial tendon to reach the apex of the crura, the head and neck of the stapes, the ISJ, and terminate by anastomosing with the descending vessels on the LPI [12].

Based on our results, as mentioned above, a quite constant vessel named by present authors as incudostapedial artery (ISA) was found in 65% of cases. It is unclear whether it is a single vessel or anastomosis of several vessels. The descending line on the LPI could be the posterior branch of the ATA described by Nager and Nager [11], while the portion between the pyramidal eminence and the lenticular process of the incus may be one of the branches described by Alberti at the level of the ST [12]. Contrary to what is historically reported in the literature, it was found that ISA BFD was directed from LPI to ST/PE in 80% of cases. We do not know yet if these data may have interesting implications in stapes' surgery. In fact, it has been widely debated about a possible ST preservation during this procedure to prevent the devascularization and necrosis of the LPI. Although many authors have reported excellent objective and subjective results in patients who underwent to stapedectomy or stapedotomy with ST preservation, its usefulness is still controversial [13–19]. In addition, according to our findings, the BFD of the stapedial vessels seems to have an opposite direction to the LPI. Among the variants of the ISR are the two parallel vessels along the ST. They may correspond to the two vessels described by Alberti such as superolateral artery and inferior lateral artery [12]. However, in our 2 reported cases, the flows are in the opposite direction.

Conclusions

The vessels blood flow direction (BFD) of the medial wall of the tympanic cavity can be easily studied in transcanal endoscopy. Specifically, the vascular anatomy of the ISR and the promontorial region can be visualized and described. The ITA at the promontorial level appeared to be present in 37.5% of cases, mainly with a superior BFD. At the ISR level, an incudostapedial vessel named incudostapedial artery (ISA) was detected in 65% of cases and its BFD appeared predominantly directed from the incus towards pyramidal eminence, on the opposite to what already reported in the literature.

Author contributions MAC: conception and design; data collection and statistical analysis; manuscript edition, revision and approval. FF: conception and design; data collection; manuscript revision and approval; PG, LA: conception and design; data interpretation supervision; manuscript revision and approval. LP, EMC: conception and design, senior supervision and critical revision of data analysis; manuscript revision and approval. All authors agree to be accountable for all aspects of the work in ensuring that questions related to the accuracy or integrity of any part of the work are appropriately investigated and resolved. MAC and PG had full access to all the data in the study and take responsibility for the integrity of the data and the accuracy of the data analysis.

Compliance with ethical standards

Conflict of interest The authors declare that they have no conflict of interest nor financial relationship to disclose.

Research involving human participants and/or animals This article does not contain any studies with animals performed by any of the authors.

Informed consent For this type of study, formal consent was not required from local IRB.

References

1. Yong M, Mijovic T, Lea J (2016) Endoscopic ear surgery in Canada: a cross-sectional study. J Otolaryngol Head Neck Surg 45:4. https://doi.org/10.1186/s40463-016-0117-7
2. Marchioni D, Soloperto D, Rubini A, Villari D, Genovese E, Artioli F, Presutti L (2015) Endoscopic exclusive transcanal approach to the tympanic cavity cholesteatoma in pediatric patients: our experience. Int J Pediatr Otorhinol 79(3):316–322
3. Marchioni D, Alicandri-Ciufelli M, Rubini A, Masotto B, Pavesi G, Presutti L (2016) Exclusive endoscopic transcanal transpromontorial approach: a new perspective for internal auditory canal vestibular schwannoma treatment. J Neurosurg 11:1–8
4. Bonali M, Anschuetz L, Fermi M, Villari D, Mariani GA, Manzoli L, Caversaccio M, Presutti L (2017) The variants of the

retro- and hypotympanum: an endoscopic anatomical study. Eur Arch Otorhinol 274(5):2141–2148. https://doi.org/10.1007/s00405-4492-0
5. Anschuetz L, Bonali M, Guarino P, Fabbri FB, Alicandri-Ciufelli M, Villari D, Caversaccio M, Presutti L (2017) Management of bleeding in exclusive endoscopic ear surgery: pilot clinical experience. Otolaryngol Head Neck Surg 157(4):700–706. https://doi.org/10.1177/0194599817726982. Epub 2017 Sep 5
6. Lindeman H (1964) Some histological examinations of the incus and stapes with especial regard to their vascularization. Acta Otolaryngol Suppl 188(Suppl 188):319.
7. Anson BJ, Harper DG, Hanson JR (1962) Vascular anatomy of the auditory ossicles and petrous part of the temporal bone in man. Trans Am Otol Soc 50:21–32
8. Lannigan FJ, O'Higgins P, McPhie P (1993) The vascular supply of the lenticular and long processes of the incus. Clin Otolaryngol Allied Sci 18(5):387–389
9. Vallejo-Valdezate LA, Herrero-Calvo D, Garrosa-García M (2016) Vascularization of the long process of the malleus: surgical implications. Eur Arch Otorhinol 273(9):2335–2342.https://doi.org/10.1007/s00405-015-3787-2. Epub 2015 Sep 24
10. Gerlinger I, Tóth M, Lujber L, Szanyi I, Móricz P, Somogyvári K, Németh A, Ráth G, Pytel J, Mann W (2009) Necrosis of the long process of the incus following stapes surgery: new anatomical observations. Laryngoscope 119(4):721–726
11. Nager GT, Nager M (1953) The arteries of the human middle ear, with particular regard to the blood supply of the auditory ossicles. Ann Otol Rhinol Laryngol 62(4):923–49
12. Alberti PW (1963) The blood supply of the incudostapedial joint and the lenticular process. Laryngoscope 73:605–628
13. Colletti V, Sittoni V, Fiorino FG (1988) Stapedotomy with and without stapedius tendon preservation versus stapedectomy: long-term results. Am J Otol 9(2):136–141
14. Alberti PW, Dawes JD (1961) Necrosis of the lenticular process of the incus after stapes surgery and its treatment. A case report. J Laryngol Otol 75:821–825
15. Arnold A, Blaser B, Häusler R (2007) Audiological long-term results following stapedotomy with stapedial tendon preservation. Adv Otorhinol 65:210–214
16. Vallejo LA, Gil-Carcedo E, Herrero D, Sánchez C, Sánchez E, Gil-Carcedo LM (2007) Analysis of the mechanical-acoustic features of the middle ear after stapedial surgery both with and without stapes muscle preservation. Acta Otorrinol Esp 58(7):302–310
17. Rasmy E (1986) Stapedius reflex after stapedectomy with preservation of the stapedius tendon. J Laryngol Otol 100(5):521–527
18. Silverstein H, Hester TO, Deems D, Rosenberg S, Crosby N, Kwiatkowski T (1999) Outcomes after laser stapedotomy with and without preservation of the stapedius tendon. Ear Nose Throat J 78(12):923–928
19. Gros A, Zargi M, Vatovec J (2000 Dec) Does it make sense to preserve the stapedial muscle during surgical treatment for otosclerosis? J Laryngol Otol 114(12):930–934