



# The Functional Implant Prosthodontic Score (FIPS): assessment of reproducibility and observer variability

Tim Joda<sup>1,2</sup> · Fernando Zarone<sup>3</sup> · Nicola U. Zitzmann<sup>2</sup> · Marco Ferrari<sup>4,5</sup>

Received: 22 November 2017 / Accepted: 22 December 2017 / Published online: 3 January 2018  
© Springer-Verlag GmbH Germany, part of Springer Nature 2018

## Abstract

**Objectives** The aim of this study was to validate the reproducibility and observer variability of the Functional Implant Prosthodontic Score (FIPS), while considering the level of dental experience for intra- and inter-examiner analysis.

**Materials and methods** A total of 44 examiners ( $n = 31$  undergraduate dental students and  $n = 13$  postgraduate prosthodontic students) applied FIPS to ten sample cases each showing one implant-supported single crown for premolar or molar replacements. Examiners' assessments were carried out twice at an interval of 2 weeks (round A and round B). Pearson's correlations including 95% confidence intervals (CI95) were calculated for intra- and inter-examiner reproducibility testing. Cohen's Kappa score was additionally used to analyze the homogeneity of each FIPS variable.

**Results** The mean values of the total FIPS scores for round A ( $7.21 \pm 0.91$ ) and round B ( $7.27 \pm 0.86$ ) showed a strong correlation of 0.9374 (CI95 0.9250; 0.9478). No significant difference was identified between undergraduates and postgraduates representing different levels of dental experience. Homogeneity analysis of the defined FIPS variables was not significantly different.

**Conclusions** Both intra- and inter-examiner analysis revealed very congruent results for reproducibility testing of FIPS. The findings validated the potential of FIPS as an objective and reliable evaluation instrument in assessing fixed implant restorations in posterior sites independent of the level of dental experience.

**Clinical relevance** FIPS can be considered as an additional diagnostic tool to classify fixed implant restorations in routine dental practice, to compare follow-up observations, and to identify potential risks of failure.

**Keywords** Diagnostic test study · Dental implant · Fixed prosthodontics · Reproducibility · Validity · Functional implant prosthodontic score (FIPS)

## Introduction

The rehabilitation of single-tooth gaps with implant-supported crowns has become a standard therapy in dental medicine today [1]. Implant dentistry is in the focus of public (social) media and online platforms, which led to an increasing patients' interest with high expectations regarding the treatment outcome [2].

The prevalence of implant restorations depends on country specific health-care systems. While tooth replacement with implant restorations is more frequent in functional posterior sites than in the anterior esthetic zone ([www.aaid.com](http://www.aaid.com)), the attention in publications and congress presentations has shifted to challenging implant therapy concepts in the anterior esthetic zone. Concomitantly, several indices have

✉ Tim Joda  
tim.joda@zmk.unibe.ch

<sup>1</sup> Department of Reconstructive Dentistry and Gerodontology, School of Dental Medicine, University of Bern, Freiburgstr. 7, 3010 Bern, Switzerland

<sup>2</sup> Department of Reconstructive Dentistry, University Center for Dental Medicine Basel, University of Basel, Basel, Switzerland

<sup>3</sup> Department of Prosthodontics, School of Dental Medicine, University of Naples, Naples, Italy

<sup>4</sup> Department of Prosthodontics and Dental Materials, School of Dental Medicine, University of Siena, Siena, Italy

<sup>5</sup> Department of Restorative Dentistry, School of Dental Medicine, University of Leeds, Leeds, UK

been published to analyze implant restorations in the anterior region yielding on esthetic parameters [3–7].

In addition to the esthetic assessment, the functional evaluation of fixed implant restorations with an objective, reliable, and quickly applicable score is of great interest for justification of patient's satisfactory outcome, risk calculation and prognosis of long-term performance [8]. In 2016, the first functional score (Functional Implant Prosthodontic Score—FIPS) was introduced for the evaluation of single-unit implant crowns in pre-molar and molar sites. FIPS combines clinical and radiographic parameters using defined variables associated with restoration's function [9]. A moderately strong correlation was found between the objective evaluation using FIPS and the subjective patients' perception according to their general expectations of the implant restoration with a coefficient of 0.85 [9].

The clinical application of a novel index for objective evaluation must be independently validated. Therefore, the aims of this study were to validate the reproducibility and observer variability of FIPS and, secondary, to investigate the potential influence of different levels of dental experience for intra- and inter-examiner analysis.

## Material and methods

### Functional Implant Prosthodontic Score (FIPS)

As previously described, the evaluation index was defined by five variables: (1) interproximal, (2) occlusion, (3) design, (4) mucosa, and (5) bone. A scoring scheme of 0–1–2 was

assigned for each variable, resulting in a maximum score of ten ( $5 \times 2$ ) [Table 1].

The variable “Interproximal” was assessed for mesial-distal contact areas and the papillary presence of the adjacent dentition. “Occlusion” was evaluated for static and dynamic patterns and “Design” for contour and shape as well as color and finish. The three variables related to the restoration were scored as major discrepancy (0), minor discrepancy (1), or no discrepancy (2). The quality and quantity of the peri-implant soft tissue conditions was categorized under “Mucosa” as non-keratinized/non-attached (0), non-keratinized/attached (1), or keratinized + attached (2). In addition, marginal bone levels were analyzed under “Bone” assessing the radiographic level of the alveolar crest mesially and distally: loss  $> 1.5$  mm (0), loss  $< 1.5$  mm (1), and no loss (2).

In general, the lowest score within each single variable assessment was decisive in case of different observations for sub-variable evaluation [9].

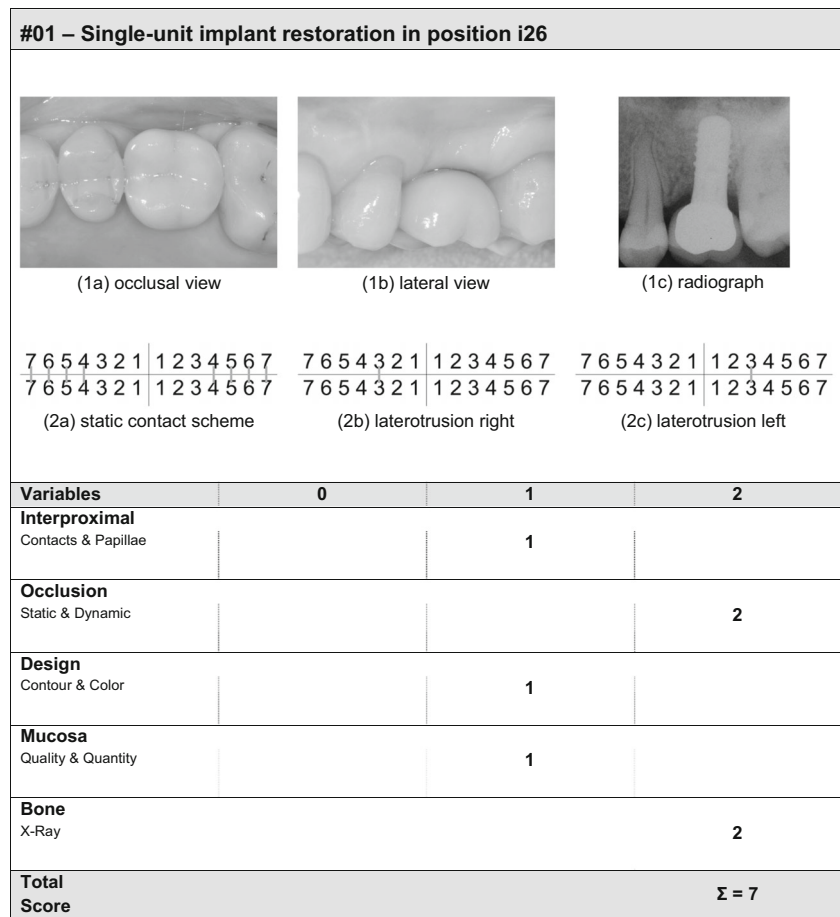
### Study setting

Standardized lateral and occlusal photographs of ten single-unit implant-supported crowns were included for reproducibility analysis of FIPS. The reconstructions were characterized by a soft tissue level type implant connected to individualized titanium abutments with cemented restorations made of manually veneered zirconium dioxide frameworks (Institut Straumann AG, Basel, Switzerland: Straumann TL RN/WN, CARES Stream; Noritake CZR, Kuraray Noritake Dental Inc., Tokyo, Japan) [Fig. 1].

**Table 1** Definition of the Functional Implant Prosthetic Score (FIPS) with the defined five variables: (1) interproximal, (2) occlusion, (3) design, (4) mucosa, and (5) bone

Variables	0	1	2
<b>Interproximal</b>			
Contacts and papillae	Major discrepancy (2× incomplete)	Minor discrepancy (1× complete)	No discrepancy (2× complete)
<b>Occlusion</b>			
Static and dynamic	Major discrepancy (supra-contact)	Minor discrepancy (infra-occlusion)	No discrepancy
<b>Design</b>			
Contour and color	Major discrepancy (contour)	Minor discrepancy (color)	No discrepancy
<b>Mucosa</b>			
Quality and quantity	Non-keratinized non-attached	Non-keratinized attached	Keratinized attached
<b>Bone</b>			
X-ray	Radiographic bone loss $> 1.5$ mm	Radiographic bone loss $< 1.5$ mm	Radiographic bone loss not detectable
Maximum score			$\Sigma = 10$

**Fig. 1** Sample patient case #01 showing an implant-supported crown in position i26: **a** lateral and **b** occlusal views as well as **c** 2D radiological imaging plus tabular evaluation form-sheet of the Functional Implant Prosthetic Score (FIPS) and corresponding variables with a scoring scheme of 0–1–2



Each implant crown was photographed with a digital SLR camera by the same prosthodontist (TJ) (Nikon Corp. Tokyo, Japan: D 3200, Micro-Nikkor AF-D 105 mm, Macro-Flash SB-29 s). At the same time, intraoral radiographs were taken displaying the entire implant including connected crown and the adjacent teeth. The magnification of the photographs and the radiographs was set at 2:1.

FIPS evaluations of the 10× implant sample-cases were performed by two groups of participants with a different level of dental experience: undergraduate dental students (*n* = 31) and postgraduate prosthodontic students (*n* = 13).

All participants carried out two FIPS assessments for each sample case, round A and round B, with a break of 2 weeks between assessments. For the second round of evaluation, the sequence of cases was reversed to reduce any kind of possible bias.

**Statistical analysis**

Descriptive methods were used for general calculations of demographic characteristics of participants and mean values of FIPS including standard deviation (SD). To evaluate the reproducibility of FIPS, Pearson’s correlation coefficients were calculated for all sum-scores of intra-examiner matched

cases of round A and round B. A 95% confidence interval (95CI) was calculated for each estimated correlation. In addition, the level of dental experience (inter-examiner analysis) was correlated with each of the five FIPS-variables including analysis of possible influence of gender for the selection of the ten sample cases. The decision criterion for a statistically significant difference between two groups was defined whether the compared 95CIs overlapped or not. If not, the consistency of the two groups at the 5% significance level was considered as statistically different.

The homogeneity of each FIPS variable was also investigated with the calculation of Cohen’s Kappa score. For the analysis of other factors, Cohen’s Kappa score was omitted due to the numeric rather than categorical character of sum-scores indicating Pearson’s correlation coefficient as appropriate method. All results were calculated with R, version 3.2.2 (The R Project for Statistical Computing, Vienna, Austria).

**Results**

A total of 44 participants (*n* = 31 undergraduate dental students and *n* = 13 postgraduate prosthodontic students) applied FIPS to ten sample cases showing each one implant-supported

**Table 2** Mean total FIPS scores for each of the ten sample cases evaluated by the groups of undergraduate dental students and postgraduate prosthodontic students separately tabularized for round A and round B

Cases	Undergraduate examiners ( <i>n</i> = 31)		Postgraduate examiners ( <i>n</i> = 13)		All examiners ( <i>n</i> = 44)	
	A	B	A	B	A	B
#01	7.16	7.58	7.54	7.77	7.30	7.64
#02	7.52	7.55	7.62	7.69	7.55	7.59
#03	6.29	6.29	6.15	6.23	6.25	6.27
#04	6.45	6.19	6.15	6.08	6.36	6.16
#05	8.23	8.55	8.92	9.15	8.43	8.73
#06	7.58	7.61	7.69	7.62	7.61	7.61
#07	4.81	4.48	4.54	4.08	4.73	4.36
#08	9.55	9.74	9.85	9.92	9.64	9.80
#09	6.71	6.87	6.92	6.92	6.77	6.89
#10	7.45	7.61	7.62	7.85	7.50	7.68
Mean	7.18	7.25	7.30	7.33	7.21	7.27

single crown in posterior position. Evaluations were carried out twice at an interval of 2 weeks.

Gender ratio was 45% females (*n* = 20)/55% males (*n* = 24). Mean age of all included participants was 28 years (49–21 years), whereas mean results for the sub-groups were 23 years (21–26 years) for undergraduates and 38 years (28–49 years) for postgraduates, respectively. The postgraduate prosthodontic students had on average 13 years of dental experience (after obtaining the DMD-degree).

The mean total FIPS scores of all included participants were  $7.21 \pm 0.91$  for round A and  $7.27 \pm 0.86$  for round B. The detailed results for each of the ten sample cases evaluated by the group of undergraduates and postgraduates are summarized in Table 2. [Table 2].

### Intra-examiner homogeneity

The values of the total FIPS scores for round A and round B showed a correlation of 0.9374 (CI95 0.9250; 0.9478). For gender homogeneity, correlation analysis revealed analogous results of 0.9343 (CI95 0.9141; 0.9499) for females and 0.9402 (CI95 0.9235; 0.9533) for males with no significant difference.

**Table 3** Pearson's correlation analysis including 95% confidence intervals (CI95) comparing round A and round B applying FIPS by undergraduates and postgraduates

	Pearson	
	Correlation	CI95
Undergraduate examiners ( <i>n</i> = 31)	0.9318	0.9154   0.9451
Postgraduate examiners ( <i>n</i> = 13)	0.9481	0.9318   0.9630

[Not significantly different (*p* > 0.05)]

### Inter-examiner homogeneity

According to the participants' level of dental experience, data was divided into two groups representing undergraduate and postgraduate students. The values of the total FIPS scores for round A and round B are shown in Table 2. The correlation between the two time-points applying FIPS was very high for both groups. As the confidence intervals were overlapping, no significant difference could be identified between undergraduates and postgraduates [Table 3].

### Homogeneity of FIPS variables

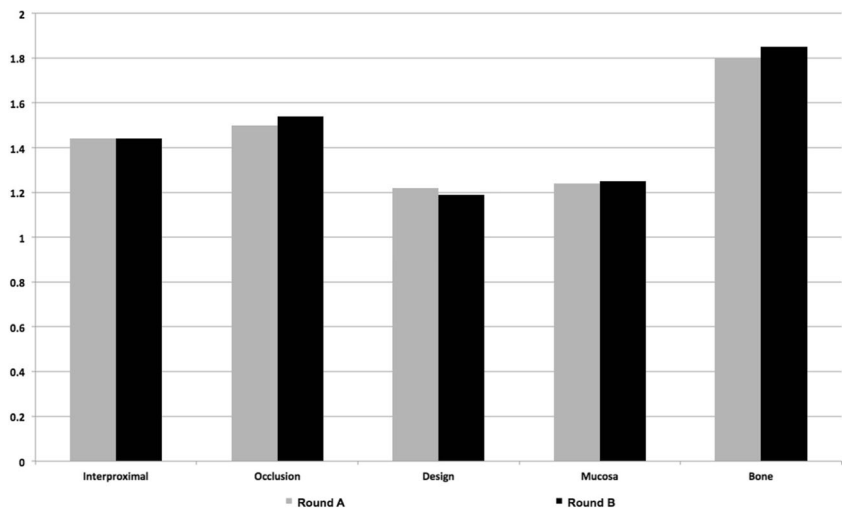
Calculations for the defined FIPS-variables (1) interproximal, (2) occlusion, (3) design, (4) mucosa, and (5) bone, revealed high correlations for all five variables comparing round A and round B. The highest scoring was evident for "Occlusion" (0.9470) and the lowest for "Bone" (0.7768) [Fig. 2].

In addition, statistical calculations were made with Cohen's Kappa score and the results were comparable to Pearson's correlation [Table 4].

### Discussion

Survival is still the major outcome parameter for the evaluation of any kind of implant treatment, while diverse surrogate parameters have also been described [10]. Specific criteria were defined in several clinical investigations and mixed up for biological assessment of the peri-implant mucosal condition and radiographic evaluation of the alveolar bone, plus technical complications of the reconstructive parts including implant connecting components [11]. Most frequently reported success criteria combined multiple parameters, such as radiographically detectable bone loss, bleeding and suppuration

**Fig. 2** Results for reproducibility testing including all 44 examiners for evaluation of round A and round B displaying mean values (Y-axis: 0–2) for the five FIPS variables (X-axis): (1) Interproximal, (2) occlusion, (3) design, (4) mucosa, and (5) bone. [All results were not significantly different ( $p > 0.05$ )]



on probing, mobility of the implant, incidence of mechanical failures, and esthetics [12].

Early diagnosis of peri-implant diseases is essential and requires clinical and radiographic examinations ideally combined with previous radiographs, which facilitate an estimation of the current bone level in relation to a reference [13, 14]. The finding of a reduced bone level can indicate progressive bone loss symptomatic for peri-implantitis, or result from previous remodeling during the initial healing phase, or can be related to a past inflammatory episode. In the current FIPS the radiographic level of the alveolar crest was categorized according to absolute loss of marginal bone, which was found to be easily applicable by both under- and postgraduates without statistically significant difference.

Universally, success in implant treatment ought to reflect the long-term outcome of the dental implant itself plus the prosthetic components as an entire reconstructive complex. Every evaluation protocol has to be qualified by its performance in terms of easy-to-use for a quick and reproducible application. In addition, protocols should involve a clinically relevant meaning for the dental professional and the patient. The present study investigated the reproducibility and

observer variability of FIPS; currently, the only functional implant scoring index linking clinical and radiographic examinations in a single evaluation protocol for implant restorations in posterior sites [9, 15].

In contrast to the most esthetically based implant indices, FIPS, as a functional-oriented score, is defined by only five variables. FIPS is intended to be as simple as possible; nevertheless, to cover all clinically and radiographically relevant aspects. The simple application combined with the clinical relevance and its derived impact is a prerequisite to implement a diagnostic evaluation index, such as FIPS, regularly, both in a university research setting and in routine dental business. However, any (medical) evaluation tool has to be ubiquitously applicable resulting in objective and reproducible outcomes independent on the operator’s level of experience. In general, mathematical correlation analyses of repeated applications are statistically considered as ‘strong’ results between 0.7 and 0.8. In this study, all calculated correlations were beyond this ranging threshold and, therefore, could be categorized as strong.

In detail, both the intra- and inter-examiner homogeneity revealed a very high value of consistency for FIPS scores analyzing intra- and inter-examiners reproducibility with no statistically significant differences under repetitive practice.

**Table 4** Pearson’s correlation analysis including 95% confidence intervals (CI95) and Cohen’s Kappa scores comparing round A and round B for the defined five FIPS variables: (1) interproximal, (2) occlusion, (3) design, (4) mucosa, and (5) bone

	Pearson		Cohen’s Kappa
	Correlation	CI95	
Interproximal	0.7922	0.7546   0.8246	0.792
Occlusion	0.9470	0.9364   0.9159	0.905
Design	0.8337	0.8028   0.8602	0.825
Mucosa	0.8661	0.8407   0.8877	0.841
Bone	0.7768	0.7369   0.8114	0.763

### Conclusions

Overall, the findings of the present study demonstrated the reliability of repeated performance of FIPS for reproducibility testing. The definition of the five FIPS-variables seems to be easy understandable and operable for standardized evaluations independent of the level dental experience. Therefore, FIPS can be considered as an additional diagnostic tool that helps to objectively categorize fixed implant restorations in posterior sites according to functional aspects during long-term follow-up of implant patients. Moreover, it might have the potential to



identify failure risks at an early stage of the implant prosthodontic treatment.

**Acknowledgements** The authors are grateful to all voluntary participants for intra- and inter-examiner analyses, and acknowledge Mr. Gabriel Fischer for the statistical support of the correlation analyses.

**Funding** The work was supported by the Department of Reconstructive Dentistry and Gerodontology, School of Dental Medicine, University of Bern, Switzerland.

## Compliance with ethical standards

**Conflict of interest** The authors declare that they have no conflict of interest.

**Ethical approval** All procedures performed in studies involving human participants were in accordance with the ethical standards of the institutional and/or national research committee and with the 1964 Helsinki declaration and its later amendments or comparable ethical standards.

**Informed consent** For this type of study, formal consent is not required.

## References

1. Wismeijer D, Bragger U, Evans C, Kapos T, Kelly JR, Millen C, Wittneben JG, Zembic A, Taylor TD (2014) Consensus statements and recommended clinical procedures regarding restorative materials and techniques for implant dentistry. *Int J Oral Maxillofac Implants* 29(Suppl):137–140. <https://doi.org/10.11607/jomi.2013.g2>
2. Pommer B, Zechner W, Watzak G, Ulm C, Watzek G, Tepper G (2011) Progress and trends in patients' mindset on dental implants. II: implant acceptance, patient-perceived costs and patient satisfaction. *Clin Oral Implants Res* 22(1):106–112. <https://doi.org/10.1111/j.1600-0501.2010.01969.x>
3. Belser UC, Grutter L, Vailati F, Bornstein MM, Weber HP, Buser D (2009) Outcome evaluation of early placed maxillary anterior single-tooth implants using objective esthetic criteria: a cross-sectional, retrospective study in 45 patients with a 2- to 4-year follow-up using pink and white esthetic scores. *J Periodontol* 80(1):140–151. <https://doi.org/10.1902/jop.2009.080435>
4. Furhauser R, Florescu D, Benesch T, Haas R, Mailath G, Watzek G (2005) Evaluation of soft tissue around single-tooth implant crowns: the pink esthetic score. *Clin Oral Implants Res* 16(6):639–644. <https://doi.org/10.1111/j.1600-0501.2005.01193.x>
5. Juodzbaly G, Wang HL (2010) Esthetic index for anterior maxillary implant-supported restorations. *J Periodontol* 81(1):34–42. <https://doi.org/10.1902/jop.2009.090385>
6. Meijer HJ, Stellingsma K, Meijndert L, Raghoobar GM (2005) A new index for rating aesthetics of implant-supported single crowns and adjacent soft tissues: the implant crown aesthetic index. *Clin Oral Implants Res* 16(6):645–649. <https://doi.org/10.1111/j.1600-0501.2005.01128.x>
7. Tettamanti S, Millen C, Gavric J, Buser D, Belser UC, Bragger U, Wittneben JG (2016) Esthetic evaluation of implant crowns and peri-implant soft tissue in the anterior maxilla: comparison and reproducibility of three different indices. *Clin Implant Dent Relat Res* 18(3):517–526. <https://doi.org/10.1111/cid.12306>
8. Joda T, Ferrari M, Gallucci GO, Wittneben JG, Bragger U (2017) Digital technology in fixed implant prosthodontics. *Periodontol* 73(1):178–192. <https://doi.org/10.1111/prd.12164>
9. Joda T, Ferrari M, Bragger U (2017) A prospective clinical cohort study analyzing single-unit implant crowns after three years of loading: introduction of a novel Functional Implant Prosthodontic Score (FIPS). *Clin Oral Implants Res* 28(10):1291–1295. <https://doi.org/10.1111/clr.12955>
10. Wyatt CC, Zarb GA (1998) Treatment outcomes of patients with implant-supported fixed partial prostheses. *Int J Oral Maxillofac Implants* 13(2):204–211
11. Chen ST, Buser D (2009) Clinical and esthetic outcomes of implants placed in postextraction sites. *Int J Oral Maxillofac Implants* 24(Suppl):186–217
12. Papaspyridakos P, Chen CJ, Singh M, Weber HP, Gallucci GO (2012) Success criteria in implant dentistry: a systematic review. *J Dent Res* 91(3):242–248. <https://doi.org/10.1177/0022034511431252>
13. Berglundh T, Zitzmann NU, Donati M (2011) Are peri-implantitis lesions different from periodontitis lesions? *J Clin Periodontol* 38(Suppl 11):188–202. <https://doi.org/10.1111/j.1600-051X.2010.01672.x>
14. Jepsen S, Berglundh T, Genco R, Aass AM, Demirel K, Derks J, Figuero E, Giovannoli JL, Goldstein M, Lambert F, Ortiz-Vigon A, Polyzois I, Salvi GE, Schwarz F, Serino G, Tomasi C, Zitzmann NU (2015) Primary prevention of peri-implantitis: managing peri-implant mucositis. *J Clin Periodontol* 42(Suppl 16):S152–S157. <https://doi.org/10.1111/jcpe.12369>
15. Joda T, Ferrari M, Bragger U (2017) Monolithic implant-supported lithium disilicate (LS2) crowns in a complete digital workflow: a prospective clinical trial with a 2-year follow-up. *Clin Implant Dent Relat Res* 19(3):505–511. <https://doi.org/10.1111/cid.12472>