

The evil of the patent foramen ovale: we are seeing but the tip of the iceberg

Bernhard Meier^{1*} and Fabian Nietlispach²

¹Department of Cardiology, University Hospital of Bern, Switzerland; and ²Department of Cardiology, University Hospital of Zurich, Switzerland

Online publish-ahead-of-print 24 March 2018

This editorial refers to ‘Patent foramen ovale closure vs. medical therapy for cryptogenic stroke: a meta-analysis of randomized controlled trials’[†], by Y. Ahmad et al., on page 1638.

The patent foramen ovale (PFO) is not considered a disease as it is present in ~20–30% of the population. Yet, it is of significant concern. Silent most of the time, the PFO can act up as a serious problem in its Mister Hyde role as the fundamental reason for paradoxical embolism engendering death, stroke, myocardial infarction, and peripheral ischaemia. More likely than late spontaneous PFO closure during life, selective mortality must be blamed for the well-documented decreasing prevalence of the PFO with age.^{1,2} Observational data on PFO carriers with thrombo-embolic events³ and long-term follow-up of random patients with or without PFO closure⁴ underpin the PFO’s licence to kill.

This issue of the journal includes an insightful meta-analysis encompassing all currently published randomized trials comparing PFO closure (mostly with continued medical therapy) with medical therapy alone in patients with cryptogenic cerebral (or systemic) ischaemic events.⁵ The superiority of PFO closure was the writing on the wall from the first randomized trial and, even before, from comparative data.⁶ However, it fell short of statistical significance in the initial randomized trials, in part because intention-to-treat analyses were used. Such analyses make little sense when implanted devices are at stake. There is no placebo effect involved and a device that stays on the shelf can hardly protect a patient against anything. Now, pre-defined *P*-values have been reached by studies concentrating on high-risk PFOs^{7,8} or following patients up for long enough;⁹ it took 3440 patients and more than 4 years of follow-up. Most turned their backs on PFO closure when it missed a superiority trial with a *P*-value of 0.08 only to embrace it enthusiastically when the *P*-value has dropped to 0.046 with extended follow-up.⁹ How strange is that? The positive result with an occluder⁸ not reaching the closure rates of Amplatzer occluders¹⁰ points out that a device may act as a filter even when it is

not watertight. This may not be the case after suture closure of the PFO.

The meta-analysis in this issue highlights the crucial point that a large PFO is more dangerous than a small PFO; why not throw in a PFO with an atrial septal aneurysm opening the PFO with virtually every heartbeat as well as a PFO with a Eustachian valve or a Chiari network, guiding the clots from the inferior vena cava straight on to the gap? The meta-analysis also expressly calls for rapid modifications of the guidelines. Guidelines so far have not acknowledged the blatant proof of non-inferiority of PFO closure vs. pure medical therapy, because the respective trials were designed as superiority trials. Failed superiority trials cannot be used to establish equipoise according to the modern stringent publication rigour. To the patient, a 15-min painless ‘mechanical vaccination’¹¹ must look more attractive than lifelong blood thinners with their ever-accruing, and with increasing age higher and more threatening, risk of bleeding. The guidelines simply do not condone such an offer to the patient. The outspoken plea to correct that adds value to this meta-analysis in comparison with recent similar publications.^{12–14} Focusing on large PFOs, in addition, sounds trivial at first but has important implications. Large PFOs can be found by simple transthoracic contrast echocardiography; small PFOs are evident only by cumbersome and unpleasant transoesophageal echocardiography. This puts a foot in the door of screening for large PFOs with the purpose of primary prevention. People before major surgery¹⁵, with a high risk for venous thrombo-embolism,³ or of families with PFO problems might be a good place to start.

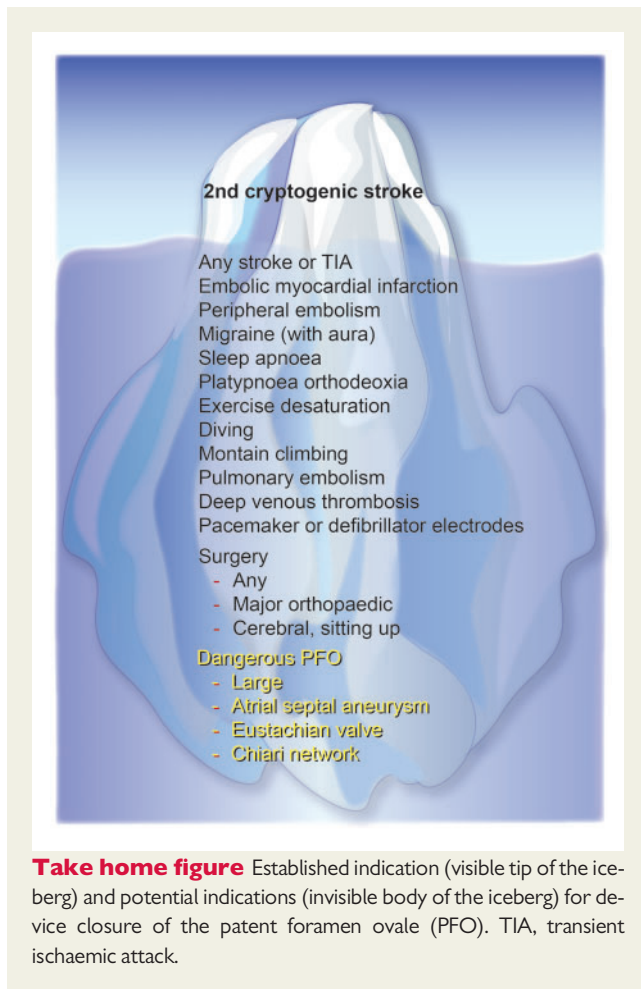
In real life, the frequency of PFO-mediated ischaemic events is underestimated. Other causes are preferentially blamed, such as atrial fibrillation, ruptured atherosclerotic plaques, or spontaneous cerebral or coronary dissections. The PFO is almost invariably the last on the list to be considered, let alone looked for. With a ratio of coronary to cerebral blood flow of ~1:3 (220 versus 750 mL/min), one PFO-mediated myocardial infarction per three PFO-mediated cerebral ischaemic events would make more sense than the 1:100 000 we seem to find in the literature. By the same token, in a large field study, high rates of coincidental strokes and myocardial

The opinions expressed in this article are not necessarily those of the Editors of the *European Heart Journal* or of the European Society of Cardiology.

[†] doi:10.1093/eurheartj/ehy121.

* Corresponding author. Department of Cardiology, University Hospital, 3010 Bern, Switzerland. Tel: +41 31 632 5830/+41 31 632 3077, Fax +41 31 382 1069, Email: bernhard.meier@insel.ch

Published on behalf of the European Society of Cardiology. All rights reserved. © The Author(s) 2018. For permissions, please email: journals.permissions@oup.com.



infarctions in patients with acute pulmonary embolism were found.¹⁶ The PFO, clearly documented as the reason for simultaneous embolism in the pulmonary and systemic circulations nine years earlier,³ was appallingly not mentioned either in the paper or in the accompanying Editorial.¹⁷

Device PFO closure can be easily accomplished as a same-day procedure with minimal discomfort and risk. The patients can hold their groin, themselves, like holding their elbow after donating blood, walk out of the catheterization laboratory, and indulge in sports an hour later. Post-treatment can be nothing or just a few weeks of low-dose acetylsalicylic acid. Acute or late complications of concern are negligible. Admittedly, all devices beget atrial arrhythmias, in rare cases even atrial fibrillation, as apparent from all meta-analyses. However, almost invariably that happens early, is transient, and does not require oral anticoagulation.

The number needed to treat to prevent one stroke by PFO closure may be extrapolated from randomized trials to be as low as two over their lifetime in patients with an index event. It may be speculated that this is even lower in patients with a high-risk PFO, when closing the PFO before rather than after an index event. Why would anyone wait for a stroke or myocardial infarction in such a patient if they can be prevented as easily as fixing a tooth, at a cost of less than €10 000? On top of that, the patients may enjoy the collateral benefits such as migraine improvement, decreased orthopnoea in platypnoea orthodeoxia, or improved physical performance in exercise

desaturation. These are examples of therapeutic rather than preventive PFO closure indications. Mind you, the collateral benefit works in both directions.

After this meta-analysis, the indication for PFO closure for prevention of a second cerebral ischaemic event after a cryptogenic index event (what a misnomer, as a stroke in the presence of a PFO is no more cryptogenic than a stroke in the presence of atrial fibrillation) is cast in stone. Or should we say cast in ice? After all, what we see with that indication is just the tip of the iceberg (*Take home figure*).

It can be harmful to withhold a therapy such as PFO closure until long-term data have proved the benefit that had been plain to see for a long time. The secret of the medical profession lies in anticipating therapies that are reasonable and that are not, and to be proactive accordingly. If one always waits for irrefutable evidence, one is sure to deprive patients. In the case of the PFO, the cause of rare but devastating events, that means that many preventable strokes, myocardial infarctions, and even deaths happened and still happen while we hesitate(d).

Conflict of interest: both B.M. and F.N. have received speaker and proctor fees from Abbott.

References

- Hagen PT, Scholz DG, Edwards WD. Incidence and size of patent foramen ovale during the first 10 decades of life: an autopsy study of 965 normal hearts. *Mayo Clin Proc* 1984;**59**:17–20.
- Tanzi A, Onorato O, Casilli F, Anzola G. Is the search for right-to-left shunt still worthwhile? *Acta Neurol Scand* 2016;**133**:281–288.
- Konstantinides S, Geibel A, Kasper W, Olschewski M, Blumel L, Just H. Patent foramen ovale is an important predictor of adverse outcome in patients with major pulmonary embolism. *Circulation* 1998;**97**:1946–1951.
- Wahl A, Jüni P, Mono ML, Kalesan B, Praz F, Geister L, Räber L, Nedeltchev K, Mattle HP, Windecker S, Meier B. Long-term propensity score-matched comparison of percutaneous closure of patent foramen ovale with medical treatment after paradoxical embolism. *Circulation* 2012;**125**:803–812.
- Ahmad Y, Howard J, Arnold A, Shun Shin M, Cook C, Petraco R, Demir O, Williams J, Iglesias J, Sutaria N, Malik I, Davies J, Mayet J, Francis D, Sen S. Patent foramen ovale closure vs. medical therapy for cryptogenic stroke: a meta-analysis of randomized controlled trials. *Eur Heart J* 2018;**39**:1638–1649.
- Agarwal S, Bajaj NS, Kumbhani DJ, Tuzcu EM, Kapadia SR. Meta-analysis of transcatheter closure versus medical therapy for patent foramen ovale in prevention of recurrent neurological events after presumed paradoxical embolism. *JACC Cardiovasc Interv* 2012;**5**:777–789.
- Mas JL, Derumeaux G, Guillon B, Massardier E, Hosseini H, Mechtouff L, Arquizan C, Bejot Y, Vuillier F, Detante O, Guidoux C, Canaple S, Vaduva C, Dequatre-Ponchelle N, Sibon I, Garnier P, Ferrier A, Timsit S, Robinet-Borgomano E, Sablot D, Lacour JC, Zuber M, Favrole P, Pinel JF, Apoil M, Reiner P, Lefebvre C, Guerin P, Piot C, Rossi R, Dubois-Rande JL, Eicher JC, Meneveau N, Lussion JR, Bertrand B, Schleich JM, Godart F, Thambo JB, Leborgne L, Michel P, Pierard L, Turc G, Barthelet M, Charles-Nelson A, Weimar C, Moulin T, Juliard JM, Chatellier G, CLOSE Investigators. Patent foramen ovale closure or anticoagulation vs. antiplatelets after stroke. *N Engl J Med* 2017;**377**:1011–1021.
- Sondergaard L, Kasner SE, Rhodes JF, Andersen G, Iversen HK, Nielsen-Kudsk JE, Settergren M, Sjostrand C, Roine RO, Hildick-Smith D, Spence JD, Thomassen L; Gore REDUCE Clinical Study Investigators. Patent foramen ovale closure or antiplatelet therapy for cryptogenic stroke. *N Engl J Med* 2017;**377**:1033–1042.
- Saver JL, Carroll JD, Thaler DE, Smalling RW, MacDonald LA, Marks DS, Tirschwell DL, RESPECT Investigators. Long-term outcomes of patent foramen ovale closure or medical therapy after stroke. *N Engl J Med* 2017;**377**:1022–1032.
- Thaman R, Faganello G, Gimeno J, Szanatho G, Neslson M, Curtis S, Martin R, Turner M. Efficacy of percutaneous closure of patent foramen ovale: comparison among three commonly used occluders. *Heart* 2011;**5**:394–399.
- Nietlispach F and Meier B. Percutaneous closure of patent foramen ovale: an underutilized prevention? *Eur Heart J*. 2016;**37**:2023–2028.
- Mojadidi MK, Elgendy AY, Elgendy IY, Mahmoud AN, Elbadawi A, Eshtehardi P, Patel NK, Wayangankar S, Tobis JM, Meier B. Transcatheter patent foramen

- ovale closure after cryptogenic stroke: an updated meta-analysis of randomized trials. *JACC Cardiovasc Interv* 2017;**10**:2228–2230.
13. Shah R, Nayyar M, Jovin IS, Rashid A, Bondy BR, Fan TM, Flaherty MP, Rao SV. Device closure versus medical therapy alone for patent foramen ovale in patients with cryptogenic stroke: a systematic review and meta-analysis. *Ann Intern Med* 2018;doi:10.7326/M17-2679.
 14. De Rosa S, Sievert H, Sabatino J, Polimeni A, Sorrentino S, Indolfi C. Percutaneous closure versus medical treatment in stroke patients with patent foramen ovale: a systematic review and meta-analysis. *Ann Intern Med* 2018;doi: 10.7326/M17-3033.
 15. Ng PY, Ng AK, Subramaniam B, Burns SM, Herisson F, Timm FP, Med C, Rudolph MI, Med C, Scheffebichler F, Med C, Friedrich S, Med C, Houle TT, Bhatt DL, Eikermann M. Association of preoperatively diagnosed patent foramen ovale with perioperative ischemic stroke. *JAMA* 2018;**319**: 452–462.
 16. Sørensen HT, Horvath-Puho E, Pedersen L, Baron JA, Prandoni P. Venous thromboembolism and subsequent hospitalisation due to acute arterial cardiovascular events: a 20-year cohort study. *Lancet* 2007;**370**:1773–1779.
 17. Lowe G. Is venous thrombosis a risk factor for arterial thrombosis? *Lancet* 2007; **370**:1742–1744.

Corrigendum

doi:10.1093/eurheartj/ehx576
 Online publish-ahead-of-print 4 October 2017

Corrigendum to: Adenoviral intramyocardial VEGF-D^{ANAC} gene transfer increases myocardial perfusion reserve in refractory angina patients: a phase I/IIa study with 1-year follow-up [*Eur Heart J* (2017); 38(33): 2547–2555]

The authors of the above article wish to inform readers that the amount given in Table 4, column 'P-value', row 'Lp(a) mg/dL' has been corrected from 0.203 to 0.023 via a post-publication correction.

The article has now been corrected online.

© The Author 2017. Published by Oxford University Press on behalf of the European Society of Cardiology.

This is an Open Access article distributed under the terms of the Creative Commons Attribution License (<http://creativecommons.org/licenses/by/4.0/>), which permits unrestricted reuse, distribution, and reproduction in any medium, provided the original work is properly cited.