Forensic Science, Medicine and Pathology
https://doi.org/10.1007/s12024-018-0081-9

CASE REPORT

Learning from the living to diagnose the dead – parallels between CT findings after survived drowning and fatal drowning

Cynthia Hourscht[1] · Andreas Christe[1,2] · Shane Diers[3] · Michael J. Thali[4] · Thomas D. Ruder[1,3]

Accepted: 25 December 2018

Abstract

A case of survived drowning is presented where CT findings of the lungs were in keeping with several findings seen on post-mortem CT (PMCT) examination after fatal drowning. These findings include interlobular septal thickening, peribronichal cuffing, mosaic pattern ground glass opacities, and perivascular nodular ground glass opacities. The absence of confounding normal post-mortem changes allows for a discussion on subtle differences between findings related to aspiration and pulmonary edema after drowning. This case represents a learning opportunity for radiologists and pathologists challenged by the complex lung findings after drowning on PMCT.

Keywords Forensic radiology · Computed tomography · Drowning · Aspiration · Edema

Introduction

Pulmonary findings on post-mortem computed tomography (PMCT) after fatal drowning vary depending on case circumstances and can range from subtle ground glass opacities to diffuse air space consolidations [1–3]. According to Christe et al. the presence of a mosaic pattern of ground glass opacities is a distinct finding on PMCT after drowning [1]. However, interpreting lung findings on PMCT is often challenging due to the presence of confounding post-mortem changes like hypostasis (also referred to as dependent fluid sediment and internal lividity) and dependent atelectasis [4–7]. These normal post-mortem findings can mimic and/or mask pathology [4–7]. Separating drowning related pathology from normal findings on post-mortem CT can therefore be very difficult.

Radiologists involved in post-mortem imaging often draw on their clinical training and experience to read PMCT. Many distinct findings and fundamental radiologic concepts can be transferred from clinical to post-mortem radiology, in spite of the generally accepted differences between the two fields [6–9]. An experienced emergency radiologist for example, will recognize traumatic injuries on PMCT without difficulty.

Cases of survived drowning are not rare in the literature [10]; however, they are a rarity in the clinical practice of many radiologists [6] and exceptionally rare in the practice of these authors. In addition, the emphasis of imaging in patients after survived drowning lies on assessing the extent of pulmonary disease rather than *making a diagnosis* of drowning on the basis of distinct imaging pattern [6, 10]. This also explains why the literature dedicated to the description of pulmonary findings on CT after non-fatal drowning is quite limited and relatively old [11, 12]. Due to this lack of exposure to non-fatal drowning cases in their clinical practice and the limited literature available, radiologists often struggle as much as pathologists when asked to separate drowning related pulmonary pathology from normal changes on PMCT [6–9].

Here we present a case of survived drowning where CT was performed within 2h after the event. The early acute pulmonary findings seen on CT in this case of survived drowning are consistent with several classic findings known from post-mortem CT after fatal drowning. The absence of confounding normal post-mortem changes allows for a discussion on subtle

✉ Thomas D. Ruder
thomas.ruder@northlanddhb.org.nz; thomas_ruder@hotmail.com

1 Institute of Diagnostic, Interventional, and Pediatric Radiology, University Hospital Bern, CH-3010 Bern, Switzerland

2 Department of Radiology, Tiefenauspital, CH-3004 Bern, Switzerland

3 Department of Radiology, Northland District Health Board, Whangarei Hospital, Whangarei 0148, New Zealand

4 Institute of Forensic Medicine, University of Zurich, CH-8057 Zurich, Switzerland

Published online: 09 January 2019

differences between findings related to aspiration and edema after drowning. This case represents a learning opportunity for both radiologists and pathologists challenged by the complex lung findings on PMCT after drowning.

Case circumstances and CT findings

A middle-aged, otherwise healthy patient was admitted to hospital after a non-fatal drowning incident. The patient had experienced acute dyspnea while swimming in a river and was submerged several times before reaching the shore with help from other swimmers. On admission, the patient reported having aspirated of small amounts of water and experiencing short bouts of coughing, but no loss of consciousness during the entire event. Clinical exam revealed bilateral pulmonary crackles, speech-dyspnea, and partial respiratory insufficiency with decreased levels of blood oxygen saturation.

Chest CT (Somatom Definition Edge, Siemens Healthineers, Erlangen, Germany) was performed within the first hour of admission. CT of the lungs revealed interlobular septal thickening, peribronchial cuffing, and both mosaic pattern ground glass opacities as well as nodular perivascular ground glass opacities (Fig. 1). There was no airspace consolidation.

The patient was kept under surveillance overnight and discharged the following morning after having fully recovered. There was no follow-up imaging after patient discharge.

Discussion

The CT findings in this case represent early acute pulmonary changes after survived drowning. The changes seen in this case of survived drowning feature several parallels to changes seen on PMCT after fatal drowning [1–3, 11, 12]. However, due to the absence of confounding normal post-mortem changes, the drowning related findings are more clearly visualized.

The cascade of drowning begins with aspiration of small amounts of water [13]. This is in agreement with the patient history in this case. Mucosal irritation from aspiration causes both acute laryngospasm and bronchospasm to protect the airways from further aspiration [1, 13, 14]. Aspiration also leads to peribronchial cuffing (bronchial wall thickening) - reflecting an attempt to remove excessive fluid from the airways [1]. Peribronchial cuffing is also seen in inflammatory diseases of the small airways [15, 16] and it is therefore likely that the inflammatory response triggered by mucosal irritation after aspiration also contributes to the bronchial wall thickening. Once aspirated fluids reach the secondary pulmonary lobules, the typical pattern of well-defined mosaic ground glass opacities, scattered throughout the lung is visible on CT [1]. Both peribronchial cuffing and mosaic ground glass opacities were present on CT in this case.

Over time, laryngospasm causes hypoxia which triggers pulmonary edema [11, 17]. Early CT signs of pulmonary edema include subtle interlobular septal thickening and peribronchial cuffing [11, 12]. These changes may progress to non-dependent nodular ground glass opacities and diffuse airspace opacification [11, 12]. In the here reported case, interlobular septal thickening, peribronchial cuffing, and nodular ground glass opacities were also visible.

In distinction to the scattered and well defined ground glass opacities after aspiration of small amounts of water, ground glass opacities from edema are typically central in location, perivascular in distribution, nodular in shape, and have more ill-defined contours. However, both types of ground glass

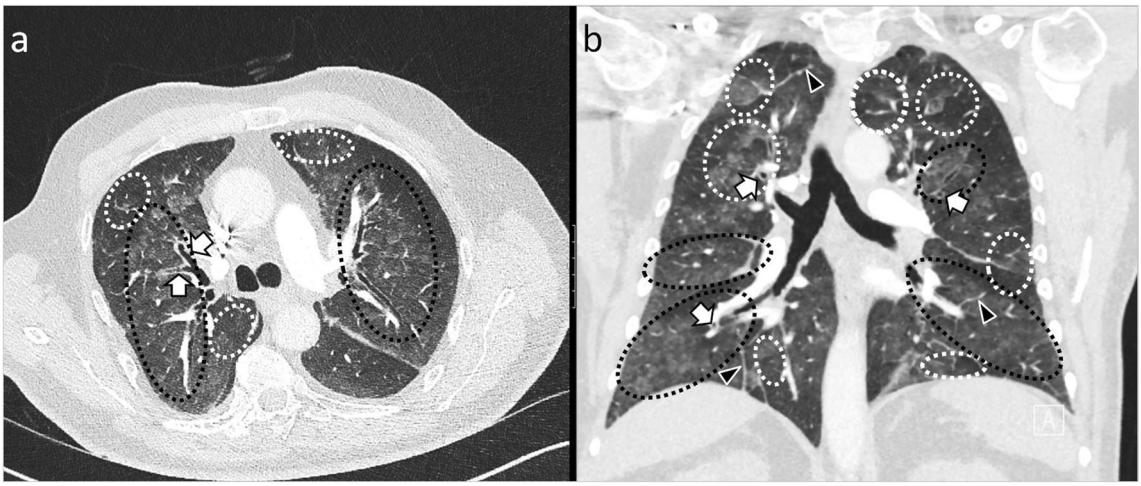

Fig. 1 CT of the lungs after non-fatal drowning, axial view (**a**) and coronal reformat (**b**). Relevant findings include signs of aspiration with peribronchial cuffing (white arrows) and mosaic ground glass opacities (white dotted circles), as well as signs of pulmonary edema with peribronchial cuffing (white arrows), interlobular septal thickening (black arrowheads), and perivascular nodular ground glass opacities (black dotted circles). Peribronchial cuffing from aspiration and edema are indistinguishable on CT

opacities represent a form of excessive alveolar fluid and their imaging characteristics on CT increasingly overlap with increasing fluid accumulation. There is no difference between peribronchial cuffing from aspiration and from edema on CT.

Finally, prolonged hypoxia results in loss of consciousness and relaxation of the laryngospasm and subsequent aspiration of large amounts of water [13, 14]. Airspace consolidations will be present on CT images after aspiration of large quantities of fluid [1, 11, 14]. There were no airspace consolidations in this case.

Conclusion

Lung findings on CT in this case of survived drowning overlap with established lung findings on PMCT after fatal drowning. Due to the absence of normal post-mortem changes in survived drowning, findings related to aspiration and pulmonary edema are more clearly visible. This case provides a learning opportunity for radiologists and pathologists involved in post-mortem imaging and may allow them to identify drowning related findings on PMCT scans and distinguish them from normal post-mortem changes with a higher level of confidence.

Key points

1. Lung findings on CT in this case of survived drowning overlap with established lung findings on post-mortem CT (PMCT) after fatal drowning.
2. Drowning related pulmonary CT findings include interlobular septal thickening, peribronichal cuffing, mosaic pattern ground glass opacities, and perivascular nodular ground glass opacities.
3. Due to the absence of confounding normal post-mortem changes in survived drowning, findings related to aspiration and pulmonary edema are more clearly visible.

Compliance with ethical standards

Conflict of interest The authors have no conflict of interest.

Ethical approval Approval by Ethical Committee is not required for case reports as single case descriptions do not fulfil the criteria of research as defined by the Human Research Act.

Informed consent Patient information has been withheld and case details have been slightly modified (without changing their significance to the case report) to protect patient anonymity.

References

1. Christe A, Aghayev E, Jackowski C, Thali MJ, Vock P. Drowning–post-mortem imaging findings by computed tomography. Eur Radiol. 2008;18:283–90.
2. Usui A, Kawasumi Y, Funayama M, Saito H. Post-mortem lung features in drowning cases on computer tomography. Jpn J Radiol. 2014;32:414–20.
3. Plaetsen S, Letter E, Piette M, Parys G, Casselman J, Verstraete K. Post-mortem evaluation of drowning with whole body CT. Forensic Sci Int. 2015;249:35–41.
4. Ruder TD. On radio-morphologic correlation of post-mortem findings in human lungs in forensic medicine. Doctoral thesis. Bern: University of Bern; 2004.
5. Germerott T, Preiss US, Ebert LC, Ruder TD, Ross S, Flach PM, et al. A new approach in virtopsy: post-mortem ventilation in multislice computed tomography. Leg Med (Tokyo). 2010;12:276–9.
6. Christe A, Flach P, Ross S, Spendlove D, Bolliger S, Vock P, et al. Clinical radiology and postmortem imaging (Virtopsy) are not the same: specific and unspecific postmortem signs. Leg Med (Tokyo). 2010;12:215–22.
7. Sutherland T, O'Donnell C. The artefacts of death: CT post-mortem findings. J Med Imaging Radiat Oncol. 2018;62:203–10.
8. Burke M, O Donnell C. Postmortem computed tomography findings in ruptured splenic artery aneurysm: value of the clinical "sentinel clot" sign in identification of bleeding location. Am J Forensic Med Pathol. 2015;36:224–6.
9. Ruder TD, Schweitzer W, Ampanozi G, Gascho D, Flach PM, Thali MJ, et al. Imaging findings of diabetes on post-mortem CT. J Forens Radiol Imag. 2018;13:27–41.
10. Olshaker JS. Submersion. Emerg Med Clin North Am. 2004;22:357–67.
11. Gluecker T, Capasso P, Schnyder P, Gudinchet F, Schaller MD, Revelly JP, et al. Clinical and radiologic features of pulmonary edema. Radiographics. 1999;19:1507–31.
12. Kim KI, Lee KN, Tomiyama N, Johkoh T, Ichikado K, Kim CW, et al. Near drowning: thin-section CT findings in six patients. J Comput Assist Tomogr. 2000;24:562–6.
13. Orlowski JP. Drowning, near-drowning and ice-water submersion. Pediatr Clin N Am. 1987;34:75–92.
14. Luijkx T, Weerakkody Y. Near drowning pulmonary oedema. Radiopaedia https://radiopaedia.org/articles/near-drowning-pulmonary-oedema. Accessed 19 Sept 2018.
15. Knipe H, Weerakkody H. Peribronchial cuffing. Radiopaedia. https://radiopaedia.org/articles/peribronchial-cuffing-1. Accessed 21 Dec 2018.
16. Bramson RT, Griscom NT, Cleveland RH. Interpretation of chest radiographs in infants with cough and fever. Radiology. 2005;236:22–9.
17. Rumbak M. The etiology of pulmonary edema in fresh water near-drowning. Am J Emerg Med. 1996;4:176–9.