European Radiology
https://doi.org/10.1007/s00330-019-06033-x

HEAD AND NECK

Value of 3T craniocervical magnetic resonance imaging following nonfatal strangulation

Jakob Heimer[1] · Carlo Tappero[1,2] · Dominic Gascho[1] · Patricia Flach[1,3] · Thomas D. Ruder[1,2,4] · Michael J. Thali[1] · Sabine Franckenberg[5]

Received: 6 September 2018 / Revised: 14 December 2018 / Accepted: 22 January 2019

Abstract

Objective The aims of this study were (1) to provide an overview of craniocervical magnetic resonance imaging (MR) findings following nonfatal strangulation (NFS), (2) to detect the time dependency of the presence of these findings, and (3) to explore the additional value of MR with regard to the forensic interpretation of NFS.

Methodology All 633 victims of manual strangulation between October 2011 and March 2018 were examined, including the case history and external findings. Following written consent, 114 cases were included in the study. The duration between the event, clinical forensic examination, and MR was noted. Radiologic images were reviewed by a clinical and a forensic radiologist.

Results The case group consisted of 90 women and 24 men with a mean age of 32.5 years. Delimitable external findings were present in 93% ($N = 106$) of cases. MR yielded a positive finding in 43% of cases ($N = 49$). There was no significant difference in the mean time interval between examinations between MR-positive and MR-negative cases. Perilaryngeal fluid accumulation was associated with difficulty swallowing and victims put in a chokehold. All cerebral MR were unremarkable, except for one patient with edema of the corpus callosum.

Conclusions The role of craniocervical MR following NFS is currently limited, particularly with regard to the forensic interpretation of NFS. MR may reveal internal injury in victims who report subjective symptoms of airway compression and in those who were placed in a chokehold. The presence of MR findings is not dependent on immediate examinations following the assault.

Key Points

- *Magnetic resonance imaging does not currently provide additional value for the estimation of the severity of nonfatal manual strangulation.*
- *Magnetic resonance imaging of the neck may reveal internal injury in cases without external findings, particularly in victims placed in a chokehold and with symptoms of airway compression.*
- *The incidence of carotid artery dissections and laryngeal fractures is low in victims of nonfatal manual strangulation.*

Keywords Magnetic resonance imaging · Forensic pathology · Forensic science · Neck injuries · Facial injuries

✉ Jakob Heimer
Jakob.Heimer@irm.uzh.ch

[1] Institute of Forensic Medicine, Department of Forensic Medicine and Imaging, University of Zurich, Winterthurerstrasse 190/52, CH-8057 Zurich, Switzerland

[2] Institute of Diagnostic, Interventional, and Paediatric Radiology, University Hospital Bern, CH-3010 Bern, Switzerland

[3] Cantonal Hospital St. Gallen, Clinic for Radiology and Nuclear Medicine, CH-9007 St. Gallen, Switzerland

[4] Department of Radiology, Whangarei Hospital, Northland District Health Board, Whangarei 0148, New Zealand

[5] Institute of Diagnostic and Interventional Radiology, University Hospital Zurich, Raemistrasse 100, CH-8091 Zurich, Switzerland

Published online: 22 February 2019

Abbreviations

ADC	Apparent diffusion coefficient
CT	Computed tomography
DWI	Diffusion-weighted imaging
FRFSE	Fast relaxation fast spin echo
FSPGR	Fast spoiled gradient echo
NFS	Nonfatal strangulation

Introduction

Manual strangulation describes the external compression of the neck with the hands, arms, or a ligature tool (ligature strangulation). While the potential fatality of manual strangulation is well recognized, the causal chain leading to death is still not fully understood. However, four main mechanisms are discussed: airway occlusion, venous occlusion, arterial occlusion, and nerve reflexes [1]. Increasing pressure on the neck successively leads to the obstruction of the jugular veins (at 2 kg), the carotid arteries (5 kg), and the airways (≥ 15 kg) [2]. While vascular occlusion with subsequent cerebral hypoxia has been considered the most relevant cause of death, the mechanism of death in manual strangulation is contemporarily understood as a multifactorial spectrum of congestive-petechial, asphyctic, and cardiac [1]. This ambiguity and the high variability in both action and outcome complicate the clinical forensic assessment of cases of nonfatal strangulation (NFS) [3], especially with regard to the juridical classification and estimation of "severity" or "danger to life" [4, 5].

The clinical forensic assessment of NFS is further complicated by the fact that external signs of injury in NFS are often discrete and may be absent on as many as 50% of cases [6]. When injuries are visible, hematoma, swelling, abrasions, fingernail marks, and congestive petechial hemorrhages of the conjunctivae, the eyelids, and the facial skin are common [3, 7]. Hyoid bone or laryngeal fractures, as well as carotid dissections, are rare [8, 9]. Victims often report symptoms such as localized pain, hoarseness, shortness of breath, and difficulty swallowing and speaking [10, 11]. Subjective symptoms such as unconsciousness, loss of urine or feces, and optical or acoustical sensations are generally accepted indicators of cerebral hypoxia and therefore of a life-threatening assault [7].

In an attempt to classify the severity of NFS, Plattner et al described three levels of severity [7], namely, "light strangulation," with skin abrasions and hematoma, "moderate strangulation," with additional symptoms of airway compression, and "severe life-threatening strangulation," with additional petechial hemorrhages with or without subjective symptoms of cerebral hypoxia. This classification reveals the prominence of petechial hemorrhages as the only external finding indicating a sufficient pressure and duration of strangulation to constitute a life-threatening danger in an assault. However, the minimum time of constant pressure for petechial hemorrhages to form is vaguely estimated to be approximately 15–30 s, and valid data is unobtainable [1]. The diagnostic ambiguity is reinforced by the fact that petechial hemorrhages are also known to form in commonplace, valsalva-related states of sudden changes in venous pressure [12].

Due to these concerns, cervical magnetic resonance imaging (MR) was experimentally introduced as a clinical forensic assessment in strangulation cases a decade ago. The new approach was expected to shed light on internal injuries impossible to document through an external examination, an assumption fueled by the fact that internal hemorrhage is often seen at autopsy and postmortem computed tomography in cases of fatal hanging and strangulation [13–17]. Currently, four publications have evaluated the use of MR in cases of survived strangulation. After the first descriptions by Yen et al [18, 19], Christe et al documented a variety of MR findings in a group of 56 cases of NFS [20, 21]. Cerebral MR has so far not been investigated in cases of NFS.

The aims of this study were (1) to provide an overview of craniocervical MR findings following NFS, (2) to detect the time dependency of the presence of these findings, and (3) to explore the additional value of MR with regard to the forensic interpretation of NFS.

Materials and methods

Study population

All victims ($N = 633$) of nonfatal strangulation between October 2011 and March 2018 were offered to undergo noncontrast MR of the head and neck (exclusion: initial presentation > 72 h after the event, < 16 years of age, pregnancy, medical contraindications to MR). The MR was offered free of charge. When informed consent was obtained, the earliest-available appointment for a clinical MR examination was arranged, and a voucher for individual transportation to the examination site was issued. Of the 117 patients that agreed to the radiological examination, three patients had to be excluded due to premature interruption linked to claustrophobia. Five cases had severe movement artifacts in some of the sequences, but these cases were not excluded from the study.

Clinical examination

Cases were examined according to the national standard guidelines [22]. Manual strangulation was defined as a reported attack to the neck with either one hand, both hands, placement in a chokehold (defined as neck compression involving flexing the arm to exert pressure on the neck), or a ligature strangulation. All cases underwent routine clinical forensic examination consisting of thorough written and photographic documentation of the external findings. A detailed case

history was noted. Patients were interviewed for transitory signs of cerebral hypoxia (loss of consciousness, urine/feces discharge) and symptoms of airway compression (difficulty breathing/swallowing, hoarseness, localized pain). The severity of the assault was determined separately for each case based on the history and findings and classified as "life-threatening" or "nonlife-threatening" by a forensic pathologist in training and her/his supervising board-certified forensic pathologist. Cases with petechial hemorrhages and/or signs of transient hypoxia were classified as "life-threatening" as per the national guidelines on strangulation [22].

MR examination and assessment

All examinations were conducted with a 3T MR (Discovery MR750w, GE Healthcare) at an associated MR center of the University Hospital of Zurich. MR was performed according to a standardized, noncontrast study protocol for the neck and head (Table 1). This standard protocol was partially modified over time. In seven cases, radiologists autonomously authorized the addition of postcontrast sequences to the standard noncontrast protocol. The postcontrast sequences were excluded from this study. MR studies were primarily reported by a radiologist in training and amended and authorized by his/her supervising board-certified neuroradiologist. All MR studies were double-reported by a second board-certified radiologist with experience in forensic imaging. Radiologists were not blinded to basic case circumstances. MR was systematically assessed for the presence of (sub-)cutaneous, intramuscular, and (peri-)laryngeal fluid accumulation, as described by Christe et al [20]. Moreover, laryngeal and hyoid fractures fractures/deformations, lymph node hemorrhages, platysmal thickening, and abnormalities of the vessel-nerve-sheath were documented.

Statistical analysis

Statistical analysis and plots were computed with R [23]. Proportions of categorical variables were compared with a χ^2 test. Means of Gaussian-distributed, metric variables were compared with Student's t test. A p value of < 0.05 was used as the threshold for statistical significance.

Results

Study population

The study population consisted of 90 women and 24 men with a mean age of 32.5 years (median 29.7, SD 12.3, range 16.2–70.0). Two-handed attacks were most prevalent ($N = 48$, 41.1%), followed by one-handed attacks ($N = 47$, 41.2%), chokeholds ($N = 14$, 12.3%), and manual ligature strangulation ($N = 5$, 4.4%) (Fig. 1). In all cases of ligature strangulation, the material used was soft and thick (e.g. towel or scarf). Chokeholds were more frequent in men than in women, while one- and two-handed attacks were more frequent in women ($p < .001$, χ^2). An overview of external, subjective, and radiological findings is presented in Table 2. Thirty-eight cases (33.3%) were considered to be life-threatening assaults.

Examination time intervals

Time intervals between the examinations are illustrated in Fig. 2. The mean time interval from the assault to the external examination was 14.3 h, 34.1 h from the exam to MR, and 48.3 h from the event to MR. Regarding the mean time interval between external examination and MR of cases which presented external findings ($N = 106$), there was no significant difference between cases with positive MR (36.7 h) and negative MR (32.9 h, t test, $p = 0.373$).

External and subjective findings

External findings (abrasions, hematoma, swelling, petechial hemorrhage) were present in 106 (93%) of cases. Sixty-seven cases presented with external findings in both regions (58.8%), while 21 (18.4%) and 18 (15.8%) cases presented with findings of the neck and face alone, respectively. Subjective findings were present in 95 cases (83.3%). Indicators of central hypoxia (loss of urine or loss of consciousness) were more frequent in chokeholds (7/14, 50%) and two-handed attacks (15/48, 31.2%) than in one-handed attacks (8/47, 17.0%) and ligature strangulation (0/5, 0%; $p = 0.036$, χ^2). There were no cases with loss of feces. Trouble swallowing was also more often observed in chokeholds (10/14, 71.4%) than in two-handed strangulation (28/48, 58.3%), one-handed strangulation (27/47, 57.4%), and ligature strangulation (1/5, 20%, χ^2 not significant, $p = 0.26$).

Radiologic findings

MR yielded a positive finding in 49 (43.0%) cases. Positive findings in 31 (27.2%) cases were limited to the cervical MR, in 7 (6.1%) cases, the positive findings were limited to the cranial MR, and in 11 (9.6%) cases, there were positive findings in both the cervical and cranial MR. The total number of radiologic findings attributed to the assault was 76, with superficial cutaneous fluid accumulation being the most prevalent ($N = 26$), followed by subcutaneous fluid accumulation ($N = 15$) and lymph node hemorrhages ($N = 13$) (Table 2). There were no cases with carotid dissection. All cerebral MR but one were negative for hypoxia-related findings. In this case, localized edema was identified in the corpus callosum (Fig. 3). In one case, both laryngeal superior horns

Table 1 Overview of used MR sequences. *DWI* diffusion-weighted imaging, *ADC* apparent diffusion coefficient, *FRFSE* fast relaxation fast spin echo, *FSPGR* fast spoiled gradient echo

Neck sequences	TE (ms)	TR (ms)	Slice thickness (mm)	Number	%
T1 water FS—axial	10	700	4	110	96.5
T2 water FS—axial	80	9000	4	113	99.1
T1 water FS—coronal (until 9/2013)	10	700	4	50	43.9
T2 water FS—coronal (from 9/2013)	80	9000	4	63	55.3
T1 InPhase FS—axial	10	700	4	66	57.9
T2 InPhase FS—axial	80	9000	4	98	86.0
Head sequences					
DWI—axial	100	6000	4	111	97.4
T2 a1 FRFSE ARC	100	8000	4	112	98.2
T1 as FSPGR 3D	4	10	1.5	112	98.2
ADC	100	6000	4	85	74.6
Exponential ADC	100	6000	4	75	65.8
Special sequences					
Examination with contrast agent				7	6.1

were fractured at their base (Fig. 4—case IV). No hyoid fractures were detected. The clinical radiologists detected radiologic findings associated with the assault in 21 cases, which was significantly less than the forensic radiologists ($N = 49$, $p < 0.001$, χ^2).

Associations of radiologic findings

More MR findings per case were detected in life-threatening assaults (0.89 findings per case) than in nonlife-threatening assaults (0.47 findings per case, $p = 0.005$, t test). There was no specific finding or localization of finding associated with a life-threatening assault. In 26 of 106 cases with external findings (hematoma, abrasions) of the face and neck, MR showed corresponding findings (superficial and subcutaneous fluid accumulation, platysma thickening, lymph node hemorrhage). In 10 cases, MR revealed radiologic findings when the external examination of the neck was unremarkable (five subcutaneous hematomas, three cases of lymph node hemorrhage, two cases of perilaryngeal fluid accumulation). Two of these cases are illustrated in Table 3 and Fig. 4. Perilaryngeal fluid accumulation/edema was seen in 15 cases. These cases were significantly associated with difficulty swallowing ($N = 14/15$, $p = 0.003$, χ^2) and with the occurrence of chokeholds ($N = 5/15$, $p = 0.047$, χ^2). Two cases with the trias of chokehold (I), difficulty swallowing (II), and positive laryngeal MR (III) findings are illustrated in Table 3 and Fig. 5.

Discussion

This study shows that a generalized application of MR in cases of NFS is not currently indicated for either therapeutic or legal reasons. Cervical MR may provide additional value in specific cases, such as chokeholds, or reported symptoms of airway compression. Despite available reports on radiological findings of cerebral hypoxia in (often temporary) survivors of hanging [24–26], we only identified a single case with localized edema possibly related to the assault. As none of the study participants presented with neurological symptoms, cranial MR does not add additional value in these cases. The complete absence of carotid dissections following manual strangulation in the entire study population is a crucial finding with implications for clinical management: carotid artery dissection clearly is an exceptionally rare pathology after manual strangulation, and not present in this sample. This implies that when victims that survive strangulation present to emergency departments for clinical assessment and radiologic investigations, especially computed tomography angiography, imaging should be limited to patients with a high clinical suspicion of dissection.

The interval between the event and the clinical forensic examination was shorter than the interval between the examination and the MR. This implicitly demonstrates the logistic effort required for a clinical forensic MR assessment. In many cases, potential study participants did not agree to undergo MR because of personal obligations, particularly related to child care (no exact data documented). While it was first assumed by the authors that an as-soon-as-possible MR examination would lead to a higher frequency of MR findings associated with the assault, a significant difference between the mean time interval from external examination to MR between MR-positive (36.7 h) and MR-negative cases (32.9 h) could not be found. While it may be true that long time intervals between the event and MR examination lead to false negative results, we have no reason to assume that MR findings become less visible within a time interval of 72 h, which was the recommended interval based on the previous investigation by Yen et al [19].

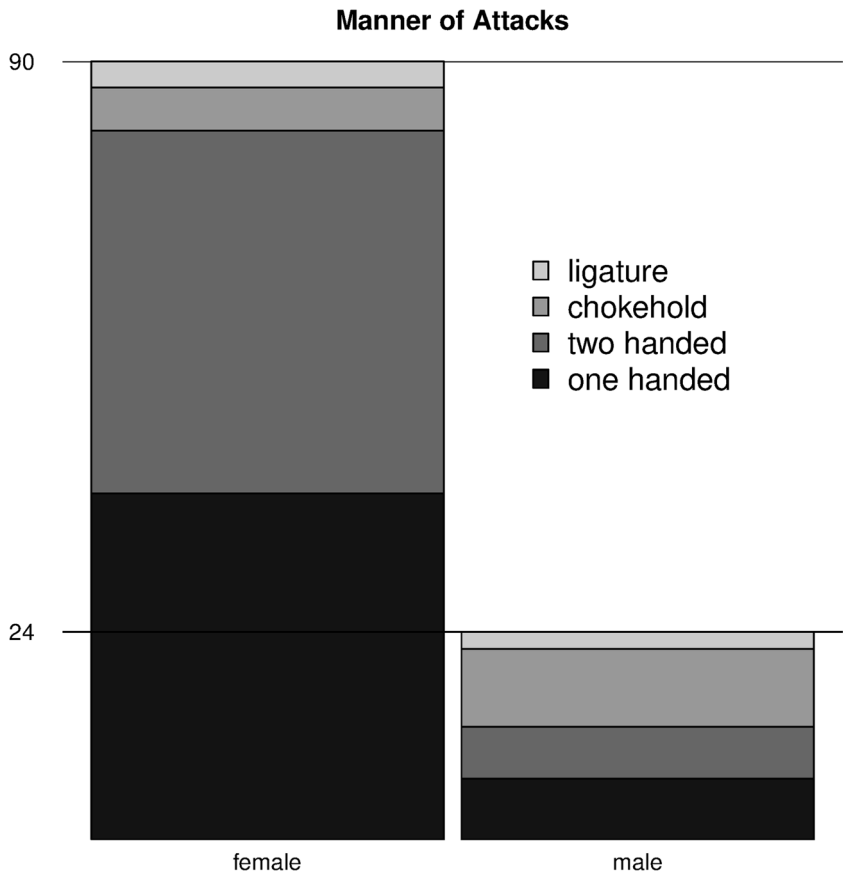

Fig. 1 Stacked bar plot of the sex of cases and the distribution of the manner of attacks: one-handed ($N = 40$(female)/7(male)), two-handed ($N = 42/6$), chokehold ($N = 5/9$), ligature ($N = 3/2$). Black lines: total number of cases ($N = 90/24$)

Despite the higher number of MR findings in assaults that were life-threatening (0.89 findings per case), MR findings correlated with "life-threatening" NFS according to Yen et al [18], i.e., findings at the vascular sheath ($N = 1$), airway-involvement ($N = 15$), and lymph node hemorrhage ($N = 13$), were uncommon and not associated with the classification of "life-threatening" in this sample. In Switzerland, the estimation of life-threatening assaults is strictly based on national guidelines, which limits this classification to the presence of petechial hemorrhage and symptoms of cerebral hypoxia. Based on our data, MR cannot currently serve in the estimation of severity. It should not be conducted in nonsevere cases with few or no external findings and symptoms, and in cases where the severity can already be determined by the presence of petechial hemorrhages and/or symptoms of transient hypoxia.

Therefore, MR following NFS may only add value for forensic interpretation by documenting or "proving" injuries that cannot be identified during the external examination, which is considered the primary purpose of MR in NFS. In more than half MR-positive cases, MR was only able to document (sub-)cutaneous fluid accumulation with a low sensitivity compared to the clinical forensic examination (26/106 = 24.5%), which is irrelevant for the forensic assessment and insignificant for therapeutic assessment. However, MR detected assault-related cervical findings in 10 cases that did not have any external findings of the neck, and the data show that MR may be a valuable asset for the visualization of subjective findings of airway compression, such as difficulty swallowing, difficulty breathing, and localized pain. Particularly, chokeholds appear to be associated with few external findings (data not shown, as external injury was not quantified), subjective airway symptoms such as trouble swallowing (10/14, 71.4%), and laryngeal MR findings (5/15, 33.3%). This association was already reported by Stanley et al in three cases in 1983 [27]. The application of MR in these cases provides additional value for both forensic and clinical-diagnostic problems.

This study was not able to reproduce the same number of findings as previous studies. Christe et al presented 121 radiological findings (lymph node enlargement not included) in 56 cases (2.16 findings/case) [20], whereas this work describes 75 MR findings in 114 cases (0.67 findings/case). All examinations in this study were conducted on a 3T MR, in comparison to the 1.5T MR used in previous studies, and higher spatial resolution may lead to more conservative interpretations of radiologic deviations. It is also possible that earlier works selected patients based on the severity of external findings, which was not the case in this study. Furthermore, the lack of standardization for this specific radiologic modality

Table 2 Overview of all findings. *Fluid accumulation

		N	%
	External findings		
Face	Hematoma	53	46.5
	Abrasion	49	43
	Swelling	29	25.4
	Mucosal defect	22	19.3
	Petechiae	17	14.9
Neck	Hematoma	72	63.2
	Abrasion	38	33.3
	Petechiae	4	3.5
	Subjective findings		
	Loss of urine	16	15
	Loss of feces	0	0
	Loss of consciousness	16	14
	Hoarseness	20	17.5
	Localized pain	44	38.6
	Trouble swallowing	65	57
	Trouble breathing (during attack)	45	39.5
	MRI findings		
Brain	Localized edema	1	0.9
Face	Facial soft tissue (superficial)*	17	14.9
	Peri-/auricular (superficial)*	3	2.6
Neck	Platysma thickening	5	4.4
	Lymph node—hemorrhage	13	11.4
	Cervical soft tissue (superficial)*	6	5.3
	Cervical soft tissue (subcutaneous)*	15	13.2
	Vessel-nerve sheath*	1	0.9
	Laryngeal fracture	1	0.9
	Peri-/laryngeal*	14	12.3
	Carotid dissection	0	0

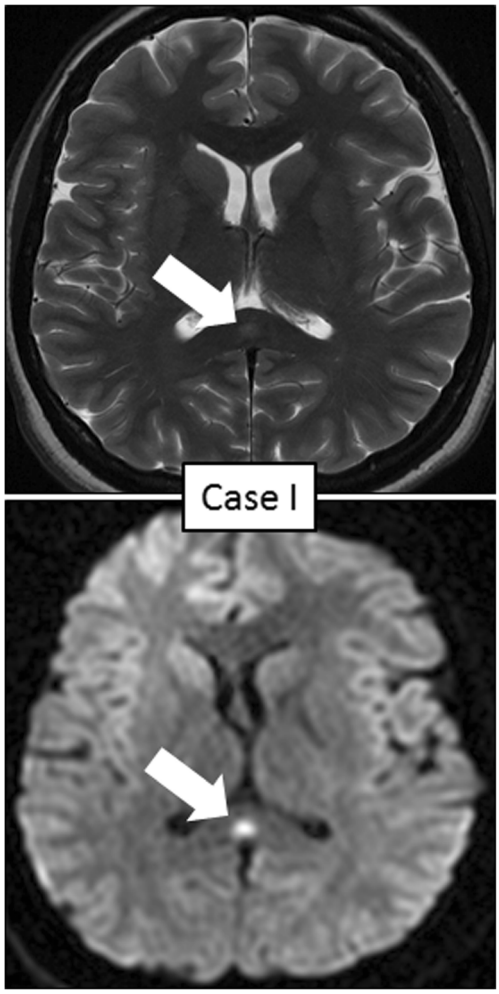

Fig. 3 Illustration of case I. Top: T2; bottom: DWI. In this case, a hyperintensity and a diffusion restriction in the splenium of the corpus callosum (white arrow) were identified

leads to high diagnostic subjectivity. In addition to interstudy differences, diagnostic success was significantly higher with forensic radiologists. This not only emphasizes the importance of experience with forensic science when reviewing radiologic material but also demonstrates the difference between the

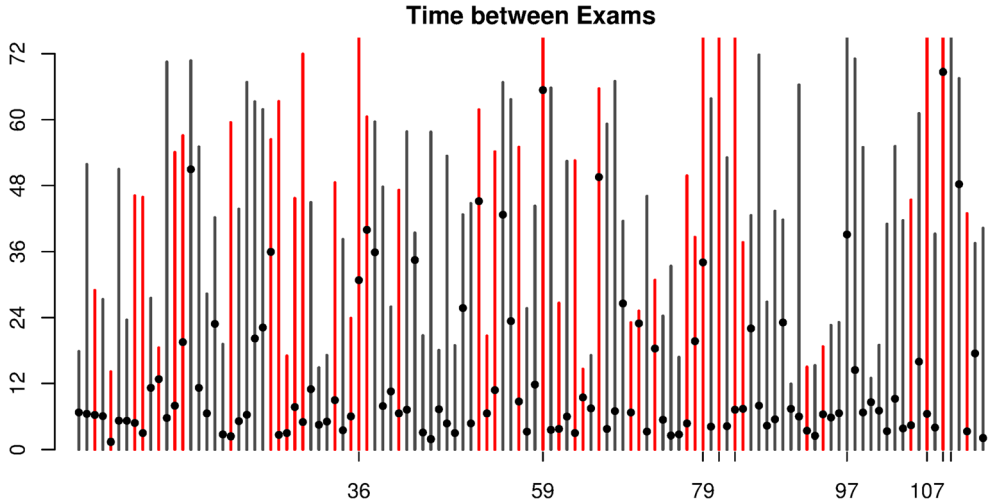

Fig. 2 Overview of the time intervals between examinations. *X*-axis: consecutive cases in chronological order; *Y*-axis: time (hours); black dots: time to clinical forensic examination; black dot to end of the line: time between clinical forensic examination and MR; black lines: cases with negative MR; red lines: cases with positive MR; ticks on *X*-axis: cases with a total time above 72 h (cases 36, 59, 79, 81, 83, 97, 107, 109, and 110)

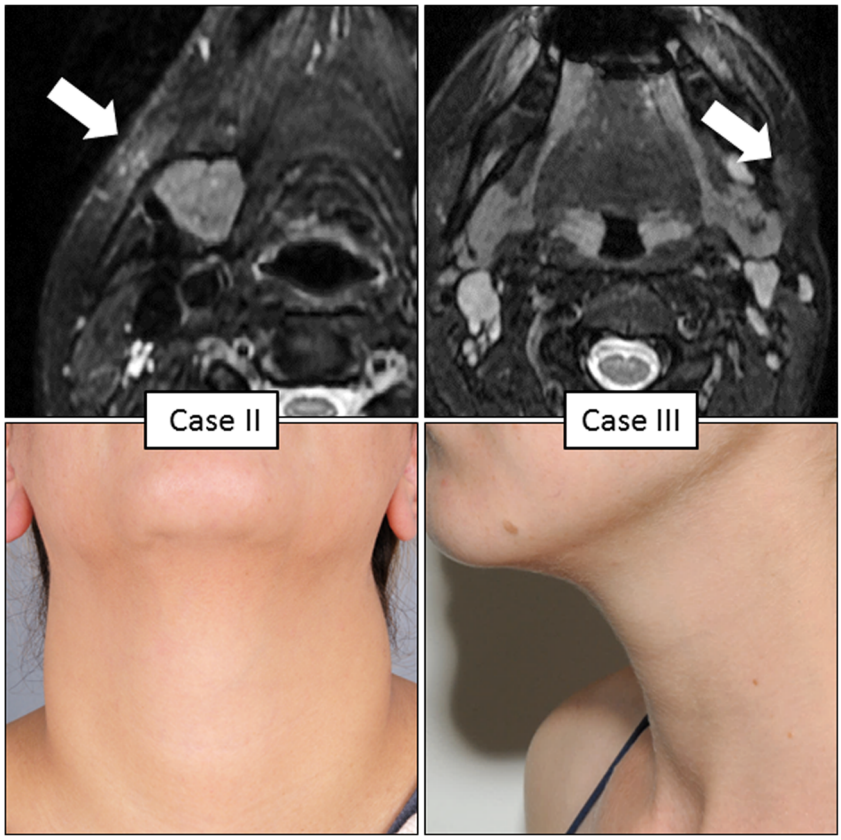

Fig. 4 Illustration of cases II and III. Both cases presented with no external findings of the neck, but MR revealed subcutaneous hemorrhage (white arrows). Sequences: fat-suppressed T2

therapeutic and the forensic perspective when reviewing the same material.

Computed tomography (CT) is a potent alternative to MR, and its ability to detect laryngeal and hyoid fractures has been shown in clinical and postmortem studies [16, 28]. CT may also detect soft tissue hemorrhage, but with lower sensitivity compared to autopsy [16]. However, soft tissue contrast is better in MR, and the exposure to radiation in the particularly young population of NFS survivors (mean age 32.5 years in this sample) poses an unanswered ethical problem. These disadvantages make CT a nonviable alternative for survivors of NFS.

This study has several limitations that deserve comment. First, the 114 subjects included represent a small subgroup of all 633 victims of strangulation. The patient selection may have introduced bias, and this subgroup may not be representative of all victims of manual strangulation examined. It is important to note that all study participants were vigilant at the

Table 3 Examples of specific cases

	Sex	Age	Assault	External findings	Subjective findings	MRI findings
Case I	f	34	One handed	Abrasion at left eyebrow	Trouble swallowing, pain	Edema at corpus callosum
Case II	f	42	Ligature (towel)	None	Trouble swallowing, pain, hoarseness	Cervical subcutaenous right-sided hematoma
Case III	f	30	Both handed	None	None	Left-sided submandibular hematoma
Case IV	m	51	Choke hold	Abrasions below right ear	Trouble breathing and swallowing, hoarseness, pain	Left-sided prevertebral/perilaryngeal edema
Case V	m	29	Choke hold	Left-sided supraclavicular hematoma	Trouble breathing and swallowing, localized pain	Bilateral edema and fracture of the superior horns of the thyroid cartilage

Case I: single case with cerebral MR finding (see Fig. 3); cases II and III: cases with no delimitable external findings of the neck but with superficial MR findings (see Fig. 4); cases IV and V: victims of chokeholds with few external findings but with (peri-)laryngeal fluid accumulation (see Fig. 5)

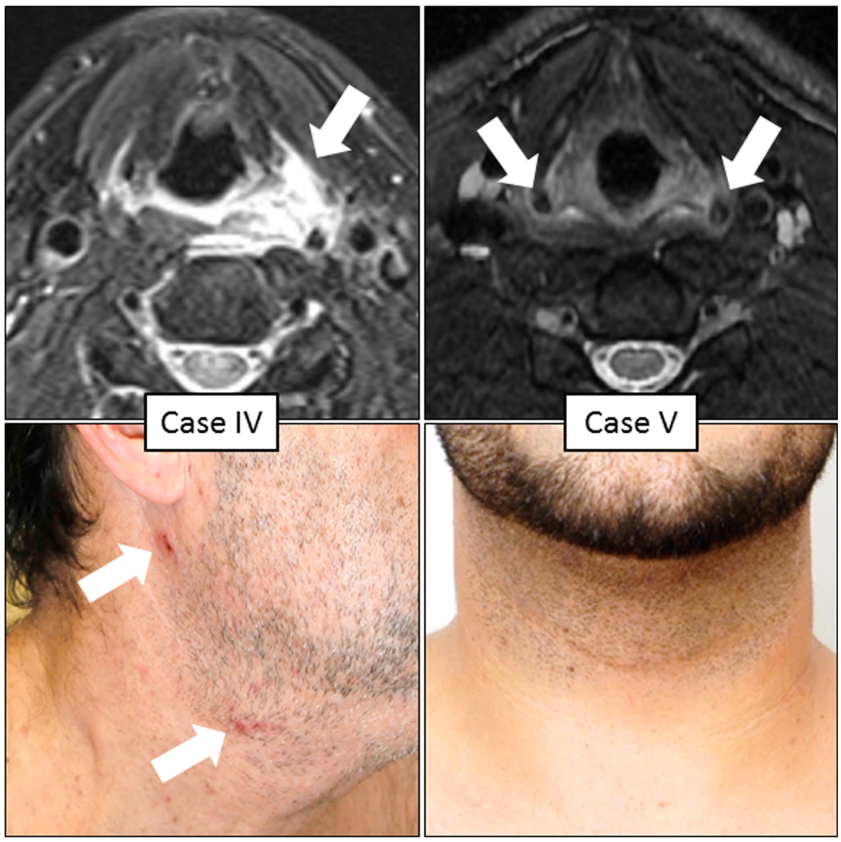

Fig. 5 Illustration of cases IV and V. Both cases were victims of chokeholds. Case IV had a few abrasions below the right ear (arrows). Case IV had a minimal supraclavicular hematoma (not visible). In case IV, perilaryngeal fluid accumulation is visible (arrow). In case V, both superior horns of the thyroid cartilage show surrounding fluid, and bilateral fractures of the superior horns were confirmed by computed tomography

time of the clinical forensic examination and traveled to the radiologic examination themselves. They were therefore not considered to be critically injured by any of the involved parties at any time. Second, the subjective component of reading and interpreting MR is a source of error. However, we have accounted for the heterogeneous quality of clinical reports by double reading the studies by expert radiologists in the field. Third, the low number of ligature strangulations, and the fact that all of them were conducted with material not suited for the application of high cervical pressure, prohibit the transfer of these results to cases of ligature strangulations done with "adequate" material, such as ropes or wires, as these materials were not represented in the data.

Conclusions

This study has revealed that the role of MR of the neck after NFS is currently limited and, in the absence of central nervous system symptoms, cranial MR is not indicated. This study has not identified specific radiologic findings or locations of findings associated with the forensic classification of life-threatening or nonlife-threatening assaults. MR may provide additional value in victims who present without external injuries but report subjective symptoms such as difficulty swallowing. In this subgroup, MR can provide objective, medico-legal evidence of internal injuries. The presence of MR findings is not dependent on an immediate examination following the assault. From a clinical perspective, the absence of carotid artery dissection indicates a reconsideration of the current approach to radiologic imaging, especially with a view to the excessive use of CT angiography, in victims of NFS when presenting to the emergency department for clinical assessment.

Funding The authors state that this work has not received any funding.

Compliance with ethical standards

Guarantor The scientific guarantor of this publication is Michael J. Thali.

Conflict of interest The authors of this manuscript declare no relationships with any companies, whose products or services may be related to the subject matter of the article.

Statistics and biometry No complex statistical methods were necessary for this paper. The authors have sufficient statistical understanding.

Informed consent Written informed consent was obtained from all subjects (patients) in this study.

Ethical approval Institutional Review Board approval was obtained for the publishing of case-related, forensic data (Ethics Committee of the Canton of Zurich, KEK ZH-Nr. 15-0686).

Methodology
- prospective
- experimental
- performed at one institution

References

1. Saukko P, Knight B (2015) Fatal pressure on the neck. In: Saukko P, Knight B (eds) Knight's forensic pathology. CRC Press, Boca Raton, pp 369–396
2. Brouardel P (1897) La pendaison, la strangulation, la suffocation, la submersion. Baillière, Paris
3. Hawley DA, McClane GE, Strack GB (2001) A review of 300 attempted strangulation cases. Part III: injuries in fatal cases. J Emerg Med 21:317–322
4. Laughon K, Glass N, Worrell C (2009) Review and analysis of laws related to strangulation in 50 states. Eval Rev 33:358–369
5. Pritchard AJ, Reckdenwald A, Nordham C (2017) Nonfatal strangulation as part of domestic violence: a review of research. Trauma Violence Abuse 18:407–424
6. Strack GB, McClane GE, Hawley D (2001) A review of 300 attempted strangulation cases. Part I: criminal legal issues. J Emerg Med 21:303–309
7. Plattner T, Bolliger S, Zollinger U (2005) Forensic assessment of survived strangulation. Forensic Sci Int 153:202–207
8. Fineron P, Turnbull J, Busuttil A (1995) Fracture of the hyoid bone in survivors of attempted manual strangulation. J Clin Forensic Med 2:195–197
9. Clarot F, Vaz E, Papin F, Proust B (2005) Fatal and non-fatal bilateral delayed carotid artery dissection after manual strangulation. Forensic Sci Int 149:143–150
10. Smith DJ Jr, Mills T, Taliaferro EH (2001) Frequency and relationship of reported symptomology in victims of intimate partner violence: the effect of multiple strangulation attacks. J Emerg Med 21: 323–329
11. Zilkens RR, Phillips MA, Kelly MC, Mukhtar SA, Semmens JB, Smith DA (2016) Non-fatal strangulation in sexual assault: a study of clinical and assault characteristics highlighting the role of intimate partner violence. J Forensic Leg Med 43:1–7
12. Prokop O, Wabnitz R (1970) Vorkommen von Bindehautblutungen bei Lebenden und Toten, dargestellt in 10 Tabellen. Z Rechtsmed 67:249–257
13. Maxeiner H, Bockholdt B (2003) Homicidal and suicidal ligature strangulation—a comparison of the post-mortem findings. Forensic Sci Int 137:60–66
14. Duband S, Timoshenko A, Mohammedi R et al (2009) Study of endolaryngeal structures by videolaryngoscopy after hanging: a new approach to understanding the physiopathogenesis. Forensic Sci Int 192:48–52
15. Pollanen MS (2000) A triad of laryngeal hemorrhages in strangulation: a report of eight cases. J Forensic Sci 45:614–618
16. Decker LA, Hatch GM, Lathrop SL, Nolte KB (2018) The role of postmortem computed tomography in the evaluation of strangulation deaths. J Forensic Sci 63:1401–1405
17. Pollanen MS (2001) Subtle fatal manual neck compression. Med Sci Law 41:135–140
18. Yen K, Vock P, Christe A et al (2007) Clinical forensic radiology in strangulation victims: forensic expertise based on magnetic resonance imaging (MRI) findings. Int J Legal Med (Tokyo) 121: 115–123
19. Yen K, Thali MJ, Aghayev E et al (2005) Strangulation signs: initial correlation of MRI, MSCT, and forensic neck findings. J Magn Reson Imaging 22:501–510
20. Christe A, Thoeny H, Ross S et al (2009) Life-threatening versus non-life-threatening manual strangulation: are there appropriate criteria for MR imaging of the neck? Eur Radiol 19:1882–1889
21. Christe A, Oesterhelweg L, Ross S et al (2010) Can MRI of the neck compete with clinical findings in assessing danger to life for survivors of manual strangulation? A statistical analysis. Legal Med 12:228–232
22. Swiss Society of Legal Medicine, Expert commission "Quality Management and Autopsy" (2012) Schädigung durch Strangulation. Available via https://www.sgrm.ch/inhalte/Forensische-Medizin/Strangulation_final_rev.pdf
23. R Core Team (2017) R: a language and environment for statistical computing. R Foundation for Statistical Computing, Vienna, Austria 2016
24. Bianco F, Floris R (1987) Computed tomography abnormalities in hanging. Neuroradiology 29:297–298
25. Ohkawa S, Yamadori A (1993) CT in hanging. Neuroradiology 35: 591
26. Kalita J, Mishra V, Misra U, Gupta R (2002) Clinicoradiological observation in three patients with suicidal hanging. J Neurol Sci 198:21–24
27. Stanley RB Jr, Hanson DG (1983) Manual strangulation injuries of the larynx. Arch Otolaryngol 109:344–347
28. Becker M, Leuchter I, Platon A, Becker CD, Dulguerov P, Varoquaux A (2014) Imaging of laryngeal trauma. Eur J Radiol 83:142–154