

Prevalence and Evolution of Susceptibility-Weighted Imaging Lesions in Patients With Artificial Heart Valves

Philippe S. Breiding, MD;* Jana T. Duerrenmatt, MS;* Felix G. Meinel, MD; Thierry Carrel, MD; Florian Schönhoff, MD; Felix Zibold, MD; Johannes Kaesmacher, MD; Jan Gralla, MD; Thomas Pilgrim, MD; Simon Jung, MD; Urs Fischer, MD, MSc; Marcel Arnold, MD;† Thomas R. Meinel, MD†

Background—In patients with mechanical heart valves, cerebral susceptibility-weighted imaging (SWI) lesions on magnetic resonance imaging, postulated to be caused by degenerative metallic abrasion, are frequently referred to as *valve abrasion*. It remains unclear whether valve implantation not requiring cardiopulmonary bypass or biological heart valves also shows those lesions.

Methods and Results—Two blinded readers rated SWI lesions and cerebral amyloid angiopathy probability according to established criteria on brain magnetic resonance imaging pre- and postinterventionally. We assessed the association between valve type/cardiopulmonary bypass use and SWI lesion count on the first postinterventional scan using multivariable logistic regression. On postinterventional magnetic resonance imaging, 57/58 (98%) patients with mechanical heart valves had at least 1 and 46/58 (79%) 3 or more SWI lesions, while 92/97 (95%) patients with biological heart valves had at least 1 and 72/97 (74%) 3 or more SWI lesions. On multivariate analysis, duration of cardiopulmonary bypass during implantation significantly increased the odds of having SWI lesions on the first postinterventional magnetic resonance imaging (β per 10 minutes 0.498; 95% CI, 0.116–0.880; $P=0.011$), whereas valve type showed no significant association ($P=0.338$). Thirty-seven of 155 (23.9%) patients fulfilled the criteria of possible/probable cerebral amyloid angiopathy.

Conclusions—SWI lesions in patients with artificial heart valves evolve around the time point of valve implantation and the majority of patients had multiple lesions. The missing association with the valve type weakens the hypothesis of degenerative metallic abrasion and highlights cardiopulmonary bypass as the main risk factor for SWI occurrence. SWI lesions associated with cardiac procedures can mimic cerebral amyloid angiopathy. Further research needs to clarify whether those lesions are associated with intracranial hemorrhage after intravenous thrombolysis or anticoagulation. (*J Am Heart Assoc.* 2019;8:e012814. DOI: 10.1161/JAHA.119.012814.)

Key Words: amyloid angiopathy • cardiopulmonary bypass • cerebral amyloid angiopathy • cerebral microbleed • heart valve • susceptibility-weighted imaging • valve abrasion

Susceptibility-weighted magnetic resonance imaging (SWI) or gradient echo magnetic resonance imaging are sensitive imaging techniques to detect cerebral microbleeds (CMBs) by utilizing the magnetic field inhomogeneity of deoxygenated hemoglobin.^{1–3} CMBs are associated with

chronic hypertension, other vascular risk factors, dementia, cerebral amyloid angiopathy (CAA), diffuse axonal injury, and also with normal aging.⁴ Unfortunately, the technique is not specific and there is a broad differential diagnosis of SWI lesions including foreign materials such as metals or ceramics,

From the University Institute of Diagnostic and Interventional Neuroradiology (P.S.B., F.Z., J.K., J.G.) and Departments of Neurology (J.T.D., J.K., S.J., U.F., M.A., T.R.M.), Cardiothoracic Surgery (T.C., F.S.), and Cardiology (T.P.), University Hospital Bern, Inselspital, University of Bern, Switzerland; Institute of Diagnostic and Interventional Radiology, Rostock University Medical Center, Rostock, Germany (F.G.M.); Institute of Diagnostic, Interventional and Pediatric Radiology, University Hospital Bern, Inselspital, University of Bern, Switzerland (J.K.).

Accompanying Tables S1, S2 and Figures S1 through S7 are available at <https://www.ahajournals.org/doi/suppl/10.1161/JAHA.119.012814>

*Dr Breiding and Mrs Duerrenmatt contributed equally to this work as co-first authors.

†Dr Arnold and Dr Meinel contributed equally to this work as co-senior authors.

Correspondence to: Thomas R. Meinel, MD, Department of Neurology, University of Bern, Freiburgstrasse 8, Bern CH-3010, Switzerland. E-mail: thomas.meinel@insel.ch

Received March 28, 2019; accepted June 26, 2019.

© 2019 The Authors. Published on behalf of the American Heart Association, Inc., by Wiley. This is an open access article under the terms of the Creative Commons Attribution-NonCommercial License, which permits use, distribution and reproduction in any medium, provided the original work is properly cited and is not used for commercial purposes.

Clinical Perspective

What Is New?

- Susceptibility-weighted imaging (SWI) lesions are a very frequent finding in neurologically symptomatic patients with mechanical and biological heart valves, and most patients have multiple lesions.
- SWI lesions were significantly associated with cardiopulmonary bypass time during implantation, but not mechanical valve type.
- SWI lesions evolved around the valve implantation and remained stable thereafter in most patients, and SWI lesions associated with heart valves can mimic cerebral amyloid angiopathy, but superficial siderosis is seldom present in those patients.

What Are the Clinical Implications?

- The hypothesis of degenerative metallic abrasion is weakened, and our findings highlight cardiopulmonary bypass as the main risk factor for SWI lesion occurrence.
- As SWI lesions (cerebral microbleeds) are increasingly considered in guiding treatment decisions for intravenous thrombolysis or anticoagulation, we hence question whether the SWI lesions seen with cardiopulmonary bypass share the same pathophysiological features and long-term bleeding risk as cerebral microbleeds seen with cerebral amyloid angiopathy or classical vascular risk factors.
- Autopsy studies are warranted to identify the true pathophysiological cause of SWI lesions in patients with cardiopulmonary bypass exposure.

vascular malformations, intracranial calcifications, brain tumors, air emboli, prior use of extracorporeal membrane oxygenation, or prolonged intensive care unit stay.^{4–8}

In patients with mechanical heart valves (mHV), SWI lesions have been described that were originally suspected to be caused by small metallic emboli by degenerative metallic abrasion of the valve structure.^{9–11} Although older mHV had a metallic shackle, modern mHV consist of pyrolytic carbon except the noble metal stent structure in some models or the annulus, which may be made up of titanium covered by a Dacron textile. This change of composition calls into question the metallic abrasion hypothesis. Nevertheless, carbon abrasion also might induce SWI artifacts.¹²

Furthermore, cardiopulmonary bypass (CPB) during valve implantation was also shown to be associated with postinterventional SWI lesions.^{5,13–15} No data are available on patients receiving biological heart valves (bHV). Therefore, it is unclear whether patients with transcatheter aortic valve implantation who do not require CPB or patients with bHV may also show those SWI lesions. In conclusion, SWI lesions

are seen in patients with any artificial heart valve (aHV) but their occurrence, cause, and significance are not well understood.

Patients with aHV require oral anticoagulation (OAC) in the case of mHV and platelet aggregation inhibitors in the case of bHV to prevent ischemic stroke and systemic emboli. However, each group may require additional platelet aggregation inhibitors or OAC for other medical reasons (eg, atrial fibrillation, low left ventricular ejection fraction, or coronary stenting). When multiple SWI lesions are detected in a certain distribution and interpreted as CMBs, CAA should be suspected,¹⁶ since it is a disease that carries a very high risk of intracranial hemorrhage (ICH). Hence, in such patients there is a therapeutic balancing act between the risk of ischemic stroke and ICH. Additionally, CMBs are increasingly considered in guiding treatment decisions for intravenous thrombolysis¹⁷ or anticoagulation,¹⁸ and such treatments might be withheld from patients with aHV because of the presence of SWI lesions. It is therefore important to know whether multiple SWI lesions in patients with aHV are true CMBs suggesting increased ICH risk or simply an epiphenomenon caused by either the material or the intracardiac procedure.

With this retrospective analysis, we want to provide a temporal and topical description of SWI lesions in patients with aHV and possibly aid in differentiating radiologically between CAA and the lesions seen with aHV.

Methods

For this study, approval of the cantonal ethics committee was obtained (KEK 2018-01300) and no informed consent was required according to local legislation. The data that support the findings of this study are available from the corresponding author upon reasonable request after clearance by the responsible ethics committee.

We identified all cerebral magnetic resonance imaging (MRI) examinations including SWI or gradient echo imaging sequences of patients with aHV by using the search terms “*klappe” (valve), “AKE” (aortic valve replacement), “MKE” (mitral valve replacement), and “Klappenabrieb” (valve abrasion) in the radiological information system of our tertiary university department of diagnostic neuroradiology. Since SWI and gradient echo imaging sequences have been used since ≈2005, we limited the date range to MRI examinations after January 1, 2005 until August 2018. We included only patients who signed the declaration of consent for the use of biological material and health-related data for medical research.

We excluded patients with diagnoses that might lead to confounding SWI lesions including ischemic stroke with hemorrhagic transformation, intracranial hemorrhage, SWI lesions associated with septic infarctions caused by infectious endocarditis, cerebral surgery, interventions or radiotherapy,

cerebral tumors, vascular malformations, cerebral trauma, moyamoya disease, cardiac myxoma, Pompe disease, or cerebral vasculitis.

Variables and Image Analysis

Biometrical data of patients included age, sex, body mass index, and renal function (glomerular filtration rate mL/min) at the time point of the first postinterventional MRI. Valve replacement was categorized in mechanical aortic valve replacement (AVR), biological aortic valve replacement, mechanical mitral valve replacement, biological mitral valve replacement, combination of mechanical aortic valve replacement and mitral valve replacement, combination of biological aortic valve replacement and mitral valve replacement, and other types of valve replacement. Patients with re-implantations of bHV after a mHV were considered mHV patients. Medication parameters included use of acetylsalicylic acid, vitamin-K antagonists, non-vitamin-K antagonist oral anticoagulants, and statin therapy at the time point of the first postinterventional MRI.

In-house imaging studies were performed using 1.5 T and 3 T Siemens scanners (Magnetom Avanto, Aera, Magnetom Verio, Siemens Medical Solution, Erlangen, Germany) with 12-channel head coil. For the 1.5 T MRI the following SWI parameters were used: repetition time 49 ms, echo time 40 ms, number of averages 1, field of view read 230 mm, field of view phase 81.3%, voxel size 1.1×0.9×1.8 mm, flip angle 15°. For 3 T: repetition time 28 ms, echo time 20 ms, number of averages 1, field of view read 230 mm, field of view phase 75%, voxel size 1.2×0.71×1.8 mm, flip angle 15°. Slice thickness of the maximum-intensity-projection of the SWI is between 12 and 16 mm.

Two readers, 1 neuroradiology fellow (P.B.) and 1 fellow in stroke neurology (T.R.M.) blinded to patients' valve status, reviewed the number and location of SWI lesions. Additionally, they assessed the presence of cortical superficial siderosis. We used the rating of the neuroradiology fellow for final analysis. The ratings of the neurology fellow were used to assess interrater agreement.

SWI lesions were defined according to the criteria proposed by Greenberg et al⁴ as round or ovoid black lesions of >1 to 10 mm size with at least half of the lesion surrounded by brain parenchyma and clearly distinct from iron or calcium deposits in typical regions, bone or vessel flow voids. We counted SWI lesions in the following regions (lobar cortico-subcortical, deep white matter, basal ganglia, pons and midbrain, cerebellar). Lobar cortico-subcortical regions were defined as <10 mm from the brain surface. In each region, we counted lesions up to a maximum of 20 per region. We rated CAA probability using recent modifications of the Boston Criteria.¹⁹

Statistical Analysis

We made univariate comparisons between patients with biological and mechanical aHV as well as between patients implanted on or without CPB using standard statistical measures (Fisher exact test for categorical variables, Mann–Whitney *U* test for nonnormally continuous or ordinally scaled variables, and Welch *t* test for independent normally distributed data). We did unadjusted analysis using Spearman's Rho correlation coefficient. We assessed interrater agreement for the number of SWI lesions using limits of agreement in the Bland-Altman plot. A difference of >5 lesions was considered clinically important. Therefore, we prespecified ±5 lesions as the maximum allowed difference.

We assessed the association between mechanical valve type as well as CPB duration (per 10-minute increase) and the odds of the number of SWI lesions on the first postinterventional MRI scan using multivariable logistic regression with adjustments for the following prespecified confounders: age (continuous), sex (categorical), body mass index (continuous), days in intensive care unit after implantation (continuous), estimated glomerular filtration rate (continuous), ascending aorta replacement (categorical), deep hypothermic circulatory arrest (DHCA, categorical), persisting foramen ovale/atrial septal defect closure (categorical), hypertension (categorical), diabetes mellitus (categorical), smoking (categorical), use of acetylsalicylic acid, clopidogrel, any OAC or statin (categorical), and Tesla of MRI (categorical 1.5 versus 3).

For follow-up examinations, SWI lesion difference and time in months from first postinterventional to last available scan was calculated and the relevant difference was defined as an alteration that exceeded the 95% CI of the interrater variability.

Results

Interrater Agreement

Bland-Altman plot for the interrater agreement showed that the limits of agreement (95% of all ratings) were from −3.5 to +6.0, within the prespecified maximum allowed difference of ±5, indicating reasonable agreement with few clinically important differences (Figure 1). There was significant proportional bias; however, its magnitude was very small ($\beta=0.077$, $P<0.001$).

Cohort Characterization

The baseline parameters of our cohort are presented in Table 1 (stratified for valve type and CPB use in Tables S1 and S2). A total of 155 patients with a median age of 71 years (interquartile range 58–77) were included. Roughly two thirds

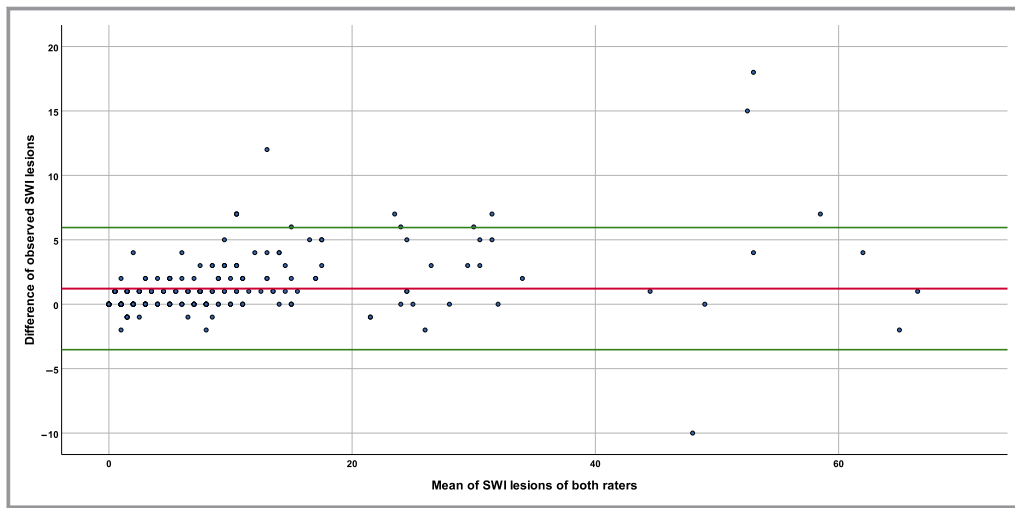


Figure 1. Bland-Altman plot for the interrater agreement. The red line indicates the mean difference of all ratings and the green lines indicate the limits of agreement (95% of all ratings). Limits of agreement were from -3.5 to $+6.0$, within the prespecified maximum allowed difference of ± 5 , indicating reasonable agreement with few clinically important differences. SWI indicates susceptibility-weighted imaging.

received a biological and one third a mechanical valve type. About half of the patients were orally anticoagulated, whereas the other half were taking antiplatelet agents. The risk factors and extent of white matter lesions correspond to an intermediate cardiovascular risk profile.

Preinterventional Scan

For 25 patients, preinterventional MRI scans were available with a median time before implantation of 12 months (interquartile range 1–35). Of those, 13 (52%) had no SWI lesion before valve implantation and a further 7 (28%) had 1 SWI lesion.

First Postinterventional Scan

Indications for postinterventional MRI examinations were an acute neurological deficit (57.4%), control of vascular pathology, eg, carotid stenosis (12.8%), epileptic seizure (6.1%), cognitive problems (4.7%), headache (2.7%), disorders of consciousness (2.7%), suspected tumor or metastasis (2.0%), movement anomalies (2.0%), vertigo (2.0%), suspected meningoencephalitis (1.4%), and others (6.1%). Location of SWI lesions was unrelated to acute lesions, if present. The median time between valve implantation and first postinterventional MRI was 17 months (interquartile range 0–76).

The increase in SWI lesions from the preinterventional to the first postinterventional MRI scan is presented in Table 2. Patients receiving a mHV had a more pronounced increase than patients receiving a bHV ($P < 0.001$). Seven of 25 patients

underwent transcatheter aortic valve implantation and 18/25 underwent open surgery. Four patients had no change in SWI lesions, all of which received bHV and 3 of 4 without use of CPB (Figure 2).

In patients with mHV, 97% (56/58) had at least 1, 87% (50/58) at least 2, and 79% (46/58) 3 or more SWI lesions (Figure S1A). In patients with bHV, 95% (92/97) had at least 1, 85% (82/97) at least 2, and 76% (72/97) 3 or more SWI lesions (Figure S1B).

On unadjusted analysis, significant differences in postinterventional SWI lesion count were observed for CPB versus no CPB use (median 7 versus 1.5, $P < 0.001$, Figure S2), mHV versus bHV (median 9 versus 5, $P = 0.001$, Figure S3), ascending aortic replacement versus no replacement (median 10 versus 5, $P < 0.001$), vitamin-K antagonists versus no vitamin-K antagonists medication (median 8 versus 5, $P = 0.042$), non-vitamin-K antagonist oral anticoagulants versus no non-vitamin-K antagonist oral anticoagulants medication (median 7 versus 2.5, $P = 0.035$), and DHCA versus no DHCA (8 versus 6, $P = 0.019$). Furthermore, age ($r_s = -0.293$, $P < 0.001$), body mass index ($r_s = -0.247$, $P = 0.002$), duration of CPB use ($r_s = 0.495$, $P < 0.001$, Figure S4), duration of DHCA use ($r_s = 0.225$, $P = 0.008$), and days of intensive care unit stay ($r_s = 0.357$, $P < 0.001$) were significantly correlated with postinterventional SWI lesion count.

According to multivariable linear logistic regression analysis adjusting for prespecified confounders outlined in the Methods section, duration of CPB (β per 10 minutes 0.498; 95% CI, 0.116–0.880; $P = 0.011$) was associated with a higher SWI lesion count on the first postinterventional MRI. No

Table 1. Baseline Characteristics of All Patients

Clinical Items	N=155
Age, y	71 (IQR 58–77)
Female sex	44 (28.4%)
BMI, kg/m ²	27.1 (IQR 24.3–30.2)
Risk factors	
Hypertension	115 (75.2%)
Smoking	44 (28.8%)
Diabetes mellitus	32 (20.9%)
eGFR, mL/min	74 (IQR 54–90)
Surgery	
Biological valve	97 (62.6%)
Mechanical valve	58 (37.4%)
Ascending aorta replacement	34 (21.9%)
PFO/ASD closure	5 (3.2%)
Days in ICU	1 (IQR 1–2)
CPB	137 (88.4%)
TAVI	18 (11.6%)
Deep hypothermic circulatory arrest	27 (18.9%)
Deep hypothermic circulatory arrest, min	19 (IQR 14–28)
Medication	
ASA	88 (56.8%)
Clopidogrel	15 (9.7%)
Dual antiplatelet	4 (2.6%)
VKA	73 (47.1%)
NOAC	12 (7.7%)
OAC, any	85 (54.8%)
Statin, any	79 (51.3%)
Imaging	
1.5 T	119 (78.3%)
3 T	33 (21.7%)
Fazekas Score	
0	31 (20.3%)
1	81 (52.9%)
2	32 (20.9%)
3	9 (5.9%)

ASA indicates acetylic salicylic acid; ASD, atrial septal defect; BMI, body mass index (kg/m²); CPB, cardiopulmonary bypass; eGFR, estimated glomerular filtration rate (mL/min); ICU, intensive care unit; IQR, interquartile range; NOAC, non-vitamin K antagonist oral anticoagulants; OAC, oral anticoagulation; PFO, persisting foramen ovale; TAVI, transcatheter aortic valve replacement; VKA, vitamin K antagonists.

statistical significant association was found for mechanical valve type ($P=0.338$).

Of the prespecified confounders, only age per year increase ($\beta=-0.326$; 95% CI, -0.566 to -0.0872 ; $P=0.008$)

Table 2. Change of Pre- to First Postinterventional Scan According to Valve Type and CPB Use

SWI Lesion Count	Preinterventional	Postinterventional	Change (n=25 With Preinterventional MRI)
Biological valve	0.5 (0–1.25), n=18	5 (2–9), n=97	+2 (1–4)
Mechanical valve	0 (0–1), n=7	9 (4–20), n=58	+9 (7–10)
Any valve (N=25)	0 (0–1), n=25	7 (3–12), n=155	+4 (1–7)
CPB yes	0 (0–1.25), n=18	7 (3–13.5), n=137	+5.5 (2.75–8.25)
CPB no	1 (0–1), n=7	1.5 (1–4), n=18	+1 (0–2)

CPB indicates cardiopulmonary bypass; MRI, magnetic resonance imaging; SWI, susceptibility-weighted imaging.

was associated with a lower SWI lesion count, whereas no statistically significant associations were found for duration of intensive care unit stay ($P=0.483$), anticoagulation use (0.552), statin use ($P=0.535$), higher body mass index per kg/m² ($P=0.162$), and DHCA ($P=0.476$). On sensitivity analyses considering only patients on-pump, CPB per 10 minutes remained a significant factor related to SWI lesion number on the first postoperative MRI scan ($\beta=0.576$; 95% CI, 0.130–1.021; $P=0.012$). In a post hoc analysis, neither selective antegrade cerebral perfusion ($P=0.575$) nor the lowest temperature during CPB was associated with postoperative SWI lesion count in bivariate correlation ($P=0.360$).

There were 6.1% of patients who fulfilled the criteria of “possible CAA” and a further 16.4% the criteria of “probable CAA” according to the modified Boston Criteria on the first postinterventional scan, with only 3.6% of patients showing superficial siderosis. Patients with bHV were more likely to fulfill CAA criteria, with 5 (5.2%) fulfilling possible and 23 (23.7%) probable CAA criteria versus 5 (8.6%) fulfilling possible and 4 (6.9%) probable CAA in patients with mHV ($\chi^2 P=0.025$). In many patients, additional very small SWI lesions <1 mm were present that were not accounted for in the analysis because they did not fulfill the established criteria for CMBs.⁴ The type of valve replacements is presented in Figure S5 and location of SWI lesions is presented in Figures S6 and S7.

Further Follow-Up MRI Scans

Follow-up MRI examinations were available for 56 patients with a median time after first postinterventional scan of 6 months (interquartile range 1–20). In 91.1% (51/56) of those, there was no further increase in SWI lesions (Figure 2). In those 5 patients with a warranted increase of SWI lesions, 3

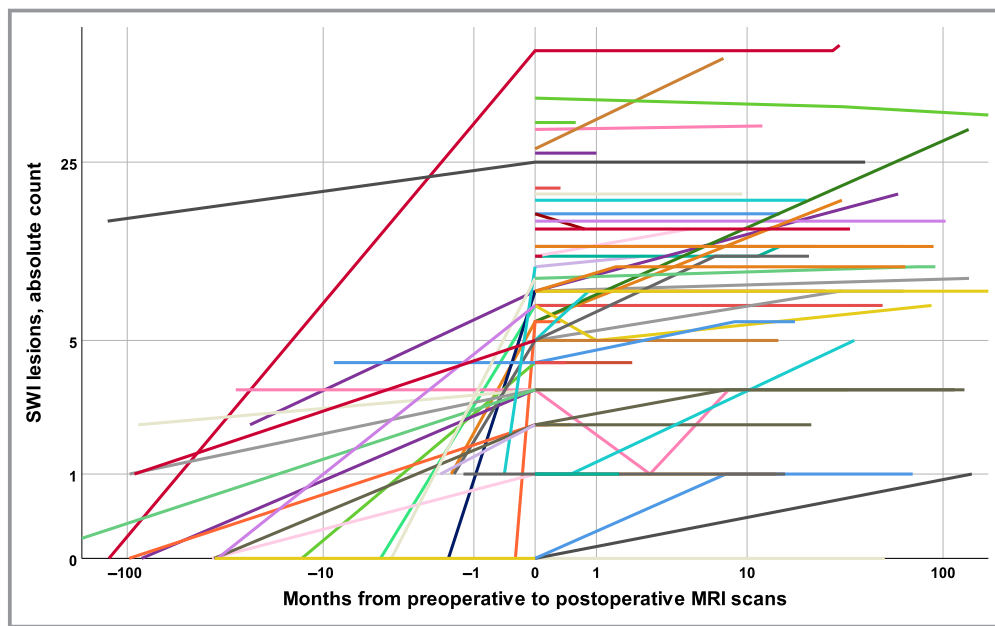


Figure 2. Double logarithmic plot of SWI lesion count of first postinterventional MRI scan in relation to valve implantation time in months. There was a median increase in SWI lesions of 4 (IQR 1–7) from the preinterventional to the first postinterventional MRI scan (bHV 2, IQR 1–4; mHV 9, IQR 7–10). bHV indicates biological heart valves; IQR, interquartile range; mHV, mechanical heart valves; MRI, magnetic resonance imaging; SWI, susceptibility-weighted imaging.

had a bHV and all had other medical conditions possibly explaining CMBs formation on follow-up imaging: 1 had chronic aortic dissection with complicated intensive care unit stay, 1 had a second surgery with CPB use, 1 had heparin-induced thrombocytopenia, and 2 had possible clinical CAA with recurrent cerebral acute ischemic events and cognitive decline. In 7 patients who had no SWI lesion on first postinterventional scan, 3 had a follow-up image available with 2 having 1 incident SWI lesion (median follow-up 2.5 years after first MRI).

Discussion

This retrospective analysis of cerebral MRI scans in aHV patients showed the following main findings: (1) In our cohort of patients with aHV, the frequency of postinterventional SWI lesions was very high irrespective of the type of valve that was implanted (mechanical or biological valve), with the vast majority of patients having multiple lesions. (2) The main risk factor for SWI lesions was duration of CPB. (3) SWI lesions associated with aHV may imitate CAA. (4) SWI lesions evolved around the valve implantation and remained stable thereafter in most patients.

The hypothesis of degenerative metallic abrasion of the valve structure was postulated almost 20 years ago based on only a few cases without pathological proof and limited knowledge about the differential diagnosis of SWI lesions.^{9–11} In population-based studies, CMBs were detected in 5% to

35% of older individuals,^{20,21} but only up to 20% of individuals showed multiple CMBs. With about 280 000 prosthetic valves implanted each year and virtually all modern aHV considered safe in MRI scans at field strengths of up to 1.5 T, MRI will be increasingly used in patients with aHV.^{22–24}

Cardiopulmonary Bypass

Our findings regarding the influence of CPB are in accordance with a recent prospective study of 75 patients undergoing on-pump cardiac surgery showing that 76% had new SWI lesions after the surgery.¹⁵ In this study, new CMBs were associated with longer CPB times (odds ratio, 1.02 per minute; 95% CI, 1.00–1.05; $P=0.04$). Hence, we can confirm the association of CPB time as a relevant factor to SWI lesion genesis. In a second study, gradient echo imaging lesions have been analyzed prospectively in patients requiring valve surgery and were found in 63% (12/19) of patients postoperatively.²⁵ The slightly lower rate of postoperative SWI lesions might be because of lower sensitivity of gradient echo imaging as compared with SWI sequences. Another study showed that SWI lesions occur after coronary bypass surgery, but only when CPB was used and with a similar frequency.¹³ It is known that the CPB circuit may contain air emboli and/or microparticles, which may also be detected using transcranial Doppler ultrasound.²⁶ However, it is rather unlikely that the postoperative SWI lesions are mainly caused by air since they were also detectable 6 weeks after surgery.¹⁵

Embolitic and hemodynamic ischemic brain infarcts are a well-known complication of valve surgery,²⁷ and secondary hemorrhagic transformation may thus explain occurrence of SWI lesions after valve implantation procedures.²⁸ However, the SWI lesions observed in our study were not associated with diffusion-weighted imaging lesions when brain MRI was performed shortly after the intervention. Furthermore, the frequency of SWI lesions in our study was higher than the known rates for diffusion-weighted imaging lesions after valve surgery and the rate of hemorrhagic transformation of ischemic stroke is usually only at $\approx 20\%$ to 30% .^{28,29} Lastly, the SWI lesions observed in our study were singular spots and did not show the classical phenotypes of hemorrhagic transformation. Hence, we do not think that secondary hemorrhagic transformation of embolic infarcts (fully) explains the SWI lesions associated with CPB use.

While known complications of DHCA are postischemic hypothermia, impaired autoregulatory mechanisms, and damage to the blood–brain barrier,³⁰ we found no significant association with postoperative SWI lesion count after adjusting for CPB time on multivariate analysis.

Valve Type

In our study, the prevalence of postinterventional SWI lesions in patients with aHV was very high. Patients with mHV had a higher lesion count than patients with bHV; however, this is likely because mHV is a confounder related to CPB since valve type was not a significant factor on multivariate analysis. Our findings are in line with a recent prospective study with pre- and postinterventional MRI scans, which showed that 90% of patients after valve implantation had SWI lesions.¹⁵ However, this study was underpowered to detect a significant difference of SWI lesions between patients with mHV and bHV.^{31,32} The occurrence of SWI lesions very early after implantation in 2 prospective studies^{15,25} challenges the hypothesis that those lesions are caused by degenerative metal abrasion, because the MRI was performed only days after the implantation and modern mHV are no longer composed of metal, but mainly carbon. This further weakens the hypothesis of degenerative metallic abrasion as a main reason for SWI lesions seen in patients with aHV and spotlights CPB as the main risk factor for SWI occurrence. Autopsy studies are warranted to identify the true pathophysiological cause of SWI lesions in patients with CPB exposure.

The small increase in patients receiving off-pump transcatheter aortic valve implantations in our cohort and in patients without SWI lesions postinterventionally might reflect non-CPB-related SWI lesion formation, underlying vascular risk factors or normal aging. However, this remains to be proven since to our knowledge no studies with systematic pre- and postinterventional SWI sequences have been

published in transcatheter aortic valve implantation patients. Studies with pre- and postinterventional SWI sequences have been performed, but results were published only for diffusion-weighted imaging lesions.³³

Because in our cohort we had additional follow-up MRIs available in several patients, we could show that the SWI lesion count remained stable over time in the majority of them. Long-term studies should clarify whether aHV represent a risk factor for ongoing excessive SWI lesion appearance.

Clinical Implications of SWI Lesions in Patients With aHV Related to CAA

In a relevant percentage of this aHV patient cohort, postinterventional distribution of SWI lesions was suggestive of CAA, with 23.9% of patients fulfilling the criteria of possible or probable CAA according to the modified Boston criteria postinterventionally. Interestingly, only 16% of those patients had superficial siderosis, whereas in true CAA superficial siderosis was more frequent than CMBs¹⁶ and represented an additional risk factor for incident ICH and poor functional outcome.³⁴ Of these patients, 9 had an available preinterventional MRI. In 4 patients without preinterventional SWI lesions, 3 fulfilled the criteria for probable CAA and 1 for possible CAA postinterventionally. Three patients already fulfilled the criteria for probable CAA before the intervention, whereas in 2 the rating changed from possible to probable.

Because CMBs are increasingly considered in guiding treatment decisions for intravenous thrombolysis^{17,35} or anticoagulation,¹⁸ we hence question whether the SWI lesions seen with CPB share the same pathophysiological features and long-term bleeding risk as CMBs seen with CAA or classical vascular risk factors. The fact that age was inversely associated with SWI lesion count also on multivariate analysis further calls into question the comparability of SWI lesions seen with aHV and true CMBs, which are known to be strongly associated with age.^{20,21}

In our cohort, several patients showed additional very small SWI lesions not commonly seen with CAA. However, the size of a SWI lesion depends on many technical factors such as magnetic field strength and sequence. Thus, we propose that future studies should include size, distribution, and shape of SWI lesions in attempts to differentiate CAA- and aHV-associated lesions using standardized MRI sequence protocols.

Limitations

This is a single-center retrospective study, which has inherent limitations. Intervals between valve implantation and MRI scans were heterogeneous and preprocedure MRI scans were available in only 25/155 (16%) of patients. Indications for

cerebral MRI were neurological symptoms in 87% of patients leading to a population bias, so generalization of our findings to aHV patients without clinical indications for cerebral MRI is not possible. The goodness of fit of our multilinear logistic regression was insufficient ($R^2=0.423$), indicating further neglected factors besides CPB contributing to SWI lesion formation. Data on extracorporeal membrane oxygenation before or after implantation were not available, which might have been used more often in patients with long CPB times. Furthermore, CPB reflects the complexity of the procedure and many other confounding factors; hence it might only be a surrogate parameter of SWI lesion formation rather than its pathophysiological explanation.

Conclusions

SWI lesions in patients with aHV were frequent and showed a temporal association with the implantation. SWI lesions associated with cardiac procedures can mimic CAA, but superficial siderosis is seldom present in those patients. Further research needs to clarify whether those lesions are associated with intracranial hemorrhage after intravenous thrombolysis or long-term anticoagulation. We propose that until clinical suspicion for CAA is high or superficial siderosis present, SWI lesions in patients with CPB exposure should not alter management. Autopsy studies are warranted to identify the true pathophysiological cause of SWI lesions in patients with aHV. Prospective studies should compare implantation procedures with and without CPB and identify further factors influencing SWI lesions formation during aHV implantation (eg, maximum activated partial thromboplastin time or specific CPB components).

Acknowledgments

Dr Meinel was involved in the study design, wrote the statistical analysis plan, organized and analyzed the data, and drafted and revised the paper. J. T. Dürrenmatt and Dr Breiding were responsible for clinical data acquisition, designed data collection tools, and drafted and revised the paper. Arnold monitored data collection of the registry, was involved in study design, and made critical revision of the manuscript. Drs Meinel, Zibold, Fischer, and Kaesmacher contributed in the design of the registry, and made critical revision of the manuscript. Dr Meinel provided statistical advice. Drs Schönhoff, Carrel and Pilgrim provided specific input on surgical or transcatheter implantation procedures and made critical revision of the manuscript. Dr Meinel had full access to all the data in the study and takes responsibility for its integrity and the data analysis.

Sources of Funding

The work of Kaesmacher was supported by the SAMW/Bangerter Foundation and the Swiss Stroke Society.

Disclosures

Dr Arnold received speaking fees and honoraria for scientific advisory boards from Covidien and Medtronic. Dr Gralla received Swiss National Science Foundation (SNSF) grants for magnetic resonance imaging in stroke. Dr Fischer is a consultant for Medtronic and Stryker. The remaining authors have no disclosures to report.

References

- Sehgal V, Delproposto Z, Haacke EM, Tong KA, Wycliffe N, Kido DK, Xu Y, Neelavalli J, Haddad D, Reichenbach JR. Clinical applications of neuroimaging with susceptibility-weighted imaging. *J Magn Reson Imaging*. 2005;22:439–450.
- Haacke EM, Mittal S, Wu Z, Neelavalli J, Cheng Y-CN. Susceptibility-weighted imaging: technical aspects and clinical applications, part 1. *AJNR Am J Neuroradiol*. 2009;30:19–30.
- Mittal S, Wu Z, Neelavalli J, Haacke EM. Susceptibility-weighted imaging: technical aspects and clinical applications, part 2. *AJNR Am J Neuroradiol*. 2009;30:232–252.
- Greenberg SM, Vernooij MW, Cordonnier C, Viswanathan A, Al-Shahi Salman R, Warach S, Launer LJ, Van Buchem MA, Breteler MM. Cerebral microbleeds: a guide to detection and interpretation. *Lancet Neurol*. 2009;8:165–174.
- Liebeskind DS, Sanossian N, Sapo ML, Saver JL. Cerebral microbleeds after use of extracorporeal membrane oxygenation in children. *J Neuroimaging*. 2013;23:75–78.
- Fanou EM, Coutinho JM, Shannon P, Kiehl TR, Levi MM, Wilcox ME, Aviv RI, Mandell DM. Critical illness-associated cerebral microbleeds. *Stroke*. 2017;48:1085–1087.
- Halefoglu AM, Yousem DM. Susceptibility weighted imaging: clinical applications and future directions. *World J Radiol*. 2018;10:30–45.
- Matsuura H, Inoue T, Konno H, Sasaki M, Ogasawara K, Ogawa A. Quantification of susceptibility artifacts produced on high-field magnetic resonance images by various biomaterials used for neurosurgical implants. Technical note. *J Neurosurg*. 2002;97:1472–1475.
- Wingerchuk DM, Krecke KN, Fulgham JR. Multifocal brain MRI artifacts secondary to embolic metal fragments. *Neurology*. 1997;49:1451–1453.
- van Gorp MJ, van der Graaf Y, de Mol BA, Bakker CJ, Witkamp TD, Ramos LM, Mali WP. Björk-Shiley convexoconcave valves: susceptibility artifacts at brain MR imaging and mechanical valve fractures. *Radiology*. 2004;230:709–714.
- Naumann M, Hofmann E, Toyka KV. Multifocal brain MRI hypointensities secondary to embolic metal fragments from a mechanical heart valve prosthesis. *Neurology*. 1998;51:1766–1767.
- Bachmann R, Deutsch H-J, Jünehülsing M, Sechtem H, Hilger H, Schicha H. Magnetresonanztomographie bei Patienten mit Herzklappenersatz. *RöFo - Fortschritte auf dem Gebiet der Röntgenstrahlen und der bildgebenden Verfahren*. 1991;155:499–505.
- Michałowska I, Furmanek MI, Smaga E, Juraszyński Z, Zieliński T, Chelstowska S, Kuśmierczyk M, Szpakowski E, Mierzyńska A, Walecki JM. Evaluation of brain lesions in patients after coronary artery bypass grafting using MRI with the emphasis on susceptibility-weighted imaging. *Kardiochir Torakochirurgia Pol*. 2015;12:1–7.
- Kim PPC, Nasman BW, Kinne EL, Oyoyo UE, Kido DK, Jacobson JP. Cerebral microhemorrhage: a frequent magnetic resonance imaging finding in pediatric patients after cardiopulmonary bypass. *J Clin Imaging Sci*. 2017;7:27.
- Patel N, Banahan C, Janus J, Horsfield MA, Cox A, Li X, Cappellugola L, Colman J, Egan V, Garrard P, Chung EML. Perioperative cerebral microbleeds after adult cardiac surgery. *Stroke*. 2018;50:336–343.
- Linn J, Halpin A, Demaerel P, Ruhland J, Giese AD, Dichgans M, Van Buchem MA, Bruckmann H, Greenberg SM. Prevalence of superficial siderosis in patients with cerebral amyloid angiopathy. *Neurology*. 2010;74:1346–1350.
- Tsigvoulis G, Zand R, Katsanos AH, Turc G, Nolte CH, Jung S, Cordonnier C, Fiebich JB, Scheitz JF, Klingner-Gratz PP, Oppenheim C, Goyal N, Safouris A,

- Mattle HP, Alexandrov AW, Schellinger PD, Alexandrov AV. Risk of symptomatic intracerebral hemorrhage after intravenous thrombolysis in patients with acute ischemic stroke and high cerebral microbleed burden: a meta-analysis. *JAMA Neurol.* 2016;73:675–683.
18. Charidimou A, Karayiannis C, Song T-J, Orken DN, Thijs V, Lemmens R, Kim J, Goh SM, Phan TG, Soufan C, Chandra RV., Slater L-A, Haji S, Mok V, Horstmann S, Leung KT, Kawamura Y, Sato N, Hasebe N, Saito T, Wong LKS, Soo Y, Veltkamp R, Flemming KD, Imaizumi T, Srikanth V, Heo JH. Brain microbleeds, anticoagulation, and hemorrhage risk. *Neurology.* 2017;89:2317–2326.
 19. Greenberg SM, Charidimou A. Diagnosis of cerebral amyloid angiopathy. *Stroke.* 2018;49:491–497.
 20. Poels MMF, Vernooij MW, Ikram MA, Hofman A, Krestin GP, van der Lugt A, Breteler MMB. Prevalence and risk factors of cerebral microbleeds. *Stroke.* 2010;41:S103–S106.
 21. Sveinbjornsdottir S, Sigurdsson S, Aspelund T, Kjartansson O, Eiriksdottir G, Valtysdottir B, Lopez OL, Van Buchem MA, Jonsson PV, Gudnason V, Launer LJ. Cerebral microbleeds in the population based AGES-Reykjavik study: prevalence and location. *J Neurol Neurosurg Psychiatry.* 2008;79:1002–1006.
 22. Karamitsos TD, Karvounis H. Magnetic resonance is a safe imaging technique in patients with prosthetic heart valves and coronary stents. *Hellenic J Cardiol.* 2019;60:38–39.
 23. Levine GN, Gomes AS, Arai AE, Bluemke DA, Flamm SD, Kanal E, Manning WJ, Martin ET, Smith JM, Wilke N, Shellock FS. Safety of magnetic resonance imaging in patients with cardiovascular devices: an American Heart Association scientific statement from the Committee on Diagnostic and Interventional Cardiac Catheterization, Council on Clinical Cardiology, and the Council on Cardiovascular Radiology and Intervention: endorsed by the American College of Cardiology Foundation, the North American Society for Cardiac Imaging, and the Society for Cardiovascular Magnetic Resonance. *Circulation.* 2007;116:2878–2891.
 24. Pibarot P, Dumesnil JG. Prosthetic heart valves. *Circulation.* 2009;119:1034–1048.
 25. Jeon SB, Lee JW, Kim SJ, Chung CH, Kwon SU, Choi CG, Choo SJ, Nah HW, Kim JS, Kang DW. New cerebral lesions on T2*-weighted gradient-echo imaging after cardiac valve surgery. *Cerebrovasc Dis.* 2010;30:194–199.
 26. Chung EML, Banahan C, Patel N, Janus J, Marshall D, Horsfield MA, Rousseau C, Keelan J, Evans DH, Hague JP. Size distribution of air bubbles entering the brain during cardiac surgery. *PLoS One.* 2015;10:e0122166.
 27. Massaro A, Messé SR, Acker MA, Kasner SE, Torres J, Fanning M, Giovannetti T, Ratcliffe SJ, Bilello M, Szeto WY, Bavaria JE, Mohler ER, Floyd TF. Pathogenesis and risk factors for cerebral infarct after surgical aortic valve replacement. *Stroke.* 2016;47:2130–2132.
 28. Neeb L, Villringer K, Galinovic I, Grosse-Dresselhaus F, Ganeshan R, Gierhake D, Kunze C, Grittner U, Fiebich JB. Adapting the computed tomography criteria of hemorrhagic transformation to stroke magnetic resonance imaging. *Cerebrovasc Dis Extra.* 2013;3:103–110.
 29. Von Kummer R, Broderick JP, Campbell BCV, Demchuk A, Goyal M, Hill MD, Treurniet KM, Majoie CBLM, Marquering HA, Mazya MV, Román LS, Saver JL, Strbian D, Whiteley W, Hacke W. The Heidelberg Bleeding Classification: classification of bleeding events after ischemic stroke and reperfusion therapy. *Stroke.* 2015;46:2981–2986.
 30. Gupta P, Harky A, Jahangeer S, Adams B, Bashir M. Varying evidence on deep hypothermic circulatory arrest in thoracic aortic aneurysm surgery. *Tex Heart Inst J.* 2018;45:70–75.
 31. Meinel TR, Breiding P, Arnold M. Letter by Meinel et al regarding article, “perioperative cerebral microbleeds after adult cardiac surgery”. *Stroke.* 2019;50:e140–e141.
 32. Patel N, Hannon C, Chung EML. Response by Patel et al to letter regarding article, “perioperative cerebral microbleeds after adult cardiac surgery”. *Stroke.* 2019;50:e142.
 33. Rodés-Cabau J, Kahlert P, Neumann FJ, Schymik G, Webb JG, Amareno P, Brott T, Garami Z, Gerosa G, Lefèvre T, Plicht B, Pocock SJ, Schlamann M, Thomas M, Diamond B, Merioud I, Beyersdorf F, Vahanian A. Feasibility and exploratory efficacy evaluation of the Embrella Embolic Deflector system for the prevention of cerebral emboli in patients undergoing transcatheter aortic valve replacement: the PROTAVI-C pilot study. *JACC Cardiovasc Interv.* 2014;7:1146–1155.
 34. Wollenweber FA, Opherck C, Zedde M, Catak C, Malik R, Duering M, Konieczny MJ, Pascarella R, Samões R, Correia M, Marti-Fàbregas J, Linn J, Dichgans M. Prognostic relevance of cortical superficial siderosis in cerebral amyloid angiopathy. *Neurology.* 2019;92:e792–e801.
 35. Charidimou A, Turc G, Oppenheim C, Yan S, Scheitz JF, Erdur H, Klinger-Gratz PP, El-Koussy M, Takahashi W, Moriya Y, Wilson D, Kidwell CS, Saver JL, Sallem A, Moulin S, Edjlali-Goujon M, Thijs V, Fox Z, Shoamanesh A, Albers GW, Mattle HP, Benavente OR, Jäger HR, Ambler G, Aoki J, Baron J-C, Kimura K, Kakuda W, Takizawa S, Jung S, Nolte CH, Lou M, Cordonnier C, Werring DJ. Microbleeds, cerebral hemorrhage, and functional outcome after stroke thrombolysis. *Stroke.* 2017;48:2084–2090.

SUPPLEMENTAL MATERIAL

Table S1. Characteristics of Patients According to Use of Cardiopulmonary Bypass (CPB).

	CPB yes (n=137)	CPB no (n=18)	P
Baseline characteristics			
Age (years)	70 (IQR 57-77)	79 (IQR 74-82)	<0.001
Female sex	37 (27.0%)	7 (38.9%)	0.404
Risk factors			
Hypertension	98 (72.6%)	17 (94.4%)	0.045
Smoking	36 (26.7%)	8 (44.4%)	0.164
Diabetes	24 (17.8%)	8 (44.4%)	0.026
eGFR	77 (IQR 60-90)	58 (IQR 36-75)	0.005
BMIw	26.9 (IQR 24.2-30.0)	28.4 (IQR 24.4-32.1)	0.388
Surgery			
Mechanical Valve	58 (42.3%)	0 (0%)	<0.001
Ascendens replacement	34 (24.8%)	0 (0%)	0.013
PFO/ASD closure	4 (2.9%)	1 (5.6%)	0.465
Days in ICU	1 (IQR 1-2)	0 (IQR 0-1)	<0.001
Medication			
ASS	78 (56.9%)	10 (55.6%)	1.000
Clopidogrel	10 (7.3%)	5 (27.8%)	0.017
VKA	70 (51.1%)	3 (16.7%)	0.006
NOAC	7 (5.1%)	5 (27.8%)	0.006
OAC, any	77 (56.2%)	8 (44.4%)	0.451
Statin, any	68 (49.6%)	11 (64.7%)	0.307
Imaging			
Number of SWI lesions on 1 st postoperative scan	7 (IQR 3-13.5)	1.5 (IQR 1-4)	<0.001

CPB: Cardiopulmonary bypass, BMI: body mass index (kg/m²), eGFR: estimated glomerular filtration rate (ml/min), PFO: persisting foramen ovale; ASD: atrial septal defect; ICU: intensive care unit; ASS: acetylic salicylic acid; VKA: vitamin k antagonists, NOAC: non vitamin k antagonist oral anticoagulants, OAC: oral anticoagulation, SWI: susceptibility weighted imaging.

Table S2. Characteristics of Patients According to Valve Type.

	Biological valve (N=97)	Mechanical Valve (N=58)	P
Baseline characteristics			
Age (years)	74 (IQR 70-79)	57 (IQR 48-64)	<0.001
Female sex	30 (30.9%)	14 (24.1%)	0.462
Risk factors			
BMI	27.7 (IQR 24.4-30.9)	26.1 (IQR 23.1-29.3)	0.035
Hypertension	80 (83.8%)	35 (61.4%)	0.004
Smoking	29 (30.2%)	15 (26.3%)	0.731
Diabetes	28 (29.2%)	4 (7.0%)	0.001
eGFR	71 (IQR 52-90)	83 (IQR 60-90)	0.051
Surgery			
Cardiopulmonary bypass (CPB) used	79 (81.4%)	58 (100%)	<0.001
CPB duration, minutes	83 (IQR 48-116)	128 (IQR 79-183)	<0.001
Ascendens replacement	14 (14.4%)	20 (34.5%)	0.005
PFO/ASD closure	4 (4.1%)	1 (1.7%)	0.651
Days in ICU	1 (IQR 1.0-1.25)	1 (IQR 1-2)	0.003
Medication			
ASS	67 (69.1%)	21 (36.2%)	<0.001
Clopidogrel	11 (11.3%)	4 (6.9%)	0.416
VKA	21 (21.6%)	52 (89.7%)	<0.001
NOAC	10 (10.3%)	2 (3.4%)	0.213
OAC, any	31 (32.0%)	54 (93.1%)	<0.001
Statin, any	58 (60.4%)	21 (36.2%)	0.005
Imaging			
Number of SWI lesions on 1 st postinterventional scan	5 (IQR 2-9)	9 (IQR 4-20)	0.001

BMI: body mass index (kg/m²), eGFR: estimated glomerular filtration rate (ml/min), PFO: persisting foramen ovale; ASD: atrial septal defect; ICU: intensive care unit; ASS: acetylic salicylic acid; VKA: vitamin k antagonists, NOAC: non vitamin k antagonist oral anticoagulants, OAC: oral anticoagulation, SWI: susceptibility weighted imaging.

Figure S1a. Distribution of SWI lesions on 1st postinterventional MRI scan in patients receiving a mechanical heart valve (N=58).

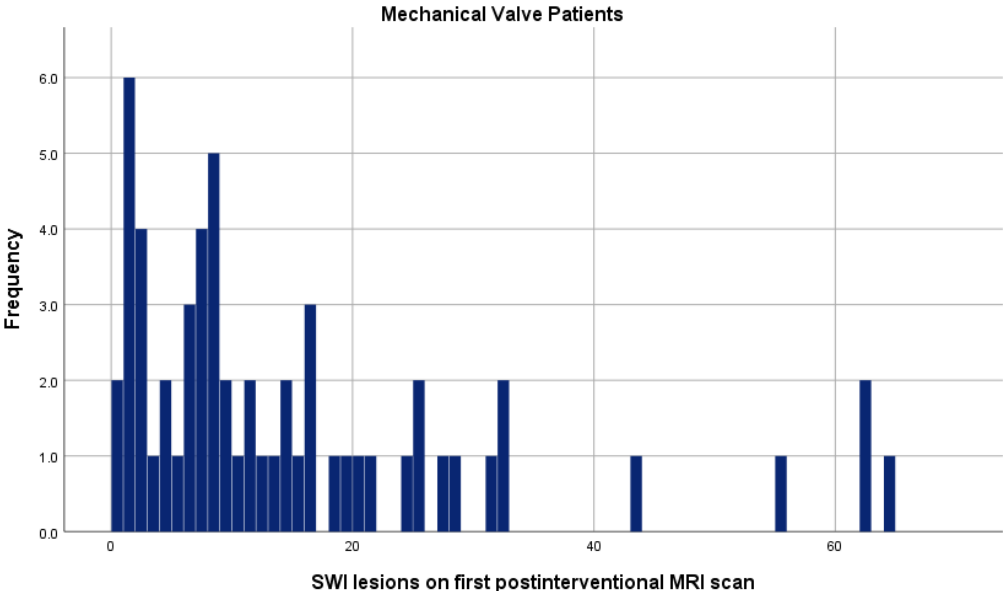
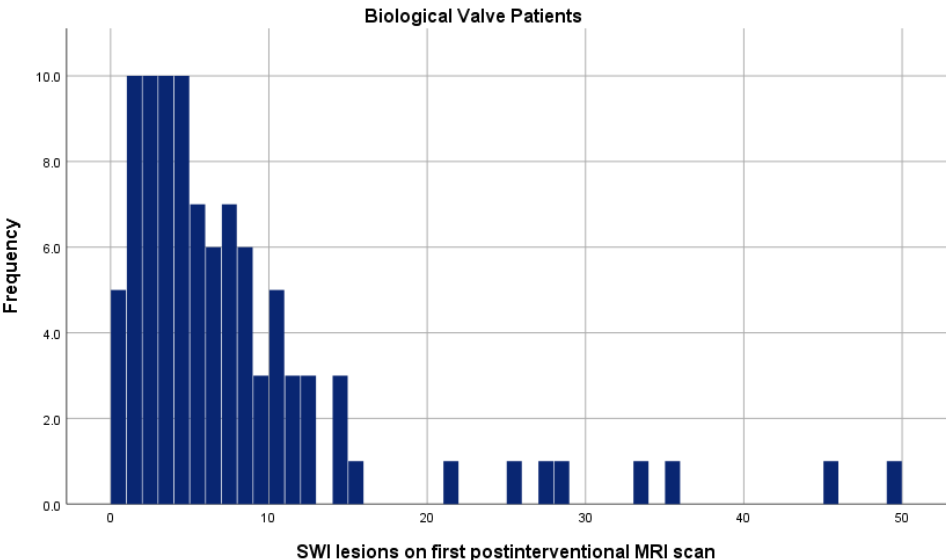
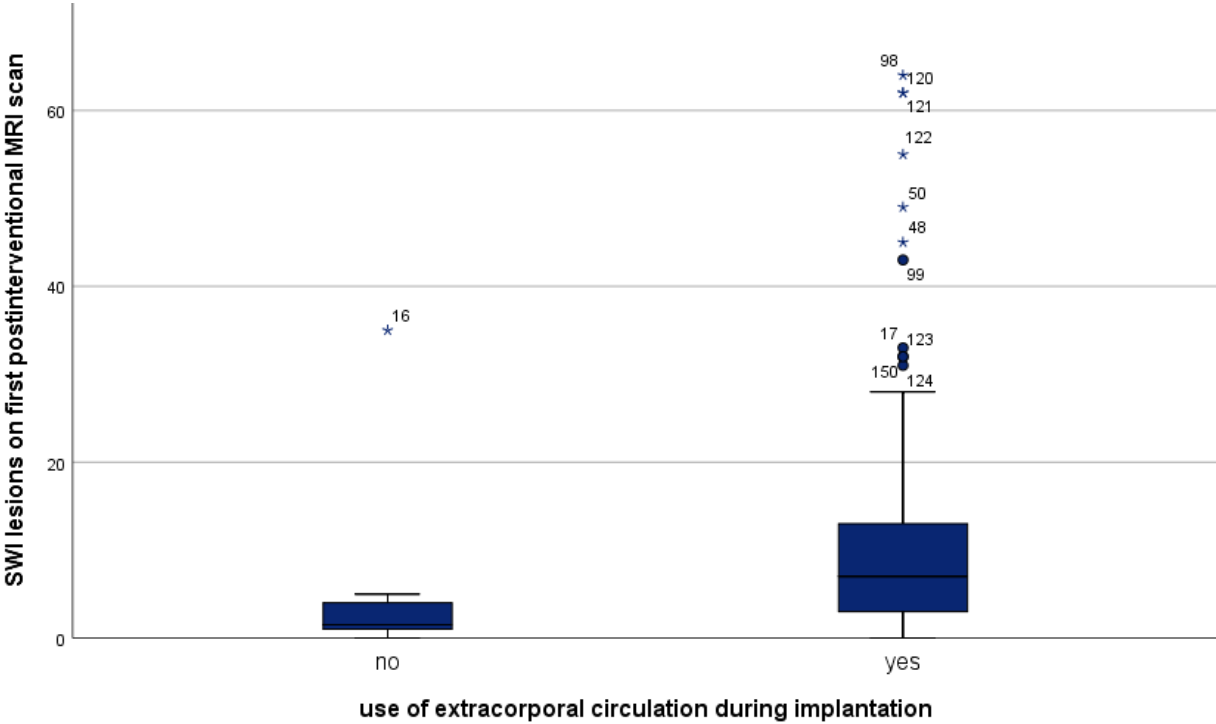


Figure S1b. Distribution of SWI lesions on 1st postinterventional MRI scan in patients receiving a biological heart valve (N=97).



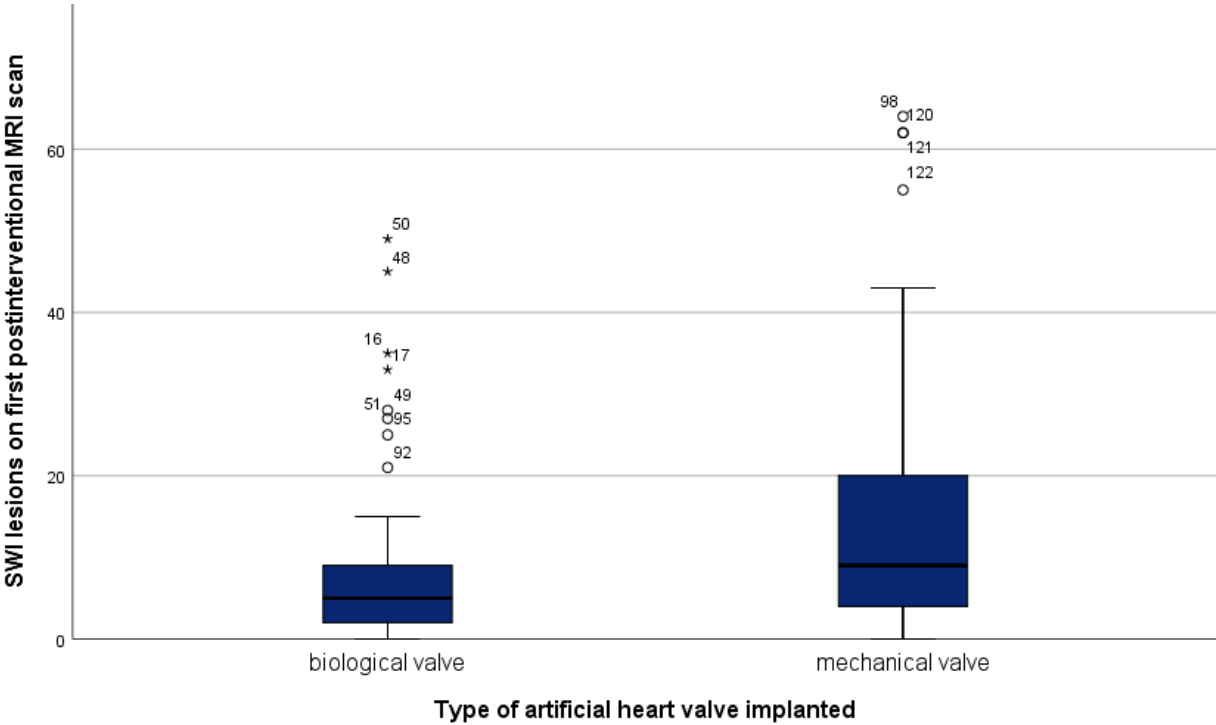
SWI: susceptibility weighted imaging

Figure S2. Distribution of SWI lesions on 1st postinterventional MRI scan in patients according to use of cardiopulmonary bypass.



SWI: susceptibility weighted imaging

Figure S3. Distribution of SWI lesions on 1st postinterventional MRI scan in patients according to type of valve implanted.



SWI: susceptibility weighted imaging

Figure S4. Scatter plot of SWI lesion count according to time of cardiopulmonary bypass.

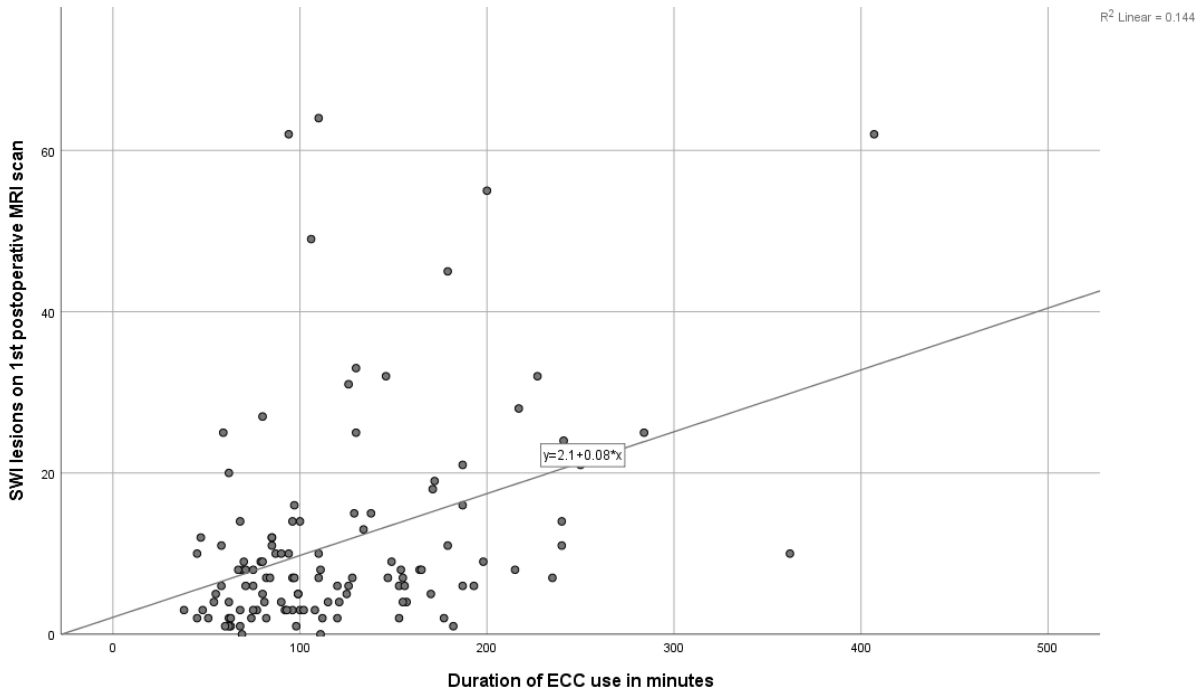


Figure S5a. Pie chart of valve type in patients on cardiopulmonary bypass.

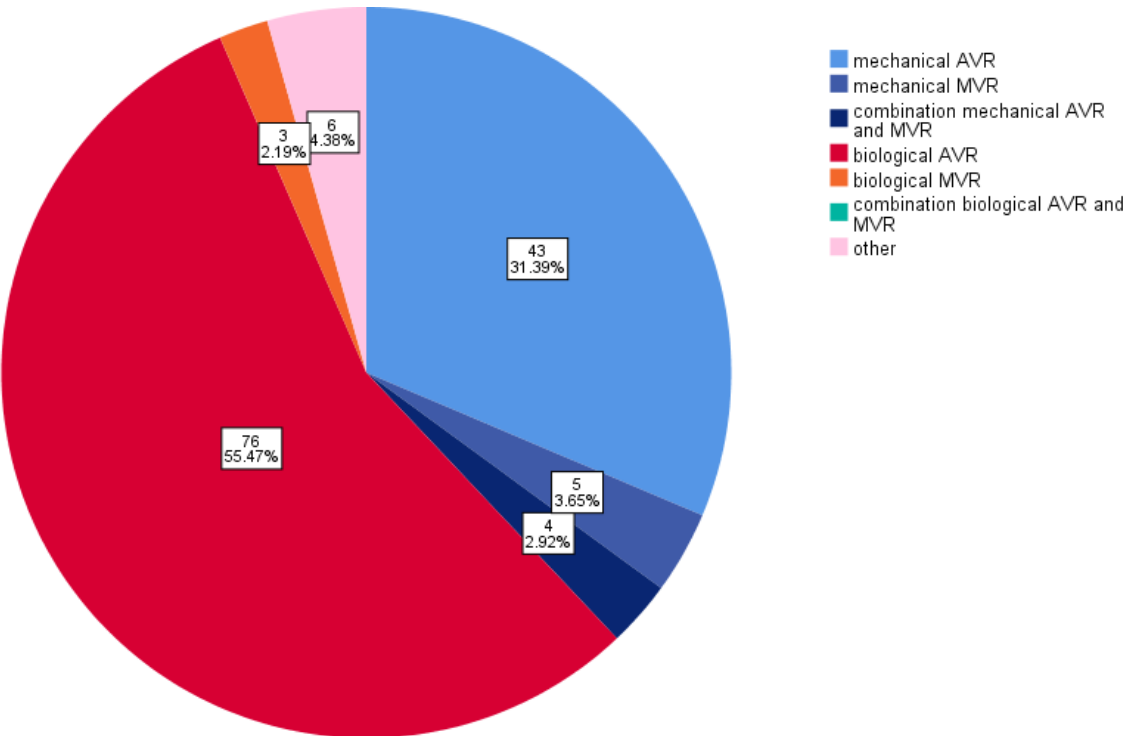


Figure S5B. Pie chart of valve type in patients off cardiopulmonary bypass.

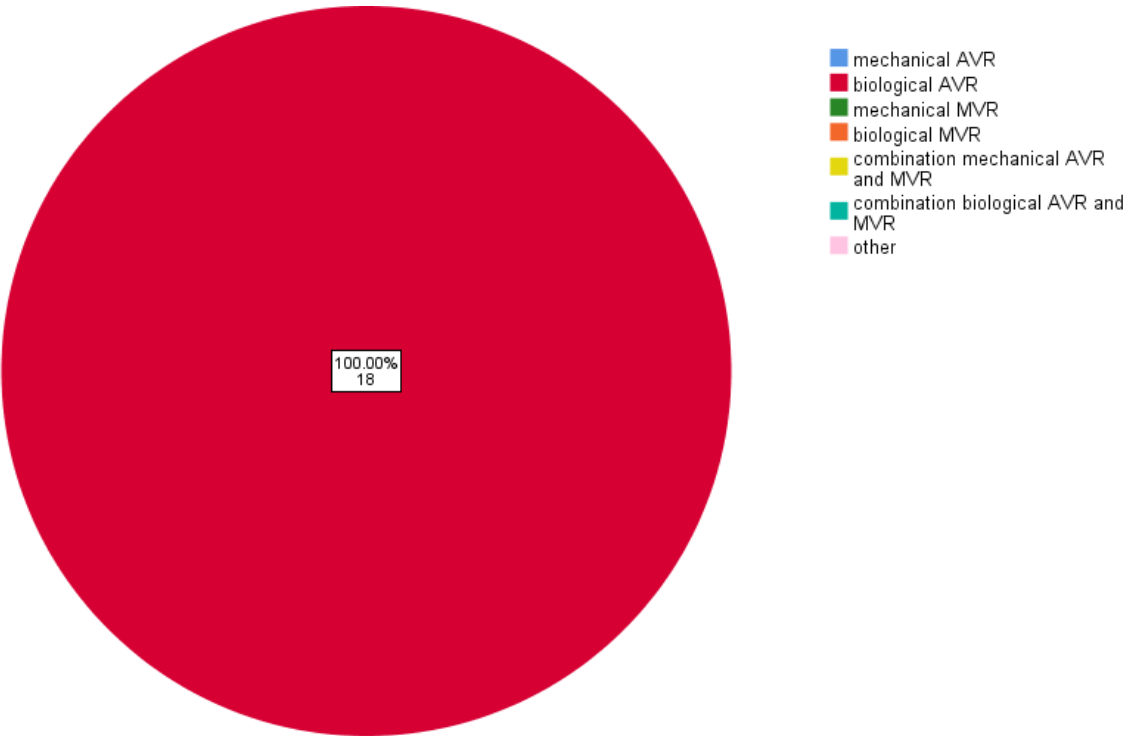


Figure S6. Location of SWI lesions according to valve type.

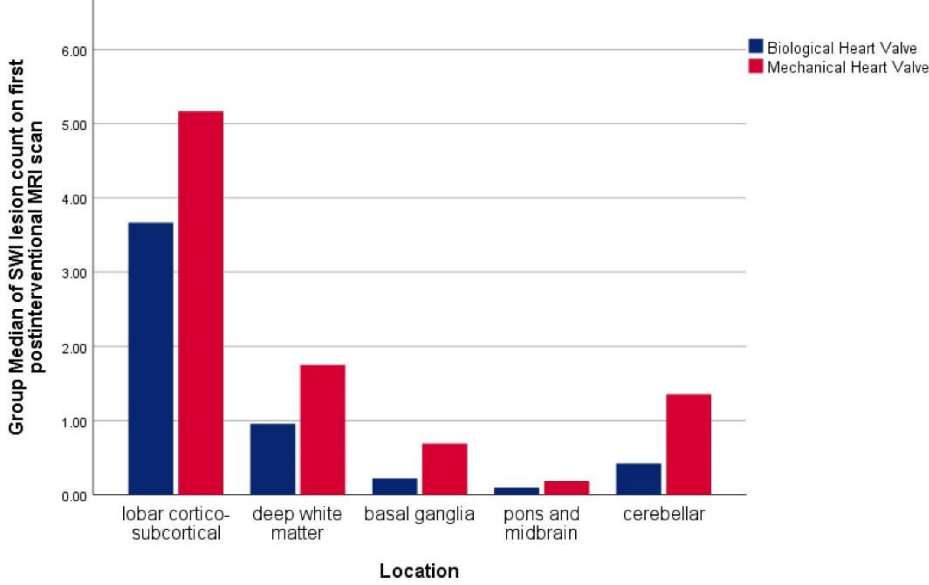


Figure S7. Location of SWI lesions according to use of cardiopulmonary bypass.

