

Fluorescence Lifetimes in Patients With Hydroxychloroquine Retinopathy

Yasmin Solberg,¹ Chantal Dysli,¹ Burkhard Möller,² Sebastian Wolf,¹ and Martin S. Zinkernagel¹

¹Department of Ophthalmology, Inselspital, Bern University Hospital, and Department of BioMedical Research, University of Bern, Bern, Switzerland

²Department of Rheumatology, Inselspital, Bern University Hospital, University of Bern, Bern, Switzerland

Correspondence: Martin S. Zinkernagel, University Hospital Bern, Freiburgstrasse 4, Bern 3010, Switzerland; martin.zinkernagel@insel.ch.

Submitted: October 29, 2018

Accepted: April 22, 2019

Citation: Solberg Y, Dysli C, Möller B, Wolf S, Zinkernagel MS. Fluorescence lifetimes in patients with hydroxychloroquine retinopathy. *Invest Ophthalmol Vis Sci.* 2019;60:2165–2172. <https://doi.org/10.1167/iovs.18-26079>

PURPOSE. To investigate fundus autofluorescence lifetime features in patients with hydroxychloroquine (HCQ) retinopathy, and to identify early markers of retinal alterations in patients due to HCQ.

METHODS. Patients attending screening for HCQ retinopathy were imaged with a fluorescence lifetime imaging ophthalmoscope. Mean retinal fluorescence lifetimes (T_m) were obtained in a short spectral channel (SSC, 498–560 nm) and a long spectral channel (LSC, 560–720 nm). Screening modalities included fundus images, fundus autofluorescence intensity images (FAF), spectral-domain optical coherence tomography (SD-OCT), visual fields, and multifocal electroretinogram (mfERG).

RESULTS. Forty-two eyes of 21 patients on HCQ therapy and 40 eyes of 20 healthy age-matched controls were included. Fourteen eyes of 7 patients with HCQ retinopathy (mean age, 66.1 [SD, 7.7] years) and 28 eyes of 14 patients (mean age, 46.1 [SD, 7.9] years) receiving HCQ without retinopathy were identified. Patients with HCQ retinopathy showed a parafoveal ring-shaped or oval area of prolonged mean fluorescence lifetimes. In these areas, mean (\pm SEM) lifetimes were 374 ± 7 ps in the SSC, and on average 19.4% longer compared to the control group ($P = 0.0001$). Patients on HCQ without retinopathy had retinal fluorescence lifetimes that were similar to the control group.

CONCLUSIONS. This study shows that HCQ retinopathy displays characteristic mean fluorescence lifetimes.

Keywords: FLIO, fluorescence lifetimes, fundus autofluorescence, ophthalmic imaging, chloroquine, hydroxychloroquine, retinopathy, retinal toxicity

Chloroquine (CQ) and hydroxychloroquine (HCQ) are commonly used in the management of a variety of autoimmune disorders, including in the treatment of rheumatoid arthritis and systemic lupus erythematosus. Despite having fewer systemic side effects in comparison to other medications, CQ and HCQ have been associated with significant retinotoxicity, which can lead to irreversible central visual loss, color vision impairment, and visual field defects.^{1–3} Although the exact pathophysiological mechanisms of retinal toxicity are still not fully understood, HCQ toxicity occurs far more frequently than originally contemplated. It is estimated that 7.5% of patients are affected after 5 years of treatment.⁴ The most important risk factors predisposing to the development of HCQ retinopathy are long-term HCQ therapy (duration > 5 years of use), higher doses (>5.0 mg/kg), concomitant renal disorders, and use of tamoxifen.^{2–4}

Early detection of CQ retinopathy is vital as the damage can progress even after cessation of the drug due to the slow clearance of the medication from the body.^{5,6} Thus, screening for early retinal toxicity is crucial to detect signs of maculopathy at a “preclinical phase” to prevent severe visual loss via early discontinuation of the medication. The American Academy of Ophthalmology recommends routinely performing an ophthalmologic examination and automated threshold visual field testing with a white 10-2 pattern, along with at least one objective imaging modality such as multifocal electroretino-

gram (mfERG), fundus autofluorescence (FAF), or spectral-domain optical coherence tomography (SD-OCT). These examinations should be performed at baseline and annually at each visit after 5 years of HCQ use.⁷

Recent technological advancements have shown that subtle changes in cellular metabolism in different metabolic conditions can be identified using fluorescence lifetime imaging microscopy (FLIM).⁸ Fluorescence lifetime imaging ophthalmoscopy (FLIO), an *in vivo* FLIM method, is a novel noninvasive imaging modality currently in clinical use to identify and quantify metabolic abnormalities in retinal diseases by imaging lifetimes of endogenous retinal fluorophores.^{9–13} The fluorescence lifetime represents the time span an intrinsic fluorophore spends in a higher energy level following an excitation with a blue laser before returning to its ground level by releasing a photon with a longer emission wavelength.

The aim of this study was to evaluate and characterize retinal fluorescence lifetimes (FLT) using the mean lifetime (T_m) in patients with CQ retinopathy and in patients using HCQ with currently no evidence of toxicity.

METHODS

This prospective case-control study was performed at the ophthalmology outpatient department of the University Hospi-



tal in Bern, Switzerland, with the approval of the local ethics committee and in accordance with the Declaration of Helsinki. An informed consent was signed prior to study entry.

For each participant a standardized sequence of investigations was performed including a general ophthalmologic examination with measurement of the best-corrected visual acuity (Snellen chart).¹⁰ Pupils were dilated with tropicamide 0.5% and phenylephrine HCl 2.5%. In both eyes, fundus color images (Zeiss FF 450plus; Zeiss, Oberkochen, Germany), optical coherence tomography (OCT) scans of the macula (Heidelberg Spectralis HRA+OCT; Heidelberg Engineering, Heidelberg, Germany), Octopus 10-2 visual fields, FAF images, and fluorescence lifetime images were obtained. Multifocal electroretinogram (mfERG) was performed in cases with HCQ retinopathy.

The diagnosis of HCQ retinopathy was made if abnormalities were detected on clinical examination, Octopus 10-2 visual fields, multifocal ERG, SD-OCT, and/or FAF. Patients with HCQ retinopathy were separated into early, obvious, and severe cases of toxicity. The early group consisted of eyes with no disruption of the ellipsoid zone (EZ) in the foveal and parafoveal area on SD-OCT. On fundus examination, no or early macular findings were identified. The obvious group comprised eyes presenting the classic parafoveal retinal pigment epithelium (RPE) changes with a disrupted parafoveal EZ on either one or both sides of the fovea, and an intact foveal EZ. The severe group included only eyes with clear foveal and parafoveal EZ disruption.

All patients were selected from patients being treated for rheumatic conditions, such as systemic lupus erythematosus, Sjogren's disease, and rheumatoid arthritis. Clinical data including the daily dose, duration of drug exposure, and a cumulative dose were recorded. Eyes with neovascular age-related macular degeneration, diabetic retinopathy, significant lens opacities, and other ophthalmic diseases affecting the macula were excluded.

Participants were divided into one of two groups: HCQ retinopathy, or on HCQ therapy without clinical evidence of retinopathy. Each group was compared to a healthy age-matched control group with no history of HCQ use.

This study is registered at ClinicalTrials.gov (NCT01981148).

Fluorescence Lifetime Imaging Ophthalmoscope

Fluorescence lifetime data were obtained using the fluorescence lifetime imaging ophthalmoscope, based on a Heidelberg retina angiograph (HRA) Spectralis system.

A 473-nm pulsed laser at 80-MHz repetition rate was used to excite retinal autofluorescence. Emitted photons were recorded in a short spectral channel (498–560 nm, SSC) and a long spectral channel (560–720 nm, LSC) using highly sensitive hybrid photon-counting detectors (HPM-100-40; Becker&Hickl, Berlin, Germany), and time-correlated single-photon counting (TCSPC) modules (SPC-150; Becker&Hickl). At least 1000 photons per pixel were recorded within the macular center. To guarantee correct allocation of the detected photons, a built-in infrared scanning laser ophthalmoscope image was used. In addition, the near-infrared image was used to align the FLIO images.

Within the central 30° of the macula, a decay trace was built from the recorded single photons, and a biexponential decay function was calculated using a binning factor of 1. The double-exponential estimate of the fluorescence decay curve calculated a mean decay trace that is characterized by a short ($T1$) and a long ($T2$) decay component, along with their relative amplitudes $a1$ and $a2$. The mean fluorescence lifetime (Tm) represents the amplitude-weighted mean fluorescence

TABLE 1. Comparison of Characteristics Between Patients With and Without Retinal Toxicity

Variable	Chloroquine Retinopathy, <i>n</i> = 7	Chloroquine Use, <i>n</i> = 14
Patient characteristics,		
No.		
Female, <i>n</i>	5	12
Age, y (range)	68.7 ± 7.9 (51-75)	46.1 ± 7.7 (34-57)
Primary indication,		
No. (%)		
Lupus erythematosus	3 (42.8)	9 (64.3)
Polyarthritis	1 (14.3)	1 (7.1)
Rheumatoid arthritis	1 (14.3)	2 (14.3)
Sjögren syndrome	1 (14.3)	1 (7.1)
Folliculitis decalvans	1 (14.3)	0 (0)
Drug use		
Cumulative use, g	920.1 ± 129.2	462.7 ± 113
Duration of use, y	14.4 ± 9.7	5.0 ± 5.3

decay time per pixel and wavelength channel, which was determined by the tau values $T1$ and $T2$, and the amplitudes $a1$ and $a2$. The theories and technical details behind FLIO have been described in more detail in previous publications.⁹⁻¹³

Analysis of Fluorescence Lifetime Data

The FLIO reader software (ARTORG Center for Biomedical Engineering Research, University of Bern, Switzerland) was used to analyze fluorescence lifetime data.

The short and the long spectral channels were analyzed separately. Retinal autofluorescence lifetimes were quantified within the standard Early Treatment Diabetic Retinopathy Study (ETDRS) grid with the following measurements: central area (diameter [d] = 1 mm), inner ring (d = 3 mm), and outer ring (d = 6 mm).¹⁰

Analysis of OCT Data

OCT images were analyzed in the foveal and parafoveal region for decreased reflectivity of the EZ, EZ disruption, interdigitation zone (IZ) disruption, RPE disruption, and external limiting membrane (ELM) disruption, as well as thinning of the outer nuclear layer (ONL).

Statistical Analysis

All data are presented as mean ± standard error of the mean (SEM). Prism GraphPad (Prism 6; GraphPad Software, Inc., La Jolla, CA, USA) was used for statistical analysis. The D'Agostino-Pearson normality test was performed and a t -test was used to compare lifetime values between cohorts. Results were averaged from both eyes in each subject before group statistics were performed. Pearson correlation coefficient was used to analyze the correlation between the continuous variables. P values of less than 0.05 were considered to be statistically significant.

RESULTS

The demographic characteristics and clinical features of the 21 included HCQ patients are shown in Table 1. All participants were Caucasian, phakic with clear media, and had no concomitant ophthalmic diseases.

Seven patients (14 eyes) showed definite HCQ retinopathy, and 14 patients (28 eyes) were on HCQ treatment but with no

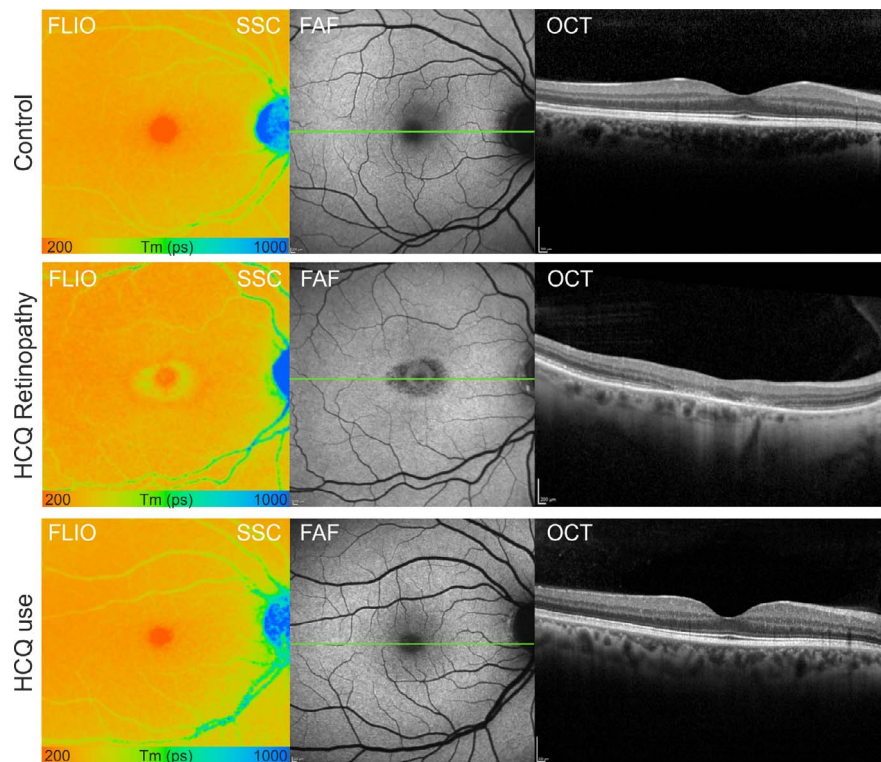


FIGURE 1. Fluorescence lifetime images (FLIO, short spectral channel [SSC], 498–560 nm), fundus autofluorescence image (FAF), in a healthy subject (control, *top row*), a patient with hydroxychloroquine (HCQ) retinopathy (*middle*), and a patient on HCQ therapy (*below*). Corresponding optical coherence tomography (OCT) scan of a horizontal scan through the macula is shown also.

clinical abnormalities. Between the two groups, significant differences included the mean age ($68.7 \pm \text{SD } 7.9$ years in eyes with HCQ retinopathy and $46.1 \pm \text{SD } 7.7$ in those without retinopathy, $P < 0.0001$), mean duration of HCQ use (14.4 ± 9.7 vs. 5.0 ± 1.5 years, $P = 0.0048$), and cumulative HCQ dose (920.1 ± 129.2 vs. 462.7 ± 113 g, $P = 0.002$). The HCQ retinopathy group included eight eyes (58.1%) with retinopathy displaying the classic bull's-eye maculopathy and six eyes (42.9%) with early retinopathy.

Patients were compared to a total of 20 healthy controls with no history of HCQ use; each analyzed group included 20 eyes of 10 age-matched subjects (mean age \pm SD: 68.7 ± 5.4 years for eyes with HCQ retinopathy and 46.4 ± 6.3 years for those without retinopathy).

Fluorescence Lifetimes in Patients With Hydroxychloroquine Retinopathy and Healthy Controls

The fundus of healthy eyes revealed normal fluorescence lifetime patterns with a gradual prolongation of lifetimes from the center outward. Patients with HCQ retinopathy displayed a pericentral ring of prolonged mean fluorescence lifetimes, which varied from a half to a complete ring-shaped lesion. Generally, the disease-specific distinctive fluorescence lifetime changes were more pronounced in the SSC; thus for simplification we focused on the SSC in this study. All patients with clinically diagnosed HCQ retinopathy displayed characteristic disease features in fundus photography, OCT, and FAF imaging (Fig. 1).

In both healthy controls and patients with HCQ retinopathy, the shortest fluorescence lifetimes were measured within the macular center (Fig. 2). However, patients with HCQ retinopathy displayed significantly longer mean fluorescence

lifetimes within the central subfield of the ETDRS grid compared to control eyes (SSC: 295 ± 22 vs. 229 ± 15.3 ps, $P = 0.002$). Furthermore, in patients with HCQ retinopathy, the mean lifetime values T_m within the inner ring of the ETDRS grid were significantly prolonged in comparison to the control subjects (SSC: 374 ± 7 vs. 313 ± 8 ps, $P = 0.0001$) (Table 2). Thereby, T_m was lengthened by 19.4% in patients with HCQ retinopathy in the SSC. In areas of structurally unaffected retina within the outer ETDRS ring, fluorescence lifetime values in patients with HCQ retinopathy were comparable with those of healthy age-matched controls ($P = 0.195$). There was no significant difference in lifetime measurements between the right and left eyes (paired t -test, $P = 0.8219$).

We analyzed differences in autofluorescence lifetimes between healthy participants and patients with HCQ retinopathy at different severity grades. Disease severity was graded as early in 4% of eyes (six), obvious in 50% of eyes (seven), and severe in 7% of eyes (one). In OCT, patients with obvious and severe HCQ retinopathy manifested with a disruption or complete parafoveal loss of ONL, ELM, EZ, and disruption of the underlying RPE layer within the parafoveal region, which corresponded to areas of prolonged mean fluorescence lifetimes. In the severe and obvious cases, a parafoveal concentric ring or crescent ring-shaped area showed a mottled loss of FAF, which correlated to prolonged lifetimes. The typical “flying saucer” sign was observed in patients with preservation of the central subfoveal architecture and a perifoveal loss of the outer retinal tissue (Fig. 3).

In four eyes with early HCQ retinopathy, FLIO demonstrated a subtle perifoveal ring of prolonged lifetimes. Patients were found to have a completely normal fundus exam and FAF; however, OCT demonstrated a minor loosening of the photoreceptor layer with thinning of the ONL (Fig. 4).

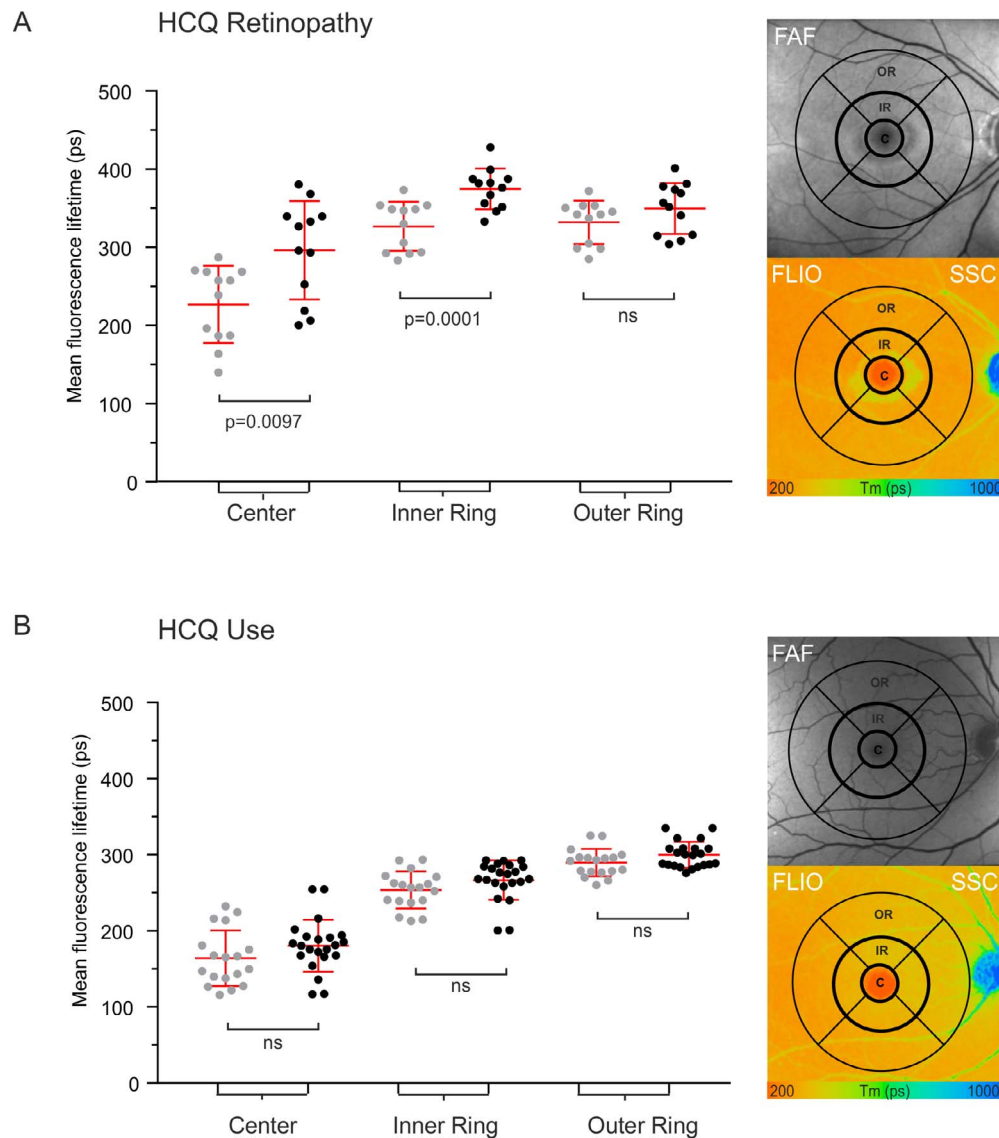


FIGURE 2. (A) Quantitative analysis of retinal autofluorescence lifetimes (FLIO) in patients with hydroxychloroquine (HCQ) retinopathy (severity = obvious) and (B) in patients on HCQ therapy without retinopathy. Mean fluorescence lifetime values, with error bars (SEM), were evaluated within the ETDRS grid shown (diameter central area C = 1 mm, inner ring IR = 3 mm, outer ring OR = 6 mm). Mean values from the SSC were compared with the healthy retina within the central area, inner and outer ETDRS ring. ns, not significant.

The mean retinal thickness of the inner EDTRS ring was significantly reduced in patients with HCQ retinopathy compared to patients currently on therapy, as well as healthy controls (259.5 ± 5.9 vs. 341.5 ± 5.9 , vs. 335.8 ± 5.5 μm ; both $P < 0.0001$). The mean retinal thickness showed no significant correlation with mean fluorescence lifetimes ($r^2 = 0.189$, $P = 0.329$).

Fluorescence Lifetimes in Patients on Chloroquine Therapy Without Retinopathy

Eyes in the HCQ group without retinopathy showed no specific findings on FAF imaging, and OCT-scan images showed structurally intact photoreceptors and a RPE/Bruch's membrane. Quantitative analysis of mean fluorescence lifetimes revealed no significant difference between patients on HCQ therapy compared to the corresponding area in the control eyes (Fig. 2). This

was observed in both the subgroup receiving HCQ treatment ≥ 5 years and in the subgroup treated with HCQ < 5 years.

The difference between mean retinal thickness of the inner ring in patients on HCQ therapy compared to healthy controls was insignificant (341.5 ± 5.9 vs. 338.2 ± 5.6 μm ; $P = 0.155$) (Table 2).

Cumulative Dose and Mean Fluorescence Lifetimes

Regression analyses were performed to evaluate the correlation between the cumulative dose and the mean fluorescence lifetimes (Fig. 5). Mean fluorescence lifetime values within the inner ring of the ETDRS grid in the SSC correlated with the cumulative HCQ dosage ($r^2 = 0.35$, $P = 0.026$). In this analysis, in eyes of patients on current HCQ treatment with no clinical evidence of retinopathy, a weak correlation between the cumulative dose and mean fluorescence lifetime values was identified ($r^2 = 0.17$, $P = 0.048$).

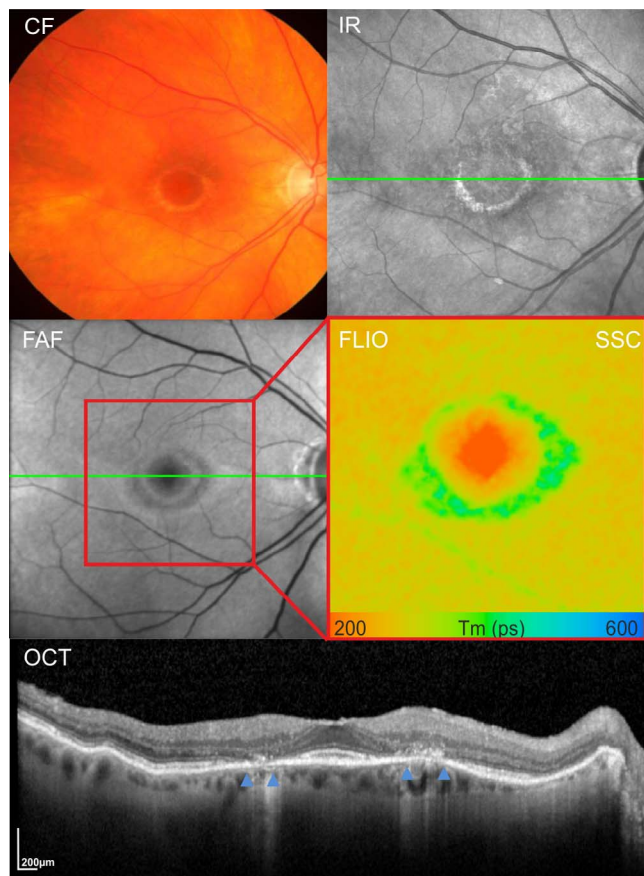


FIGURE 3. Correlation of fluorescence lifetime findings with optical coherence tomography (OCT). Color fundus (CF), infrared (IR), FAF intensity, autofluorescence lifetime images (FLIO, SSC = 498–560 nm), and OCT of the indicated *green line* in the FAF and IR images. Areas of long fluorescence lifetimes (*green*) in FLIO corresponded to areas of RPE atrophy with the absence of ONL, EZ, IZ, and intraretinal hyperreflective deposits (marked with *blue arrowheads*).

Analysis of Individual Fluorescence Lifetime Components

A two-dimensional (2-D) histogram allows in-depth analysis of the amplitude-weighted mean fluorescence lifetime value, T_m , by separately representing its two single components, T_1 (short decay component) on the x -axis and T_2 (long decay component) on the y -axis.

Thereby, the fovea featured the shortest T_1 , combined with short T_2 values, in all cohorts. The lifetime cloud of areas with photoreceptor atrophy in patients with HCQ retinopathy revealed longer T_1 and T_2 values than the surrounding retina. In patients currently on HCQ therapy without retinopathy, no differences in the lifetime clouds was observed in comparison to healthy controls. The optic nerve head featured the longest T_2 values in all cohorts (Fig. 6).

DISCUSSION

Over the past decade, advancements in retinal imaging, histologic studies, and animal experiments have increased our understanding of pathological features of CQ/HCQ retinopathy. However, as clinical changes can be subtle, particularly in early stages of disease, and can lead to irreversible visual impairments, imaging techniques are needed to identify alterations at an earlier stage. Within the field of

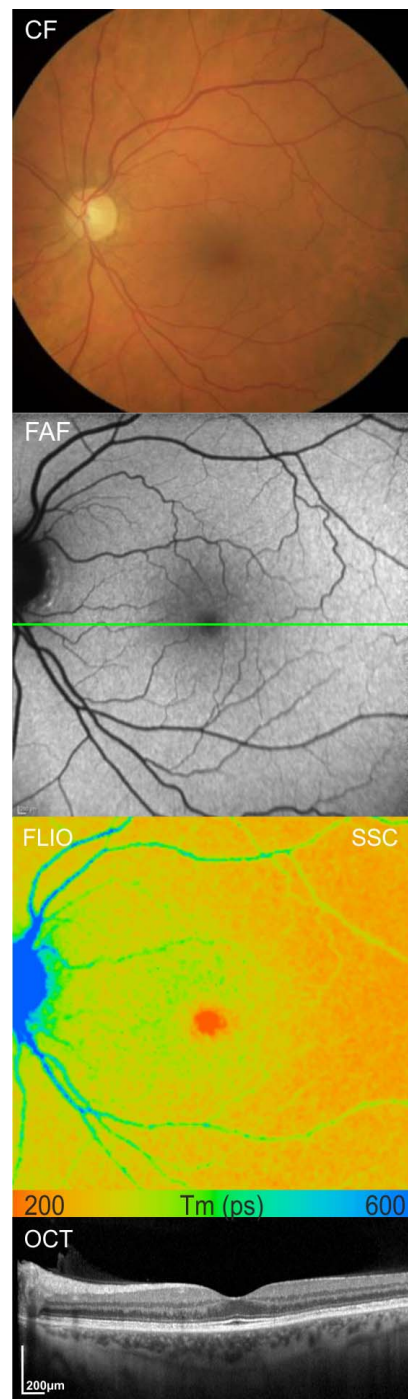


FIGURE 4. Multimodal imaging of one eye of a patient with early HCQ retinopathy showing a parafoveal ring of prolonged lifetimes. Fundus photography (CF), FAF image, fluorescence lifetime images in the SSC (FLIO, SSC); and SD-OCT horizontal scan of the indicated *green line* in the FAF image.

retinal imaging, FLIO is a relatively novel imaging modality with the ability to identify subtle alterations within the retina, and to provide further information in addition to conventional retinal imaging techniques.^{9–11,14,15}

The mechanism by which CQ/HCQ causes retinal toxicity is not well established; however, the outer retina, specifically the photoreceptors and RPE, have been proposed to play a major role.^{16–18} Previous studies have shown that both CQ and HCQ

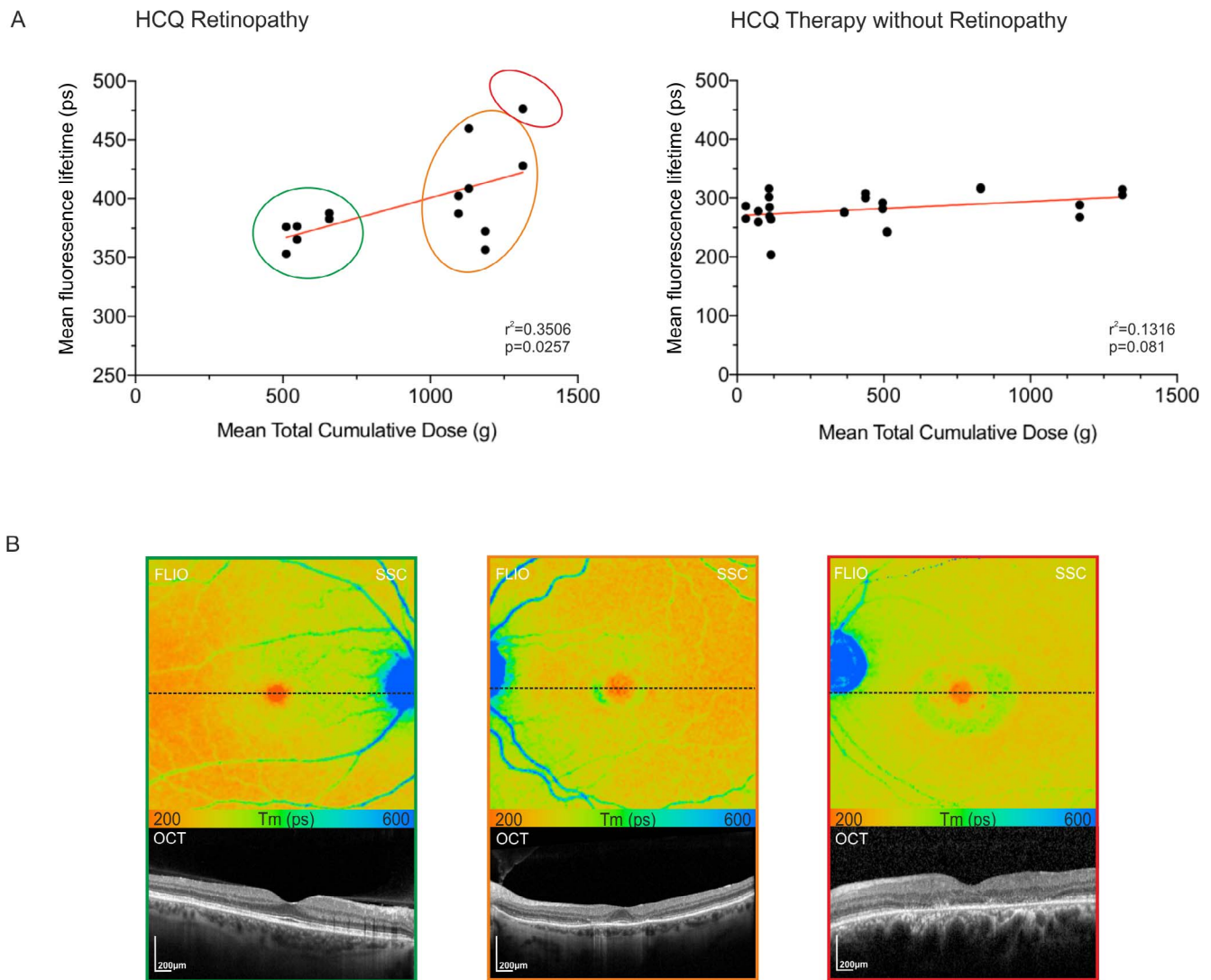


FIGURE 5. (A) Correlation of fluorescence lifetimes within the inner ring (IR) of the standard EDTRS grid with mean total cumulative dose in grams. A correlation index of (A) patients with HCQ retinopathy, $r^2 = 0.35$ ($P = 0.026$) and (B) HCQ use, $r^2 = 0.17$ ($P = 0.048$) was measured. (B) Representative fluorescence lifetime (FLIO, SSC) images of the three severity groups, early (green), obvious (orange), severe (red), with correlating OCT scan of the indicated lines in the FLIO images.

may interfere in the visual cycle by inhibiting the uptake activity of an organic anion transporting polypeptide, 1A2 (OATP1A2), found in the RPE. This is in agreement with the proposed accumulation of the medication in ocular tissues, such as the RPE, choroid, ciliary body, and iris, and in the retina.¹⁹ The accumulation of the medication at the level of the RPE may explain why further progression of the retinopathy can occur even after cessation of the drug.^{20,21} Consequently, outer retinal and photoreceptor degeneration with subsequent, secondary deterioration of the RPE may occur, which can be observed on OCT. While it remains unknown why the para- and perifoveal area of photoreceptors are most prone to the toxic effects of HCQ observed clinically and demonstrated in histology, it has been suggested that the difference in concentration between foveal and pericentral cones may be responsible.^{22,23}

In this prospective study, we investigated retinal fluorescence lifetimes in 14 eyes of 7 patients with HCQ retinopathy, and in 28 eyes of 14 patients currently on HCQ therapy using autofluorescence FLIO. In our study, patients with HCQ retinopathy displayed characteristic mean fluorescence life-

time patterns. Fluorescence lifetime imaging illustrated that the HCQ toxicity localizes in the parafoveal area, in the typical bulls-eye distribution with prolongation of retinal fluorescence lifetimes.

While at early stages in HCQ retinopathy retinal pigment epithelial abnormalities were identified as a fine paracentral ring of prolonged lifetimes, in more advanced cases, the circle of prolonged lifetimes appeared to broaden and become more distinct, which corresponded to the severity of OCT changes.

In early HCQ toxicity, the fine paracentral ring of prolonged lifetimes correlated to loosening of the photoreceptor layer and outer retinal abnormalities including the disruption of the IZ, with or without a disruption of the of EZ. This finding confirms results of a previous study in patients with retinitis pigmentosa, where areas of preserved RPE in the presence of photoreceptor disruption displayed a ring with prolonged fluorescence lifetimes in FLIO.²⁴

In more obvious and advanced stages of HCQ retinopathy, the distinct ring of prolonged lifetimes was measured within areas of atrophy, which correlated to a diffuse loss of photoreceptors and RPE with an increased transmission of

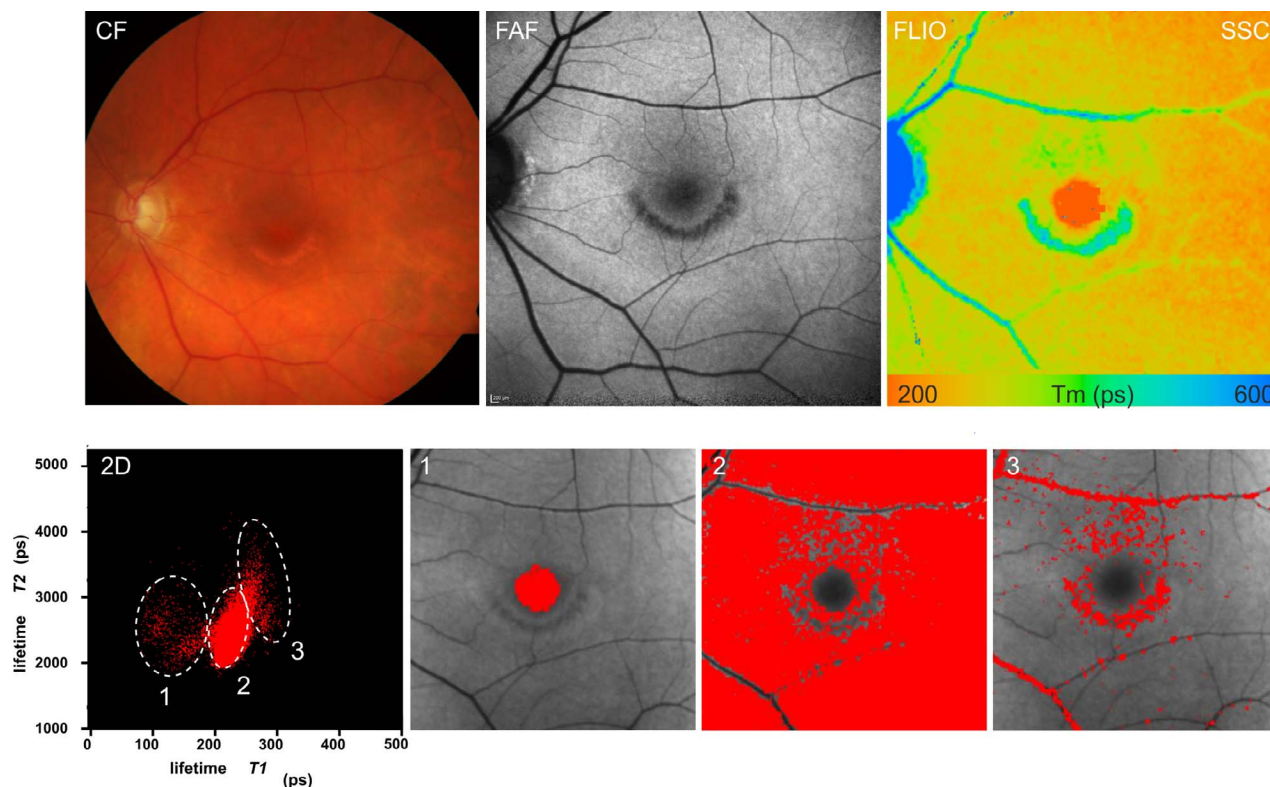


FIGURE 6. Analysis of individual lifetime components and spatial distribution in patients with definite HCQ retinopathy. Color fundus (CF), FAF intensity, and mean fluorescence lifetime (*Tm*, SSC) images. Corresponding distribution histograms of the short decay component *T1* versus the long decay component *T2* are shown. Spatial distribution of different lifetime clusters as follows: (1) fovea with short *T1* and short *T2*; (2) surrounding retina with short *T1* and midrange *T2*; and (3) atrophy with long *T1* and long *T2*.

the OCT signal to the choroid. This is in keeping with previous fluorescence lifetime reports of patients with geographic atrophy, Stargardt disease, retinitis pigmentosa, and choroide-remia, where prolonged lifetimes were identified within areas of photoreceptor and RPE atrophy.^{9,11,24}

We can only speculate about the provenience of the observed prolonged fluorescence lifetimes. Because areas with long fluorescence lifetimes are congruent with areas of hypoautofluorescence in FAF (Fig. 3), a contribution of lipofuscin can be excluded. On the other hand, long fluorescence lifetimes may be explained by loss of photoreceptors and a higher contribution of the choroid to observed lifetimes, similarly to what has been described in patients with choroideremia.²⁵ One possible, but speculative explanation for the short fluorescence lifetimes observed could be the presence of residual visual cycle activity, with or without the generation of visual cycle by-products, within this border zone between the unaffected retina and the RPE atrophy.^{26,27}

Plotting individual lifetime components, such as *T1* and *T2* on the 2-D histogram (Fig. 6), allows visualization of specific

retinal areas, such as the perifoveal area. In addition, areas with atrophy can be visualized. This tool may be used for quantification of atrophic changes in follow-up examinations and longitudinal studies.

This study had several limitations. Because the general consensus is that HCQ mainly targets the parafovea area, we considered only structural and functional characterization related to the central macular area.^{7,28} However, this may not be applicable for all patients, as numerous reports have confirmed that in Asian populations, for example, a more pericentral retinopathy, extending to the vascular arcades, is observed.²⁹ As our study population consisted solely of Caucasians of European descent, in which the peripheral phenotype has been documented in only 2% of cases, no significant results bias is expected.²⁹ Furthermore, as FLIO has been shown to be influenced by opacities in the optical axis, especially in the short spectral channel, we cannot exclude that some of the observed changes in our study were caused by imaging artifacts. Larger cohorts will be required to evaluate characteristic lifetime patterns in patients with HCQ retinop-

TABLE 2. Comparison of Mean Fundus Autofluorescence Lifetimes (\pm SD) Within the ETDRS Areas Between Subjects on HCQ Therapy and a Control Group Without HCQ

ETDRS	Central	Inner Ring	Outer Ring
HCQ retinopathy group, <i>n</i> = 7	295.2 \pm 34.4	374.4 \pm 26.7	348.3 \pm 29.4
Control group, <i>n</i> = 20	229.2 \pm 33.8	313.5 \pm 20.1	329.0 \pm 28.1
<i>P</i> value	0.002	0.0001	0.19
HCQ therapy group, <i>n</i> = 14	193.1 \pm 39.1	273.0 \pm 31.2	302.3 \pm 13.6
Control group, <i>n</i> = 20	163.3 \pm 33.1	255.0 \pm 19.9	290.2 \pm 13.9
<i>P</i> value	0.11	0.15	0.07

athy. In addition, to gain further insight into the long-term effects of HCQ therapy in patients with no clinical evidence of retinopathy, a larger population of patients on HCQ for over 5 years will be required. Longitudinal follow-up examinations of the patients currently taking HCQ and further correlation with functional parameters are currently under way to identify markers for disease progression.

This study established that HCQ retinopathy displays a characteristic mean fluorescence lifetime pattern. In patients currently on HCQ therapy with no clinical retinopathy, lifetimes were comparable to those of age-matched controls, suggesting that in HCQ retinopathy, FLIO is not yet able to detect metabolic changes before structural damage occurs. However, in this study we established that the FLIO technique in general might be helpful to detect, quantify, and monitor for retinal changes in patients taking HCQ.

Acknowledgments

Supported by Heidelberg Engineering GmbH, Germany.

Disclosure: **Y. Solberg**, None; **C. Dysli**, None; **B. Möller**, None; **S. Wolf**, Allergan (C), Bayer (C) Novartis (C), Heidelberg Engineering (F, C), Zeiss (C), Chengdu Kanghong (C); **M.S. Zinkernagel**, Allergan (C), Bayer (F, C), Novartis (C, D), Heidelberg Engineering (F)

References

- Rynes RI. Antimalarial drugs in the treatment of rheumatological diseases. *Br J Rheumatol*. 1997;36:799-805.
- Marmor MF, Kellner U, Lai TY, Lyons JS, Mieler WF; American Academy of Ophthalmology. Revised recommendations on screening for chloroquine and hydroxychloroquine retinopathy. *Ophthalmology*. 2011;118:415-422.
- Marmor MF, Kellner U, Lai TY, Melles RB, Mieler WF; American Academy of Ophthalmology. Recommendations on screening for chloroquine and hydroxychloroquine retinopathy (2016 revision). *Ophthalmology*. 2016;123:1386-1394.
- Melles RB, Marmor MF. The risk of toxic retinopathy in patients on long-term hydroxychloroquine therapy. *JAMA Ophthalmol*. 2014;132:1453-1460.
- Brinkley JR Jr, Dubois EL, Ryan SJ. Long-term course of chloroquine retinopathy after cessation of medication. *Am J Ophthalmol*. 1979;88:1-11.
- Mavrikakis M, Papazoglou S, Sfikakis PP, Vaiopoulos G, Rougas K. Retinal toxicity in long term hydroxychloroquine treatment. *Ann Rheum Dis*. 1996;55:187-189.
- Marmor MF, Carr RE, Easterbrook M, Farjo AA, Mieler WF; American Academy of Ophthalmology. Recommendations on screening for chloroquine and hydroxychloroquine retinopathy: a report by the American Academy of Ophthalmology. *Ophthalmology*. 2002;109:1377-1382.
- Becker W. Fluorescence lifetime imaging—techniques and applications. *J Microsc*. 2012;247:119-136.
- Dysli C, Wolf S, Hatz K, Zinkernagel MS. Fluorescence lifetime imaging in Stargardt disease: potential marker for disease progression. *Invest Ophthalmol Vis Sci*. 2016;57:832-841.
- Dysli C, Wolf S, Berezin MY, Sauer L, Hammer M, Zinkernagel MS. Fluorescence lifetime imaging ophthalmoscopy. *Prog Retin Eye Res*. 2017;60:120-143.
- Dysli C, Wolf S, Zinkernagel MS. Autofluorescence lifetimes in geographic atrophy in patients with age-related macular degeneration. *Invest Ophthalmol Vis Sci*. 2016;57:2479-2487.
- Sauer L, Klemm M, Peters S, et al. Monitoring foveal sparing in geographic atrophy with fluorescence lifetime imaging ophthalmoscopy - a novel approach. *Acta Ophthalmol*. 2018;96:257-266.
- Sauer L, Gensure RH, Hammer M, Bernstein PS. Fluorescence lifetime imaging ophthalmoscopy: a novel way to assess macular telangiectasia type 2. *Ophthalmol Retina*. 2018;2:587-598.
- Dysli C, Queller G, Abegg M, et al. Quantitative analysis of fluorescence lifetime measurements of the macula using the fluorescence lifetime imaging ophthalmoscope in healthy subjects. *Invest Ophthalmol Vis Sci*. 2014;55:2106-2113.
- Dysli C, Wolf S, Zinkernagel MS. Fluorescence lifetime imaging in retinal artery occlusion. *Invest Ophthalmol Vis Sci*. 2015;56:3329-3336.
- Kellner S, Weinitz S, Kellner U. Spectral domain optical coherence tomography detects early stages of chloroquine retinopathy similar to multifocal electroretinography, fundus autofluorescence and near-infrared autofluorescence. *Br J Ophthalmol*. 2009;93:1444-1447.
- Marmor MF. Comparison of screening procedures in hydroxychloroquine toxicity. *Arch Ophthalmol*. 2012;130:461-469.
- Rodriguez-Padilla JA, Hedges TR III, Monson B, et al. High-speed ultra-high-resolution optical coherence tomography findings in hydroxychloroquine retinopathy. *Arch Ophthalmol*. 2007;125:775-780.
- Rosenthal AR, Kolb H, Bergsma D, Huxsoll D, Hopkins JL. Chloroquine retinopathy in the rhesus monkey. *Invest Ophthalmol Vis Sci*. 1978;17:1158-1175.
- de Sistiernes L, Hu J, Rubin DL, Marmor MF. Localization of damage in progressive hydroxychloroquine retinopathy on and off the drug: inner versus outer retina, parafovea versus peripheral fovea. *Invest Ophthalmol Vis Sci*. 2015;56:3415-3426.
- Mititelu M, Wong BJ, Brenner M, Bryar PJ, Jampol LM, Fawzi AA. Progression of hydroxychloroquine toxic effects after drug therapy cessation: new evidence from multimodal imaging. *JAMA Ophthalmol*. 2013;131:1187-1197.
- Bernstein HN, Ginsberg J. The pathology of chloroquine retinopathy. *Arch Ophthalmol*. 1964;71:238-245.
- Wetterholm DH, Winter FC. Histopathology of chloroquine retinal toxicity. *Arch Ophthalmol*. 1964;71:82-87.
- Dysli C, Schurch K, Pascal E, Wolf S, Zinkernagel MS. Fundus autofluorescence lifetime patterns in retinitis pigmentosa. *Invest Ophthalmol Vis Sci*. 2018;59:1769-1778.
- Dysli C, Wolf S, Tran HV, Zinkernagel MS. Autofluorescence lifetimes in patients with choroideremia identify photoreceptors in areas with retinal pigment epithelium atrophy. *Invest Ophthalmol Vis Sci*. 2016;57:6714-6721.
- Sparrow JR, Fishkin N, Zhou J, et al. A2E, a byproduct of the visual cycle. *Vision Res*. 2003;43:2983-2990.
- Sparrow JR, Marsiglia M, Allikmets R, et al. Flecks in recessive Stargardt disease: short-wavelength autofluorescence, near-infrared autofluorescence, and optical coherence tomography. *Invest Ophthalmol Vis Sci*. 2015;56:5029-5039.
- Yusuf IH, Sharma S, Luqmani R, Downes SM. Hydroxychloroquine retinopathy. *Eye (Lond)*. 2017;31:828-845.
- Lee DH, Melles RB, Joe SG, et al. Pericentral hydroxychloroquine retinopathy in Korean patients. *Ophthalmology*. 2015;122:1252-1256.