



Serological detection of anti-leptospiral antibodies in outdoor cats in Switzerland

Sarah Noëmi Hässle^a, Sabrina Rodriguez-Campos^b, Judith Howard^c, Christelle Speiser-Fontaine^d, Simone Schuller^{a,*}

^a Department Clinical Veterinary Medicine, Division of Small Animal Internal Medicine, Vetsuisse Faculty, University of Bern, Länggassstrasse 128, CH-3001, Bern, Switzerland

^b Institute of Veterinary Bacteriology, Vetsuisse Faculty, University of Bern, Länggassstrasse 122, CH-3012, Bern, Switzerland

^c Central Diagnostic Laboratory, Department of Clinical Veterinary Medicine, Vetsuisse Faculty, University of Bern, Länggassstrasse 124, CH-3012, Bern, Switzerland

^d Companion Animal Medical Department, Virbac group, 13^{ème} rue LID, F-06511, Carros, France

ARTICLE INFO

Keywords:

Leptospirosis
Feline
Seroprevalence
Microscopic agglutination test

ABSTRACT

Leptospirosis is endemic in Switzerland affecting a broad range of hosts. The aim of this study was to estimate the exposure of cats to *Leptospira* in Switzerland.

Plasma samples from 107 outdoor cats with an array of clinical problems were tested via microscopic agglutination test for the presence of anti-leptospiral antibodies against 12 serovars of 9 serogroups. Using a reciprocal cut-off titre of 1:100, an overall seroprevalence of 10.3% (95%CI 5.2–17.7) was observed. Seroreactivity against serovars Bratislava ($n = 6$), Australis (2), Pomona (3) and Copenhageni (1) was detected with reciprocal titres ranging from 1:100 to 1:800. The serologic status of the cats was independent of the disease group ($p = 0.62$). These results show that cats in Switzerland are commonly exposed to *Leptospira* and confirm the importance of serogroup Australis in this region.

1. Introduction

Leptospirosis is endemic in Switzerland causing acute systemic disease in dogs (Major, Schweighauser, & Francey, 2014), beavers (Marreros et al., 2018) and sporadically humans (Schreiber et al., 2015) and abortion in livestock (Schnydrig et al., 2017; Vidal, Syring, & Rodriguez-Campos, 2015). In Swiss dogs, a dramatic increase in the incidence of acute leptospirosis was documented between 2003 and 2012 (Major et al., 2014). In both, clinically infected and asymptomatic dogs in Switzerland, the predominant infecting serovars belong to serogroup Australis (Delaude et al., 2017; Major et al., 2014).

The role of *Leptospira* as a pathogen in cats is not fully understood. Serologic evidence supports natural infection in cats with seroprevalences ranging between 4 and 17.9% (Pratt, Conan & Rajeev, 2017; Weis et al., 2016), but reports of acute clinical disease are rare (Agunloye & Nash, 1996; Arbour, Blais, Carioto & Sylvestre, 2012) and studies examining a possible relationship between seropositivity and chronic kidney disease have so far yielded contradictory results (Luciani, 2004; Rodriguez et al., 2014; Shropshire et al., 2016). Urinary shedding of pathogenic *Leptospira* spp. has been reported in 3% of outdoor cats in Germany, suggesting that cats may play a significant

role as maintenance hosts (Weis et al., 2016). The aim of this study was to estimate the seroprevalence of anti-leptospiral antibodies in Swiss outdoor cats.

2. Materials and methods

2.1. Ethical statement

Written owner consent for the use of patient-related data and remnant samples for research purposes was obtained for all cats. Studies using remnant samples do not require formal ethical approval in Switzerland.

2.2. Study design, inclusion and exclusion criteria

The study was designed as a retrospective serologic survey based on stored feline plasma samples collected between March and December 2017. Samples were included, irrespective of the presenting problem or final diagnosis, if written consent for the use of clinical data and remnant diagnostic samples was present and the medical history indicated the cat had outdoor access. Samples were excluded if macroscopically

* Corresponding author.

E-mail address: simone.schuller@vetsuisse.unibe.ch (S. Schuller).

Table 1
Panel of 12 *Leptospira* spp. used as live antigens for microscopic agglutination testing (MAT).

Genomospecies	Serogroup	Serovar	Strain
<i>L. interrogans</i>	Australis	Australis	Ballico
	Australis	Bratislava	Jez-Bratislava
	Autumnalis	Autumnalis	Akiyami A
	Canicola	Canicola	Hond Utrecht IV
	Icterohaemorrhagiae	Copenhageni	M20
	Icterohaemorrhagiae	Icterohaemorrhagiae	RGA
	Pomona	Pomona	Pomona
	Pyrogenes	Pyrogenes	Salinem
	Sejroe	Hardjo	Hardjoprajitno
	Sejroe	Sejroe	M84
<i>L. borgpetersenii</i>	Ballum	Ballum	Mus127
<i>L. kirschneri</i>	Grippotyphosa	Grippotyphosa	Moskva V

haemolytic or lipaemic, or if the plasma volume was insufficient for microscopic agglutination testing (MAT).

2.3. Sample handling

Blood was collected into lithium heparin tubes and the plasma separated after centrifugation, samples of which were stored at -20°C for no more than 10 months.

2.4. Microscopic agglutination testing

Plasma samples were examined for the presence of antibodies against pathogenic *Leptospira* by microscopic agglutination test (MAT) at the Swiss national reference laboratory for animal leptospirosis (ZOBA) according to WHO standard using live cultures of twelve *Leptospira* serovars belonging to nine serogroups (Table 1). Plasma samples were initially screened for agglutination of *Leptospira* at a dilution of 1:100. While a cut-off titre of ≥ 100 has been used in the majority of existing prevalence studies in cats (Pratt et al., 2017; Weis et al., 2016), lower titres can be taken as evidence of previous exposure to *Leptospira* spp (Mylonakis et al., 2005) but these were not examined in the present study. Reactive sera were titrated in a serial two-fold dilution to determine the end-point titre defined as the highest serum dilution at which at least 50% agglutination occurred. All samples were read within 30 min after incubation for 2.5 h at 29°C . To reduce inter-observer variability, all samples were analysed by the same person. A reciprocal titre of $\geq 1:100$ was set as the cut-off value for seropositivity.

2.5. Statistical analysis

The data was analysed using a commercial software program (NCSS 11 Statistical Software. 2016. NCSS, LLC, Kaysville, Utah, USA). Differences between seropositive and seronegative cats regarding age, sex, breed, region of origin (by postal code) and disease group were examined using the Kruskal–Wallis Multiple-Comparison Z-value test for continuous data and the Pearson's Chi squared or Fisher's exact test for categorical data. The relationship between age and seropositivity was tested using logistic regression analysis. Statistical significance was set at $p < 0.05$.

3. Results

3.1. Sampled population

All cats lived within a 120 km radius of the hospital, which corresponds to its main region of referral. The median age of the cats was 6.9 years (IQR 2.5–11 years; range 1 month–17 years). There were 66 males (5 entire/61 neutered) and 41 females (5 entire/36 neutered). The cats were of 12 different breeds and showed a wide range of clinical problems (Fig. 1). None of the cats was vaccinated against leptospirosis. Disorders of the urinary tract were diagnosed in 16/107 cats. These were chronic kidney disease ($n = 8$), in 5/8 cases in conjunction with uni- or bilateral ureteral obstruction, idiopathic cystitis ($n = 3$), ureteral obstruction with bacterial urinary tract infections (UTI) ($n = 2$), acute kidney injury (AKI) ($n = 2$) and bacterial UTI with no other problems ($n = 1$).

The gastrointestinal problems included ileus ($n = 3$), acute hepatitis of undetermined origin ($n = 3$), acute gastroenteritis ($n = 2$), pancreatitis ($n = 2$) and one each of the following: bacterial cholangitis, triaditis, hepatic lipidosis, hepatic amyloidosis, gastric mid-body stenosis, feline gastrointestinal eosinophilic sclerosing fibroplasia, obstipation and atresia ani.

Conditions grouped under “other” were: feline infectious peritonitis ($n = 4$), pyothorax ($n = 2$), and one each of the following: sterile exudate in the thoracic cavity of undetermined origin, chylothorax, multiple dermal abscesses, Evans' syndrome, sublingual cyst and multiple fistulant skin lesions.

3.2. Seroreactivity and reactive serogroups

Of the 107 samples tested, 11 (10.3%; 95%CI 5.2–17.7) had a

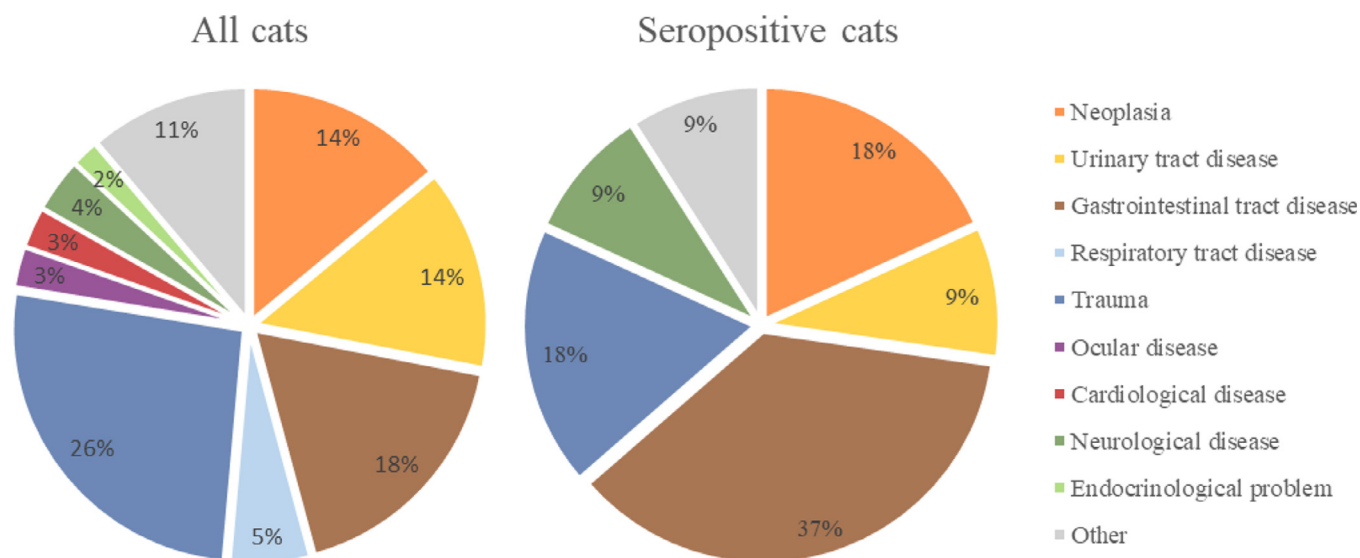


Fig. 1. Proportions of disease categories in 107 outdoor cats presented to a referral hospital in Switzerland included in this study.

Table 2
Numbers of individuals, relative prevalence (%) and 95% confidence interval (CI) of reactivity to *Leptospira* serovars in 107 cats.

MAT titre	Leptospiral serovar												
	All serovars	Grippityphosa	Australis	Pomona	Canicola	Icterohaemorrhagiae	Hardjo	Bratislava	Autumnalis	Sejroe	Pyogenes	Ballum	Copenhageneri
≥1:100	n	11	2	3	1	1	1	6	1	1	1	1	1
	%	10.3	1.9	2.8	1.0	1.0	1.0	5.6	1.0	1.0	1.0	1.0	0.9
	CI	5.2–17.7	0.2–6.6	0.6–8.0	0.0–2.0	0.0–2.0	0.0–2.0	2.1–11.8	0.0–2.0	0.0–2.0	0.0–2.0	0.0–2.0	0.0–2.0
≥1:200	n	9	2	2	1	1	1	5	1	1	1	1	1
	%	8.4	1.9	1.9	1.0	1.0	1.0	4.7	1.0	1.0	1.0	1.0	1.0
	CI	3.9–15.4	0.2–6.6	0.2–6.6	0.0–2.0	0.0–2.0	0.0–2.0	1.5–10.6	0.0–2.0	0.0–2.0	0.0–2.0	0.0–2.0	0.0–2.0
≥1:400	n	3	1	1	1	1	1	2	1	1	1	1	1
	%	2.8	1.0	1.0	1.0	1.0	1.0	1.9	1.0	1.0	1.0	1.0	1.0
	CI	0.6–8.0	0.0–2.0	0.0–2.0	0.0–2.0	0.0–2.0	0.0–2.0	0.2–6.6	0.0–2.0	0.0–2.0	0.0–2.0	0.0–2.0	0.0–2.0
≥1:800	n	1	1	1	1	1	1	1	1	1	1	1	1
	%	0.9	1.0	1.0	1.0	1.0	1.0	0.9	1.0	1.0	1.0	1.0	1.0
	CI	0.02–5.1	0.0–2.0	0.0–2.0	0.0–2.0	0.0–2.0	0.0–2.0	0.0–2.0	0.0–2.0	0.0–2.0	0.0–2.0	0.0–2.0	0.0–2.0

positive MAT reaction at a dilution of 1:100 (Table 2). Of these, 10 were positive for one single serovar and one was positive for two serovars. Seroreactivity was observed for serogroup Australis (n = 8), Pomona (n = 3) and Icterohaemorrhagiae (n = 1). Titres of 1:400 were found in 3 cats (serovar Bratislava (n = 2) and Pomona (n = 1)) and a titre of 1:800 was found in 1 cat (serovar Pomona).

There were no significant differences in age, sex, neuter status, breed or region of origin between seropositive and seronegative cats (p > 0.05). There was no statistically significant relationship between age and seropositivity (R2 0.0016; p = 0.73).

The serologic status of the cats was independent of their disease group (p = 0.62). Two out of the eleven seropositive cats were presented at the clinic because of trauma, two with acute gastroenteritis and one each of the following: alimentary small-cell lymphoma, acute hepatitis, obstipation, seizure, AKI of unknown cause and multiple abscesses.

The cat with the titre of 1:800, which is the cut-off commonly used to diagnose acute infection (Hartmann et al., 2013), had a chronic history of inappetence, weight loss and hyperthyroidism. Upon examination a marked increase in serum amyloid A (124 µg/ml; reference range <5) was present in the absence of an inflammatory leucogram. Albumin was moderately decreased (20.6 g/l; reference range 30.3–40.5). A marked proteinuria was detected (urinary protein creatinine ratio 2.26; reference range <0.4) with an inactive sediment. Ultrasonographically the cat showed a diffuse thickening of the muscularis of the small intestine, a nodular hepatomegaly, moderate mesenteric lymphadenopathy and a mottled appearance of the spleen. The kidneys showed a loss in corticomedullary definition with radial striation. These findings were suggestive of lymphoma and a chronic proteinuric nephropathy. However, fine needle aspiration of liver, spleen and mesenteric lymph nodes were inconclusive, and no further diagnostics were performed.

4. Discussion

The results of this study demonstrate that exposure to pathogenic *Leptospira* can occur in cats not suspected to have leptospirosis living in western Switzerland. The seroprevalence of 10.3% in this cohort does not exceed that reported in other recent studies which range between 4% and 17.9% (Pratt et al., 2017; Weis et al., 2016). In comparison, the seroprevalence in Swiss dogs not suspected to have leptospirosis was 17% in a recent seroprevalence study (Delaude et al., 2017).

The predominant serogroup that cats reacted with was Australis, followed by Pomona and Icterohaemorrhagiae. The present data suggests that despite different lifestyles and potentially different routes of infection, dogs and cats in Switzerland are exposed to similar serogroups. In acutely infected dogs in Switzerland, the predominant reactive serogroup is Australis, with fewer reactions to Grippityphosa, Icterohaemorrhagiae and Pomona (Major et al., 2014).

Cats included in this study were not suspected to have leptospirosis and showed a wide range of clinical problems. Seropositive cats were no more likely to have signs suggestive of leptospirosis, such as acute or chronic renal insufficiency, hepatic problems or effusions, than seronegative cats. In the cat with the highest reciprocal titre (1:800 against serogroup Pomona), a marked proteinuria with an inactive sediment was detected but no final diagnosis was established. With the hindsight knowledge of its high MAT titre, real-time PCR on a urine sample to detect possible chronic renal colonization with pathogenic *Leptospira* spp. would have been of interest at the time, but was not performed.

Despite acute clinical leptospirosis likely being a rare occurrence in cats, clinicians should bear in mind that cats clearly can get naturally infected with pathogenic *Leptospira* spp. and some may develop clinical signs such as acute or chronic nephropathies and effusions (Agunloye & Nash, 1996; Arbour et al., 2012).

Limitations of this study include the use of convenience samples of a hospital population of cats rather than a prospective, stratified

approach; the limited number of samples analysed and the sole use of MAT for serogroup diagnosis. Future studies should apply serology in combination with urine real-time PCR and molecular typing in a larger cohort of cats, to further characterize their role as incidental or reservoir hosts of *Leptospira* spp. in Switzerland.

In summary, outdoor cats in Switzerland are exposed to *Leptospira* spp. with a seroprevalence of 10.3%. The predominant serogroup was Australis, which correlates with findings in acutely infected dogs and dogs not suspected to have leptospirosis in Switzerland.

Declaration of Competing Interest

Christelle Speiser-Fontaine is employed by VIRBAC, Companion Animal Medical Department, Carros, France, which also funded this study.

Acknowledgements

We would like to thank Stefanie Müller from the Swiss National Reference Laboratory for Leptospirosis for performing the MATs.

Ethical statement

Written owner consent for the use of patient-related data and leftover samples for research purposes was obtained for all cats. Studies using leftover samples do not require formal ethical approval in Switzerland.

References

- Agunloye, C. A., & Nash, A. S. (1996). Investigation of possible leptospiral infection in cats in Scotland. *The Journal of Small Animal Practice*, 37(3), 126–129.
- Arbour, J., Blais, M. C., Carioto, L., & Sylvestre, D. (2012). Clinical leptospirosis in three cats (2001–2009). *Journal of the American Animal Hospital Association*, 48(4), 256–260. <https://doi.org/10.5326/jaaha-ms-5748>.
- Delaude, A., Rodriguez-Campos, S., Dreyfus, A., Counotte, M. J., Francey, T., Schweighauser, A., et al. (2017). Canine leptospirosis in Switzerland-A prospective cross-sectional study examining seroprevalence, risk factors and urinary shedding of pathogenic leptospires. *Preventive Veterinary Medicine*, 141, 48–60. <https://doi.org/10.1016/j.prevetmed.2017.04.008>.
- Hartmann, K., Egberink, H., Pennisi, M. G., Lloret, A., Addie, D., Belák, S., et al. (2013). *Leptospira* species infection in cats: ABCD guidelines on prevention and management. *Journal of Feline Medicine and Surgery*, 15, 576–581. <https://doi.org/10.1177/1098612X13489217>.
- Luciani, O. (2004). *Réceptivité et sensibilité du chat aux leptospires*. Nantes (France): National Veterinary School of Nantes.
- Major, A., Schweighauser, A., & Francey, T. (2014). Increasing incidence of canine leptospirosis in Switzerland. *International Journal of Environmental Research and Public Health*, 11(7), 7242–7260. <https://doi.org/10.3390/ijerph110707242>.
- Marreros, N., Zurcher-Giovannini, S., Oraggi, F. C., Djelouadji, Z., Wimmershoff, J., Pewsner, M., et al. (2018). Fatal leptospirosis in free-ranging Eurasian beavers (*Castor fiber* L.), Switzerland. *Transboundary and Emerging Diseases*, 65(5), 1297–1306. <https://doi.org/10.1111/tbed.12879>.
- Mylonakis, M. E., Bourti-Hatzopoulou, E., Koutinas, A. F., Petridou, E., Saridomichelakis, M. N., Leontides, L., et al. (2005). Leptospiral seroepidemiology in a feline hospital population in Greece. *Veterinary Record*, 156(19), 615–616 doi:156/19/615 [pii].
- Pratt, N., Conan, A., & Rajeev, S. (2017). *Leptospira* seroprevalence in domestic dogs and cats on the Caribbean Island of Saint Kitts. *Veterinary Medicine International*, 2017, 5904757. <https://doi.org/10.1155/2017/5904757>.
- Rodriguez, J., Lapointe, C., Arsenaud, J., Carioto, L., & Harel, J. (2014). Serologic and Urinary PCR Survey of Leptospirosis in Healthy Cats and in Cats with Kidney Disease. *Journal of Veterinary Internal Medicine*, 28(2), 284–293.
- Schnydrig, P., Vidal, S., Brodard, I., Frey, C., Posthaus, H., Perreten, V., et al. (2017). Bacterial, fungal, parasitological and pathological analyses of abortions in small ruminants from 2012–2016. *Schweizer Archiv für Tierheilkunde*, 159(12), 647–656. <https://doi.org/10.17236/sat00136>.
- Schreiber, P. W., Aceto, L., Korach, R., Marreros, N., Ryser-Degiorgis, M. P., & Gunthard, H. F. (2015). Cluster of Leptospirosis acquired through river surfing in Switzerland. *Open Forum Infectious Diseases*, 2(3), 1–7. <https://doi.org/10.1093/ofid/ofv102>.
- Shropshire, S. B., Veir, J. K., Morris, A. K., & Lappin, M. R. (2016). Evaluation of the *Leptospira* species microscopic agglutination test in experimentally vaccinated cats and *Leptospira* species seropositivity in aged azotemic client-owned cats. *Journal of Feline Medicine and Surgery*, 18(10), 768–772. <https://doi.org/10.1177/1098612X15593902>.
- Vidal, S., Syring, C., & Rodriguez-Campos, S. (2015). Implications of *Leptospira* spp. in bovine abortion. 2nd ELS (European Leptospirosis Society) meeting.
- Weis, S., Rettinger, A., Bergmann, M., Llewellyn, J. R., Pantchev, N., Straubinger, R. K., et al. (2016). Detection of *Leptospira* DNA in urine and presence of specific antibodies in outdoor cats in Germany. *Journal of Feline Medicine and Surgery*. <https://doi.org/10.1177/1098612X16634389>.