



# Surgical Treatment of Periimplantitis With Augmentative Techniques

Ausra Ramanauskaite, DDS,\* Karina Obreja, DDS, Dr. med.dent.,† Robert Sader, Prof., Dr.med.dent.mult,‡ Fouad Khoury, DDS; Dr. med. dent, PhD,§ Georgios Romanos, DDS, Dr. med.dent., PhD,¶ Ki Tae Koo, DDS, MS, PhD,# Philip Leander Keeve, DMD, Dr. med.dent,\*\* Anton Sculean, DMD, Dr. med. dent, MS, PhD,†† and Frank Schwarz, Prof., Dr. med. dent.‡‡

The diagnosis of periimplantitis describes a pathological condition occurring in tissues around dental implants, characterized by inflammation in the periimplant connective tissue and the progressive loss of supportive bone.<sup>1</sup> As substantial evidence supports the bacterial etiology of periimplantitis,<sup>2</sup> the treatment of the disease should include anti-infective measures.

Based on the current evidence, non-surgical treatments, including mechanical debridement with or without adjunctive (ie, local antibiotics, antimicrobial photodynamic therapy) or alternative measures (eg, air abrasive devices, Er:YAG laser monotherapy), have demonstrated

**Objectives:** To address the focused question: “In patients with osseointegrated implants diagnosed with periimplantitis, what are the clinical and radiographic outcomes of augmentative surgical interventions compared with nonaugmentative surgical measures”?

**Material and Methods:** Literature screening was performed in MEDLINE through the PubMed database, for articles published until January 1, 2018. Human studies reporting on the clinical (ie, bleeding on probing [BOP] and probing depth [PD] changes) and/or radiographic (ie, periimplant defect reduction and/or fill) treatment outcomes after surgical augmentative periimplantitis therapy, and/or comparing augmentative and nonaugmentative surgical approaches were searched.

**Results:** Thirteen comparative and 11 observational clinical studies

were included. Surgical augmentative periimplantitis therapy resulted in mean BOP and PD reduction ranging from 26% to 91%, and 0.74 to 5.4 mm, respectively. The reported mean radiographic fill of intrabony defects ranged between 57% and 93.3%, and defect vertical reduction varied from 0.2 to 3.77 mm. Three randomized controlled clinical studies failed to demonstrate the superiority of augmentative therapy compared with nonaugmentative approach in terms of PD and BOP reduction.

**Conclusions:** The available evidence to support superiority of augmentative surgical techniques for periimplantitis management on the treatment outcomes over nonaugmentative methods is limited. (*Implant Dent* 2019;28:187–209)

**Key Words:** periimplant disease, regeneration, management, augmentation

\*Research Associate, Department of Oral Surgery and Implantology, Carolinum, Goethe University, Frankfurt, Germany; Department of Oral Surgery, Universitätsklinikum Düsseldorf, Düsseldorf, Germany.  
†Oral Surgeon, Department of Oral Surgery and Implantology, Carolinum, Johann Wolfgang Goethe-University Frankfurt, Frankfurt, Germany.  
‡Professor, Department for Oral, Cranio-Maxillofacial and Facial Plastic Surgery, Medical Center of the Goethe University Frankfurt, Frankfurt am Main, Germany.  
§Director, Private Dental Clinic Schloss Schellenstein, Olsberg, Germany; Professor, Department of Oral and Maxillofacial Surgery, University of Muenster, Germany.  
¶Professor, Department of Periodontology, School of Dental Medicine, Stony Brook University, Stony Brook, NY.  
#Professor, Department of Periodontology, Dental Research Institute, School of Dentistry, Seoul, Republic of Korea.  
\*\*Head, Department of Periodontology, Private Dental Clinic Schloss Schellenstein, Olsberg, Germany.  
††Professor, Chairman, Department of Periodontology, School of Dental Medicine, University of Bern, Bern, Switzerland.  
‡‡Professor, Chairman, Department of Oral Surgery and Implantology, Carolinum, Johann Wolfgang Goethe-University Frankfurt, Frankfurt, Germany.

Reprint requests and correspondence to: Ausra Ramanauskaite, DDS, Department of Oral Surgery and Implantology, Carolinum, Goethe University, Theodor-Stern-Kai 7, 60596 Frankfurt am Main, Germany, Phone:+49 69 6301 7924, Fax: +49 69 6301 3829, E-mail: Ramanauskaite@med.uni-frankfurt.de

ISSN 1056-6163/19/02802-187  
Implant Dentistry  
Volume 28 • Number 2  
Copyright © 2019 Wolters Kluwer Health, Inc. All rights reserved.

DOI: 10.1097/ID.0000000000000839

limited efficacy for the management of periimplantitis and were particularly compromised at advanced defect sites.<sup>3,4</sup> These findings may be mainly attributed to the limited access of nonsurgical measures to advanced pockets and the inability to completely remove bacterial deposits from structured implant surfaces.

In contrast, surgical interventions have been shown to improve the efficacy of periimplantitis treatment.<sup>4</sup> They provide better access to the periimplant

defect, which, in turn, allows for a more effective implant surface decontamination.<sup>4</sup> Although nonaugmentative surgical treatment approaches including open-flap debridement (OFD) alone or with adjunctive resective therapy (eg, pocket elimination, bone recontouring, and implantoplasty) primarily aims at resolving inflammation and arresting the further progression of the disease, augmentative treatments additionally seek to reconstruct the osseous defect compartment.<sup>5</sup>

Numerous augmentation protocols using various methods for surface decontamination, along with autogenous bone and various bone replacement materials with or without barrier membranes, have been proposed for the management of periimplantitis. Until now, it remains difficult to draw conclusions concerning which augmentative protocol is superior as well as to evaluate its clinical efficacy over nonaugmentative treatments.<sup>6,7</sup>

Therefore, the aim of the present review is to evaluate the existing evidence regarding the effectiveness of surgical augmentative therapy for periimplantitis management and to compare it with nonaugmentative therapy alone.

## MATERIALS AND METHODS

The reporting of this systematic analysis adhered to the Preferred Reporting Items for Systematic Review and Meta-Analyses (PRISMA) statement.<sup>8</sup>

### Focus Questions

The following questions were developed according to the population, intervention, comparison, and outcome (PICO) study design:

“In patients with osseointegrated implants diagnosed with periimplantitis, what are the clinical and radiographic outcomes of augmentative surgical interventions compared with nonaugmentative surgical measures?”

**Population:** Patients diagnosed with periimplantitis based on case definitions used in respective publications;

**Intervention:** Surgical augmentative periimplantitis measures;

**Comparison:** Surgical nonaugmentative measures.

**Outcomes:** *primary:* changes in clinical parameters (ie, bleeding on probing [BOP %] and periimplant probing depth [PD {mm}]); *secondary:* radiographic defect fill [%] and/or defect reduction (mm).

### Search Strategy

A literature search was performed in MEDLINE through the PubMed database of the US National Library of Medicine, for articles published until January 1, 2018. The combination of

Medical Subject Heading search terms (ie, MeSH) and free-text terms included:

“peri-implant disease” OR  
“periimplant disease” OR  
“peri-implant infection” OR  
“periimplant infection” OR  
“peri-implantitis” OR “Peri-implantitis (MeSH)”

AND

“treatment” OR “surgical treatment” OR “regenerative treatment” OR “augmentative treatment” OR “augmentative therapy” OR “surgical therapy” OR “regenerative therapy” OR “reconstructive treatment” OR “reconstructive therapy” OR “augmentative therapy” OR “augmentative treatment”.

### Selection of Studies

Two independent reviewers (A.R. and K.O.) conducted the literature search. Disagreements regarding inclusion during the first and second stages of the study selection were resolved by discussion.

During the first stage of study selection, the titles and abstracts were screened and evaluated according to the following inclusion criteria:

1. Prospective, randomized, controlled clinical trials (RCTs), case-control studies, prospective cohort studies, cross-sectional studies, and case series in humans reporting changes in clinical parameters (ie, BOP and PD), and/or presenting radiographic data (defect reduction [mm] and/or defect fill) after surgical augmentative treatment and/or comparing augmentative and nonaugmentative surgical approaches with a follow-up of at least 3 months;
2. Studies that include patients with at least one osseointegrated implant affected by periimplantitis;
3. Studies describing the definition of periimplantitis;
4. Studies presenting a surgical augmentative intervention aimed at the treatment of periimplantitis;
5. Publications in English language in an international, peer-reviewed journal.

At the second stage of selection, all full-text articles identified during the first stage were acquired and evaluated according to the following exclusion criteria:

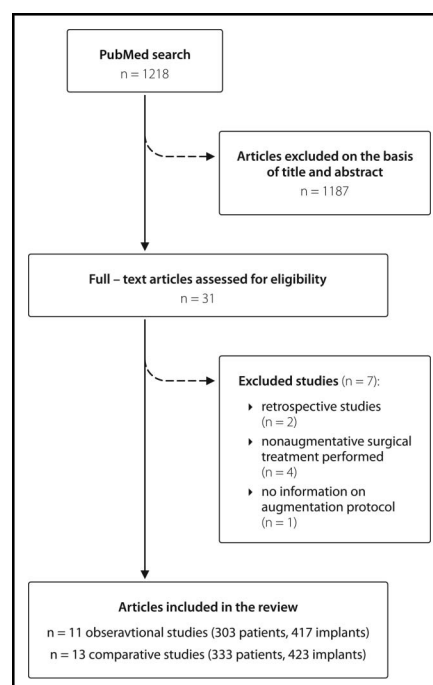


Fig. 1. The flowchart presenting literature search.

**Table 1.** Study and Patient Characteristics: Comparative Studies

Author	Study Design	Case Definition (Defect Type)	Follow-up Period	No. of Patients/ Implants
1. Khoury and Buchmann 2001 <sup>34</sup>	Controlled clinical study	Bone loss >50% of implant length + intrabony crater-form defect	3 y	25/41 Test 1: 20 implants Test 2: 9 implants Control: 12 implants
2. Deppe et al, <sup>39</sup> 2007	Controlled clinical study	PD ≥5 mm + BOP + progressive vertical bone loss	5 y	16/32 Test: 9/17 Control: 7/15
3. Schwarz et al, <sup>23,41,42</sup> 2006, 2008, 2009	RCT	PD >6 mm, BOP/pus + intrabony component >3 mm	4 y	20/21 Test: 9/9 Control: 10/11
4. Schwarz et al, <sup>26</sup> 2010	Controlled clinical study	PD >6 mm + BOP/pus + intrabony defect component >3 mm + supracrestal component ≤1 mm	12 mo	27/27 Test Ib: 9/9 Ic: 9/9 Control: 9/9
5. Aghazadeh et al, <sup>22</sup> 2012	RCT	PD ≥5 mm + BOP/Pus + radiographic bone loss ≥2 mm + angular periimplant bone defect ≥3 mm	12 mo	45/71 Test: 23/37 Control: 22/34
6. Wohlfahrt et al, <sup>18</sup> 2012	RCT	PD ≥5 mm + BOP + 1-, 2-, 3-wall intrabony defects ≥4 mm depth	12 mo	32/32 Test: 16/16 Control: 16/16
7. Andersen et al, <sup>19</sup> 2017	RCT (Wohlfahrt et al Continuum)		7 y	12/12 Test: 6/6 Control: 6/6
8. Roos-Jansaker et al, <sup>32,33,43</sup> 2007, 2011, 2014	Controlled clinical study	Bone loss >3 threads (≥1.8 mm) 1–4 intrabony defect + BOP and/or pus	5 y	25/45 Test: 13/23 Control: 12/22
9. Jepsen et al, <sup>20</sup> 2016	RCT	PD ≥5 mm + BOP/pus + intraosseous circumferential 3-wall defects ≥3 mm depth, defect angle ≤35°	12 mo	63/63 Test: 33/33 Control: 30/30
10. Guler et al, <sup>25</sup> 2016	Controlled clinical study	PD >5 mm + BOP/pus  Class Ib defects (vestibular dehiscence + circumferential bone resorption) Class Ic defects (vestibular dehiscence + circumferential bone resorption) Class Id defects (circumferential bone resorption)	6 mo	24/35 Test: 18/19 Control: 6/16
11. Isehede et al, <sup>37</sup> 2016	RCT	PD ≥ 5 mm + BOP/pus + angular bone loss ≥ 3 mm	12 mo	29/29 Test: 15/15 Control: 14/14

(continued on next page)

Table 1. (Continued)

Author	Study Design	Case Definition (Defect Type)	Follow-up Period	No. of Patients/ Implants
12. Schwarz et al, <sup>21,44-46</sup> 2011, 2012, 2013, 2017	RCT	PD $\geq$ 6 mm + BOP/pus intrabony component > 3 mm + supracrestal component >1 mm	7 y	15/15 Test: 6/6 Control: 9/9
13. Rocuzzo et al, <sup>38,47</sup> 2011, 2017	Controlled clinical study	PD $\geq$ 6 mm + crater-like intrabony defects	7 y	26/26 Test: 12/12 Control: 14/14

Author	Implant Type	Age Mean $\pm$ SD, (Range), y	Sex, Female/Male	Patient Smoking Status
1. Khoury and Buchmann 2001 <sup>34</sup>	IMZ and F2 implants (Friadent GmbH, Mannheim, Germany)	48.2 $\pm$ 6.3	22/3	No information
2. Deppe et al, <sup>39</sup> 2007	IMZ; Frialit-2, Brånemark implants, Nobel Biocare, Straumann	No information	No information	No information
3. Schwarz et al, <sup>23,41,42</sup> 2006, 2008, 2009	Brånemark, Camlog, ITI (TPS and SLA), MTX, TSV, ZL	54.4 $\pm$ 12.5 y	14/8	1 patient light smoker (<10 cig./d)
4. Schwarz et al, <sup>26</sup> 2010	Brånemark, Camlog, ITI, TSV (Tapered Screw Vent)	48.5 $\pm$ 14.6	No information	Included nonsmokers and light smokers (<10 cig./d)
5. Aghazadeh et al, <sup>22</sup> 2012	Implamed, Nobel Biocare, Straumann, TIUnite, nonidentified.	Test: 67.0 $\pm$ 7.5 Control: 70.1 $\pm$ 6.2	27/18	Smokers: Test: 69.6% Control: 40.9%
6. Wohlfahrt et al, <sup>18</sup> 2012	Astra Tech, Nobel Biocare (Nobel Mark III, Nobel Replace), Straumann, Frialit (Dentsply Friadent)	Test: 65.0 $\pm$ 10.0 Control: 57.2 $\pm$ 12.3	13/19	Smokers: Test: 6 (37.5%) Control: 10 (58.8%)
7. Andersen et al, <sup>19</sup> 2017		Test: 67 $\pm$ 12.9 Control: 67.2 $\pm$ 11.8	5/7	Smokers or former smokers: 10/12 patients (83%)
8. Roos-Jansaker et al, <sup>32,33,43</sup> 2007, 2011, 2014	Brånemark implants	Test: 64.9 $\pm$ 7.5 Control: 65.7 $\pm$ 7.4	14/11	Current smokers: Test: 10 (76.9%) Control: 8 (66.7%) Former smokers: Test: 2 (15.4%) Control: 3 (25%) Never smoked: Test: 1 (7.7%) Control: 1 (8.3%)

(continued on next page)

**Table 1.** (Continued)

Author	Implant Type	Age Mean $\pm$ SD, (Range), y	Sex, Female/Male	Patient Smoking Status
9. Jepsen et al, <sup>20</sup> 2016	Ankylos, Astra, Dyna, Friadent Xive, Nobel Biocare, SIC Invent, Straumann, Tri-Max, TMI; Zimmer, Biomet 3i	Test: 57.5 $\pm$ 12.6 Control: 59.1 $\pm$ 12.2	27/36	Current smokers: Test: 11 (33.3%) Control: 7 (23.3%) Former smokers: Test: 9 (27.3%) Control: 11 (36.7%) Nonsmokers: Test: 13 (39.4%) Control: 12 (40.0%)
10. Guler et al, <sup>25</sup> 2016	Zimmer, Adin Global, MIS-Implants, ITI, Ankylos, Dentsply Friadent, Xive (Dentsply), nonidentified	45.36 $\pm$ 14.1	9/15	Light smokers included (<10 cig.7 d): Test: 3 (18.75%) Control: 3 (50%)
11. Isehed et al, <sup>37</sup> 2016	Nobel turned, Nobel TiUnite, Astra, Straumann SLA, 3i	Test: median 70.0 (61–81) Control: median 73.5 (67–83) Median: 63	Test: 9/6 Control: 9/5	Current smokers: Test: 4 (26.7%) Control: 6 (42.9%)
12. Schwarz et al, <sup>21,44–46</sup> 2011, 2012, 2013, 2017	Astra Tech, Brånemark, Nobel Biocare, Camlog, ITI, KSI Bauer Schraube, REP Nobel Replace, Tapered Screw Vent, Zimmer, Dentsply Friadent, nonidentified	Median: 63	11/4	No information
13. Rocuzzo et al, <sup>38,47</sup> 2011, 2017	SLA and TPS Straumann	60 $\pm$ 7.9	14/10	4 smokers (33%)

SLA, sandblasted and acid-etched; TPS, titanium plasma-sprayed.

**Table 2.** Study and Patient Characteristics: Observational Studies

Author	Study Design	Case Definition (Defect Type)	Follow-up Period	No. of Patients/ Implants
1. Behneke et al, <sup>35</sup> 2000	Prospective study	PD >5 mm + progressive crater-like or saucer shape periimplant bone defect	6 mo–3 y	17/25
2. Haas et al, <sup>36</sup> 2000	Observational study	Signs of inflammation (redness, swelling, secretion) + BOP + PD >6 mm + progressive bone loss. Narrow vertical bone defects were included	9.5 mo	17/24
3. Roos-Jansaker et al, <sup>32</sup> 2007	Case series	Progressive bone loss of 3 threads (1.8 mm) or more after the first year of healing + BOP/pus	12 mo	12/16
4. Romanos et al, <sup>29</sup> 2008	Case series	Deep periimplant intrabony defects followed by bleeding and periimplant pockets	27.10 (17.83) mo	15/19
5. Wiltfang et al, <sup>40</sup> 2010	Prospective case series	Vertical bone loss $\geq$ 4 mm + circumferential crater defect with loss of oral and vestibular bone	12 mo	22/36
6. Froum et al, <sup>17</sup> 2012	Case series	PD $\geq$ 5 mm + BOP + bone loss $\geq$ 3 mm	2–10 y	100/170
7. Matarasso et al, <sup>30</sup> 2013	Prospective case series	PD $\geq$ 5 mm + BOP + $\geq$ 2 mm of marginal bone loss or exposure of $\geq$ 1 implant thread	12 mo	11/11
8. Schwarz et al, <sup>28</sup> 2014	Case series	PD >6 mm + intrabony component > 3 mm + radiographic supracrestal defect $\geq$ 1 mm Combined effects: Class Ib (ie, buccal dehiscence + semicircular bone resorption to the middle of the implant body) Class Ic (ie, circular bone resorption under maintenance of the buccal and oral compacta)	6 mo	10/13
9. Rocuzzo et al, <sup>31</sup> 2016	Prospective case series	Crater-like lesion + PD > 6 mm	12 mo	75/75
10. Rotenberg et al, <sup>24</sup> 2016	Retrospective case series	PD $\geq$ 5 mm + BOP/pus + radiographic bone loss	12 mo	11/11
11. Nart et al, <sup>27</sup> 2017	Case series	PD > 5 mm + BOP/Pus + 2-wall or 3-wall intrabony defects $\geq$ 3 mm depth identified on intraoral radiographs	12 mo	13/17

Author	Implant Type	Age, Mean $\pm$ SD, (Range), y	Sex, Female/Male	Patient Smoking Status
1. Behneke et al, <sup>35</sup> 2000	ITI screw implants	51.7	11/6	No information
2. Haas et al, <sup>36</sup> 2000	IMZ implants (Friadent, Mannheim, Germany)	No information	13/4	No information
3. Roos-Jansaker et al, <sup>32</sup> 2007	Brånemark implants	64.4 $\pm$ 6.0, (56–75)	9/3	Current smokers: 8 (66.7%) Former smokers: 2 (16.7%) Never smoked: 2 (16.7%)
4. Romanos et al, <sup>29</sup> 2008	Ankylos, ITI, IMZ implants	57.21 $\pm$ 12.14	10/5	No information
5. Wiltfang et al, <sup>40</sup> 2010	Implant type not indicated	Range (24–83)	12/10	No information
6. Froum et al, <sup>17</sup> 2012	Implant type not indicated	58.08, (20–83)	53/47	19 implants placed in smoking patients, 151—nonsmokers
7. Matarasso et al, <sup>30</sup> 2013	Tissue-level sandblasted, acid-etched surface implants (Straumann)	63.6 $\pm$ 8.9	5/6	5 smokers (45%)/6 nonsmokers (55%)

(continued on next page)

Table 2. (Continued)

Author	Implant Type	Age, Mean $\pm$ SD, (Range), y	Sex, Female/Male	Patient Smoking Status
8. Schwarz et al. <sup>28</sup> 2014	Brånemark, Camlog, ITI, Nobel Biocare, TSV (Tapered Screw Vent), Zimmer and nonidentified implants	55.8 $\pm$ 16.6	5/5	Only nonsmokers or light smokers (<10 cig./d) included
9. Rocuzzo et al. <sup>31</sup> 2016	Sandblasted, acid-etched surface implants (Straumann)	57.8 $\pm$ 8.5	36/39	11 smokers (15%)
10. Rotenberg et al. <sup>24</sup> 2016	Sandblasted, acid-etched surface implants (Straumann)	61 $\pm$ 5.8, (51–70)	5/6	Included only nonsmokers
11. Nart et al. <sup>27</sup> 2017	TiUnite (Nobel Biocare), Shot blasting (Klockner), Biomimetics (Avinent), and Laser-lok (Biohorizons).	57.76 $\pm$ 6.21, (51–67)	8/5	5 patients (38.5%) light smokers (<10 cig./d)

1. Review papers, case reports, letters, editorials, and abstracts on *in vitro* and animal studies;
2. Studies not providing data on clinical and/or radiographic data or treatment protocols;
3. Studies not providing a definition of periimplantitis;
4. Studies published not in international peer-reviewed journal.

The initial electronic search resulted in the identification of 1218 titles (Fig. 1). At the first stage, 1187 publications were excluded based on the title and abstract. At the second stage, the remaining 31 full-text articles were evaluated. The reasons for excluding studies after full-text assessment were as follows: retrospective studies,<sup>8,9</sup> nonaugmentative surgical treatment was performed (n = 4),<sup>10–13</sup> and information on the augmentation protocol was lacking (n = 1).<sup>14</sup> Finally, 24 studies were identified for inclusion in the review.

#### Data Collection

Data extraction templates were used to retrieve general information on the study design, periimplantitis case definitions, follow-up periods, number of implants and patients, implant type, patient sex, age, and smoking status (Tables 1 and 2). The treatment methods applied in the test and control groups, the mode of healing (ie, submerged or nonsubmerged), information on the use of systemic antibiotics, and clinical and/or radiographic treatment outcomes are presented in Tables 3 and 4. The mean values and SDs of BOP, PD values, radiographic bone defect fill, or defect reduction after the respective treatment were extracted for the data analysis.

Information on further disease progression/treatment complications and treatment success based on the criteria that the authors used is presented in Tables 3–5.

#### Quality Assessment

The Cochrane Collaboration's tool for assessing risk of bias was used in the case of controlled clinical trials.<sup>15</sup> Methodological quality assessment of the observational studies was based on

the Newcastle-Ottawa Quality Assessment Scale for Cohort studies<sup>16</sup> (Table 6 and 7).

#### Data Synthesis

Due to the heterogeneity among the studies regarding study designs, treatment protocols applied, and outcome variables, no quantitative analysis was performed.

## RESULTS

Presented in Tables 1–4 are 13 comparative and 11 observational clinical studies that reported on the surgical treatment of periimplantitis by using augmentative therapies. The follow-up time ranged from 6 months to 7 years for comparative studies and from 6 months to up to 2 to 10<sup>17</sup> years for observational studies. Out of the 12 comparative clinical studies included, 7 appeared to be randomized controlled clinical trials.<sup>18–23</sup> All controlled clinical studies were judged to have high to unclear risk of bias (Table 6). The included observational studies scored between 5 and 7 stars (out of 9) based on the Newcastle-Ottawa Scale (Table 7).

#### Patient Characteristics

Five hundred and ninety patients were treated with the augmentative surgical approach. The mean age of the patients ranged from 45.36 to 70.1 years. Seventeen studies (10 controlled and 7 observational studies) reported on the smoking statuses of the patients. Particularly, although one observational study included only nonsmoking patients,<sup>24</sup> 5 investigations (3 controlled<sup>23,25,26</sup> and 2 observational<sup>27,28</sup>) involved both nonsmokers and light smokers (<10 cig./d). In the rest of the controlled and observational studies, the number of smokers ranged from 23.3% to 76.9%, and from 15% to 66.7%, respectively (Tables 1 and 2).

#### Implant Characteristics

In total, 840 implants of various surfaces (379 in controlled and 417 in observational studies) were included in the review. Although the majority of the implants had moderately rough surfaces (5 controlled<sup>18–20,22,25</sup> and 5 observational<sup>24,27,29–31</sup> studies), 2 studies were conducted with smooth-surface implants

**Table 3.** Treatment Protocols, Outcomes, and Complications: Comparative Studies

Author	Presurgical Therapy	Treatment				
		Decontamination of Implant Surface	Grafting Material	Membrane	Submerged/ Nonsubmerged Healing	Systemic Antibiotics
1. Khoury and Buchmann 2001	6 mo before surgery nonsurgical implant scaling + irrigation with chlorhexidine (0.2%)	Test 1: 0.2% chlorhexidine digluconate, citric acid (pH = 1) (1 min) and rinsed with H <sub>2</sub> O <sub>2</sub> and 0.9% saline Test 2: 0.2% chlorhexidine digluconate, citric acid (pH = 1) (1 min) and rinsed with H <sub>2</sub> O <sub>2</sub> and 0.9% saline Control: 0.2% chlorhexidine digluconate, citric acid (pH = 1) (1 min) and rinsed with H <sub>2</sub> O <sub>2</sub> and 0.9% saline	Autogenous bone	Nonresorbable membrane  Resorbable membrane  No membrane	Submerged	Antibiotics administered 4 wk before surgery (for 1 wk), and later starting 1 d and finishing 7 d after surgery according to the individual susceptibility test results
2. Deppe et al, 2007	Presurgical chlorhexidine application (0.3%) for 3 wk	Test: air polishing + CO <sub>2</sub> laser (cw mode, 2.5 W, 12 × 5 s) Control: air polishing	Beta tricalcium phosphate combined with autogenous bone chips harvested from the retromolar area (50:50)	Nonresorbable membrane	4 mo submerged	No
3. Schwarz et al, 2006, 2008, 2009	OHI + nonsurgical therapy	Test: mechanical debridement (plastic curettes) Control: mechanical debridement (plastic curettes)	Nanocrystalline hydroxyapatite paste Bovine-derived xenograft	No membrane Native collagen barrier membrane	Non-submerged	No
4. Schwarz et al, 2010	Nonsurgical therapy using Er:YAG laser 4 wk before surgery  Test: Class Ib°, Class Ic°° Control: Class Ie°°°	Mechanical debridement (carbon curettes) + decontamination with cotton pellets soaked in the sterile saline	Bovine-derived xenograft	Native collagen barrier membrane	Non-submerged	No
5. Aghazadeh et al, 2012	OHI	Test: mechanical debridement (titanium instruments) + decontamination using H <sub>2</sub> O <sub>2</sub> (1 min) Control: mechanical debridement (titanium instruments) + decontamination using H <sub>2</sub> O <sub>2</sub> (1 min)	Bovine-derived xenograft Autogenous bone chips harvested from the mandibular ramus region	Resorbable synthetic barrier membrane	Non-submerged	Postoperative antibiotics Azithromycin 2 × 250 mg 1 d, 1 × 250 mg 2–4 d

(continued on next page)



**Table 3.** (Continued)

Author	Presurgical Therapy	Treatment				
		Decontamination of Implant Surface	Grafting Material	Membrane	Submerged/ Nonsubmerged Healing	Systemic Antibiotics
6. Wohlfahrt et al, 2012	NR	Test: titanium curettes and 24% ethylenediaminetetraacetic acid gel (2 min)	Titanium granules	No membrane	6 mo submerged	Amoxicillin (500 mg 3 times/d) and metronidazole (400 mg 2 times/d) starting 3 d before surgery and continuing 7 d after the surgery
7. Andersen et al, 2017 (Continuum Wohlfahrt et al, 2012)	NR	Control: titanium curettes and 24% ethylenediaminetetraacetic acid gel (2 min)	Open-flap surgery			
		Test: titanium curettes and 24% ethylenediaminetetraacetic acid gel (2 min)	Titanium granules	No membrane		Amoxicillin (500 mg 3 times/d) and metronidazole (400 mg 2 times/d) starting 3 d before surgery and continuing 7 d after the surgery
8. Roos-Jansaker et al, 2007, 2011, 2014	NR	Control: titanium curettes and 24% ethylenediaminetetraacetic acid gel (EDTA) (2 min)	Open-flap surgery		6 mo submerged	
		Test: H <sub>2</sub> O <sub>2</sub> (3 min)	Algae-derived xenograft	Resorbable synthetic membrane	Non-submerged	Amoxicillin 375 mg x 3 per d + metronidazole 400 mg x 2 per d, 10 d after the surgery
9. Jepsen et al, 2016	1 mo before surgery OHI* + nonsurgical periodontal/periimplant cleaning	Control: H <sub>2</sub> O <sub>2</sub> (3 min)		No membrane		
		Test: rotary titanium brush and 3% H <sub>2</sub> O <sub>2</sub> (1 min) followed by rinsing with saline (60 s)	Titanium granules	No membrane	Non-submerged	Amoxicillin 500 mg 3 times/d + metronidazole 400 mg 2 times/d, 8 d, starting 1 d before surgery
		Control: rotary titanium brush and 3% H <sub>2</sub> O <sub>2</sub> (1 min) followed by rinsing with saline (60 s)	Open-flap surgery			

(continued on next page)

Table 3. (Continued)

Author	Presurgical Therapy	Treatment				Submerged/ Nonsubmerged Healing	Systemic Antibiotics
		Decontamination of Implant Surface	Grafting Material	Membrane			
10. Guler et al, 2016	OHI + mechanical nonsurgical cleaning	Test: rotating titanium brush	Titanium granules	PRF (platelet-rich fibrin membrane)	Non-submerged	Amoxicillin clavulanate 2 × 1000 mg/d, 7 d	
		Control: rotating titanium brush	Xenograft	Resorbable collagen membrane + PRF (platelet-rich fibrin membrane)			
11. Isehede et al, 2016	OHI	Test: mechanical ultrasonic and titanium hand instruments cotton gauze-soaked in sodium chloride	Emdogain (0.3 ml)	No membrane	Non-submerged	No	
		Control: mechanical ultrasonic and titanium hand instruments cotton gauze-soaked in sodium chloride	Open-flap surgery				
12. Schwarz et al, 2011, 2012, 2013, 2017	Initial nonsurgical therapy + OHI	Test: Er:YAG laser device (cone- shape glass fiber tip) at 11.4 J/ cm <sup>2</sup> implantoplasty at buccally and supracrestally exposed implant parts	Bovine-derived xenograft	Native collagen membrane	Non-submerged	No	
		Control: open-flap surgery + mechanical debridement (plastic curette) + decontamination (cotton pellets soaked in saline) implantoplasty at buccally and supracrestally exposed implant parts					
13. Rocuzzo et al, 2011, 2017	Professional implant cleaning + OHI	Test: SLA surface implants (plastic curettes) + decontamination (24% EDTA and 1% CHX gel)	Bovine-derived xenograft	No membrane	Non-submerged	1 g of amoxicillin + clavulanic acid 2 times/d, 6 d	
		Control: TPS surface implants (plastic curettes) + decontamination (24% EDTA and 1% CHX gel)					

(continued on next page)

**Table 3.** (Continued)

Author	Treatment Outcomes			
	PD Changes (mm) (SD); (Range)	BOP Changes (%) (SD); (Range)	Radiographic Outcomes	Further Disease Progression/Complications
1. Khoury and Buchmann 2001	Implant level Test 1: 5.4 (3.0)  Test 2: 2.6 (1.6) Control: 5.1 (2.7) Significant improvement compared to baseline in all groups ( $P > 0.001$ ). Significantly less improvement in test 2 group compared to test 1 and the control ( $P \leq 0.05$ )	NR	Radiographic vertical intrabony defect height reduction (mm): 2.8 (3.1) 1.9 (3.2) 2.4 (2.7) Significantly less improvement in test 2 group compared to baseline ( $P = 0.102$ ). No difference among the groups ( $P \leq 0.05$ ).	17 out of 29 barrier-treated implants (58.6%) were compromised by early posttherapy complication (eg, dehiscence, exposure, fistula, or sequester formation)
2. Deppe et al, 2007	Implant level Test: baseline: 5.0 (1.3), after 5 y: 2.5 (1.4).  Control: baseline: 4.8 (1.4), after 5 y: 2.5 (1.1). No significant difference between the groups	NR	Radiographic DIB (distance from the implant shoulder to the first bone contact): 4.5 (1.2) mm 4.7 (1.1) mm  No significant difference between the groups	Test group: 4 implants were lost due to a chronic inflammation  Control group: 4 implants were lost due to a severe infection developed within first weeks after surgery
3. Schwarz et al, 2006, 2008, 2009	Subject level Test: 1.1 (0.3) Control: 2.5 (0.9) Significantly higher at control sites	32 51 Significantly higher at control sites	NR	After 12 mo, 2 patients had to be discontinued due to severe pus formation.
4. Schwarz et al, 2010	Ib: 1.6 (0.9) Ic: 1.6 (0.7) Ie: 2.7 (16.7) Significant improvement compared to baseline ( $P < 0.001$ ) Ie group tended to reveal higher mean PD reduction	Ib: 38.9 (16.6) Ic: 25.9 (16.7) Ie: 61.1 (16.7) Significant improvement compared to baseline ( $P < 0.001$ ) Significantly higher BOP reduction in Ie group	NR	None
5. Aghazadeh et al, 2012	Implant level  Test: 3.1 (0.2) Control: 2.0 (0.2) Significantly higher in the test group ( $P < 0.01$ )	  50.4 (5.3) 44.8 (6.3) No significant difference between the groups	Mean radiographic bone defect fill (mm): 1.1 (0.3) 0.2 (0.3) Significantly higher in test group ( $P < 0.05$ )	None

(continued on next page)

Table 3. (Continued)

Author	Treatment Outcomes			
	PD Changes (mm) (SD); (Range)	BOP Changes (%) (SD); (Range)	Radiographic Outcomes	Further Disease Progression/ Complications
6. Wohlfahrt et al, 2012	Implant level Test: 1.7 (1.7); (-2.3, 4.3) Control: 2.0 (2.3); (-1.5, 6.5)	0.38 (2.1); (-2, 6) 0.56 (2.9); (-5, 6)	Radiographic defect height reduction (mm): 2.0 (1.7); (-0.9, 5.2) Mean radiographic intrabony defect fill (%): 57.0 (45.1); (-33.9, 167.6) Radiographic defect height reduction (mm): 0.1 (1.9); (-5.7, 5.2) Between-group comparison: Significantly higher in test group Mean radiographic intrabony defect fill (%): -14.8 (83.4); (-278.7, 84.6) significantly higher in test group.	Further progression of bone loss:  Test: 4 implants Control: 7 implants
7. Andersen et al, 2017 (Continuum Wohlfahrt et al, 2012)	Significant improvement compared to baseline ( $P < 0.001$ )  No significant difference between the groups ( $P = 0.66$ ) Test: baseline: 6.5 (1.9), after 7 y: 4.3 (2.4)	Not significant improvement compared to baseline  No significant difference between the groups ( $P = 0.60$ ) At least one BOP-positive site (out of 6): 5 implants	Mean radiographic osseous defect fill (mm): 1.92 (2)	Implant loss: Test group: 3 implants (one implant due to the technical complications)
8. Roos-Jansaker et al, 2007, 2011, 2014	Control: baseline: 6.5 (2.3), after 7 y: 3.5 (1.2) Implant level PD reduction at the deepest site (mm) Test: 3.0 (2.4) Control: 3.3 (2.0) No significant difference between the groups ( $P = 0.60$ )	5 implants  NR	1.3 (1.4)  Radiographic defect fill (mm): 1.5 (1.2) 1.1 (1.2)  No significant difference between the groups ( $P = 0.249$ )	Progressive periimplantitis (bone loss $\geq 1.0$ mm + BOP) in 5 y period detected in 2.2% of implants

(continued on next page)

**Table 3.** (Continued)

Author	Treatment Outcomes			Further Disease Progression/ Complications
	PD Changes (mm) (SD); (Range)	BOP Changes (%) (SD); (Range)	Radiographic Outcomes	
9. Jepsen et al, 2016	Implant level			None
	Test: 2.8 (1.3)	56.1 (30.5)	Radiographic defect height reduction (mm): Mesial/distal: 3.61 (1.96)/3.56 (2.07) Mean radiographic intrabony defect fill (%): Mesial/distal: 79.00 (29.85)/74.22 (36.33)	
	Control: 2.6 (1.4)	44.9 (38.2)	Radiographic defect height reduction (mm): Mesial/distal: 1.05 (1.42)/1.04 (1.34) Significantly higher in test group Mean radiographic intrabony defect fill (%):mesial/distal: 23.11 (46.28)/21.89 (30.16)	
	Significant reduction compared to baseline (P < 0.001) No significant difference between groups	Significant reduction compared to baseline (P < 0.001) No significant difference between groups	Significantly higher in test group.	
10. Guler et al, 2016	Implant level			In control group, collagen membrane was exposed in 2 patients
	Test: baseline: 5.28 (1.06), after 6 mo: 3.34 (0.82)	Baseline: 50.17 (25.19)%, after 6 mo: 24.32 (11.22) %	Mean radiographic bone defect fill (mm): 1.74 (0.65)	
	Control: baseline: 4.72 (1.02), after 6 mo: 3.18 (0.54)	Baseline: 63.51 (24.38)%, after 6 mo: 33.00 (15.51)%	1.05 (0.54)	
11. Isehed et al, 2016	Test: 2.8 Control: 3.00	BOP decreased from approximately 90% to 30%, but relapsed to nearly 70% at 12-mo.	Marginal bone level changes (mm): Test: increased: 0.9 Control: decreased: 0.1	Two patients were treated with systemic antibiotics at 3-mo follow-up due to severe infection. One implant disintegrated in the control group.
	Did not differ from baseline to 12 mo between the groups.	Did not differ from baseline to 12 mo between the groups.		

*(continued on next page)*

Table 3. (Continued)

Author	Treatment Outcomes			Further Disease Progression/ Complications
	PD Changes (mm) (SD); (Range)	BOP Changes (%) (SD); (Range)	Radiographic Outcomes	
12. Schwarz et al, 2011, 2012, 2013, 2017	Subject level Test: 0.74 (1.89) Control: 2.55 (1.67) Significant improvement compared to baseline ( $P < 0.001$ )	86.66 (18.26) 89.99 (11.65) Significant improvement compared to baseline ( $P < 0.001$ )	NR	In a 7-y period, 2 patients in test groups and 2 in the control group had to be discontinued due to pus formation and progressive radiographic bone loss.
13. Rocuzzo et al, 2011, 2017	Subject level Baseline: 75.0 (31.2), after 7 y: 7.5 (12.1) Test: baseline: 6.6 (1.3), after 7 y: 3.2 (0.7) Control: baseline: 7.3 (1.5), after 7 y: 3.4 (0.6) Significantly higher reduction in test group ( $P = 0.01$ )	Baseline: 90.0 (12.9), after 7 y: 30.0 (19.7) Significant improvement compared to baseline ( $P < 0.001$ )	Mean bone level decrease: Baseline: 2.9 (0.9) mm, after 7 y: 0.8 (1.0) mm  Baseline: 3.7 (1.6) mm, after 7 y: 1.7 (0.9) mm	In 7 y, antibiotic and/or surgical therapy was necessary in 8 implants (2 in the test group and 6 in the control group)
	Significant improvement compared to baseline ( $P < 0.001$ )	Significant improvement compared to baseline ( $P < 0.001$ )	Significantly higher reduction in the control group.	

Class I<sup>b</sup>—buccal dehiscence + semicircular bone resorption to the middle of the implant body.  
Class Ic<sup>b</sup>—buccal dehiscence + circular bone resorption under maintenance of the lingual compacta.  
Class Ic<sup>oo</sup>—circular bone resorption under maintenance of the buccal and oral compacta.  
NR, not reported; OH, oral hygiene instruction; SLA, sandblasted and acid-etched; TPS, titanium plasma-sprayed.

(one observational<sup>32</sup> and one comparative study<sup>33</sup>), and 3 studies (one comparative<sup>34</sup> and 2 observational<sup>35,36</sup> studies) focused on rough-surface implants only. Seven investigations included both smooth, rough, and moderately rough,<sup>21,23,26,28,37</sup> or rough and moderately rough<sup>38,39</sup> implants. Two observational studies did not provide information on the surfaces of the implants.<sup>17,40</sup>

#### Case Definitions

Definitions of the periimplantitis cases selected for the augmentative treatment varied widely among the included studies (Tables 1–4). Except for the 2 studies, where periimplantitis diagnosis was based only on radiographical evaluation,<sup>34,40</sup> the rest of the investigations defined periimplantitis by the presence of BOP and/or PD  $>5$  mm, and radiographic bone loss. In addition, the majority of the cases presented intrabony periimplant defect configurations.<sup>18–23,25–29,31,33–40</sup>

#### Comparison of Augmentative and Nonaugmentative Approaches

Three RCTs assessed the clinical efficacy of augmentative therapy over the OFD approach alone.<sup>18–20</sup> Two studies included the same patient sample and reported the treatment outcomes at 12 months and 7 years of follow-up.<sup>18,19</sup> At 12 months after the treatment, two 1-year clinical investigations demonstrated a significantly higher percentage of radiographic fill of the intrabony defect treated with titanium granules when compared to nonaugmentative treatment.<sup>18,20</sup> However, the clinical treatment outcomes, in terms of PD and BOP reduction, did not differ between the 2 treatment approaches at both 12-month and 7-year follow-up.<sup>18–20</sup> In the 7-year investigation, due to the small number of the patients (6 test and 6 control), statistical analysis between the groups was not performed.<sup>19</sup> Nevertheless, the results indicated a minimal difference in osseous defect depth changes between the groups.<sup>19</sup>

#### Characteristics of Interventions

**Decontamination.** Methods to decontaminate the implant surface included mechanical,<sup>17,20,21,23–25,30,35,37,39</sup> chemical,<sup>17–19,22,31–34,38,40</sup> laser

**Table 4.** Treatment Protocols, Outcomes and Complications: Observational Studies

	Presurgical Therapy	Author Treatment				
		Decontamination of Implant Surface	Grafting Material	Membrane	Submerged/ Nonsubmerged Healing	Systemic Antibiotics
1. Behneke et al, 2000	1-mo before surgery local-disinfecting treatment using weekly submarginal irrigation with iodine solution	Air-powder abrasive with sodium carbonate (30 s) + rinse with sterile saline	Autogenous block-shape (18 implants) or particulate bone grafts (7 implants)	No membrane	Nonsubmerged	Metronidazole 400 × 2 for 7 d
2. Haas et al, 2000	NR	Toluidine blue O (1 min) and soft laser light (wave length 906 nm)	Particulate autogenous bone	Nonresorbable e-PTFE membrane	Submerged	Augmentin (5 d)
3. Roos-Jansaker et al, 2007	NR	H <sub>2</sub> O <sub>2</sub> (3%)	Nonbovine-derived bone substitute	Resorbable membrane	Submerged	Amoxicillin (375 mg x 3) + metronidazole (400 mg x 2) for 10 d, starting 1 d before surgery
4. Romanos et al, 2008	NR	CO <sub>2</sub> laser decontamination	Particulate autogenous bone (10 implants)/or bovine-derived xenograft (9 implants)	Resorbable collagen membrane	12 submerged, 7 nonsubmerged, 12 submerged	No
5. Wiltfang et al, 2010	Mechanical implant cleaning + periimplant pocket irrigation with chlorhexidine (0.12%) (3 times a week)	Etching gel (Gluma Etch 20 Gel)	Autogenous bone and demineralized xenograft (1:1) containing native bone morphogenetic protein (BMPs) and vascular endothelial growth factor	No membrane	Non-submerged	Prophylactic antibiotics (amoxicillin/sulbactam) were given perioperatively
6. Froum et al, 2012	1 mo before surgery full-mouth debridement + OHI	Pellets soaked in minocycline (50 mg/ml) and 0.12% chlorhexidine gluconate (CHX) (for 45–60 s) + air-powder abrasive + saline spray + application of EMD (Emdogain) or PDGF (platelet-derived growth factor)	Mineralized freeze-dried bone allograft	Resorbable membrane and/or subepithelial connective tissue graft	Non-submerged	No
7. Matarasso et al, 2013	OHI + motivation + nonsurgical mechanical cleaning and polishing 8–10 wk before the surgery	Implantoplasty at suprabony exposed implant parts + air-abrasive with glycine powder for intrabony defect (30 s) + rinsed with saline solution (30 s)	Deproteinized bovine bone mineral	Resorbable membrane	Non-submerged	Amoxicillin 875 mg + clavulanic acid 125 mg, 5 d.

(continued on next page)

Table 4. (Continued)

	Presurgical Therapy	Author Treatment				
		Decontamination of Implant Surface	Grafting Material	Membrane	Submerged/ Non-submerged Healing	Systemic Antibiotics
8. Schwarz et al, 2014	Nonsurgical therapy using Er:YAG laser 2 wk before surgery	Implantoplasty at buccally and supracrestally exposed implant parts + decontamination of unmodified surface with plastic curettes and cotton pellets soaked in saline	Bovine-derived xenograft	Native collagen membrane at intrabony components + connective tissue graft on the buccal aspect	Non-submerged	Amoxicillin 2 × 1000 mg/d (in case of allergy: Clindamycin 2 × 600 mg/d) 1 h before and 5 d postoperatively
9. Rocuzzo et al, 2016	OHI + scaling and root planning of teeth and cleaning of implant shoulders	Mechanical decontamination with titanium curettes and titanium brush in deep narrow pockets + EDTA 24% (2 min) + CHX gel (1%) (2 min)	Deproteinized bovine bone mineral with 10% collagen	+/- in case of no keratinized tissue, connective tissue graft from the tuberosity are	Non-submerged	1 g of amoxicillin + clavulanic acid x 2, starting 1 h before surgery, 6 d
10. Rotenberg et al, 2016	NR	Mechanical debridement with titanium-coated curettes and plastic-tipped ultrasonic instrument + CHX (0.12%) soaked gauze applied (2 min)	Collagen-coated bovine bone	No membrane	Non-submerged	Amoxicillin 500 mg x 3 or 300 mg clindamycin x 4
11. Nart et al, 2017	OHI + supragingival and subgingival mechanical debridement 6 wk before surgery	Mechanical debridement with stainless steel curette + implantoplasty supracrestally + intrabony defect debrided with ultrasonic device + 3% H <sub>2</sub> O <sub>2</sub> (1 min) + rinsed with saline	50% particulated mineralized cancellous allograft impregnated with trombomycine and 50% impregnated with vancomycin	Collagen membrane	Non-submerged	No
Treatment Outcomes						
	PD Changes (mm) (SD); (Range)	BOP Changes (%) (SD); (Range)	Radiographic Outcomes		Further Disease Progression/Complications	
1. Behneke et al, 2000	Implant level Median reduction: 3.3 mm after 3-y	NR	Radiographic mean bone defect fill (mm): 3.7  Median defect depth reduction (mm) at re-entry surgery: 6.9-0.7 Bone repair: 90%.		Treatment failure (explanation) in 6 patients	

(continued on next page)



Table 4. (Continued)

	Treatment Outcomes			
	PD Changes (mm) (SD); (Range)	BOP Changes (%) (SD); (Range)	Radiographic Outcomes	Further Disease Progression/ Complications
2. Haas et al, 2000	NR	NR	Radiographic mean defect fill (implant level):  2 (1.9) mm, (36.4%)	Exposure of the membrane occurred un all patients after a mean of 3 wk postoperative. 2 implants failed and had to be removed
3. Roos-Jansaker et al, 2007	Implant level 4.2 (1.5); (2–7)	NR	Radiographic mean bone defect fill (mm): 2.3 (1.2); (0.6–5.1)	2 wk after postoperative membrane exposure occurred in 31.3% of implant areas
4. Romanos et al, 2008	Implant level Baseline PD (mm): 6.00 (2.03), After treatment: 2.48 (0.63) Reduced significantly compared to baseline ( $P > 0.01$ )	Baseline bleeding index: 2.76 (0.35), after treatment: 1.03 (0.85) Reduced significantly compared to baseline ( $P > 0.01$ )	Complete radiographic bone fill found in all defects after the xenogenic bone graft, in sites treated with autogenous bone graft, at least 2/3 of the defect was filled.	None reported
5. Wiltfang et al, 2010	Implant level Reduction of PD (mm): 4 (95% CI: 3.3–4.6)	Baseline: 61%, after 12 mo: 25%	Radiographic mean bone defect fill (mm): 3.5 (95% CI: 2.7, 4.3)	1 implant (3%) was lost due to mobility
6. Froum et al, 2012	Implant level: 5.10 (2.20); 2–12	91.1%	Mean radiographic bone gain (mm): 1.77 (1.99)	2 implants were lost due to a disease progression 18 implants required 1 additional surgery and 10 implants required 2 additional surgeries to achieve the desired outcome
7. Matarasso et al, 2013	Implant level Baseline: 8.1 (1.8), after 12 mo: 4.0 (1.3).  Significant reduction compared to baseline ( $P = 0.032$ ).	Baseline: 19.7 (40.1), after 12 mo: 6.1 (24.0)  Significant reduction compared to baseline ( $P = 0.001$ ).	Radiographic marginal bone level changes (mm): Baseline: 8.0 (3.7), after 12 mo: 5.2 (3.0). Significant decrease ( $P < 0.001$ ). Radiographic mean bone defect fill: 93.3 (13.0) % Radiographic depth of intrabony defect (mm): Baseline: 3.5 (3.5), after 12 mo: 0.5 (13.0) Significant reduction ( $P < 0.001$ )	2 implants displayed early membrane exposure
8. Schwarz et al, 2014	Implant level	74.39 (28.52)	NR	None reported

(continued on next page)

Table 4. (Continued)

	Treatment Outcomes		Radiographic Outcomes	Further Disease Progression/ Complications
	PD Changes (mm) (SD); (Range)	BOP Changes (%) (SD); (Range)		
9. Rocuzzo et al, 2016	2.53 (1.80) Significant improvement compared to baseline ( $P =$ 0.001) Implant level 2.92 (1.73) Significant reduction compared to baseline ( $P < 0.0001$ ) Implant level	Significant improvement compared to baseline ( $P =$ 0.001) 53.2 (39.4)% Significant reduction compared to baseline ( $P < 0.0001$ ) 2 implants remained BOP positive (18%).	NR	12 mo after the treatment, 6 implants were removed due to a progression of periimplantitis
10. Rotenberg et al, 2016	3.3 (0.4) Significant compared to baseline ( $P < 0.002$ ) Implant level Initial deepest PD: $7.88 \pm 1.22$ After 12 mo: $4.23 \pm 1.62$ ( $P = 0.001$ ).	70.6% ( $P = 0.001$ ),	NR	None
11. Nart et al, 2017			Mean radiographic intrabony defect at baseline (mm): $4.33$ $\pm 1.62$ , after 12 mo: $0.56 \pm 0.88$ ( $P = 0.001$ ). Bone defect fill: $86.99 \pm 18.2\%$ .	None

NR, not reported; OH, oral hygiene instruction.

therapy,<sup>21,26,28,29,39</sup> or their combinations (Tables 3 and 4). In addition, one comparative and 3 observational studies, in adjunct to mechanical,<sup>21,27,28</sup> air-powder abrasive,<sup>30</sup> or laser (Er:YAG)<sup>21</sup> decontamination methods, involved the performance of implantoplasty to supra-crestally and buccally exposed implant parts.

#### Comparative studies

When considering the effectiveness of different implant surface decontamination protocols after augmentative periimplantitis surgery, Deppe et al<sup>39</sup> did not find a difference between the use of a carbon dioxide laser and air polishing on a long-term basis (5 years) in terms of the clinical attachment, PD, and radiographic marginal bone level changes. Moreover, clinical outcomes (eg, clinical attachment gain and BOP reduction) obtained by using laser decontamination (Er:YAG) were comparable with the conventional decontamination (plastic curettes + cotton pellets soaked in saline) approaches as demonstrated in the findings of the 7-year investigation.<sup>21</sup>

#### Augmentation protocols.

##### Bone substitutes alone

Four observational<sup>24,31,35,40</sup> and one controlled clinical study<sup>38</sup> reported on augmentative periimplantitis treatment using bone substitute materials without a barrier membrane. Besides, 3 comparative studies included control groups treated with bone filler alone.<sup>23,33,34</sup> A variety of bone replacement materials were applied (autogenous bone,<sup>34,35</sup> alloplastic bone filler,<sup>23</sup> and xenograft<sup>24,31,33,38</sup>). Moreover, in 4 controlled clinical studies, intrabony periimplant defects were filled using titanium granules.<sup>18–20,25</sup>

##### Guided bone regeneration

The guided bone regeneration concept including the application of a bone substitute material and a barrier membrane was performed in 7 observational<sup>17,27–30,32,36</sup> and 8 comparative studies.<sup>21–23,25,26,33,34,39</sup> Resorbable<sup>17,21–23,25–30,32–34</sup> and nonresorbable<sup>34,36,39</sup> membranes were used. In addition to the use of a collagen membrane, in one observational study, connective tissue graft was placed on

**Table 5.** Success of the Surgical Augmentative Treatment Indicated in the Studies

Author	Definition of Treatment Success	Treatment Success
Jepsen et al, <sup>20</sup> 2016	Complete disease resolution: PD ≤4 mm, no BOP at 6 implant sites and no further bone loss	30% (10/33) of implants
Schwarz et al, <sup>21</sup> 2017	Absence of BOP	Test: 4 out of 6 patients Control: 5 out of 9 patients Total: 9/15 patients (60%)
Rocuzzo et al, <sup>38</sup> 2017	PD < 5 mm, no BOP or pus, no further bone loss	Test: 7/12 (58.3%) implants Control: 2/14 (14.3%) implants Significantly higher success in the test group ( $P = 0.04$ )
Aghazadeh et al, <sup>22</sup> 2012	Successful treatment outcome PD ≤5 mm, allowing for one site with BOP, no pus, and gain or no loss of alveolar bone Successful treatment outcome defined by PD ≤ 5 mm, no BOP, no pus (at any implant surface), and gain or no loss of alveolar bone	Test: 38.5% implants Control: 13.9% implants  The likelihood of treatment success was higher in the test group (LR: 3.2, 95% CI: 1.0–10.6, $P < 0.05$ ) Test: 8 implants (20.5%) Control: 4 implants (11.1%)
Roos-Jansaker et al, <sup>33</sup> 2014	Successful treatment: radiographic evidence of ≥25% bone fill, but independent of PD or BOP radiographic evidence of ≥25% bone fill, PD ≤5 mm, but independent of bleeding score radiographic evidence of ≥25% bone fill, PD ≤5 mm, bleeding of probing score ≤1	66.7% (30/45) implants  62.2% (28/45) implants  51.1% (23/45) implants

the buccal aspect of the implant, which at the 6-month follow-up was associated with minimal mucosal height changes.<sup>28</sup>

**Addition of biologically active materials**  
Addition of biologically active materials were applied in 2 observational (enamel matrix derivative [EMD] or

platelet-derived growth factor,<sup>17</sup> and xenograft containing native bone morphogenetic protein and vascular endothelial growth factor<sup>40</sup>) and 2

**Table 6.** Assessment of the Risk of Bias for Included Controlled Clinical Studies

Author	Random Sequence Generation	Allocation Concealment	Blinding	Incomplete Outcome Data	Selective Reporting	Other Bias	Summary Assessment
Khoury and Buchmann, 2001 <sup>34</sup>	†	†	†	†	*	*	Unclear
Deppe et al, <sup>39</sup> 2007	†	†	†	*	†	*	Unclear
Schwarz et al, <sup>23,41,42</sup> 2006, 2008, 2009	*	†	*	‡	†	*	Unclear
Schwarz et al, <sup>26</sup> 2010	†	†	†	*	*	*	Unclear
Aghazadeh et al, <sup>22</sup> 2012	†	*	‡	*	*	*	Unclear
Wohlfahrt et al, <sup>18</sup> 2012	†	*	*	*	*	*	Unclear
Andersen et al, <sup>19</sup> 2017	†	*	*	‡	‡	‡	Unclear
Roos-Jansaker et al, <sup>32,33,43</sup> 2007, 2011, 2014	†	†	†	‡	†	*	Unclear
Jepsen et al, <sup>20</sup> 2016	*	*	*	‡	*	*	High risk
Guler et al, <sup>25</sup> 2016	†	†	‡	*	*	*	Unclear
Ished et al, <sup>37</sup> 2016	‡	*	*	*	*	*	High risk
Schwarz et al, <sup>44–46,21</sup> 2011, 2012, 2013, 2017	‡	†	†	†	†	*	Unclear
Rocuzzo et al, <sup>38,47</sup> 2011, 2017	†	†	‡	‡	†	*	Unclear

\*Low risk.  
†Unclear risk.  
‡High risk.

**Table 7.** Assessment of the Risk of Bias for Included Observational Studies

Author	Selection (Max 4*)			
	Representativeness of the Sample	Selection of Nonexposed Cohort	Ascertainment of Exposure	Demonstration of the Outcomes of Interest was Not Present at Start of the Study
1. Behneke et al, 2000			*	*
2. Haas et al, 2000			*	*
3. Roos-Jansaker et al, 2007			*	*
4. Romanos et al, 2008			*	*
5. Wiltfang et al, 2010			*	*
6. Froum et al, 2012			*	*
7. Matarasso et al, 2013			*	*
8. Schwarz et al, 2014			*	*
9. Rocuzzo et al, 2016			*	*
10. Rotenberg et al, 2016			*	*
11. Nart et al, 2017			*	*

Author	Comparability (max 2*) Comparability of Cohorts on the Basis of the Design or Analysis	Outcome (max 3*)			Total
		Ascertainment of Outcome	Was Follow-up Long Enough for Outcomes to Occur?	Adequacy of Follow-up of Cohorts	
1. Behneke et al, 2000		*	*	*	5*
2. Haas et al, 2000		*	*	*	5*
3. Roos-Jansaker et al, 2007	**	*	*	*	7*
4. Romanos et al, 2008	*	*	*	*	6*
5. Wiltfang et al, 2010	*	*	*	*	6*
6. Froum et al, 2012	**	*	*	*	7*
7. Matarasso et al, 2013	**	*	*	*	7*
8. Schwarz et al, 2014	**	*	*	*	7*
9. Rocuzzo et al, 2016	**	*	*	*	7*
10. Rotenberg et al, 2016	**	*	*	*	7*
11. Nart et al, 2017	**	*	*	*	7*

Newcastle-Ottawa Quality Assessment Scale (Max 9\*).

controlled clinical trials (platelet-rich fibrin [PRF] membranes<sup>25</sup> and EMD<sup>37</sup>). In addition, one observational study used allogenic bone substitutes impregnated in antibiotics.<sup>27</sup>

### Comparative studies

**Type of bone filler.** Surgical treatment outcomes using different bone filler materials were compared in the 3 clinical studies.<sup>22,23,25</sup> Accordingly, after 12 months of healing, significantly higher radiographic bone level gain and mean BOP and PD reduction were obtained with the use of xenograft in comparison to autogenous bone.<sup>22</sup> However, when interpreting these results it should be taken into consideration that xenogenic bone is more radiopaque than autogenous bone. Furthermore, improved clinical outcomes, in terms of BOP and PD reduction, were noted for slowly resorbing

bovine-derived minerals over hydroxyapatite particles.<sup>23</sup> Increased radiographic bone defect fill was detected in the sites treated with the porous titanium granules compared to xenograft, while the clinical outcomes (ie, PD reduction and clinical attachment changes [CAL]) did not differ between the groups.<sup>25</sup>

### Adjunctive use of barrier membrane.

Augmentative periimplantitis treatments with and without a barrier membrane were evaluated in 3 comparative studies.<sup>23,33,34</sup> The mean radiographic fill of an intrabony defect obtained by the use of autogenous bone and a nonresorbable membrane was indicated to be 2.8 mm, followed by the use of autogenous bone alone (2.4 mm), and amounted to 1.1 mm when autogenous bone particles were applied in conjunction

with a resorbable membrane.<sup>34</sup> The comparison among the 3 investigated groups did not reach a significant difference.<sup>34</sup> These findings corroborate the data presented in the 5-year investigation, where the additional use of a resorbable membrane did not improve the treatment outcome.<sup>33</sup> On the contrary, a 4-year clinical study revealed better clinical outcomes when a combination of bone-grafting material and a membrane were used in comparison to the use of grafting material alone.<sup>23</sup>

*Addition of biologically active materials.* The results of RCT, that attempted to evaluate the effect of EMD for the management of periimplantitis compared to OFD, showed that the use of EMD did not result in improved PD and BOP after 12 months, but was associated with increased marginal bone level

and increased prevalence of Gram +/aerobic bacteria.<sup>37</sup>

#### Healing Mode and Systemic Antibiotics

Submerged postoperative healing was performed in 4 controlled<sup>18,19,34,39</sup> and 2 observational studies.<sup>32,36</sup> One observational study included both healing modes.<sup>29</sup>

Systemic antibiotics were prescribed in 15 studies, except 5 controlled<sup>21,23,26,37,39</sup> and 3 observational studies.<sup>17,29,40</sup> Preoperative prophylactic antibiotics were used in one observational study.<sup>40</sup> None of the included studies compared neither the potential influence of modes of healing (ie, non-submerged vs submerged) nor the effect of additional systemic antibiotics after periimplantitis augmentative therapy.

#### Clinical and Radiographic Treatment Outcomes

Augmentative periimplantitis therapy was shown to result in significant improvements in BOP<sup>20–23,26–28,30,31,38</sup> and PD values<sup>18,20–31,33,34,38</sup> in comparison to the baseline. In particular, the mean BOP reduction ranged from 25.9%<sup>25</sup> to 89.99%<sup>21</sup> and 91%<sup>17</sup> in 1- to 7-year period, and the mean PD reduction ranged from 0.74<sup>21</sup> to 5.4 mm.<sup>34</sup>

The reported mean radiographic fill of the intrabony defect ranged between 57%<sup>18</sup> and 93.3%.<sup>30</sup> In addition, the radiographic reduction of the intrabony defect height varied from 0.2<sup>22</sup> and 2.8 mm,<sup>34</sup> up to 3.70<sup>35</sup> and 3.77 mm.<sup>27</sup>

#### Success of Augmentative Therapy

Composite outcomes for the treatment success were indicated in 5 of the studies (Table 5). Depending on the criteria that was applied, treatment success ranged between 11% and 38.5% of the implants in a 1-year period<sup>20,22</sup> and between 14.3%<sup>38</sup> and 66.7%<sup>33</sup> of the implants, and 60% of the patients,<sup>21</sup> in the long-term investigations (5–7 years).

#### Further Disease Progression and Other Complications

Despite the successful clinical and radiographic clinical performance of augmentative therapies, cases of implant loss, disease recurrence, and further progression were reported<sup>17–19,21,23,31,33,35,37–40</sup> (Tables 3 and 4). Exposure of the barrier

membrane (nonresorbable<sup>34,36</sup> and resorbable<sup>25,30,32</sup>), fistula, or sequester formation were reported in 58.6% of the cases when barrier membrane (resorbable and nonresorbable) was used.<sup>34</sup>

#### Factors Influencing Augmentative Treatment Outcomes

The clinical outcomes of surgical augmentative therapy were reported to be influenced by the implant surface characteristics,<sup>38</sup> as well as by the periimplant defect configuration.<sup>26</sup> Particularly, moderately rough surface implants demonstrated superior clinical treatment outcomes in comparison to rough surface implants,<sup>38</sup> and circumferential-type defects were shown to perform in a superior manner in conjunction with a dehiscence-type defect.<sup>26</sup>

#### CONCLUSIONS/RECOMMENDATIONS

- Surgical augmentative periimplantitis therapy resulted in improved clinical and radiographic treatment outcomes compared to the baseline in the majority of studies with 6 months to 7 to 10 years of follow-up.
- Augmentative surgical techniques with the application of the titanium granules did not demonstrate superior clinical treatment outcomes when compared to a nonaugmentative approach (3 RCTs).
- There is no evidence to support the superiority of a specific material, product, or membrane in terms of long-term clinical treatment benefits.
- The method of implant surface decontamination did not influence the clinical outcomes of surgical augmentative periimplantitis therapy (1 RCT and 1 controlled comparative study).
- Clinical augmentative treatment outcomes were shown to be influenced by factors such as periimplant bone defect morphology and implant surface characteristics (2 controlled clinical studies).
- Due to the lack of comparative studies, no clinical recommendations can be given for the mode of healing (ie, nonsubmerged vs submerged) as well as for the adjunctive use of systemic antibiotics.

- Periimplantitis recurrence requiring retreatment or leading to implant loss was reported.

#### DISCLOSURE

The authors claim to have no financial interest, either directly or indirectly, in the products or information listed in the article.

#### ROLES/CONTRIBUTIONS BY AUTHORS

A. Ramanauskaite made substantial contribution to the data collection, conception, and interpretation of data as well as manuscript writing. K. Obreja contributed to the data collection, interpretation and data discussion. R. Sader contributed to critical evaluation of the manuscript and data discussion. F. Khoury contributed to critical evaluation of the manuscript and data discussion. G. Romanos contributed to critical evaluation of the manuscript and data discussion. K. T. Koo contributed to critical evaluation of the manuscript and data discussion. P. L. Keeve contributed to critical evaluation of the manuscript and data discussion. A. Sculean contributed to critical evaluation of the manuscript and data discussion. S. Frank made substantial contribution to the interpretation of data and manuscript writing.

#### ACKNOWLEDGMENTS

Ausra Ramanauskaite and Karina Obreja equally contributed to the present work and share the first authorship.

#### REFERENCES

1. Schwarz F, Derks J, Monje A, et al. Peri-implant diseases and conditions: Peri-implantitis. *J Periodontol*. 2018 [epub ahead of print].
2. Lang NP, Berglundh T. Periimplant diseases: Where are we now? Consensus of the seventh European Workshop on Periodontology. *J Clin Periodontol*. 2011; 38:178–181.
3. Klinge B, Meyle J. Peri-implant tissue destruction. The third EAO consensus conference 2012. *Clin Oral Implants Res*. 2012;23:108–110.
4. Schwarz F, Schmucker A, Becker J. Efficacy of alternative or adjunctive measures to conventional treatment of

peri-implant mucositis and peri-implantitis: A systematic review and meta-analysis. *Int J Implant Dent*. 2015;1:22–56.

5. Renvert S, Polyzois IN. Clinical approaches to treat peri-implant mucositis and peri-implantitis. *Periodontol*. 2000;2015;68:369–404.

6. Khoshkam V, Chan HL, Lin GH, et al. Reconstructive procedures for treating peri-implantitis: A systematic review. *J Dent Res*. 2013;92:131s–138s.

7. Esposito M, Grusovin MG, Worthington HV. Interventions for replacing missing teeth: Treatment of peri-implantitis. *Cochrane Database Syst Rev*. 2012;1:Cd004970.

8. Mijiritsky E, Yatzkaier G, Mazor Z, et al. The use of porous titanium granules for treatment of peri-implantitis lesions: Preliminary clinical and radiographic results in humans. *Br Dent J*. 2013;214:E13.

9. Lagervall M, Jansson LE. Treatment outcome in patients with peri-implantitis in a periodontal clinic: A retrospective study. *J Periodontol*. 2013;84:1365–1373.

10. Serino G, Turri A. Outcome of surgical treatment of peri-implantitis: Results from a 2-year prospective clinical study in humans. *Clin Oral Implants Res*. 2011;22:1214–1220.

11. De Angelis N, Felice P, Grusovin MG, et al. The effectiveness of adjunctive light-activated disinfection (LAD) in the treatment of peri-implantitis: 4-month results from a multicentre pragmatic randomised controlled trial. *Eur J Oral Implantol*. 2012;5:321–331.

12. Carcuac O, Derks J, Abrahamsson I, et al. Surgical treatment of peri-implantitis. 3-year results from a randomized controlled clinical trial. *J Clin Periodontol*. 2017;44:1294–1303.

13. Toma S, Lasserre JF, Taieb J, et al. Evaluation of an air-abrasive device with amino acid glycine-powder during surgical treatment of peri-implantitis. *Quintessence Int*. 2014;45:209–219.

14. Caccianiga G, Rey G, Baldoni M, et al. Clinical, radiographic and microbiological evaluation of high level laser therapy, a new photodynamic therapy protocol, in peri-implantitis treatment; a Pilot Experience. *Biomed Res Int*. 2016;2016:6321906.

15. Moher D, Liberati A, Tetzlaff J, et al. Preferred reporting items for systematic reviews and meta-analyses: The PRISMA statement. *J Clin Epidemiol*. 2009;62:1006–1012.

16. Wells GA, Shea B, O'Connell D, et al. *The Newcastle—Ottawa Scale (NOS) for Assessing the Quality of Nonrandomized Studies in Meta-analyses*; 2009. Available at: [http://](http://www.wohrica.com/programs/clinical_epidemiology/oxford.htm)

[www.wohrica.com/programs/clinical\\_epidemiology/oxford.htm](http://www.wohrica.com/programs/clinical_epidemiology/oxford.htm).

17. Froum SJ, Froum SH, Rosen PS. A regenerative approach to the successful treatment of peri-implantitis: A consecutive series of 170 implants in 100 patients with 2- to 10-year follow-up. *Int J Periodontics Restorative Dent*. 2015;35:857–863.

18. Wohlfahrt JC, Lyngstadaas SP, Ronold HJ, et al. Porous titanium granules in the surgical treatment of peri-implant osseous defects: A randomized clinical trial. *Int J Oral Maxillofac Implants*. 2012;27:401–410.

19. Andersen H, Aass AM, Wohlfahrt JC. Porous titanium granules in the treatment of peri-implant osseous defects—a 7-year follow-up study. *Int J Implant Dent*. 2017;3:50–57.

20. Jepsen K, Jepsen S, Laine ML, et al. Reconstruction of peri-implant osseous defects: A multicenter randomized trial. *J Dent Res*. 2016;95:58–66.

21. Schwarz F, John G, Schmucker A, et al. Combined surgical therapy of advanced peri-implantitis evaluating two methods of surface decontamination: A 7-year follow-up observation. *J Clin Periodontol*. 2017;44:337–342.

22. Aghazadeh A, Rutger Persson G, Renvert S. A single-centre randomized controlled clinical trial on the adjunct treatment of intra-bony defects with autogenous bone or a xenograft: Results after 12 months. *J Clin Periodontol*. 2012;39:666–673.

23. Schwarz F, Sahm N, Bieling K, et al. Surgical regenerative treatment of peri-implantitis lesions using a nanocrystalline hydroxyapatite or a natural bone mineral in combination with a collagen membrane: A four-year clinical follow-up report. *J Clin Periodontol*. 2009;36:807–814.

24. Rotenberg SA, Steiner R, Tatakis DN. Collagen-coated bovine bone in peri-implantitis defects: A Pilot study on a novel approach. *Int J Oral Maxillofac Implants*. 2016;31:701–707.

25. Guler B, Uraz A, Yalim M, et al. The comparison of porous titanium granule and xenograft in the surgical treatment of peri-implantitis: A prospective clinical study. *Clin Implant Dent Relat Res*. 2017;19:316–327.

26. Schwarz F, Sahm N, Schwarz K, et al. Impact of defect configuration on the clinical outcome following surgical regenerative therapy of peri-implantitis. *J Clin Periodontol*. 2010;37:449–455.

27. Nart J, de Tapia B, Pujol A, et al. Vancomycin and tobramycin impregnated mineralized allograft for the surgical regenerative treatment of peri-implantitis: A 1-year follow-up case series. *Clin Oral Investig*. 2017;22:2199–2207.

28. Schwarz F, Sahm N, Becker J. Combined surgical therapy of advanced

peri-implantitis lesions with concomitant soft tissue volume augmentation. A case series. *Clin Oral Implants Res*. 2014;25:132–136.

29. Romanos GE, Nentwig GH. Regenerative therapy of deep peri-implant infrabony defects after CO2 laser implant surface decontamination. *Int J Periodontics Restorative Dent*. 2008;28:245–255.

30. Matarasso S, Iorio Siciliano V, Aglietta M, et al. Clinical and radiographic outcomes of a combined resective and regenerative approach in the treatment of peri-implantitis: A prospective case series. *Clin Oral Implants Res*. 2014;25:761–767.

31. Rocuzzo M, Gaudio L, Lungo M, et al. Surgical therapy of single peri-implantitis intrabony defects, by means of deproteinized bovine bone mineral with 10% collagen. *J Clin Periodontol*. 2016;43:311–318.

32. Roos-Jansaker AM, Renvert H, Lindahl C, et al. Submerged healing following surgical treatment of peri-implantitis: A case series. *J Clin Periodontol*. 2007;34:723–727.

33. Roos-Jansaker AM, Persson GR, Lindahl C, et al. Surgical treatment of peri-implantitis using a bone substitute with or without a resorbable membrane: A 5-year follow-up. *J Clin Periodontol*. 2014;41:1108–1114.

34. Khoury F, Buchmann R. Surgical therapy of peri-implant disease: A 3-year follow-up study of cases treated with 3 different techniques of bone regeneration. *J Periodontol*. 2001;72:1498–1508.

35. Behneke A, Behneke N, d'Hoedt B. Treatment of peri-implantitis defects with autogenous bone grafts: Six-month to 3-year results of a prospective study in 17 patients. *Int J Oral Maxillofac Implants*. 2000;15:125–138.

36. Haas R, Baron M, Dortbudak O, et al. Lethal photosensitization, autogenous bone, and e-PTFE membrane for the treatment of peri-implantitis: Preliminary results. *Int J Oral Maxillofac Implants*. 2000;15:374–382.

37. Ished C, Holmlund A, Renvert S, et al. Effectiveness of enamel matrix derivative on the clinical and microbiological outcomes following surgical regenerative treatment of peri-implantitis: A randomized controlled trial. *J Clin Periodontol*. 2016;43:863–873.

38. Rocuzzo M, Pittoni D, Rocuzzo A, et al. Surgical treatment of peri-implantitis intrabony lesions by means of deproteinized bovine bone mineral with 10% collagen: 7-year-results. *Clin Oral Implants Res*. 2017;28:1577–1583.

39. Deppe H, Horch HH, Neff A. Conventional versus CO2 laser-assisted

treatment of peri-implant defects with the concomitant use of pure-phase beta-tricalcium phosphate: A 5-year clinical report. *Int J Oral Maxillofac Implants*. 2007;22:79–86.

40. Wiltfang J, Zernial O, Behrens E, et al. Regenerative treatment of peri-implantitis bone defects with a combination of autologous bone and a demineralized xenogenic bone graft: A series of 36 defects. *Clin Implant Dent Relat Res*. 2012;14:421–427.

41. Schwarz F, Sculean A, Bieling K, et al. Two-year clinical results following treatment of peri-implantitis lesions using a nanocrystalline hydroxyapatite or a natural bone mineral in combination with a collagen membrane. *J Clin Periodontol*. 2008;35:80–87.

42. Schwarz F, Bieling K, Latz T, et al. Healing of intrabony peri-implantitis defects

following application of a nanocrystalline hydroxyapatite (Ostim) or a bovine-derived xenograft (Bio-Oss) in combination with a collagen membrane (Bio-Gide). A case series. *J Clin Periodontol*. 2006;33:491–499.

43. Roos-Jansaker AM, Lindahl C, Persson GR, et al. Long-term stability of surgical bone regenerative procedures of peri-implantitis lesions in a prospective case-control study over 3 years. *J Clin Periodontol*. 2011;38:590–597.

44. Schwarz F, Hegewald A, John G, et al. Four-year follow-up of combined surgical therapy of advanced peri-implantitis evaluating two methods of surface decontamination. *J Clin Periodontol*. 2013;40:962–967.

45. Schwarz F, John G, Mainusch S, et al. Combined surgical therapy of

peri-implantitis evaluating two methods of surface debridement and decontamination. A two-year clinical follow up report. *J Clin Periodontol*. 2012;39:789–797.

46. Schwarz F, Sahm N, Iglhaut G, et al. Impact of the method of surface debridement and decontamination on the clinical outcome following combined surgical therapy of peri-implantitis: A randomized controlled clinical study. *J Clin Periodontol*. 2011;38:276–284.

47. Rocuzzo M, Bonino F, Bonino L, et al. Surgical therapy of peri-implantitis lesions by means of a bovine-derived xenograft: Comparative results of a prospective study on two different implant surfaces. *J Clin Periodontol*. 2011;38:738–745.