

## P150

## Effects of oxygen administration during CMR imaging in patients with multi-vessel coronary artery disease

Guensch DP.<sup>1</sup>; Fischer K.<sup>1</sup>; Yamaji K.<sup>2</sup>; Ueki Y.<sup>2</sup>; Jung B.<sup>3</sup>; Raber L.<sup>2</sup>; Von Kobligk-Tengg H.<sup>3</sup>; Eberle B.<sup>1</sup>

<sup>1</sup>Bern University Hospital, Department of Anaesthesiology and Pain Medicine, Bern, Switzerland

<sup>2</sup>Bern University Hospital, Department of Cardiology, Bern, Switzerland

<sup>3</sup>Bern University Hospital, Institute for Diagnostic, Interventional and Paediatric Radiology, Bern, Switzerland

**Funding Acknowledgements:** Funded by institutional funds of the Department of Anaesthesiology and Pain Medicine, Inselspital, Bern University Hospital, Bern, Switzerland

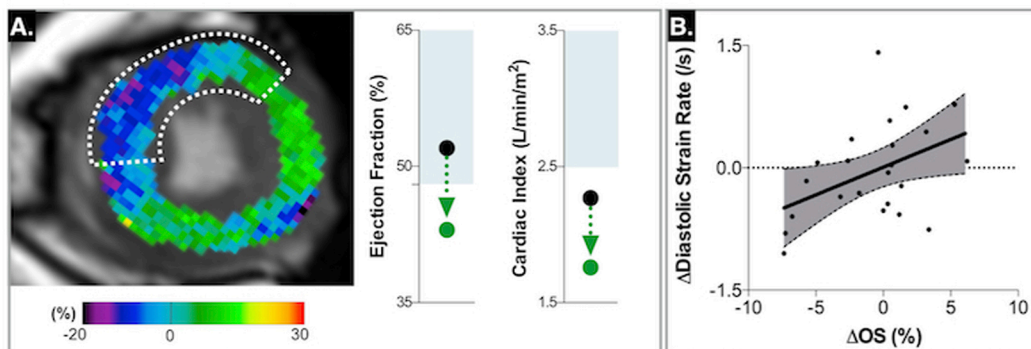
**Background:** Hyperoxia is a known coronary vasoconstrictor and it has been shown that supraphysiologic oxygen concentrations reduce coronary blood flow. In patients with coronary artery disease (CAD) this may even induce ischemia. The purpose of this study was to assess the impact of oxygen inhalation on myocardial oxygenation, contractility and relaxation during a cardiovascular magnetic resonance (CMR) scan in patients with multi-vessel CAD.

**Methods:** Twenty-six patients with stable multi-vessel CAD underwent a CMR scan in the interval between staged coronary revascularization procedures. The diameter stenosis (%DS) was assessed by quantitative coronary angiography (QCA). Ten healthy controls underwent the same CMR scan. This included standard cine function imaging and oxygenation-sensitive (OS-)CMR images acquired prior to and after inhaling O<sub>2</sub> for 5 min (10L/min, reservoir mask). Myocardial oxygenation changes were assessed by calculating the %change in OS signal intensity (SI) in end-systolic frames. Global cardiac function and regional contractility using feature tracking strain were analyzed after tracing myocardial contours in systole and diastole.

**Results:** The mean degree of coronary stenosis was  $63 \pm 15\%$ . 42% of patients experienced a decrease in OS-SI ( $-4.5 \pm 2.2\%$ ), while 29% improved oxygenation ( $3.2 \pm 2.0\%$ ). Myocardium perfused via higher-grade stenoses showed more pronounced decreases in tissue oxygenation ( $r = -0.405$ ,  $p = 0.049$ ). In stenosed segments, the time to peak systolic strain increased  $25 \pm 39$ ms during hyperoxia in comparison to normoxia ( $p = 0.005$ ). This was not seen in remote myocardium ( $p = 0.831$ ) or healthy subjects ( $p = 0.857$ ). Depression of diastolic strain rate was associated with more pronounced deterioration of myocardial oxygenation in affected segments ( $r = 0.438$ ,  $p = 0.037$ ) as opposed to normal myocardium (remote:  $r = 0.163$ ,  $p = 0.435$ ; controls:  $r = -0.077$ ,  $p = 0.856$ ). A decrease in ejection fraction ( $-6 \pm 4$  vs.  $+3 \pm 3\%$ ) and cardiac index ( $-0.4 \pm 0.2$  vs.  $0.3 \pm 0.3$  L/min/m<sup>2</sup>) was observed in 48% and 64% of patients during hyperoxia, respectively, but not in controls.

**Conclusion:** In a substantial proportion of patients with CAD, hyperoxia impairs systolic and also diastolic function. The latter is known to be affected early in the ischemic cascade. A higher degree stenosis is associated with more pronounced deoxygenation during hyperoxia. Thus oxygen supplementation may confound systolic and diastolic function assessment in CAD. This may also be true for perfusion studies. In patients with known or suspected CAD, oxygen should only be used during CMR exams to ensure normoxemia, while hyperoxia should be avoided. Further research is warranted to better understand the heterogeneity of the response to oxygen.

Abstract P150 Figure.



**A:** After 5 minutes of oxygen inhalation, myocardial oxygenation deteriorated in the anterior and anteroseptal wall in this patient with a LAD stenosis. This was accompanied by a marked decrease in ejection fraction and cardiac output. **B:** A hyperoxia induced reduction in myocardial oxygenation was correlated to poorer diastolic strain rate in post-stenotic segments.