Operative Orthopädie und Traumatologie

Surgical Techniques

Oper Orthop Traumatol
https://doi.org/10.1007/s00064-019-00642-x
Received: 10 April 2019
Revised: 21 July 2019
Accepted: 23 July 2019

Editor
A. Roth, Leipzig

Christiane Sylvia Leibold · Florian Schmaranzer · Klaus-Arno Siebenrock · Simon Damian Steppacher
Department for Orthopedic Surgery, University Hospital Berne, Bern, Switzerland

Femoral osteotomies for the treatment of avascular necrosis of the femoral head

Introductory remarks

Nontraumatic osteonecrosis (ONFH) of the femoral head is a devastating condition with a multifactorial etiology. Apart from idiopathic etiology, osteonecrosis of the femoral head occurs secondary to corticosteroid use, alcohol abuse, sickle cell disease, and radiotherapy cytotoxic agents among others. Without treatment, the osteonecrosis is usually progressive and often causes femoral head collapse, leading to osteoarthritis [12]. Multiple treatment options are available for the treatment of osteonecrosis of the femoral head. They range from conservative treatment to several surgical treatment methods such as core decompression, bone grafting, angular femoral osteotomy, rotational transtrochanteric osteotomies, and total hip arthroplasty depending on the stage, extension, and localization of the osteonecrosis.

There is no general consensus on the optimal treatment for this challenging condition [3]. In this article, we focus on femoral osteotomy as a therapeutic option and give a detailed description of the method we use for the treatment of ONFH in patients who qualify for hip-preserving surgery.

Surgical principle and objective

The aim of femoral osteotomies in the treatment of ONFH is to move the area of necrosis out of the weight-bearing region, which leads to delayed progression or even healing of the necrosis. Femoral osteotomies in the treatment of ONFH can be divided into angular and rotational osteotomies. With a rotational transtrochanteric osteotomy, the necrotic zone of the head-neck fragment is rotated anterior or posterior around the neck axis to unload the necrotic zone. With a varus angular osteotomy, the necrotic lesion is shifted medially and the lateral, typically non-necrotic part of the femoral head is displaced in the area of weight-loading. Additional flexion or extension correction can be performed, depending on the localization of necrosis on sagittal magnetic resonance imaging (MRI) sequences. For all procedures, precise knowledge of the vascular anatomy of the proximal femur is essential to avoid iatrogenic necrosis [11, 15].

Advantages

- Surgical hip dislocation [4] provides full access to the acetabulum and the femoral head
- Direct treatment of the necrotic area can be performed with curettage, bone grafting, and treatment of cartilage lesions
- Concomitant procedures such as offset correction, labral treatment, or correction of femoral torsion can be performed [21]
- A varus or flexion osteotomy decreases the loading force on the necrotic lesion and helps the bone to heal

Disadvantages

- Minimum 8 weeks of limited weight-bearing
- Technically demanding surgical technique
- Change in hip anatomy with changes in lever arm, muscular tension, and leg length shortening due to varus osteotomy may lead to limping
- Trochanteric screws or plate may require secondary hardware removal

Indications

- Circumscribed osteonecrosis of the femoral head
- No advanced degenerative signs (Tönnis grade ≤ 1 in the conventional radiograph)
- Relatively young patient (age < 50 years)

Contraindications

- Advanced radiographic joint degeneration (> Tönnis grade 1)
- Extensive osteonecrosis (Kerboul ≥ 240°)
- Advanced lesions (≥ grade 3b Association Research Circulation Osseous [ARCO] classification)
- Older patients (age ≥ 50 years)

Published online: 29 November 2019

Oper Orthop Traumatol https://doi.org/10.1007/s00064-019-00642-x

C. S. Leibold · F. Schmaranzer · K.-A. Siebenrock · S. D. Steppacher

Femoral osteotomies for the treatment of avascular necrosis of the femoral head

Abstract

Objective. Unloading of the area of necrosis out of the weight-bearing region by shifting healthy bone in the main weight-bearing area, which may delay the progression of the necrosis and enable healing.
Indications. Circumscribed osteonecrosis of the femoral head without advanced degenerative signs (Tönnis grade ≤ 1) in the relatively young patient (age < 50 years).
Contraindications. Radiographic joint degeneration (> Tönnis grade 1); extensive avascular necrosis (Kerboul angle > 240°); advanced lesions (≥ Association Research Circulation Osseous [ARCO] classification 3b).
Surgical technique. By performing a surgical hip dislocation, full access to the hip joint is gained. A femoral varus osteotomy is used to turn the necrotic lesion of the femoral head out of the central weight-bearing area and more medially. Osteosynthesis is performed with an angular stable screw or a blade plate. Via a trapdoor procedure, direct debridement and autologous bone grafting from the trochanter major is possible. The cartilage flap is preserved whenever possible or supplanted by an autologous matrix-induced chondrogenesis (AMIC).
Postoperative management. A passive motion device is installed during hospital stay beginning immediately after surgery to prevent capsular adhesions. After surgery, patients are mobilized with partial weight-bearing of 15 kg with the use of crutches for at least 8 weeks. Forced abduction and adduction as well as flexion of more than 90° are restricted to protect the trochanteric osteotomy. After radiographic confirmation of healing at the 8-week follow-up, stepwise return to full weight-bearing is allowed and abductor training is initiated.
Results. Nine patients (10 hips) with osteonecrosis of the femoral head were treated with surgical hip dislocation and varus osteotomy. Six hips were treated with autologous bone grafting, four hips with antegrade drilling. Chondral lesions were sutured in four cases, whereas two cases needed an AMIC treatment. The mean age at operation was 29 ± 9 years (20–49), and the mean follow-up time for all patients was 3 ± 2 years (1–7). Conversion to a total hip prosthesis was required for one hip with progressing arthrosis. The other nine hips showed no progression of necrosis and an improved clinical outcome. Complications were pseudarthrosis of the femoral osteotomy and pseudarthrosis of the greater trochanter.

Keywords

Osteonecrosis · Hip dislocation · Osteotomy · Trapdoor procedure · Weight-bearing

Femorale Umstellungsosteotomien zur Behandlung avaskulärer Femurkopfnekrosen

Zusammenfassung

Operationsziel. Entlastung der nekrotischen Zone des Femurkopfs durch Hereinschwenken von gesundem Knochen in die Hauptbelastungszone, um ein Fortschreiten der Nekrose zu verhindern und eine Ausheilung zu ermöglichen.
Indikationen. Umschriebene Osteonekrose des Femurkopfs ohne fortgeschrittene Degeneration (Tönnis-Klassifikation ≤ 1) bei jüngeren Patienten (Alter < 50 Jahren).
Kontraindikationen. Fortgeschrittene Gelenkdegeneration (Tönnis-Klassifikation >1), ausgedehnte Nekrosen (Kerboul-Winkel > 240°) und ausgeprägte Nekrosen (≥ ARCO 3b).
Operationstechnik. Mittels chirurgischer Hüftluxation kann das komplette Hüftgelenk eingesehen werden. Mit einer varisierenden Osteotomie wird die nekrotische Läsion aus der zentralen, gewichtstragenden Zone des Kopfs weiter nach medial geschwenkt. Die Osteosynthese kann mit einer winkelstabilen Platte oder einer Klingenplatte durchgeführt werden. Mit der Trapdoor-Technik kann die Nekrose zusätzlich direkt kürettiert und mit autologem Knochen aufgefüllt werden. Der Knorpellappen wird, wenn möglich, erhalten oder bei Defekten durch eine autologe matrixinduzierte Chondrogenese (AMIC-Plastik) ersetzt.
Weiterbehandlung. Unmittelbar postoperativ wird mit der Mobilisation auf einer passiven Bewegungsschiene begonnen, um kapsulären Adhäsionen vorzubeugen. Für mindestens 8 Wochen findet eine Teilbelastung des Beins an Unterarmgehstöcken statt. Forcierte Abduktion, Adduktion und Flexion über 90° sind in dieser Zeit zu vermeiden, um die Konsolidierung der Trochanterosteotomie nicht zu gefährden. Nach radiologisch bestätigter Heilung des Knochens in der 8-Wochen-Kontrolle können der schrittweise Übergang zur Vollbelastung sowie in der Folge das Abduktorentraining begonnen werden.
Ergebnisse. Neun Patienten (10 Hüften) mit Osteonekrose des Femurkopfs wurden mittels chirurgischer Hüftluxation und varisierender Osteotomie behandelt. Bei 6 Hüften wurde der Defekt mit autologer Knochenspende aufgefüllt, bei 4 Hüften erfolgte ein antegrades Anbohren der Läsion. Der Knorpeldefekt konnte in 4 Fällen wieder angenäht und in 2 Fällen mit einer AMIC-Plastik behandelt werden. Das mittlere Alter bei Operation betrug 29 ± 9 Jahre (Spanne 20–49 Jahre), der mittlere Nachkontrollzeitraum für alle Patienten war 3 ± 2 Jahre (Spanne 1–7 Jahre). Eine Hüfte konvertierte aufgrund fortschreitender Arthrose zu einer Hüfttotalprothese. Die weiteren 9 Hüften zeigten keine Progression der Nekrose und ein verbessertes klinisches Resultat. Komplikationen beinhalteten eine Pseudarthrose der Femurosteotomie und eine Pseudarthrose des Trochanters.

Schlüsselwörter

Osteonekrose · Hüftluxation · Osteotomie · Trapdoor-Technik · Gewichtsbelastung

Patient information

- General surgical risks (thrombosis; lung embolism; allergic reactions; injuries of skin, muscle, and nerves due to intraoperative positioning; injury of cutaneous nerves with numbness/dysesthesia; excessive bleeding requiring blood products; delayed wound healing and infection)
- Specific risks of this procedure:
  - Progression of necrosis and osteoarthritis in spite of operation
  - Delayed union and pseudarthrosis of the osteotomy or greater trochanter

- Leg length discrepancy
- Heterotopic ossification

Preoperative work-up

- Good knowledge of the patient's history (e.g., ongoing steroid therapy, chemotherapy, alcohol abuse) is essential to evaluate whether a hip-preserving operation is an option
- Standardized radiographic imaging including anteroposterior pelvic radiograph and axial view for planning with templates
- Magnetic resonance arthrography of the hip, preferably with intra-articular contrast agent injection and leg traction for evaluation of size and location of the necrosis and the intra-articular damage [16]
- Axial imaging (computed tomography [CT] or MRI) for evaluation of femoral torsion, for possible additional correction of torsion
- Preoperative templating for the direction and degree of femur osteotomy; varus osteotomy shifts a medially located lesion more medial and the non-affected lateral part into the weight-bearing zone, femoral flexion osteotomy shifts an anteriorly located lesion more anterior and the non-affected posterior part into the weight-bearing zone; both varus and flexion osteotomies can be combined; no more than 20° of correction in any direction is usually performed

Instruments

- Locking compression plate for proximal femur (pediatric hip plate; DePuy Synthes, Zuchwil, Switzerland) or angled blade plate for adults (DePuy Synthes)
- Optional fibrin glue (Tissucol; Baxter, Warsaw, Poland) for cartilage treatment
- Optional autologous matrix-induced chondrogenesis (AMIC) with type I/III collagen matrix (Chondro-Gide; Geistlich Pharma, Wolhusen, Switzerland)

Anesthesia and positioning

- General anesthesia with full relaxation of the musculature
- Strict lateral decubitus position
- Stabilization of patient with two side supports
- Placement of the uninvolved lower leg in a tunnel bolster to avoid pressure and arrangement of a flat surface in a horizontal position for the involved lower limb
- Disinfection and sterile drapes include the entire lower extremity up to the thorax; the great trochanter should be freely palpable
- Fluoroscopy for intraoperative orientation and monitoring of the osteotomy, angular corrections, and placement of hardware
- Single-shot intravenous antibiotic prophylaxis (cefuroxime)

Surgical technique

(**Figs. 1, 2, 3, 4, 5, 6, 7, 8, 9 and 10**).

Surgical hip dislocation

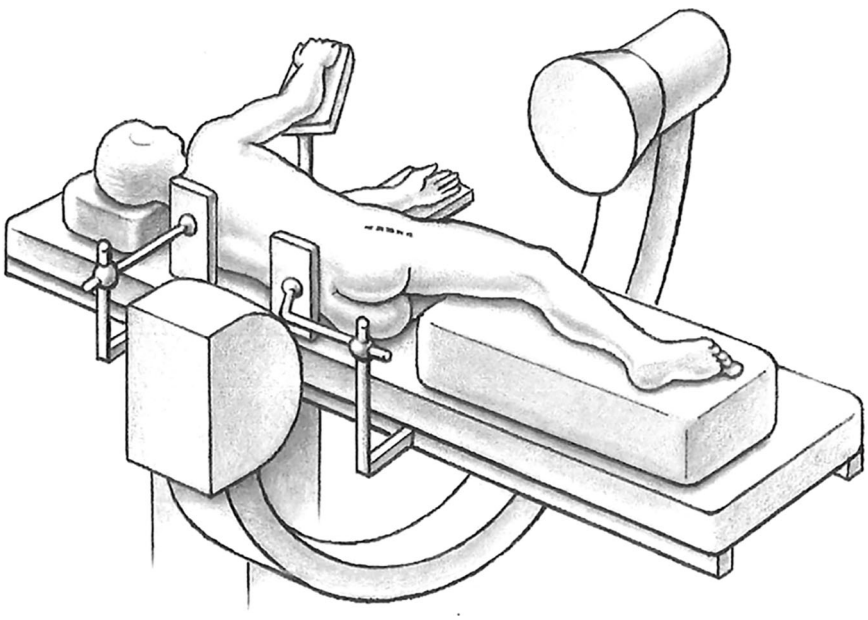

Fig. 1 ▲ A straight lateral skin incision of 15–20 cm is made, centered over the greater trochanter with the patient in the lateral decubitus position

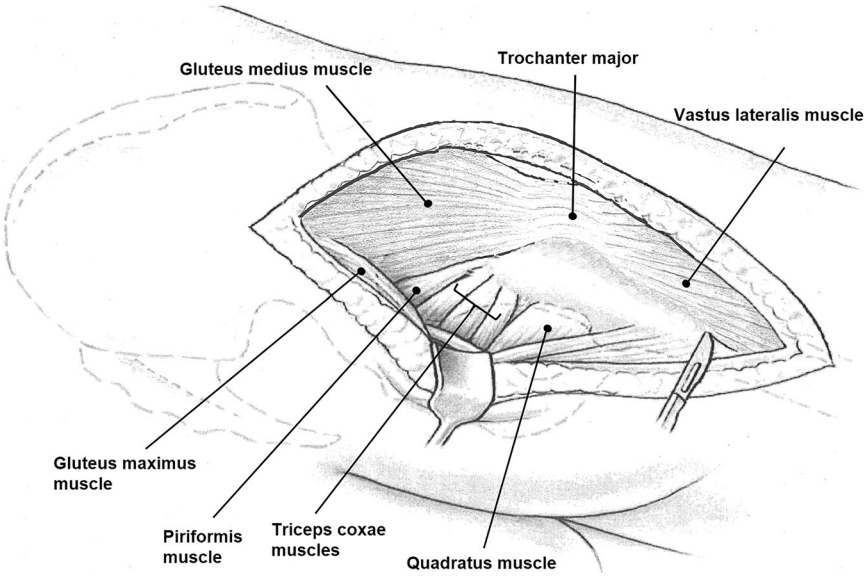

Fig. 2 ▲ A surgical hip dislocation is an intermuscular and internerval approach. After incision of the tractus, the superficial interval between the gluteus maximus and gluteus medius (Gibson interval) is developed. The deep interval is between the piriformis and the gluteus minimus muscle and best developed with the hip in extension and internal rotation

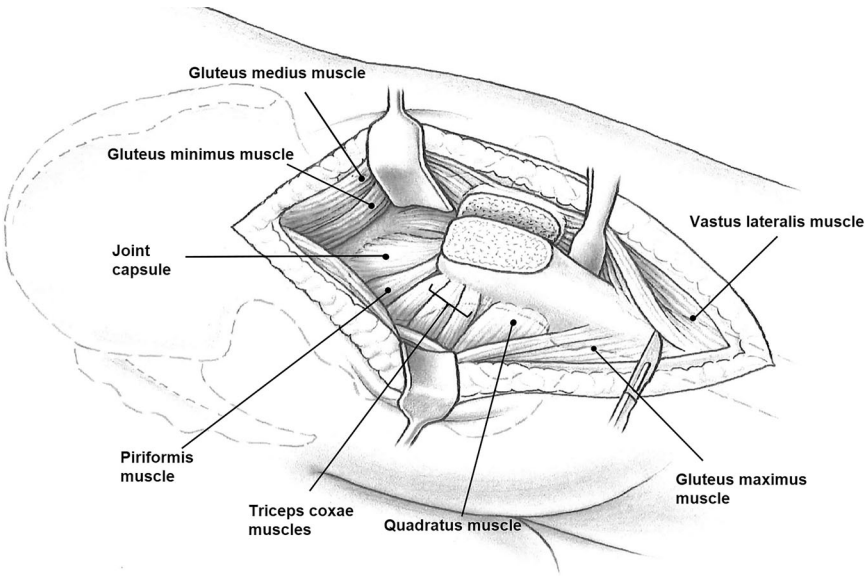

Fig. 3 ▲ Typically, a stepped trochanteric osteotomy is performed to minimize the risk of trochanteric pseudarthrosis after refixation. Alternatively, a flat osteotomy can be performed when the greater trochanter has to be distalized, if the varus osteotomy would result in a high riding trochanter [1]. The osteotomy starts at the posterosuperior tip of the greater trochanter and ends 10–15 mm distal to the lateral tubercle. Proximally, the osteotomy should end just anterior to the most posterior insertion of the gluteus medius leaving the short external rotators attached to the proximal femur. The trochanteric fragment is mobilized together with the vastus lateralis, gluteus minimus, and medius muscle ventrally and the capsule is exposed

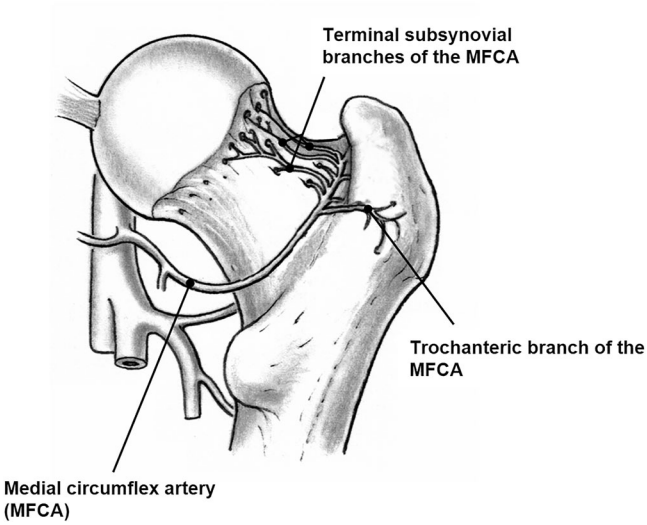

Fig. 4 ◄ The vascular anatomy of the proximal femur has to be respected when performing an osteotomy. The main nutrient vessel of the femoral head is the medial branch of the medial femoral circumflex artery (*MCFA*)

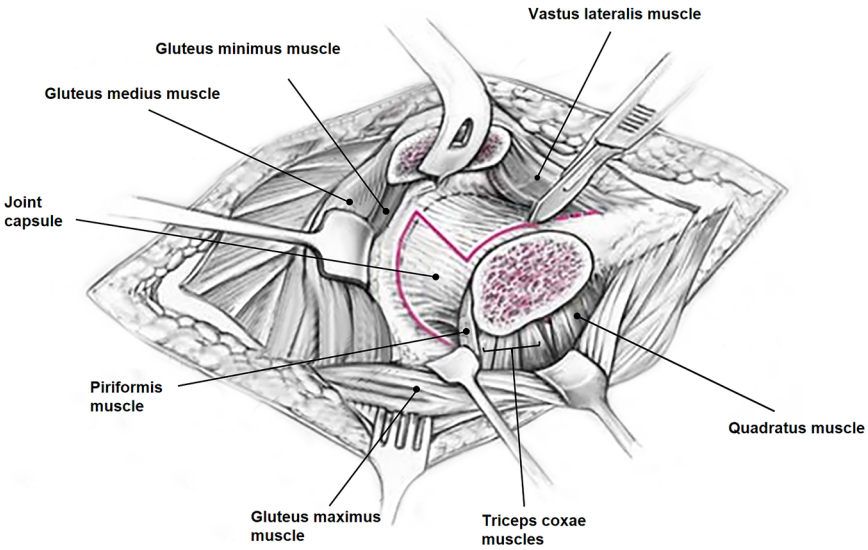

Fig. 5 ▲ The capsule is incised in a z-shaped manner without violating the labrum. The ligamentum teres is cut in a subluxed position to allow for full dislocation of the femoral head

Trapdoor procedure [13]

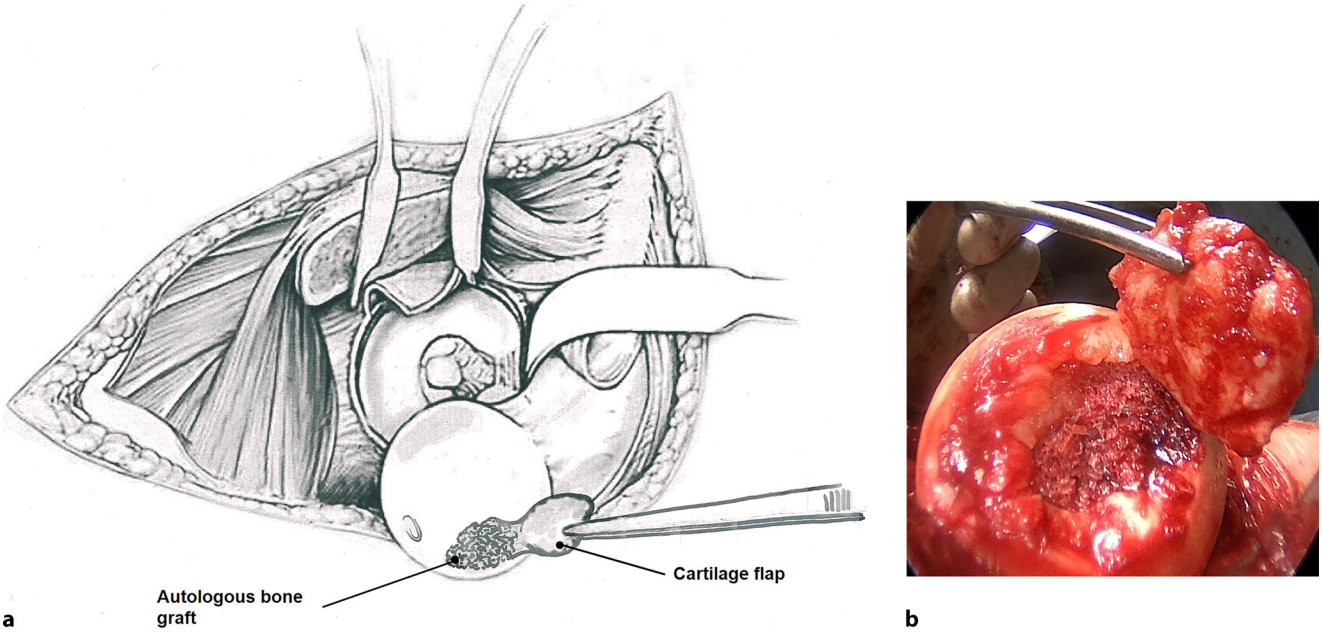

Fig. 6 ▲ **a** The acetabulum and femoral head are inspected. Typically, the cartilage covering the area of the femoral head necrosis is frayed, softened, or detached from the subchondral bone. The cartilage is elevated from the subchondral bone to access the necrotic bone. If not delaminated, an incision of the cartilage at the border of the necrotic area is made. With a high--speed burr, curettage of the necrotic bone is performed. Bone is removed until bleeding cancellous bone is found. Through the trochanteric osteotomy, harvesting of autologous cancellous bone of the trochanter major is performed. **b** The lesions are filled with impaction bone grafting [19]. Wherever possible, cartilage is preserved by gluing back the previously detached cartilage using fibrin glue and suturing of the cartilage boarder with resorbable monofilament sutures. With a concomitant femoral cartilage defect present, an autologous matrix-induced chondrogenesis (AMIC) is performed. AMIC is used for full cartilage defects, which are then covered with a type I/III collagen matrix (Novocart), glued to the bone with fibrin glue, and attached to the stable cartilage with sutures

Femoral osteotomy

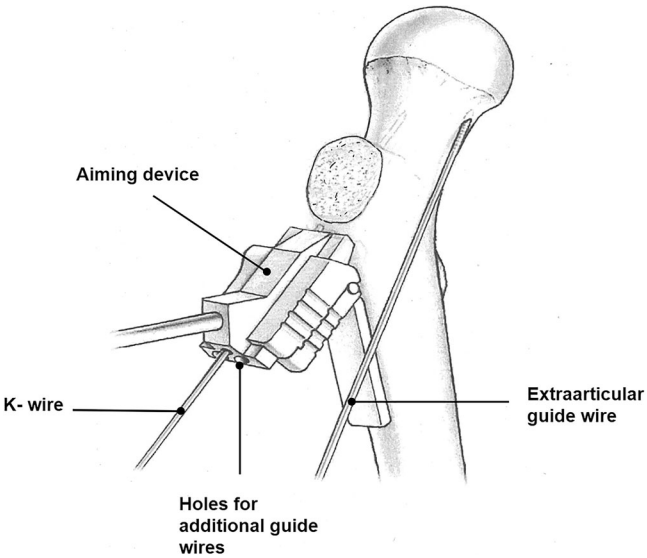

Fig. 7 ▲ The first guide wire is placed extra-articularly in line with the axis of the femoral neck. It indicates the femoral antetorsion and the height of the entry point of the positioning Kirschner wire in the sagittal plane. The calculated correction angle has to be adjusted on the aiming block. The aiming block consists of a guide proximally and a wing distally; the wing must be placed parallel to the shaft of the femur. If additional flexion or extension correction is needed, the wing of the aiming block can be placed posterior or anterior on the diaphysis. The positioning Kirschner wire is then inserted through the aiming block and placed in the center of the femoral neck

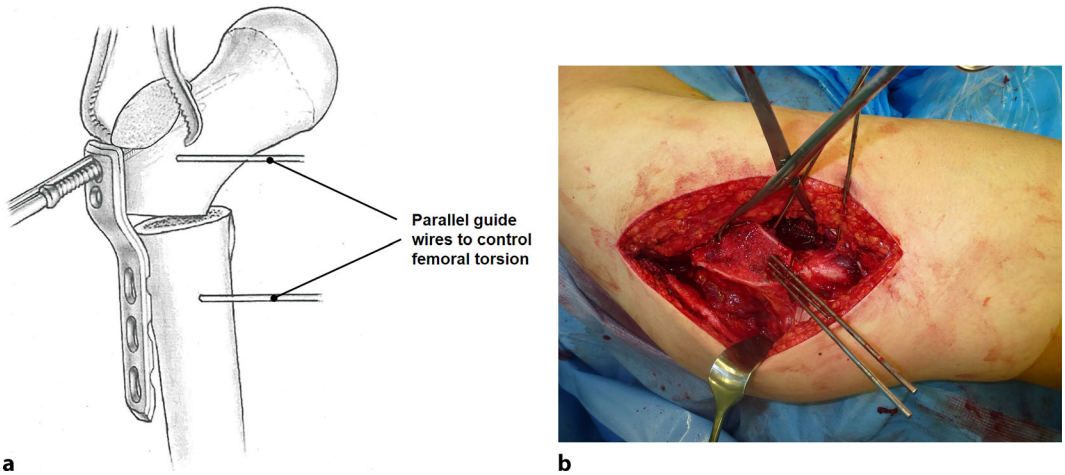

Fig. 8 ▲ Two more guide wires are inserted through the holes provided in the aiming block; they will serve as guide wires for the cannulated femoral neck screws. To control the rotation, the anterior cortex is marked with two parallel wires. The osteotomy is typically performed at the intertrochanteric level perpendicular to the shaft under constant irrigation. A varization of 15–20° is usually sufficient. The plate is attached to the proximal fragment with three angular stable and cannulated screws; typically, two of them are placed in the femoral neck, one in the calcar region

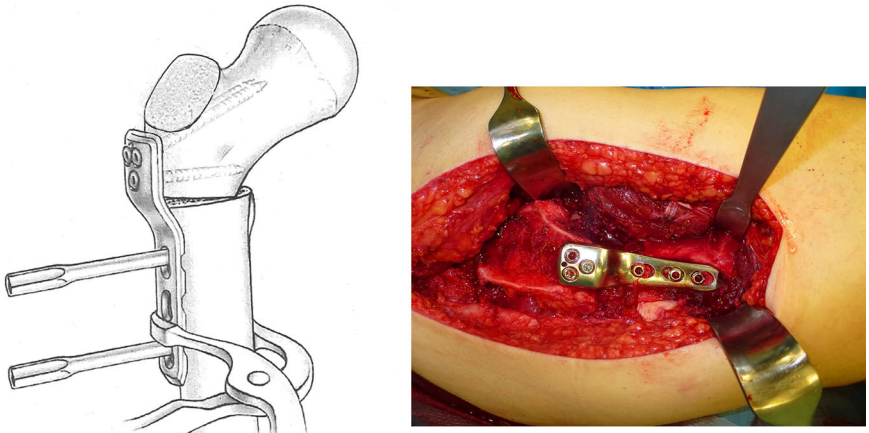

a b

Fig. 9 ▲ An implant with offset can be used to prevent additional lateralization of the diaphyseal fragment. The plate is then fixed to the diaphyseal fragment with either locking head or cortical screws

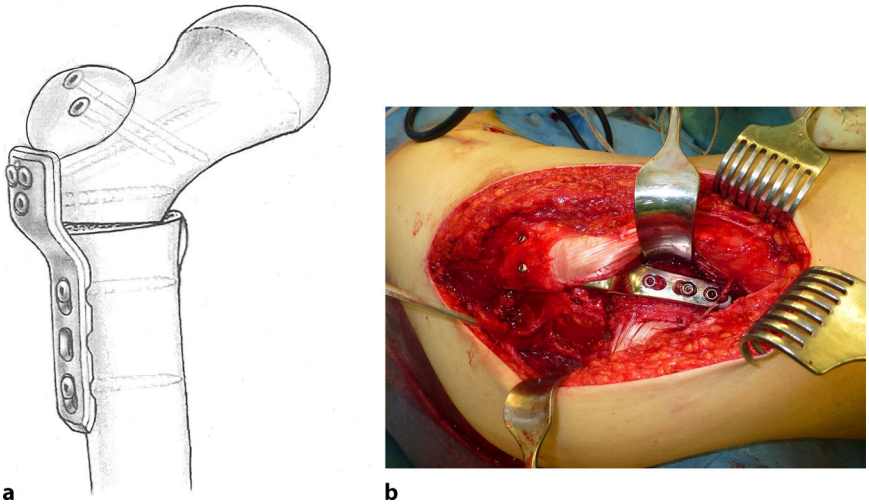

a b

Fig. 10 ▲ Fixation of the trochanteric fragment is performed with 3.5-mm cortical screws, optionally in a distalized position to avoid a high riding trochanter

Special surgical considerations

Surgical hip dislocation offers an excellent overall view of the joint, which allows for direct inspection and treatment of the necrosis, the chondral damage, and all concomitant pathologies to improve joint containment. During surgery, range of motion can be evaluated directly. Offset correction, labral attachment, and correction of torsional deformities can be performed additionally.

Postoperative management

Our postoperative protocol includes the use of a continuous passive motion device during hospital stay, beginning directly after surgery to prevent capsular adhesions. After surgery, patients are mobilized with partial weight-bearing of 15 kg with the use of crutches for at least 8 weeks. Forced abduction and adduction as well as flexion of more than 90° are restricted to protect the trochanteric osteotomy. Prophylaxis against thrombosis is applied as long as no full-weight bearing is allowed. After radiographic confirmation of healing at the 8-week follow-up, stepwise return to full weight-bearing is allowed and abductor training is initiated. Usually, return to work is possible 3 months after surgery.

Errors, hazards, complications

- Iatrogenic lesion of the femoral circumflex arteries with further damage to the blood flow of the femoral head
- Insufficient debridement of necrotic lesions (when performing curettage of the bone, the sclerotic zone of the bone around the necrosis must be removed until healthy bone is bleeding)
- Excessive debridement of cartilage (whenever possible, cartilage, even if already damaged, should be preserved)
- Delayed union or pseudarthrosis of the femoral osteotomy
- Intra-articular adhesions
- Heterotopic ossifications
- Excessive angular correction might result in new impingement conflict, pseudarthrosis of the osteotomy, leg length discrepancy, and high riding trochanter

Results

Preoperative findings

We retrospectively evaluated ten hips in nine patients with avascular osteonecrosis of the femoral head, who all underwent surgical hip dislocation with varus osteotomy between April 2011 and May 2017 (**Table 1**). The preoperative ARCO staging [5, 14, 20] based on radiographs and MRI was as follows: six hips with ARCO stage IIIa and four hips with a femoral head collapse (ARCO IIIb). Two patients (two hips) had previous hip surgery: One patient with posttraumatic avascular necrosis of the femoral head following a lateral neck fracture had undergone osteosynthesis with a dynamic hip screw 3 years before surgical hip dislocation and valgus osteotomy of the proximal femur for non-union 1 year later. Another patient had hip arthroscopy with core decompression and bone marrow injection in the femoral head 2 years before surgical hip dislocation.

Table 1 Preoperative patient data

Parameter	
Total number of hips (patients)	10 (9)
ARCO stage	IIIa = 6 IIIb = 4
Tönnis grade	0 = 9 1 = 1
Age at surgery	29 ± 9 (20–49)
Gender (% male of all hips)	77
Side (% right of all hips)	69
Height (cm)	174 ± 9 (160–184)
Weight (kg)	78 ± 13 (65–110)
Duration of surgery (h)	3.8 ± 1 (2.0–5.7)
Blood loss (ml)	800 ± 480 (300–1900)

Infobox 1 Explanation of scores

The *Kerboul angle* is a system used to quantify the size of a lesion. To calculate it, the center of the femoral head is first identified. Two lines are then drawn from this point to the borders of the lesion on both anteroposterior and lateral radiographs. The sum of the angles on the anteroposterior and lateral radiographs is the Kerboul angle. Lesions are classified as small, medium, or large—small: 160° or less, medium: 161–199°, large: 200° or more.

The *Merle d'Aubigné-Postel score* includes the parameters pain, mobility, and ability to walk, with each one rated from 0 points (= worst condition) to 6 points (= best condition). Addition of the scores for pain and mobility results in an absolute estimation of hip function. The difference between preoperative and postoperative status (all three categories, with pain, mobility, and walking ability) is multiplied by two before being added.

Table 2 Comparison with other centers using femoral osteotomies for nontraumatic osteonecrosis

Author	Method	Hips (*n*)	Mean follow-up in months (range)	Stage	Survivorship rate (%)
Steppacher et al. [17]	Subtrochanteric varus osteotomy	10	36 (12–84)	ARCO II and III	90
Zhao G et al. [22]	Transtrochanteric curved varus osteotomy	73	148.8 (60–372)	Japanese Orthopedic Association score (JOA) III and IV	92
Ito H et al. [10]	Varus half-wedge proximal femoral osteotomy	34	216 (126–312)	JOA II and III	82
Ikemura S et al. [9]	Transtrochanteric curved varus osteotomy	42	70.8 (24–150)	JOA I and III	98
Hamanishi M et al. [8]	Intertrochanteric curved varus osteotomy	53	NR	JOA I–III	98
Sugioka + Yanamoto [18]	Transtrochanteric posterior rotational	51	144 (14–252)	ARCO III and IV	100
Ha YC et al. [7]	Transtrochanteric rotational	113	51.6 (36–108)	Ficat II and III	88
Zhao G et al. [23]	Transtrochanteric anterior rotational	43	87.6 (36–120)	JOA III	95
Zhao G et al. [24]	Transtrochanteric posterior rotational	51	132 (60–240)	JOA III and IV	94
Biswal et al. [2]	Transtrochanteric rotational	60	84 (18–156)	Ficat II and III	82

Procedures

Femoral osteotomy was performed on ten hips. For six of them, curettage of the necrotic area and autologous bone grafting (trapdoor technique) were carried out and for four of them, antegrade drilling of the necrosis. Of the six hips that underwent the trapdoor procedure, the cartilage flap was sutured in four hips. Two hips were treated with an AMIC plastic. An intra-articular cam deformity was addressed in eight hips with offset correction. An extra-articular impingement of the greater trochanter and the pelvis was treated in four hips with relative femoral neck lengthening.

Follow-up

No patient was lost to follow-up. We were able to perform clinical and radiographic follow-up for all patients for a mean of 3 ± 2 years (1–7 years).

Evaluation

No hip showed progression of osteonecrosis (for evaluation scores, see **Infobox 1**). Seven hips remained in the same ARCO stage on the conventional radiograph at the most recent follow-up compared with the preoperative status. Three hips showed improvement by at least one ARCO stage: two hips with ARCO 3b preoperatively and one hip with ARCO 3a. All six hips that had autologous bone grafting showed signs of graft integration. The four hips with antegrade drilling of the lesion showed an improvement of the Kerboul angle [6] from 180 ± 46° (106–250°) preoperatively to 85 ± 26° (62–120°; $p < 0.001$). Progression of osteoarthritis was found in one hip: One hip with posttraumatic ONFH and ARCO IIIb showed progression from Tönnis I to II at the 2-year-follow-up with conversion to total hip arthroplasty. At the most recent follow-up, hip function was improved and pain was decreased compared with the preoperative status in all nine hips with a preserved hip joint. The prevalence of a positive anterior impingement test decreased from 92% preoperatively to 15% at the most recent follow-up ($p < 0.001$). The mean Merle d'Aubigné–Postel score increased from 14.1 ± 3.2 (8–17) preoperatively to 16.6 ± 0.7 (15–17) at the most recent follow-up ($p = 0.016$).

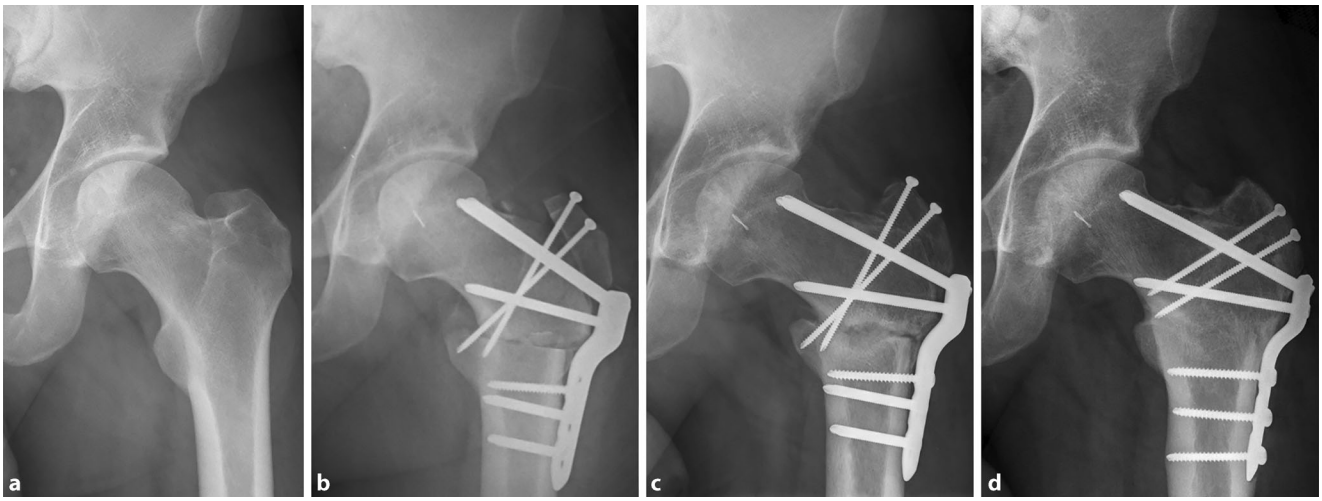

Fig. 11 ▲ Exemplary case with re-osteosynthesis of a pseudarthrosis. **a** Preoperative image with osteonecrosis; **b** shortly after surgery following varization and trapdoor procedure; **c** 8 months postoperatively with pseudarthrosis of the femoral osteotomy; **d** 4-year postoperative image after re-osteosynthesis of the osteotomy, maintaining sphericity of the femoral head

Revision surgery and complications

Next to isolated hardware removal in three hips, subsequent surgeries were performed on three hips; one patient underwent repeated surgical hip dislocation for previously non-treated femoroacetabular impingement including acetabular rim trimming and labral re-attachment at the 1-year follow-up. Another patient had re-osteosynthesis of a pseudarthrosis following femoral osteotomy at the 8-month follow-up but the final outcome was good (◘ **Fig. 11**). For a third patient, conversion to a total hip arthroplasty was made at the 2-year follow-up. We also observed a pseudarthrosis of the greater trochanter following osteotomy, which required no further surgery.

The results of other centers using femoral osteotomies for ONFH are shown in ◘ **Table 2**.

Corresponding address

Dr. Christiane Sylvia Leibold
Department for Orthopedic Surgery, University Hospital Berne
Freiburgstraße 8, 3010 Bern, Switzerland
christianesylvia.leibold@insel.ch

Compliance with ethical guidelines

Conflict of interest C.S. Leibold, F. Schmaranzer, K.-A. Siebenrock, and S.D. Steppacher declare that they have no competing interests.

Ethical review board approval was given for this study. All patients provided written consent and agreed to attend regular follow-up examinations.

References

1. Albers CE, Steppacher SD et al (2014) Relative femoral neck lengthening improves pain and hip function in proximal femoral deformities with a high-riding trochanter. Clin Orthop Relat Res 473(4):1378–1387
2. Biswal S, Hazra S et al (2009) Transtrochanteric rotational osteotomy for nontraumatic osteonecrosis of the femoral head in young adults. Clin Orthop Relat Res 467(6):1529–1537. https://doi.org/10.1007/s11999-008-0696-3
3. Chughtai M, Piuzzi N et al (2017) An evidence-based guide to the treatment of osteonecrosis of the femoral head. Bone Joint J 99b:1267–1279
4. Ganz R, Gill TJ et al (2002) Surgical dislocation of the adult hip a technique with full access to the femoral head and acetabulum without the risk of avascular necrosis. J Bone Joint Surg Br 83(8):1119–1124
5. Gardeniers JWM, Gosling-Gardeniers AC et al (2014) The ARCO staging system: generation and evolution since 1991. In: Koo K-H, Mont MA, Gordon M (eds) Osteonecrosis. Springer, Berlin, Heidelberg, pp 215–218
6. Ha YC, Jung WH et al (2006) Prediction of collapse in femoral head osteonecrosis: a modified kerboul method with use of magnetic resonance images. J Bone Joint Surg Am 88(3):35–40
7. Ha YC, Kim HJ et al (2011) Effects of age and body mass index on the results of transtrochanteric rotational osteotomy for femoral head osteonecrosis: surgical technique. J Bone Joint Surg Am 93(1):75–84
8. Hamanishi M, Yasunaga Y et al (2014) The clinical and radiographic results of intertrochanteric curved varus osteotomy for idiopathic osteonecrosis of the femoral head. Arch Orthop Trauma Surg 134(3):305–310
9. Ikemura S, Yamamoto T et al (2007) Leg-length discrepancy after transtrochanteric curved varus osteotomy for osteonecrosis of the femoral head. J Bone Joint Surg Br 89(6):725–729
10. Ito H, Tanino H et al (2012) Long-term results of conventional varus half-wedge proximal femoral osteotomy for the treatment of osteonecrosis of the femoral head. J Bone Joint Surg Br 94(3):308–314
11. Kalhor M, Ganz R et al (2012) Anatomic variations in femoral head circulation. Hip Int 22(3):307–312
12. Koo K-H, Mont MA, Jones LC et al (eds) (2014) Osteonecrosis. Springer, Berlin, Heidelberg
13. Mont MA, Einhorn TA et al (1998) The trapdoor procedure using autogenous cortical and cancellous bone grafts for osteonecrosis of the femoral head. J Bone Joint Surg Br 80(1):56–62
14. Mont MA, Marulanda GA et al (2006) Systematic analysis of classification systems for osteonecrosis of the femoral head. J Bone Joint Surg Am 88(3):16–26
15. Seeley MA, Georgiadis AG et al (2016) Hip vascularity: a review of the anatomy and

clinical implications. J Am Acad Orthop Surg 24(8):515–526
16. Schmaranzer F, Todorski IAS et al (2017) Intra-articular lesions: imaging and surgical correlation. Semin Musculoskelet Radiol 21(5):487–506
17. Steppacher SD et al. (2019) Surgical hip dislocation with femoral osteotomy and bone grafting prevents head collapse in hips with advanced necrosis. Hip Int 17:1120700019856010. https://doi.org/10.1177/1120700019856010. [Epub ahead of print]
18. Sugioka Y, Yamamoto T (2008) Transtrochanteric posterior rotational osteotomy for osteonecrosis. Clin Orthop Relat Res 466(5):1104–1109
19. Sultan A, Mont MA et al (2018) The use of non-vascularized bone grafts to treat osteonecrosis of the femoral head: indications, techniques, and outcomes. Int Orthop. https://doi.org/10.1007/s00264-018-4056-y
20. Sultan AA, Mohamed N et al (2018) Classification systems of hip osteonecrosis: an updated review. Int Orthop. https://doi.org/10.1007/s00264-018-4018-4
21. Tannast M, Siebenrock KA (2010) Open therapy of femoroacetabular impingement. Oper Orthop Traumatol 22(1):3–16
22. Zhao G, Yamamoto T, Ikemura S et al (2010) Radiological outcome analysis of transtrochanteric curved varus osteotomy for osteonecrosis of the femoral head at a mean follow-up of 12.4 years. J Bone Joint Surg Br 92(6):781–786
23. Zhao G, Yamamoto T et al (2012) Clinico-radiological factors affecting the joint space narrowing after transtrochanteric anterior rotational osteotomy for osteonecrosis of the femoral head. J Orthop Sci 17(4):390–396
24. Zhao G, Yamamoto T et al (2013) Radiological outcome analyses of transtrochanteric posterior rotational osteotomy for osteonecrosis of the femoral head at a mean follow-up of 11 years. J Orthop Sci 18(2):277–283