

## CASE REPORT

# Cryptococcosis with ocular and central nervous system involvement in a 3-year-old dog

Jean-Baptiste Barbry<sup>1</sup>  | Anne Sophie Poinard<sup>1</sup>  | Eymeric Gomes<sup>2</sup> |  
Alexane Durand<sup>3</sup> | Olivier Balland<sup>1</sup> 

<sup>1</sup>Lorrainevet, Ludres, France

<sup>2</sup>C.H.V. Fréguis, Arcueil, France

<sup>3</sup>Division of Clinical Radiology, Department of Clinical Veterinary Medicine, Vetsuisse Faculty, University of Bern, Bern, Switzerland

## Correspondence

Jean-Baptiste Barbry, Lorrainevet, 127 rue Pierre Gilles de Gennes, Ludres 54710, France.  
Email: Ophtalmologie@lorrainevet.fr

## Abstract

To date, cryptococcosis remains sporadic in Europe, and this is a case of canine cryptococcosis with ocular and CNS involvement in continental Europe with identification of the organism on cerebral spinal fluid (CSF) cytology and description of the clinical and MRI features, and outcome.

## KEYWORDS

chorioretinitis, cryptococcosis, fluconazole, France, MRI

## 1 | CASE PRESENTATION

### 1.1 | Case history

A three-year-old male Münsterländer dog was presented to the Lorrainevet ophthalmology service to explore vision loss associated with anosmia. The dog had a large hunting activity, he had never travelled outside its region (Lorraine, France), and he was adequately vaccinated and dewormed. This acute loss of vision had started 30 days prior. During the prior examination, the dog was alert without other signs than loss of vision. Bilateral primary chorioretinitis was diagnosed at this time, and the vet diagnosis hypothesis was toxoplasmosis. No clinical improvement was observed with treatment based on prednisolone (Dermipred, Ceva Santé Animale) 1 mg/kg/d and clindamycin (Zodon, Ceva Santé Animale) 11 mg/kg/d.

### 1.2 | General clinical examination

During his first presentation to the ophthalmology service, the animal was ambulatory, slightly lethargic, and

the rest of the clinical examination were within normal limits.

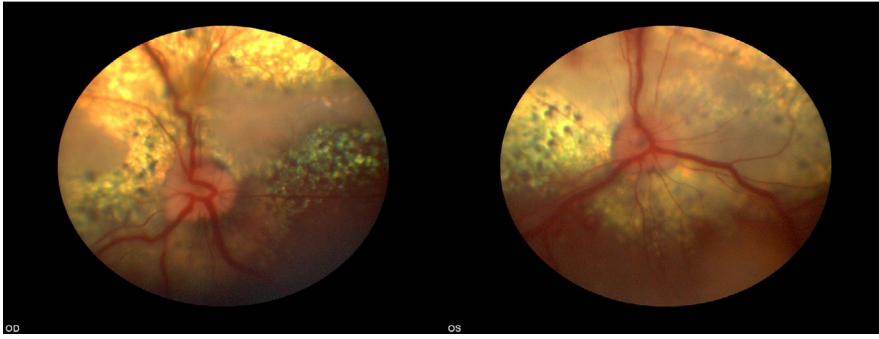
### 1.3 | Ophthalmic examination

Cotton ball test and menace response were absent on the both eyes (OU). Direct and indirect pupillary light reflexes were absent OU. The dazzle reflex was present but slow and incomplete OU. Biomicroscopic examination (Kowa SL17 slit lamp, Kowa) showed minor conjunctival hyperemia and complete mydriasis OU. Fundic examination with indirect binocular ophthalmoscopy (Heine Omega 500, Herrsching; Volk 2.2, Panretinal lens, Mentor) revealed an ill-defined papilledema, vast subretinal granulomas associated with detachment of the retina, as well as numerous small retinal hemorrhages OU (Figure 1). The intraocular pressure (IOP) by rebound tonometry (Tonovet, Icare) was within normal limits (OD: 13 mm Hg, OS: 12 mm Hg).

A diagnosis of hemorrhagic exudative chorioretinitis with partial detachment of the retina and granuloma formation was established.

This is an open access article under the terms of the Creative Commons Attribution-NonCommercial-NoDerivs License, which permits use and distribution in any medium, provided the original work is properly cited, the use is non-commercial and no modifications or adaptations are made.

© 2019 The Authors. *Clinical Case Reports* published by John Wiley & Sons Ltd.



**FIGURE 1** Fundic examination with indirect binocular ophthalmoscopy (Heine Omega 500, Herrsching; Volk 2.2, Panretinal lens, Mentor) revealing an ill-defined papilledema, vast subretinal granulomas associated with detachment of the retina, as well as numerous small retinal hemorrhages OU

## 2 | INVESTIGATIONS

### 2.1 | Complementary examinations

Dark- and light-adapted electroretinogram (ERG) was performed under general anesthesia. The animal was sedated with intravenous propofol 4 mg/kg (PropoVet Multidose, Zoetis) and ketamine 3 mg/kg (Anesketin 100 mg/mL, Dechra), and then, an isoflurane relay was done. Pupils were dilated with topical tropicamide 1%. The electric response of the retinas to light stimulation in photopic and scotopic environment as well as after a period of adaptation during the ERG was absent. ERG confirmed alteration of retinal function.

Twenty-four hours after ERG, the animal started to show central nervous system (CNS) involvement, with symmetrical ataxia and impaired postural responses in all four limbs, and a generalized seizure. The seizure was managed with diazepam (Diazepam, TVM) 1 mg/kg/h. These findings indicated a concurrent central disease.

Complete blood count and biochemical analysis (ie, urea, creatinine, ALP, ALT, glycemia, total protein, albumin, globulin) showed no abnormalities.

Magnetic resonance imaging (MRI) was performed under general anesthesia; the animal was sedated with intravenous butorphanol 0.3 mg/kg (Torbugesic Vet, Zoetis), midazolam 0.2 mg/kg (Midazolam, Mylan), and propofol 4 mg/kg (PropoVet Multidose, Zoetis); and then, an isoflurane relay was done. The MRI of the brain showed a broad-based extra-axial plaque-like lesion in the right olfactory bulb that extended mildly to left, as well as along the rostral aspect of the falx cerebri, and caudally to the optic chiasm, and within the orbital fissure (damage to the emergence of cranial nerves III, IV, and VI and of the ophthalmic branch of the V). The mass was moderately hyperintense in T2w images, isointense in T1w and SST1w precontrast images, and strongly contrast enhancing in T1w and SST1w postcontrast images with well-defined margins (Figure 2). Diffuse mild irregular thickening and strong contrast enhancement of the meninges were noted in T1w postcontrast images, extending across the brain (Figure 3).

Following MRI, a CSF sample was obtained from the cerebellomedullary cistern. The fluid was characterized by

hyperproteinorachie at 1.2 g/L (reference limit < 0.2 g/L) and the presence of an abundant population of inflammatory cells dominated by clearly activated macrophages (46%) and lobed polymorphonuclear neutrophils (44%). No blood contamination was noted (0 red blood cells; reference limit, <30 red blood cells/mL; Figure 4).

Cerebral spinal fluid cytology allowed the direct observation of eosinophilic spherical elements of variable size surrounded by a thick refractive cell wall that sometimes exhibited budding evaginations. These elements, both free and intracellular (macrophages), were most likely consistent with cryptococci (Figure 5).

Assaying for *Cryptococcus neoformans* capsular antigens in serum by a latex agglutination testing (VEBIO veterinary biology) was positive at a dilution of 1/100.

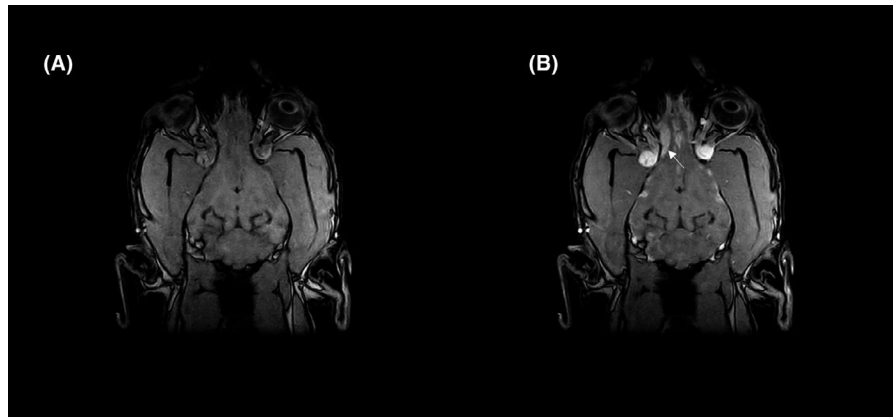
## 3 | DIFFERENTIAL DIAGNOSIS

The differential diagnoses for this bilateral chorioretinitis associated with an extra-axial mass and diffuse meningitis were most likely a fungal disease (aspergillosis, cryptococcosis), or a neoplastic process (round cell tumors, such as lymphoma or histiocytic sarcoma, or less likely metastatic), another infectious disease (toxoplasmosis, neosporosis), or much less likely an immune-mediated disease.

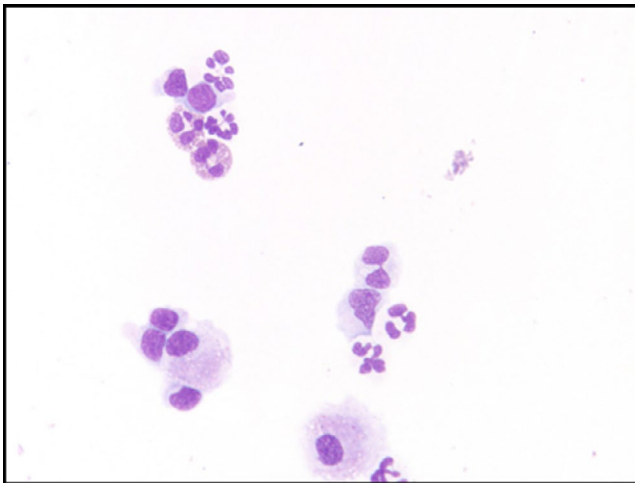
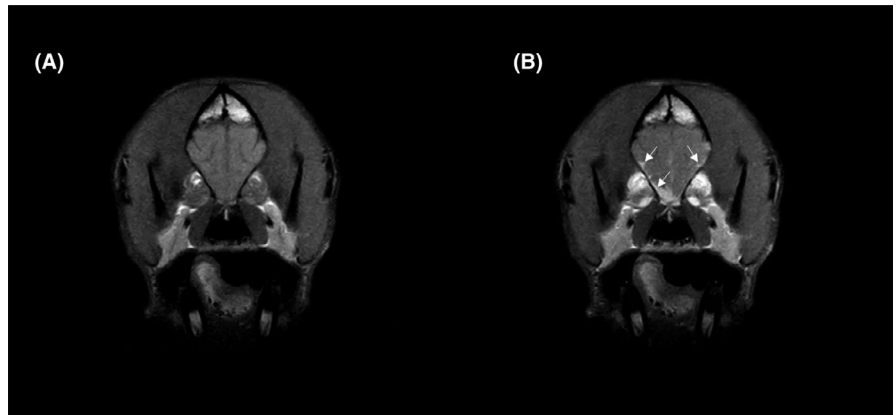
## 4 | TREATMENT

The dog was hospitalized for 15 days. During the first four days, the dog was nonambulatory. Treatment with fluconazole (Triflucan 200 mg, Pfizer) per os, at a dosage of 5 mg/kg/BID, was established. Fluid therapy with Ringer's lactate at 2 ml/kg/h was also provided. The dog recovered its appetite after two days of hospitalization and was again ambulatory after four days. After four days of hospitalization, prednisolone treatment (Dermipred, Ceva Santé Animale) was initiated at 1 mg/kg/SID. On the sixth day of hospitalization, a complete blood count and biochemistry analysis (APL, ALT, total protein and albumin levels) revealed no abnormalities. The dog was discharged from

**FIGURE 2** Dorsal pre- (A) and postcontrast (B) magnetic resonance images of the brain showing a well-defined plaque-like lesion (arrow) in the right olfactory bulb that extended to the left and along the falx cerebri, which was isointense in SST1w precontrast sequences, and strongly enhancing in SST1w postcontrast sequence



**FIGURE 3** Transverse T1w pre- (A) and postcontrast (B) image of the forebrain showing a thin and strong meningeal enhancement encephala (arrows)



**FIGURE 4** Photomicrograph of a cytospin preparation of the cerebrospinal fluid, revealing a marked inflammatory pleocytosis (macrophages, neutrophils, and eosinophils)

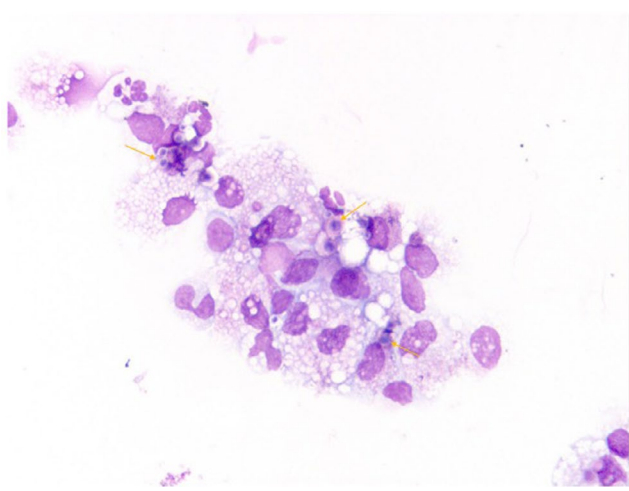
the hospital after 15 days of treatment, blind and slightly ataxic but in good general condition. Systemic corticosteroids were gradually discontinued (1 mg/kg/SID for 7 days, then 0.5 mg/kg/SID for seven days, and then 0.5 mg/kg every two days for 7 days), and only fluconazole (Triflucan 200 mg, Pfizer) was continued at home at the dosage of 5 mg/kg/BID.

## 5 | OUTCOME AND FOLLOW-UP

A complete clinical and ophthalmological examination as well as the liver enzyme levels (ALP and ALT) was performed each month and did not reveal any abnormalities. After six months of treatment with fluconazole (Triflucan 200 mg, Pfizer) at the same dose and frequency, the dog was alert and had no neurological signs. Cotton ball test and menace response were absent OU. Direct and indirect pupillary light reflexes were present, slowed down, and incomplete OU. Indirect ophthalmoscopic examination revealed a decrease of the retinal hemorrhages and persistence of the subretinal granulomas and several small, pigmented nodules scattered throughout the tapetal fundus OU.

## 6 | DISCUSSION

Cryptococcosis is a systemic fungal infection of global importance occurring in humans as well as in a large variety of animal species including dogs.<sup>1</sup> It is mainly due to two species of encapsulated yeasts, ranging from 3.5 to 7  $\mu\text{m}$  in size, that are soil saprophytes: *Cryptococcus neoformans* (*C neoformans*) and *Cryptococcus gattii* (*C gattii*).<sup>2</sup> Geographically, it is found particularly in North America



**FIGURE 5** Photomicrograph of a cytospin preparation of the cerebrospinal fluid showing several yeast forms consistent with *Cryptococcus* species (arrows)

(Southern California,<sup>3</sup> Western British Columbia<sup>4</sup>), and on the east coast of Australia,<sup>5</sup> while it has remained sporadic to date in Europe.<sup>6,7</sup> The incidence of cryptococcosis is lower in dogs than in cats, with a retrospective study indicating a risk of infection of <13 out of 100 000.<sup>8</sup> It particularly affects dogs under 6 years old, and no gender-based predisposition has been reported.<sup>9</sup> American Cocker Spaniels,<sup>10</sup> Great Danes,<sup>11</sup> Doberman Pinschers, and German Shepherds<sup>5</sup> appear to be overrepresented.

Cryptococcosis most often occurs by inhalation of fungal yeasts in suspension in the air that then lodge in the nasal, paranasal, and pulmonary tissues before spreading more widely by blood or direct extension.<sup>12</sup> The polysaccharide capsule that covers these yeasts, which is useful for the diagnosis, protects them from the immune system of the host.<sup>13</sup> Although dissemination can affect any organ, the central nervous system (CNS), the eyes, and the skin are most commonly affected.<sup>14</sup> In our case, invasion of the right olfactory bulb, visualized on the MRI, suggests a direct contamination across the cribriform plate.<sup>10</sup> The eyes are affected in approximately 20 to 40% of dogs affected with cryptococcosis.<sup>14</sup> The most commonly observed ocular abnormalities are multifocal granulomatous lesions of the choroid that can produce a subretinal exudate with secondary retinal detachment,<sup>15</sup> retinal hemorrhages, optic neuritis from progression of the chorioretinitis to the optic nerve<sup>16</sup> or from progression of the meningitis to the optic nerve,<sup>14</sup> and more rarely a retrobulbar abscess with destruction of peripheral tissues.<sup>1</sup>

Definitive diagnosis of systemic cryptococcosis is based on direct observation of the microorganisms and/or a positive fungal culture, and/or a significantly positive latex cryptococcal antigen agglutination testing.<sup>4</sup> Two of these three methods were used to confirm our diagnostic hypothesis. The microorganisms can be visualized in 90% of CSF samples

when there are neurological manifestations.<sup>17</sup> When they are not identified, a fungal culture can be performed starting with the infected tissues, CSF, or blood, on Sabouraud dextrose agar with a growth delay of two to 10 days.<sup>4</sup> The latex cryptococcal antigen agglutination testing (LCAT) measures the capsular cryptococcal polysaccharide antigen with both high specificity and sensitivity<sup>18</sup> for the diagnosis of *Cryptococcus* infection. Very recently, a point-of-care cryptococcal antigen lateral flow assay (LFA) was used to diagnose cryptococcosis in dogs, and the test is suitable for excluding clinical cryptococcosis, but confirmatory testing of positive results using the LCAT is recommended.<sup>19</sup> The neurological symptoms led us to investigate yeasts in the CSF, but it would have been wise to perform an intravitreal puncture to confirm the cryptococcal nature of the chorioretinitis,<sup>15</sup> as the microorganisms are found there in 75% of cases when there is ocular involvement.<sup>14</sup> A PCR-based test has been used in humans,<sup>20</sup> but its use has not been reported in dogs. Identification of the infecting species was not performed in this case, although it would have been of epidemiological relevance.

The usefulness of brain imaging in the diagnosis of CNS cryptococcosis remains limited. Indeed, in humans, the MRI is normal in 50% of cases.<sup>21</sup> The lesions are nonspecific and are mainly represented by the formation of parenchymal masses, isolated or diffuse lesions of the meninges. The MRI lesions observed in our case are similar to those described in the literature for dogs.<sup>3,6,22</sup> Ocular involvement often occurs with neurological involvement in dogs. In case of suspicion of cryptococcosis infection after the ophthalmological examination, the authors advise to perform a serum latex agglutination test in first intention. If the latter is positive, an MRI examination of the brain is then recommended, as CNS lesions can be present before the onset of neurological signs. As cryptococcosis can also involve the spinal cord, MRI should not be limited to the brain, if the neurological signs are indicative of a spinal cord lesion.<sup>7,23</sup>

Cryptococcosis remains hard to treat in dogs and cats, with the treatment consisting of the use of systemic antifungals that can be used as monotherapy or in combination. There is, however, not a clearly established protocol. Among the most often used antifungals are amphotericin B, flucytosine, fluconazole, and itraconazole. Fluconazole has proven to be effective for treating cryptococcosis in humans and animals,<sup>22</sup> inhibiting the synthesis of ergosterol, the main sterol of the fungal cellular membrane. Thus, it is a fungistatic, although it also exhibits fungicidal properties for cryptococcosis, and its good penetration across the blood-brain barrier makes it a treatment of choice in case of CNS involvement.<sup>14</sup> As azoles have hepatotoxic properties, it is recommended to monitor liver parameters during the treatment.<sup>4</sup> However, fluconazole was used at a dose of 5 mg/kg/BID<sup>4</sup> in a recent clinical case during 5 years without impairment of liver function.<sup>23</sup> In the beginning, the antifungal treatment needs to be monitored closely (hence the merit of hospitalization), as the death of fungal cells can

increase the inflammatory response at the level of the eyes and the CNS.<sup>15</sup> Although rare in Europe, this clinical case brings out the importance of an etiological diagnosis prior to implementation of a symptomatic treatment of chorioretinitis. Indeed, the use of a treatment based on glucocorticoids prior to implementation of an antifungal treatment, as is was the case for our animal, can substantially exacerbate progression of the disease.<sup>5</sup> Prednisone at 1 mg/kg/SID can be added to the therapeutic regime after implementation of the antifungal treatment in case of intraocular inflammation.<sup>15</sup>

Despite establishment of a suitable antifungal treatment, the prognosis remains poor. In a study of dogs with CNS involvement, the median survival time after diagnosis was 12 days in those receiving antifungal treatment. This median increased to 190 days for dogs who survived at least four days after the diagnosis.<sup>3</sup> In this case, the dog was still alive after 270 days of treatment. Resolution of the clinical signs does not imply the eradication of the infection, as improvement occurs well before all of the viable cryptococci have been eliminated from the tissues of the host.<sup>5</sup> A relapse can occur months if not even years after an apparent clinical “cure,” and this is so even when the antifungal treatment is continued.<sup>23</sup> Antigen titers should ideally be monitored every two or three months when the animal is receiving antifungal treatment, and for at least a year after treatment is stopped.<sup>8</sup> In this case, for financial reasons, the antigen titer had still not been reevaluated since the beginning of the treatment. Lastly, in humans the prognosis is directly reevaluated by the delay between the onset of clinical signs and the diagnosis.<sup>24</sup>

## 7 | TAKE HOME MESSAGES

Even though cryptococcosis is currently sporadic in Europe<sup>6</sup> and particularly in France, it needs to be part of the differential diagnostic in cases of bilateral chorioretinitis, particularly when it is granulomatous.

The definitive diagnosis of cryptococcosis is based on direct observation of the microorganisms, on a positive fungal culture, and/or on a positive latex agglutination test.

The etiological diagnosis with chorioretinitis is important as the use of certain symptomatic treatments such as glucocorticoids can accelerate progression of the underlying disease process, in case of infection.

The prognosis for cryptococcosis is poor and directly correlates with the extent and the magnitude of the disease at the time of the diagnosis. Implementation of an adequate treatment and rigorous monitoring can, however, quite substantially increase the chances of survival.

## CONFLICT OF INTEREST

None declared.

## AUTHOR CONTRIBUTIONS

JBB: involved in main work and manuscript writing. ASP: involved in manuscript revision. EG: served as ECVDI specialist and read and interpreted the MRI results. AD: served as ECVDI specialist and revised the manuscript. OB: served as Ophthalmology DESV specialist, is in charge of the patient, and approved the final version for submission.

## ORCID

Jean-Baptiste Barbry  <https://orcid.org/0000-0003-3565-4365>

Anne Sophie Poinsard  <https://orcid.org/0000-0002-8933-4458>

Olivier Balland  <https://orcid.org/0000-0003-1672-9018>

## REFERENCES

- Jacobs GJ, Medleau L. Cryptococcosis. In: Greene CE, ed. *Infectious diseases of the dog and cat*. Philadelphia: WB Saunders Co; 1998:383-390.
- Malik R, Krockenberger M, O'Brien C, et al. Cryptococcosis. In: Green CE, ed. *Infectious diseases of the dog and cat*, 3rd edn. St. Louis: Elsevier Saunders. 2006:584-598.
- Sykes JE, Sturges BK, Cannon MS, et al. Clinical signs, imaging features, neuropathology, and outcome in cats and dogs with central nervous system cryptococcosis from California. *J Vet Intern Med*. 2010;24(6):1427-1438.
- Vorathavorn VI, Sykes JE, Feldman DG. Cryptococcosis as an emerging systemic mycosis in dogs. *J Vet Emerg Crit Care*. 2013;23(5):489-497.
- O'Brien CR, Krockenberger MB, Wigney DI, et al. Retrospective study of feline and canine cryptococcosis in Australia from 1981 to 2001: 195 cases. *Med Mycol*. 2004;42(5):449-460.
- Robson K, Smith PM. Cryptococcal meningoencephalitis in a dog. *Veterinary Record*. 2011;168(20):538.
- Belluco S, Thibaud JL, Guillot J, et al. Spinal cryptococcoma in an immunocompetent cat. *J Comp Pathol*. 2008;139(4):246-251.
- Berthelin CF, Bailey CS, Kass PH, et al. Cryptococcosis of the nervous system in dogs. Part 1: epidemiologic, clinical and neuropathologic features. *Prog Vet Neurol*. 1994;5:88-97.
- Lester SJ, Malik R, Bartlett KH, et al. Cryptococcosis: update and emergence of *Cryptococcus gattii*. *Vet Clin Pathol*. 2011;40(1):4-17.
- Trivedi SR, Sykes JE, Cannon MS, et al. Clinical features and epidemiology of cryptococcosis in cats and dogs in California: 93 cases (1988–2010). *J Am Vet Med Assoc*. 2011;239(3):357-369.
- Malik R, Dill-Macky E, Martin P, et al. Cryptococcosis in dogs: a retrospective study of 20 consecutive cases. *J Med Vet Mycol*. 1995;33(5):291-297.
- Neilson JB, Fromtling RA, Bulmer GS. Cryptococcus neoformans: size range of infectious particles from aerosolized soil. *Infect Immun*. 1977;17(3):634-638.
- Buchanan KL, Murphy JW. What makes *Cryptococcus neoformans* a pathogen? *Emerg Infect Dis*. 1998;4(1):71-83.

14. Taboada J, Grooters AM. Cryptococcosis. In Ettinger SJ, Feldman EC, eds. *Textbook of Veterinary Internal Medicine*, 7th edn. St. Louis, MO: Saunders Elsevier; 2010:988-992.
15. Krohne SG. Canine systemic fungal infections. *Vet Clin North Am Small Anim Pract*. 2000;30(5):1063-1090.
16. Martin CL. Ocular manifestations of systemic disease. In: Gelatt KN, ed. *Veterinary Ophthalmology*, 3rd edn. Baltimore, MD: Lippincott Williams & Wilkins; 1999:1401-1448.
17. Berthelin CF, Legendre AM, Bailey CS, et al. Cryptococcosis of the nervous system in dogs. Part 2: diagnosis, treatment, monitoring, and prognosis. *Prog Vet Neurol*. 1994;5:136-146.
18. Malik R, McPetrie R, Wigney DI, et al. A latex cryptococcal antigen agglutination test for diagnosis and monitoring of chemotherapy. *Aust Vet J*. 1996;74(5):358-364.
19. Krockenberger MB, Marschner C, Martin P, et al. Comparing immunochromatography with latex antigen agglutination testing for the diagnosis of cryptococcosis in cats, dogs and koalas. *Med Mycol*. 2019;1-8.
20. Rappelli P, Are R, Casu G, et al. Development of a nested PCR for detection of *Cryptococcus neoformans* in cerebrospinal fluid. *J Clin Microbiol*. 1998;36(11):3438-3440.
21. Bretaudeau K, Eloy O, Richer A, et al. Cryptococcal meningo-encephalitis in an apparently immunocompetent patient. *Rev Neurol (Paris)*. 2006;162(2):233-237.
22. Tiches D, Vite CH, Dayrell-Hart B, et al. A case of canine central nervous system cryptococcosis: management with fluconazole. *J Am Anim Hosp Assoc*. 1998;34(2):145-151.
23. Galban E, Perkins J. Arachnoid diverticulum diagnosis following treatment of cryptococcal meningitis in a dog. *Clin Case Rep*. 2018;6(4):557-563.
24. Aye C, Henderson A, Yu H, Norton R. Cryptococcosis - the impact of delay to diagnosis. *Clin Microbiol Infect*. 2016;22(7):632-635.

**How to cite this article:** Barbry J-B, Poinard AS, Gomes E, Durand A, Balland O. Cryptococcosis with ocular and central nervous system involvement in a 3-year-old dog. *Clin Case Rep*. 2019;7:2349–2354. <https://doi.org/10.1002/ccr3.2491>