

Detection of specific *Treponema* species and *Dichelobacter nodosus* from digital dermatitis (Mortellaro's disease) lesions in Swiss cattle

M. Alsaad^{1,2}, I. Locher^{1,2}, J. Jores², P. Grimm³, I. Brodard², A. Steiner¹, P. Kuhnert²

¹Clinic for Ruminants, Vetsuisse-Faculty Bern, University of Bern; ²Institute of Veterinary Bacteriology, Vetsuisse-Faculty Bern, University of Bern; ³Clinic for Ruminants and Swiss Bovine Health Service (RGD)

Summary

The aim of this study was to determine the prevalence of the three *Treponema* species as well as *D. nodosus* in Digital dermatitis (DD) and slurry of Swiss cattle using PCR. A total of 86 specimens from 24 farms were enrolled in the study. Slurry samples from 21 DD-affected and one unaffected farm were collected to assess the potential of environmental transmission. Nested and real-time PCR were performed from the specimens to detect *Treponema* species and *D. nodosus*, respectively. The DD-stages were positive for at least one or more of the DD-associated *Treponema* species in 50 of 61 cases (82.0%) and in 9 of 25 cases (36.0%) in unaffected animals. Infected animals with small focal active lesions showed a significantly lower prevalence (14.8%) compared to the other DD stages (67.2%; $P=0.011$). Most prevalent was *T. phagedenis* (65.1%). *D. nodosus* was detected in 51.8% of clinical DD lesions and 24.1% in unaffected cases, but its presence was not significantly associated with the various DD-stages. All samples positive for *D. nodosus* contained the acid protease gene *aprB2* but were negative for *aprV2*, the latter associated with virulence in sheep foot rot. Control farms were negative for all DD-associated *Treponema* species while positive for *aprB2* and negative for *aprV2*. The presence of *aprB2* suggests it is ubiquitous in the animal environment. With respect to the slurry samples, three out of 21 specimens (14.3%) were positive for one or more of the DD-associated *Treponema* species and eleven out of 21 specimens (52.4%) were positive for *aprB2* and negative for *aprV2* of *D. nodosus*. In conclusion, an association was found between the presence of clinical DD and specific *Treponema* species, while for *D. nodosus* no such link with DD lesions could be observed.

Keywords: Cattle, *Dichelobacter nodosus*, *Treponema* spp., Digital Dermatitis, PCR

Nachweis spezifischer *Treponema* Spezies und von *Dichelobacter nodosus* aus Läsionen von *Dermatitis digitalis* (Mortellaro'sche Krankheit) bei Rindern in der Schweiz

Dermatitis digitalis (DD) der Rinder ist eine multifaktorielle Infektionskrankheit, die sich zu einem bedeutenden wirtschaftlichen und weltweit wichtigen Tierwohl-Problem entwickelt hat. Drei *Treponema* Spezies *T. pedis*, *T. medium* und *T. phagedenis* sind mit DD assoziiert, jedoch ist die Prävalenz der Erreger bei Rindern in der Schweiz bislang nicht untersucht. Es wurde zudem berichtet, dass *Dichelobacter nodosus* zur Entwicklung von DD beiträgt.

Ziel dieser Studie war, die Prävalenz der drei oben genannten *Treponema* Spezies, sowie von *D. nodosus* in DD Läsionen und Umweltproben mittels spezifischer PCR Verfahren zu bestimmen. Zweiundzwanzig Betriebe mit und zwei Betriebe ohne klinische Anzeichen von DD bei Rindern wurden in die Studie aufgenommen. Insgesamt wurden 86 Proben von verschiedenen DD-Stadien gesammelt (M1, n = 15; M2, n = 19; M3, n = 9; M4, n = 2; M4.1, n = 16 und M5, n = 25; M1-M5 = Stadien der DD). Diese wurden mittels steriler, trockener Wattestäbchen direkt von der Oberfläche der Läsionen genommen.

Am häufigsten wurde *T. phagedenis* (65,1%) nachgewiesen. *D. nodosus* wurde in 51,8% der klinischen DD-Läsionen (M1 bis M4.1) und in 24,1% der M5 Proben (klinisch gesund) nachgewiesen. Das Vorkommen der verschiedenen Treponemen korrelierte nicht mit den DD-Stadien. Alle für *D. nodosus* positiv getesteten Proben waren *aprB2*-positiv und negativ für *aprV2*. *aprV2*-positive *D. nodosus* Stämme verursachen Moderhinke beim Schaf. DD-freie Betriebe waren negativ für

<https://doi.org/10.17236/sat00201>

Received: 19.09.2018
Accepted: 28.01.2019

Detection of specific *Treponema* species and *Dichelobacter nodosus* from digital dermatitis (Mortellaro's disease) lesions in Swiss cattle

M. Alsaad et al.

alle DD-assoziierten *Treponema* Spezies, aber positiv für *aprB2* und durchwegs negativ für *aprV2*. Bei den Umweltproben waren drei der 21 Proben (14,3%) aus Betrieben mit Rindern, welche an DD erkrankt waren positiv für mindestens eine oder mehrere der DD-assoziierten *Treponema* Spezies, und 11 von 21 Proben (52,4%) waren positiv für *aprB2*. Alle untersuchten Proben waren negativ für *aprV2* von *D. nodosus*.

Abschliessend kann festgehalten werden, dass ein Zusammenhang besteht zwischen DD-Läsionen und dem Nachweis von einer oder mehreren spezifischen *Treponema* Spezies. Bei *D. nodosus* konnte keine Assoziation zum Auftreten von DD-Läsionen beobachtet werden. Diese Studie zeigt erstmals, dass die drei *Treponema* Spezies *T. pedis*, *T. medium* und *T. phagedenis* auch in der Schweiz an der Mortellaro'schen Krankheit beteiligt sind.

Schlüsselwörter: Rind, Lahmheit, Klauen, *Dichelobacter nodosus*, *Treponema* spp., Dermatitis digitalis

Introduction

Digital dermatitis (DD) (also known as Hairy Foot Warts, Strawberry Foot Rot, Mortellaro's Disease, Raspberry or Verrucose Dermatitis) is an infectious acute or chronic ulcerative foot disease, initially reported in Italy¹. DD lesions typically develop on the plantar skin, proximal to the bulb of the heel, or occasionally, within the interdigital cleft. The disease has a big impact on the well-being of animals, as well as the productivity of dairy farms. Losses are caused by high treatment costs including the application of antibiotics, decreased milk production and reduced reproductive efficiency in affected cattle^{2,3}. Compared to other foot diseases, DD causes the highest financial impact, as the incidence rate of the clinically relevant M2 stage within a herd is high⁴. The average costs per case of DD were estimated to amount in total to 133 USD, made up of treatment costs (42%), followed by the consequences of decreased fertility (31%) and milk loss (27%)³. A more recent study showed that even DD lesions smaller than 2 cm in diameter can cause lameness and production losses⁵.

In recent years, DD has become an emerging issue in dairy herds worldwide with increasing prevalence in many countries^{6,7}. A cross-sectional study conducted during routine claw-trimming of 1,449 Swiss dairy cows from June 2010 until February 2011 estimated the prevalence of DD to be 29.1% at the cow and 73.1% at herd level⁸. Poor environmental conditions of housed cattle are likely to result in increased risk of contracting DD, as continuous exposure of feet to moisture and poor hygiene conditions are considered predisposing factors for DD^{9,10}.

DD is characterized by an inflammatory dermatitis of the skin with necrosis of infected tissue¹¹. Histopathologically, DD lesions show hyperplasia of the epidermis with hyperkeratosis, loss of the stratum corneum and/or granulosum, necrosis of the epidermis leading to ulceration, colonies of spirochaetal bacteria, and a mixed inflammation of varying severity in the dermis with exocytosis into the epidermis^{2,12,13}. The etiology of DD is still not completely resolved. Studies on the pathogenesis of DD support the hypothesis that bacteria from the genus *Treponema* appear to be the most commonly identified organisms present and involved in DD lesions^{14,15}. *Treponema* species are gram-negative anaerobic spirochaetes that are very difficult to culture¹⁶. Attempts to isolate *Treponema* from DD lesions are still mostly unsuccessful due to their fastidious nature and the high level of bacterial contamination of specimens¹⁷. However, a limited number of *Treponema* species from DD lesions have been successfully isolated as shown in earlier studies in the United Kingdom^{14,18}. Isolates from DD lesions could be attributed to three distinct phylogroups represented by the species *Treponema pedis*, *Treponema phagedenis*, and *Treponema medium*¹⁷⁻¹⁹. The presence of one or any combination of these three species is associated with clinical symptoms of DD as documented by several PCR-based investigations^{18,20}.

Other bacteria, including *Fusobacterium necrophorum*, *Porphyromonas* species, *Bacteroides* species, *Campylobacter* species, *Guggenheimella* species, *Borrelia* species, and *Dichelobacter nodosus*, have also been found in DD lesions, suggesting a polymicrobial etiology of *Treponema* species and other microbes²¹⁻²³.

D. nodosus is the main pathogen involved in the multifactorial disease of ovine foot rot. We recently established a competitive real-time (rt)PCR distinguishing between the protease genes *aprV2* and *aprB2*, thereby allowing the direct detection and differentiation of ovine virulent and benign strains of *D. nodosus*, respectively²⁴.

Identification of the *Treponema* species associated with DD lesions in Switzerland would enable better understanding of the epidemiology of DD, facilitate efficient treatment campaigns and subsequently control DD. In the present study, we determined the prevalence of *T. pedis*, *T. phagedenis*, and *T. medium* in healthy and DD-affected animals as well as slurry from the environment of DD-positive farms in different regions of Switzerland using PCR-based methods. Farms without clinical findings of DD were included as a control group and examined using the same methodology.

Animals, Material and Methods

Ethics statement

The study protocol was approved by the animal experimentation committee of the Swiss cantons of Aargau, Basel, Bern, Fribourg, Graubünden, Jura, Luzern, Nidwalden, St. Gallen, Schwyz, Solothurn, Thurgau, Vaud, and Zürich (permission BE 62/15+).

Collection of swab samples and DD lesion scoring

A total of 22 farms with clinical DD (14 free-stall and 8 tie-stall) and two farms without clinical DD (one free-stall and one tie-stall) were enrolled in the study (Fig. 1) and sampled between November 2015 and June 2018. Twenty two dairy farms and 2 beef cattle farms consisting of different breeds were involved in this study. The cows were allowed daily access to pasture during the grazing season (April to October) and weekly access to an outside yard (mastic asphalt) during the winter season (November to March).

The DD lesions were scored by a trained and experienced study author (MA) according to Döpfer et al.²⁵ and extended by Berry et al.²⁶. Briefly, M1 ("M" refers

Detection of specific *Treponema* species and *Dichelobacter nodosus* from digital dermatitis (Mortellaro's disease) lesions in Swiss cattle

M. Alsaad et al.

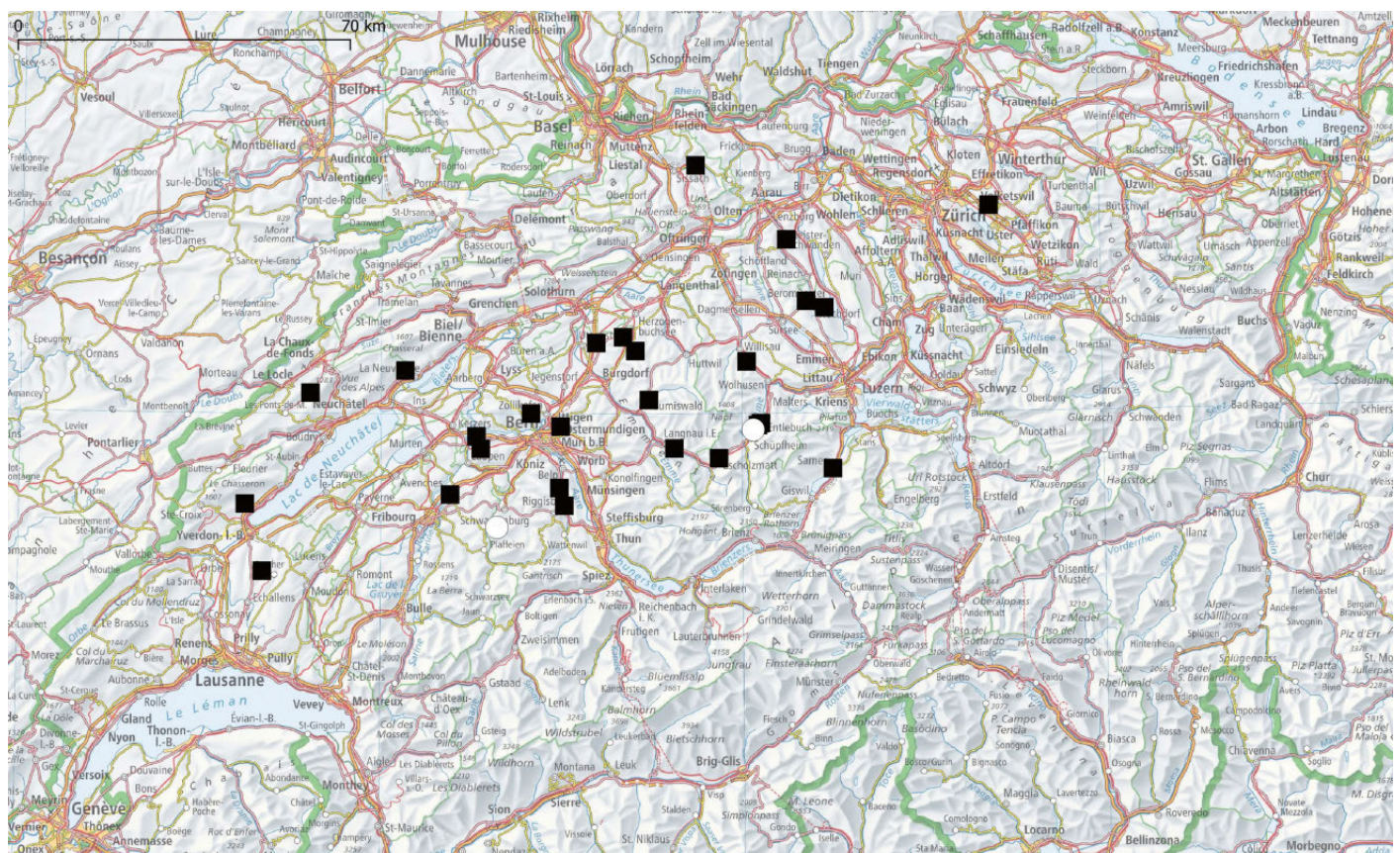


Fig. 1: Geographical distribution of farms with clinical Digital Dermatitis (DD) (black squares) and farms without clinical DD (white circles) in Switzerland. The map was created with QGIS v2.8.1 (<https://www.qgis.org/de/site/>) using postal codes of farm locations. Postal code 6166 represents 3 farms and 4466 corresponds to 2 farms.

Detection of specific *Treponema* species and *Dichelobacter nodosus* from digital dermatitis (Mortellaro's disease) lesions in Swiss cattle

M. Alsaad et al.

to Mortellaro's initial description of the lesion) describes infected animals with small (<2 cm diameter) focal active lesions; M2 infected animals with larger (>2 cm diameter) classic active ulcers; M3 healing scabbed lesions, and M4 represents chronic stages of infection, characterized by dyskeratosis or surface proliferation; M4.1 refers to a chronic stage with small active M1 lesions, and M5 describes unaffected animals with no lesions (normal skin). In addition, the farmers were asked about the current status of DD on their farms before the sampling was performed (DD present, DD not present or DD suspected).

A total of 86 samples were collected (M1, n=15; M2, n=19; M3, n=9; M4, n=2 and M4.1, n=16 and M5, n= 25) using sterile, dry cotton swabs. The individual samples were taken by rubbing the swab over the lesion (M1 to M4.1) and from the interdigital space in cases of clinically unaffected tissue (M5).

Slurry samples (n= 21) from DD-affected farms and one unaffected farm with free-stall accommodation were collected with sterile, dry cotton swabs and pooled from different locations on the floor: (i) from the floor of the drinking area, (ii) from below the cow brush, (iii) from below the concentrate feeding area and (iv) from the milking robot in cases where an automatic milking system was present. In tie-stall farms (data available only from DD-affected farms), the swabs were collected from different locations on the floor at the position of the hind limbs. Slurry samples (but no feet samples) were additionally collected from 8 farms with DD. DD was diagnosed in these farms by clinical inspection of the feet in the claw trimming chute (n=6) or in the milking parlor (n=2).

The individual swabs were immediately placed into an Eppendorf tube containing 1 ml SV lysis buffer (4 M guanidine thiocyanate, 0.01M Tris-HCl, 1% β -mercaptoethanol) for 2 min with gentle stirring. The swab was then discarded and the remaining lysate transferred to the laboratory for DNA extraction within 1 week of sampling.

Laboratory analyses

DNA extraction

DNA extraction was performed from 500 μ l lysate according to an adapted protocol of Stäuble et al.²⁴ using a semi-automated extraction robot (KingFisher™ Duo-Prime, Thermo Fisher Scientific). The DNA was eluted in 60 μ l H₂O and stored at -20°C until further processing.

PCR assays

General *Treponema* and species-specific *Treponema* PCR.

A general *Treponema* PCR, as well as specific nested PCR assays for *T. medium*, *T. phagedenis*, and *T. pedis*, were performed according to Evans et al.¹⁴ with the exception of the 16S rRNA gene PCR which was performed utilizing primers 16SUNI-L and 16SUNI-R as published elsewhere²⁷. PCR master-mix contained 1 \times FIREPol® Master Mix Ready to load with 12.5 mM MgCl₂ (Solis Biodyne) and 0.4 mM of each primer. For general *Treponema* PCR and the initial 16S rRNA gene amplification, 2 μ l DNA template was added to 28 μ l master-mix. Temperature cycling for these two PCRs entailed an initial denaturation step at 95°C for 3 min followed by 35 cycles of 95°C for 30 s, annealing for 30 s at 53°C and extension at 72°C for 90 s. A final elongation step at 72°C for 7 min was included.

The nested species-specific *Treponema* PCRs were done using 29 μ l master-mix and 1 μ l PCR product as a template from the initial reaction of 16S rRNA gene amplification (see above). Temperature cycling entailed an initial denaturation step at 95°C for 3 min, followed by 40 cycles of 95°C for 30 s, annealing for 30 s either at 68°C for *T. medium* and *T. pedis* primers, or at 64°C for *T. phagedenis* primers and extension at 72°C for 1 min. A final elongation step at 72°C for 7 min was included. To ensure and to validate each PCR assay, H₂O was used as a negative control and the corresponding positive field samples were used as positive controls. PCR products were visualized by gel electrophoresis on submarine 1% agarose gels after staining with ethidium bromide. Positive reactions were determined by the presence of bands of the appropriate sizes using 100 bp ladder as a molecular size marker.

Detection of *D. nodosus*:

Detection and virulotyping of *D. nodosus* was done using the competitive rtPCR according to Stäuble et al.²⁴. This rtPCR distinguished between the presence of the gene *aprV2* encoding the thermostable protease AprV2, and the gene *aprB2* coding for the thermosensitive protease AprB2 of *D. nodosus*. All rtPCR reactions were analyzed in duplicate, with a mean threshold cycle (Ct) value of <40 rated positive.

Statistical analysis

Chi-square test (with Pearson's Chi-Square) was used to investigate associations between the presence of *Treponema* species, *aprB2*-positive *D. nodosus* and the DD status of the animals. In all analyses, an associated probability (*p*-value) of 0.05 was considered significant. All the data were analyzed using the software package NCSS¹⁰ (NCSS LLC, Kaysville, UT).

Table 1: PCR detection of *T. medium*, *T. phagedenis*, *T. pedis* and *aprB2*-positive *D. nodosus* in DD specimens swabbed from lesions in Swiss cattle.

¹ DD-stage	<i>T. medium</i>	<i>T. phagedenis</i>	<i>T. pedis</i>	Presence of at least one DD-associated species	<i>aprB2</i> -positive <i>D. nodosus</i>
M1	2/15 (13.3%)	9/15 (60%)	8/15 (53.3%)	9/15 (60%)	13/15 (86.7%)
M2	13/19 (68.4%)	15/19 (79%)	13/19 (68.4%)	16/19 (84.2%)	11/19 (57.9%)
M3	5/9 (55.6%)	8/9 (88.9%)	4/9 (44.4%)	8/9 (88.9%)	8/8 (100%)
M4	2/2 (100%)	2/2 (100%)	2/2 (100%)	2/2 (100%)	2/2 (100%)
M4.1	12/16 (75%)	15/16 (93.8%)	13/16 (81.3%)	15/16 (93.8%)	9/14 (64.3%)
M5	4/25 (16%)	7/25 (28%)	6/25 (24%)	9/25 (36%)	20/25 (80%)
P-value	0.00005	0.00009	0.0038	0.00045	0.1179

¹ Macroscopic classification of bovine digital dermatitis lesions according to Döpfer et al.²⁵ and extended by Berry et al.²⁶.

Detection of specific *Treponema* species and *Dichelobacter nodosus* from digital dermatitis (Mortellaro's disease) lesions in Swiss cattle

M. Alsaad et al.

Results

DD presence on farms

In the DD positive farms (n=22), 11 farmers were aware of the disease, 8 were completely unaware of the presence of clinical DD on their farm, 2 suspected the presence of clinical DD, but were not sure and information from 1 farm was not documented and is therefore missing.

Detection of *Treponema* species and *D. nodosus*

Feet samples

The results of specific *Treponema* species PCR assays of DD stages M1 to M5 are shown in Table 1. The DD-stages M1 to M4.1 (affected skin) and M5 (healthy skin) were positive for at least one or more of the DD-associated *Treponema* species (50/61; (81.97%)) and (9/25; (36%)), respectively ($P < 0.0001$). *Treponema phagedenis* was the most prevalent species detected (65.12%). When only evaluating samples taken from clinically affected skin, M1 showed lower prevalence (14.7%) when compared to the other DD stages (M2, M3, M4, and M4.1) (67.2%) ($P=0.011$).

Chi-square analysis showed that the three DD-associated *Treponema* species were unequally distributed among the DD stages. Positive samples for *aprB2* of *D. nodosus* were not significantly associated with DD-stages. The two control farms were negative for all DD-associated *Treponema* species, while *aprB2*-positive in 77.8%. The *aprV2* gene of *D. nodosus* was not detected in any of the feet investigated.

Slurry samples

Three out of 21 slurry specimens (14.3%) were positive for at least one or more of the DD-associated *Treponema* species (2/21 [9.5%] for *T. medium* and 1/21 [4.8%] for *T. phagedenis*), while 52.4% (11/21) were positive for *aprB2* and all were negative for *aprV2* of *D. nodosus*. DD *Treponema* species and *aprB2* positive *D. nodosus* were not identified in the slurry of the unaffected DD farm.

Of the total 107 samples tested, 87 (81.3%) showed consistent results with the general *Treponema* PCR and the specific *Treponema* PCRs. In 10 cases (4 from the same farm with stage M5, 5 from slurry samples and one from a stage M2 animal), the general PCR was positive while all specific *Treponema* PCRs were negative. In another 10 cases (all clinical stages of DD but no slurry samples were represented) at least one of the specific PCRs was positive whereas the general *Treponema* PCR was negative.

Discussion

Digital dermatitis is most commonly diagnosed by clinical foot examination²⁸. Laboratory investigations are often not conclusive due to the unclear etiology of DD and difficulties when culturing *Treponema*. Fluorescent in situ hybridization (FISH) has already been applied to visualize and localize *Treponema* species¹³. Results of the FISH analysis indicated that *Treponema* species were the predominant bacteria in the deep part of the lesions at border between affected and healthy tissue¹¹.

The use of PCR-based techniques has helped to overcome these problems and certain *Treponema* species have recently been shown to be involved in the etiology of DD. To the best of our knowledge, our study is the first to investigate the prevalence of three *Treponema* species and *D. nodosus* in DD lesions and environmental samples in Switzerland.

In addition, the present study found only two control farms without any clinical signs of DD lesions. This demonstrates that DD prevalence on farms is underestimated. Eight out of 21 farmers were not aware of the presence of clinical DD on their farm. This can be explained by the findings of Berry et al.²⁹ who reported that only certain stages of DD cause pain and thus early growth stages of DD do not always present with lameness. Furthermore, detection of slight lameness is challenging for farmers.

Detection of specific *Treponema* species and *Dichelobacter nodosus* from digital dermatitis (Mortellaro's disease) lesions in Swiss cattle

M. Alsaad et al.

Multiple studies have associated *Treponema* species with DD lesions in cattle^{22,25,30}. Evans et al.¹⁴ reported that *T. phagedenis*-like, *T. medium*/*T. vincentii*-like and *T. putidum*/*T. denticola*-like were present in DD lesion biopsies with a prevalence of 98%, 96.1% and 74.5%, respectively. In our study, we used swab specimens and demonstrated the presence of at least one of the DD-associated *Treponema* species in DD lesions (82.0%) and healthy tissue (36%) using the same PCR-based approach. Swab sampling unlike the biopsy technique, does not require local anesthesia, but may only be sensitive to *Treponema* that are present on superficial tissues. *Treponema* species like *T. medium* and *T. phagedenis* have been reported to be found deep inside lesions³¹. This may explain negative PCR results even in the presence of typical DD lesions as bacteria in the deep part of the lesions cannot be sampled by the swab method. Moter et al.³¹ reported that the presence of certain *Treponema* species may correlate with the invasiveness of the disease. More recently, Krull et al.²³ reported an increase in *Treponema* prevalence from 0.0% in healthy foot skin to 94.3% in DD lesions using deep sequencing analysis and compared to a novel scoring system based on lesion morphology. Sullivan et al.³² reported that in beef cattle, at least one of the three DD-associated *Treponema* species were positive in all isolated DD lesions, while no DD-associated *Treponema* DNA was amplified from healthy foot tissues. Similar to our study, there was at least one *Treponema* species in a statistically significant proportion of DD lesions ((M1 to M4.1) as compared to healthy foot tissues (M5).

Finally, the prevalence was lower in swabs of M1 lesions as compared to the other lesion stages (M2 to M4.1). This is also in agreement with Krull et al.²³, who reported relatively low abundance of *Treponema* species in the early stages of the lesions as compared to the advanced lesions, and the presence of certain *Treponema* species may correlate with the invasiveness of the disease³¹.

There was good consistency between the general and the specific *Treponema* PCR with results showing more than 80% agreement. The fact that some samples representing all clinical stages were only positive with the specific but not the general *Treponema* PCRs is most probably due to the higher sensitivity of the nested specific PCRs compared to the conventional one-step general PCR. On the other hand, samples solely positive with the general *Treponema* PCR could indicate the presence of other *Treponema* species than the ones covered by the specific PCR in those samples. As these included mainly samples from slurry and stage M5 animals from a single farm, it suggests that these *Treponema* are most probably not associated with DD lesions.

D. nodosus was recently shown to cause interdigital dermatitis in cattle and is considered to be a major player

in the pathogenesis and polymicrobial character of DD lesions^{22,33}. We did not detect a difference in *D. nodosus* prevalence in DD lesions versus healthy foot skin specimens, which challenges the current view on the relevance of this species in DD pathogenesis. The lack of a statistical difference of *D. nodosus* in healthy and DD lesions is most likely due to its presence in all stages of lesions. This is in agreement with Krull et al.²³ and Zinicola et al.³⁴ who found no difference in the prevalence of *D. nodosus* between DD lesions and healthy skin specimens. Sullivan et al.³² reported that *D. nodosus* were present in 68% and 26% of beef cattle DD lesions and clinically healthy feet of beef cattle, respectively, comparable with our findings (51.8% and 24.1% in DD and healthy skin specimens, respectively). The established real-time PCR by Stäuble et al.²⁴ allowed the virulotyping of *D. nodosus* and confirmed the absence of acid protease AprV2-positive *D. nodosus* in all samples collected in our study.

The slurry samples showed a low prevalence of DD-associated *Treponema* species (14.3%). Similarly, a work by Klitgaard et al.³⁵, using high-throughput sequencing, identified a small amount of bacterial DNA from DD-associated *Treponema* species in environmental samples (e.g., manure slurry) collected from dairy farms. Although the DD *Treponema* species were present in very low abundance in environmental samples, their presence may act as a source of infection²³. Evans et al.³⁶ used quantitative PCR to test environmental and animal associated samples for the three *Treponema* species identified in DD lesions. In their study, they were unable to identify the three DD-associated *Treponema* species in environmental or fecal samples; however, several samples from the bovine rectal mucosal junction and gingiva were positive.

Conclusions

This study clearly demonstrated an association between DD lesions and specific *Treponema* species (*T. pedis*; *T. medium* and *T. phagedenis*), while *D. nodosus* did not have such a close link, as compared to healthy feet. In addition, acid protease AprV2-positive *D. nodosus* were not identified in any sample investigated. DD *Treponema* species were present in a low number of slurry samples, where they may act as a potential reservoir of DD treponemes. Further investigations are needed to isolate and identify various species of *Treponema* within DD lesions.

Acknowledgments

We thank our collaborators at the Swiss Bovine Health Service for their help during sample collection.

Détection d'espèces de *Treponema* spécifiques et de *Dichelobacter nodosus* de lésions dues à la Dermatite digitée (Mortellaro) chez des bovins suisses

La Dermatite digitée (DD) chez les bovins est une maladie infectieuse podale multifactorielle, qui est devenue un problème émergent pour le bien-être animal et pour l'économie au niveau mondial. Trois espèces de *Treponema*, *T. pedis*, *T. medium* et *T. phagedenis*, sont associées avec la DD. Cependant, leur prévalence est inconnue en Suisse. Il a également été rapporté que *Dichelobacter nodosus* pouvait contribuer au développement de la DD. Le but de cette étude a été de déterminer la prévalence des trois espèces de *Treponema* ainsi que de *D. nodosus* dans des lésions de DD et du lisier de vaches suisses, en utilisant des techniques basées sur la PCR. Vingt-deux exploitations avec de la DD clinique et deux exploitations sans signes cliniques de DD ont été incluses dans l'étude. Un total de 86 échantillons de cas de DD ont été prélevés (M1, n=15; M2, n=19; M3, n=9; M4, n=2, M4.1, n=16 and M5, n=25) en utilisant des coton-tiges secs et stériles. De plus, afin d'évaluer le potentiel de transmission par l'environnement, des échantillons de lisier ont été prélevés sur des exploitations atteintes de DD (n=21) et sur une exploitation à stabulation libre exempte de DD. La PCR nichée et la PCR en temps réel ont ensuite été utilisées sur l'ADN extrait des échantillons afin de détecter les espèces de *Treponema* et *D. nodosus*, respectivement. Les associations entre la présence d'espèces de *Treponema* et de *D. nodosus* avec le statut DD des animaux ont été évaluées avec le test Pearson's Chi-Square. Les stades de DD (M1 à M4.1) et M5 (peau saine) étaient positifs pour au moins une ou plusieurs espèces de *Treponema* associées à la DD dans 50 de 61 cas (82.0%) et 9 de 25 cas (36.0%), respectivement. Les lésions M1 ont montré une prévalence nettement inférieure (14.8%) comparé aux autres stades de DD (M2, M3, M4 et M4.1; 67.2%; $P=0.011$). *T. phagedenis* était prédominant (65.1%). *D. nodosus* a été détecté dans 51.8% des lésions cliniques de DD (M1 à M4) et 24.1% des échantillons M5, mais sa présence n'était pas associée significativement avec les divers stades de DD. Tous les échantillons positifs pour *D. nodosus* contenaient le gène de la protéase acide *aprB2*, mais étaient négatifs pour *aprV2*, un gène associé à la virulence dans le piétin des moutons. Les exploitations de contrôle étaient négatives pour toutes les espèces de *Treponema* associées à la DD, mais positives pour *aprB2* et négatives pour *aprV2*. La présence du gène *aprB2* suggère qu'il est ubiquitaire dans l'environnement des animaux et n'est pas une association en soi avec le piétin des moutons. En ce qui concerne les échantillons de lisier, trois des 21 échantillons (14.3%) étaient positifs pour au moins

Individuazione di specifiche specie di *Treponema* e *Dichelobacter nodosus* nelle lesioni da dermatite digitale (Mortellaro) nei bovini svizzeri.

La dermatite digitale (DD) è una malattia infettiva multifattoriale del piede bovino che è diventata un problema economico e di benessere animale emergente a livello mondiale. Tre specie di *Treponema*, *T. pedis*, *T. medium* e *T. phagedenis* sono associate alla DD, ma la prevalenza in Svizzera rimane ancora sconosciuta. Inoltre è stato messo in evidenza che *Dichelobacter nodosus* è implicato nella patogenesi della DD. Lo scopo di questo studio era quindi quello di determinare la prevalenza delle tre specie *Treponema* e *D. nodosus* nelle lesioni di DD e nei liquami di bovini svizzeri utilizzando tecniche basate sulla PCR. Sono state arruolate nello studio 22 aziende con DD clinica e 2 aziende in cui la DD era assente. Sono stati raccolti 86 campioni di casi di DD (M1, n=15; M2, n=19; M3, n=9; M4, n=2, M4.1, n=16 e M5, n=25) utilizzando tamponi di cotone sterili e asciutti. Inoltre, per valutare il potenziale di trasmissione ambientale, sono stati raccolti campioni di liquami provenienti da aziende agricole affette da DD (n=21) e da un'azienda agricola a stabulazione libera non affetta. Sono state poi effettuate "nested PCR" e "real-time PCR" sul DNA estratto dai campioni per rilevare rispettivamente le specie di *Treponema* e *D. nodosus*. Il test Chi-Quadrato di Pearson è stato utilizzato per studiare le associazioni tra la presenza di specie di *Treponema* e *D. nodosus* e lo stato DD degli animali. Gli stadi DD (M1 a M4.1) e M5 (cute sana) erano positivi per almeno una o più delle specie di *Treponema* associate alla DD in 50 dei 61 casi (82.0%) e 9 dei 25 casi (36.0%), rispettivamente. Le lesioni M1 hanno mostrato una prevalenza significativamente più bassa (14.8%) rispetto agli altri stadi di DD (M2, M3, M4, M4 e M4.1; 67.2%; $P=0.011$). La specie predominante era *T. phagedenis* (65.1%). *D. nodosus* è stato rilevato nel 51.8% delle lesioni cliniche di DD (M1 a M4.1) e nel 24.1% dei campioni prelevati da lesioni M5, ma la sua presenza non era associata in modo significativo ai vari stadi di DD. Tutti i campioni positivi per *D. nodosus* contenevano il gene della proteasi acida *aprB2*, ma erano negativi per *aprV2*, quest'ultimo associato a virulenza nella Zoppina della pecora. Gli allevamenti di controllo sono risultati negativi per tutte le specie di *Treponema* associate alla DD, mentre sono risultati positivi per *aprB2* e negativi per *aprV2*. La presenza di *aprB2* suggerisce che questo gene sia ubiquitario nell'ambiente animale e non un'associazione di per sé con la Zoppina ovina. Per quanto riguarda i campioni di liquame, 3 dei 21 campioni (14,3%) sono risultati positivi per almeno una o più delle specie di *Treponema* associate alla DD e 11 dei 21 campioni (52,4%) sono risultati positivi per *aprB2* e negativi per *aprV2* di

Detection of specific *Treponema* species and *Dichelobacter nodosus* from digital dermatitis (Mortellaro's disease) lesions in Swiss cattle

M. Alsaad et al.

Detection of specific *Treponema* species and *Dichelobacter nodosus* from digital dermatitis (Mortellaro's disease) lesions in Swiss cattle

M. Alsaad et al.

une ou plusieurs espèces de *Treponema* associées à la DD et onze des 21 échantillons (52.4%) étaient positifs pour *aprB2* et négatifs pour *aprV2* de *D. nodosus*. En conclusion, une association a été trouvée entre la présence de DD clinique et des espèces de *Treponema* spécifiques, alors que pour *D. nodosus* aucun lien avec des lésions de DD n'a pu être observé. Cette étude démontre la présence des trois espèces de Tréponèmes chez les bovins suisses et facilite la compréhension de l'implication de *Treponema* spécifiques dans les lésions de DD.

Mots clés: Bovin, *Dichelobacter nodosus*, *Treponema* spp., Dermatite Digitale, PCR

D. nodosus. In conclusione, è stata trovata un'associazione tra la presenza di DD clinica e specifiche specie di *Treponema*, mentre per *D. nodosus* non è stato osservato alcun legame di questo tipo con le lesioni di DD. Questo studio fornisce prove della presenza delle tre specie di treponema nel bestiame svizzero e facilita la comprensione del coinvolgimento di specifiche specie di *Treponema* nelle lesioni di DD.

Parole chiave: Bovini, *Dichelobacter nodosus*, *Treponema* spp., Dermatite Digitale, PCR

References

- Cheli R, Morterello C: La dermatite digitale del bovino, Proceedings, The 8th International Conference on Diseases of Cattle. Piacenza, Milan, Italy 1974. 8:208–213.
- Read DH, Walker RL: Papillomatous digital dermatitis (footwarts) in California dairy cattle: clinical and gross pathologic findings. *J Vet Diagn Invest* 1998; 10(1): 67-76.
- Cha E, Hertl JA, Bar D, Grohn YT: The cost of different types of lameness in dairy cows calculated by dynamic programming. *Prev Vet Med* 2010; 97(1): 1-8.
- Brujinis MR, Hogeveen H, Stassen EN: Assessing economic consequences of foot disorders in dairy cattle using a dynamic stochastic simulation model. *J Dairy Sci* 2010; 93(6): 2419-2432.
- Dopfer D: Digital dermatitis in dairy and beef cattle, the long term consequences and impact-how to prevent the losses caused by DD, Proceedings, Proceedings of the XV.Middle European Buiatric Congress. Maribor, 2015.
- Capion N, Thamsborg SM, Enevoldsen C: Prevalence of foot lesions in Danish Holstein cows. *Vet Rec* 2008; 163(3): 80-85.
- Logue D: Understanding bovine digital dermatitis. *Vet Rec* 2011; 168(8): 212-213.
- Becker J, Steiner A, Kohler S, Koller-Bahler A, Wuthrich M, Reist M: Lameness and foot lesions in Swiss dairy cows: I. Prevalence. *Schweiz Arch Tierheilkd* 2014; 156(2): 71-78.
- Wells SJ, Garber LP, Wagner BA: Papillomatous digital dermatitis and associated risk factors in US dairy herds. *Prev Vet Med* 1999; 38(1): 11-24.
- Palmer MA, Donnelly RF, Garland MJ, Majithiya R, O'Connell NE: The effect of slurry on skin permeability to methylene blue dye in dairy cows with and without a history of digital dermatitis. *Animal* 2013; 7(10): 1731-1737.
- Nielsen MW, Strube ML, Isbrand A, Al-Medrasi WD, Boye M, Jensen TK, et al.: Potential bacterial core species associated with digital dermatitis in cattle herds identified by molecular profiling of interdigital skin samples. *Vet Microbiol* 2016; 186: 139-149.
- Cruz CE, Pescador CA, Nakajima Y, Driemeier D: Immunopathological investigations on bovine digital epidermitis. *Vet Rec* 2005; 157(26): 834-840.
- Klitgaard K, Boye M, Capion N, Jensen TK: Evidence of multiple *Treponema* phylotypes involved in bovine digital dermatitis as shown by 16S rRNA gene analysis and fluorescence in situ hybridization. *J Clin Microbiol* 2008; 46(9): 3012-3020.
- Evans NJ, Brown JM, Demirkan I, Singh P, Getty B, Timofte D, et al.: Association of unique, isolated treponemes with bovine digital dermatitis lesions. *J Clin Microbiol* 2009; 47(3): 689-696.
- Dopfer D, Anklam K, Mikheil D, Ladell P: Growth curves and morphology of three *Treponema* subtypes isolated from digital dermatitis in cattle. *Vet J* 2012; 193(3): 685-693.
- Moore LJ, Woodward MJ, Grogono-Thomas R: The occurrence of treponemes in contagious ovine digital dermatitis and the characterisation of associated *Dichelobacter nodosus*. *Vet Microbiol* 2005; 111(3-4): 199-209.
- Anklam K, Kulow M, Yamazaki W, Dopfer D: Development of real-time PCR and loop-mediated isothermal amplification (LAMP) assays for the differential detection of digital dermatitis associated treponemes. *PLoS One* 2017; 12(5): e0178349.
- Evans NJ, Brown JM, Demirkan I, Murray RD, Vink WD, Blowey RW, et al.: Three unique groups of spirochetes isolated from digital dermatitis lesions in UK cattle. *Vet Microbiol* 2008; 130(1-2): 141-150.
- Clegg SR, Crosby-Durrani HE, Bell J, Blundell R, Blowey RW, Carter SD, et al.: Detection and Isolation of Digital Dermatitis Treponemes from Bovine Pressure Sores. *J Comp Pathol* 2016; 154(4): 273-282.
- Sullivan LE, Clegg SR, Angell JW, Newbrook K, Blowey RW, Carter SD, et al.: High-level association of bovine digital dermatitis *Treponema* spp. with contagious ovine digital dermatitis lesions and presence of *Fusobacterium necrophorum* and *Dichelobacter nodosus*. *J Clin Microbiol* 2015; 53(5): 1628-1638.
- Schlafer S, Nordhoff M, Wyss C, Strub S, Hubner J, Gescher DM, et al.: Involvement of *Gugenheimella bovis* in digital dermatitis lesions of dairy cows. *Vet Microbiol* 2008; 128(1-2): 118-125.
- Rasmussen M, Capion N, Klitgaard K, Rogdo T, Fjeldaas T, Boye M, et al.: Bovine digital dermatitis: possible pathogenic consortium consisting of *Dichelobacter nodosus* and multiple *Treponema* species. *Vet Microbiol* 2012; 160(1-2): 151-161.

- ²³ Krull AC, Shearer JK, Gorden PJ, Cooper VL, Phillips GJ, Plummer PJ: Deep sequencing analysis reveals temporal microbiota changes associated with development of bovine digital dermatitis. *Infect Immun* 2014; 82(8): 3359-3373.
- ²⁴ Stauble A, Steiner A, Frey J, Kuhnert P: Simultaneous detection and discrimination of virulent and benign *Dichelobacter nodosus* in sheep of flocks affected by foot rot and in clinically healthy flocks by competitive real-time PCR. *J Clin Microbiol* 2014; 52(4): 1228-1231.
- ²⁵ Dopfer D, Koopmans A, Meijer FA, Szakall I, Schukken YH, Klee W, et al.: Histological and bacteriological evaluation of digital dermatitis in cattle, with special reference to spirochaetes and *Campylobacter faecalis*. *Vet Rec* 1997; 140(24): 620-623.
- ²⁶ Berry SL, Read DH, Famula TR, Mongini A, Dopfer D: Long-term observations on the dynamics of bovine digital dermatitis lesions on a California dairy after topical treatment with lincomycin HCl. *Vet J* 2012; 193(3): 654-658.
- ²⁷ Kuhnert P, Capaul SE, Nicolet J, Frey J: Phylogenetic positions of *Clostridium chauvoei* and *Clostridium septicum* based on 16S rRNA gene sequences. *International Journal of Systematic Bacteriology* 1996; 46(4): 1174-1176.
- ²⁸ Relun A, Guatteo R, Roussel P, Bareille N: A simple method to score digital dermatitis in dairy cows in the milking parlor. *J Dairy Sci* 2011; 94(11): 5424-5434.
- ²⁹ Berry SL: Infectious diseases of the Bovine claw., Proceedings, In Proceedings of the 14th International Symposium and 6th Conference on Lameness in Ruminants. Colonia, Uruguay, 2006.
- ³⁰ Yano T, Moe KK, Yamazaki K, Ooka T, Hayashi T, Misawa N: Identification of candidate pathogens of papillomatous digital dermatitis in dairy cattle from quantitative 16S rRNA clonal analysis. *Vet Microbiol* 2010; 143(2-4): 352-362.
- ³¹ Moter A, Leist G, Rudolph R, Schrank K, Choi BK, Wagner M, et al.: Fluorescence in situ hybridization shows spatial distribution of as yet uncultured treponemes in biopsies from digital dermatitis lesions. *Microbiology* 1998; 144 (Pt 9): 2459-2467.
- ³² Sullivan LE, Evans NJ, Blowey RW, Grove-White DH, Clegg SR, Duncan JS, et al.: A molecular epidemiology of treponemes in beef cattle digital dermatitis lesions and comparative analyses with sheep contagious ovine digital dermatitis and dairy cattle digital dermatitis lesions. *Vet Microbiol* 2015; 178(1-2): 77-87.
- ³³ Capion N, Boye M, Ekstrom CT, Jensen TK: Infection dynamics of digital dermatitis in first-lactation Holstein cows in an infected herd. *J Dairy Sci* 2012; 95(11): 6457-6464.
- ³⁴ Zinicola M, Lima F, Lima S, Machado V, Gomez M, Dopfer D, et al.: Altered microbiomes in bovine digital dermatitis lesions, and the gut as a pathogen reservoir. *PLoS One* 2015; 10(3): e0120504.
- ³⁵ Klitgaard K, Nielsen MW, Ingerslev HC, Boye M, Jensen TK: Discovery of bovine digital dermatitis-associated *Treponema* spp. in the dairy herd environment by a targeted deep-sequencing approach. *Appl Environ Microbiol* 2014; 80(14): 4427-4432.
- ³⁶ Evans NJ, Brown JM, Murray RD, Getty B, Birtles RJ, Hart CA, et al.: Characterization of novel bovine gastrointestinal tract *Treponema* isolates and comparison with bovine digital dermatitis treponemes. *Appl Environ Microbiol* 2011; 77(1): 138-147.

Corresponding author

M. Alsaad
 Clinic for Ruminants/Institute of Veterinary Bacteriology
 Vetsuisse-Faculty, University of Bern
 Bremgartenstrasse 109a
 3012 Bern
 Switzerland
 Tel.: +41 31 631 22 23
 E-Mail: maher.alsaad@vetsuisse.unibe.ch

Detection of specific *Treponema* species and *Dichelobacter nodosus* from digital dermatitis (Mortellaro's disease) lesions in Swiss cattle

M. Alsaad et al.