Check for updates

Selective Arterial Embolizations of Renal Angiomyolipomas Using 96% Ethanol: A Case Series of 5 Patients

Clinical Medicine Insights: Case Reports
Volume 13: 1–7
© The Author(s) 2020
Article reuse guidelines:
sagepub.com/journals-permissions
DOI: 10.1177/1179547620906863
SAGE

Alexander Rosenov[1], Marc Schindewolf[1], Iris Baumgartner[1] and Christoph Saely[2,3]

[1]Division of Angiology, Swiss Cardiovascular Center, Inselspital, Bern University Hospital, University of Bern, Bern, Switzerland. [2]Department of Medicine I, Academic Teaching Hospital Feldkirch, Feldkirch, Austria. [3]Vorarlberg Institute for Vascular Investigation and Treatment (VIVIT), Feldkirch, Austria.

ABSTRACT: Angiomyolipomas are rare benign tumors of the kidneys, with a risk of spontaneous hemorrhage including severe retroperitoneal bleedings. In this study, we report clinical outcomes of 5 patients who underwent 8 embolization sessions using 96% ethanol, as there is scarce data using this embolic agent for this indication. The primary angiographic success could be achieved in all but 1 lesion, which was not accessible due to vasospasm of the supplying vessel. Therapeutic success could be demonstrated in all treated cases for which follow-up imaging was available (n = 3). In 1 complex patient, a mildly reduced renal function, as well as a new onset of arterial hypertension was detected after treatment. Nontarget embolization of vital kidney tissue was demonstrated in another patient; it remained asymptomatic. Embolization therapy using 96% ethanol is an optional method to treat renal angiomyolipomas.

KEYWORDS: Angiomyolipoma, embolization, ethanol

RECEIVED: January 11, 2020. **ACCEPTED:** January 24, 2020.

TYPE: Case Report

FUNDING: The author(s) received no financial support for the research, authorship, and/or publication of this article.

DECLARATION OF CONFLICTING INTERESTS: The author(s) declared no potential conflicts of interest with respect to the research, authorship, and/or publication of this article.

CORRESPONDING AUTHOR: Alexander Rosenov, Division of Angiology, Swiss Cardiovascular Center, Inselspital, Bern University Hospital, University of Bern, Freiburgstrasse 18, 3010 Bern, Switzerland. Email: alexander.rosenov@insel.ch

Background

Angiomyolipomas are relatively rare benign tumors of the kidneys, with a risk of spontaneous hemorrhage that may lead to severe retroperitoneal bleedings. In serial ultrasound screenings, angiomyolipomas could be found in 0.1% of the male and in 0.22% of the female population, respectively.[1,2] Angiomyolipomas consist of abnormal blood vessels, smooth muscle cells, and fat cells in varying amounts. The structurally altered blood vessels are prone to the formation of aneurysms and to ruptures, as they bear no internal elastic lamina and their smooth muscle is replaced by fibrous tissue, which makes the vessels more rigid and tortuous.[3-5]

A review of the literature showed that almost 60% of patients present with clinical symptoms,[2] most typically with flank pain, a palpable tender mass, and macroscopic or microscopic hematuria. Of importance is the possible complication of a potentially life-threatening hemorrhage. Nevertheless, a significant number of angiomyolipomas are detected incidentally on radiographic findings, where the presence of fatty tissue in the renal tumor is essential to diagnose an angiomyolipoma using magnetic resonance imaging (MRI) or computed tomography (CT) studies.[2]

In 80% of the patients, angiomyolipomas occur sporadically, whereas 20% are associated with tuberous sclerosis complex (TSC), an autosomal dominant systemic disorder predisposing to benign tumor formation in multiple organs. Both sporadic and in TSC-associated angiomyolipomas affect women in almost 90% of cases.[2,6]

Established indications for therapy are clinically symptomatic lesions of any size or a tumor size exceeding 4 cm of diameter. Treatment options include nephrectomy, partial nephrectomy, and selective arterial embolization. Recent therapy strategies are focusing on the nephron-sparing procedure of embolization. Embolization therapy of angiomyolipomas has been performed with variety of agents used for embolization, such as gelatin, polyvinyl alcohol, coils, foam, ethanol, and combinations of these agents.[6-9] Ethanol is used alone or in combination with other agents such as oil or microparticles.[10-12] Pure ethanol is a widely used embolization agent, but there is only scarce data using it for this indication.[13] In the literature, predominately oil or microparticles are added to ethanol when treating angiomyolipomas.[10-12] In this study, we want to report on the findings of using pure 96% ethanol.

Patients and Methods

We analyzed all patients who underwent selective arterial embolization of renal angiomyolipomas at our institution between March 2015 and May 2017. In this period, no patients referred to our institution were excluded from this treatment option. Data on differently treated patients by other medical specialties were not available. In total, 5 patients were treated in 8 embolization sessions. In all of them, 96% ethanol was used. Written informed consent was obtained from all patients.

Treatment

The embolization procedures were planned electively in general anesthesia for precise cardiopulmonary monitoring and because of the painful nature of this procedure when performed without

source: https://doi.org/10.7892/boris.141799 | downloaded: 12.10.2024

Creative Commons Non Commercial CC BY-NC: This article is distributed under the terms of the Creative Commons Attribution-NonCommercial 4.0 License (https://creativecommons.org/licenses/by-nc/4.0/) which permits non-commercial use, reproduction and distribution of the work without further permission provided the original work is attributed as specified on the SAGE and Open Access pages (https://us.sagepub.com/en-us/nam/open-access-at-sage).

general anesthesia. To modulate the inflammatory reaction,[14] a single dose of prednisone 125 mg was administered intravenously before the procedure (Solu-Medrol; Pfizer PFE Switzerland, Zurich, Switzerland). After the intervention, oral dexamethasone (Dexamethason Galepharm, Zurich, Switzerland) was routinely prescribed for 4 or 7 days at an initial dose of 8 mg/d and was weaned off. For pain management, nonsteroidal anti-inflammatory drugs (NSAIDs) were prescribed.

Femoral arteries were accessed using a 5 F sheath (Radiofocus introducer II, Terumo, Tokyo, Japan). Subsequently, abdominal aortographies were performed followed by catheterization of the target renal arteries (C1; Cordis, Miami Lakes, FL, USA). Super-selective angiographies were performed to identify the supplying vessels of the angiomyolipomas. Then, embolizations were performed by slowly instilling ethanol under free flow conditions. Due to lack of visibility of ethanol under fluoroscopy, it was either mixed with contrast in a ratio 5:1 or it was applied in very small quantities followed by super-selective repeated angiograms. Injection was performed using 1 mL insulin syringes for better low flow control. Repeated injections were delayed by at least 1 to 2 minutes always followed by fluoroscopic contrast injection to estimate effect of ethanol embolization and to fill the microcatheter with contrast for better tracking the course of embolization.

Successful occlusions of the tumors supplying vessels were verified in a subsequent control angiography. The patients were discharged the next day. Routine postintervention ultrasound was performed either on the first day after the procedure or within 4 weeks. Postintervention cross-sectional imaging was performed with MRI or CT scans at the discretion of the referring specialists. Therapeutic success was defined as an eliminated arterial perfusion signal in duplex sonography and MRI or CT-scan.

Results

Patients

Five female patients aged 38 to 63 years (median age: 52.2 years) were treated in 8 elective embolization sessions. Details on these patients (labeled A through E) are summarized in Table 1.

One patient (patient C) had a single angiomyolipoma, 2 patients (patients B and D) had 2 unilateral angiomyolipomas, and 2 other patients (patients A and E) had multiple bilateral angiomyolipomas, one of which was associated with TSC (patient E). Two patients (patients A and E) had a history of prior partial nephrectomy and in the same 2 patients, a planned second embolization was performed due to the multilobular tumor characteristics. In 1 patient (patient D), a reintervention was performed due to recurrent symptoms.

The treated angiomyolipomas had diameters ranging between 4.5 and 10.8 cm. Indications for the initial treatment were a large tumor size in 4 cases (patients A, C, D, E) and a history of bleeding in 1 case (patient B; Figure 1), respectively. In the latter patient, an elective embolization was performed 6 months after a self-limiting retroperitoneal hemorrhage occurred. A median amount of 7.7 mL of alcohol was used per embolization session (range: 1.0-13.3 mL).

Efficacy

In all of our 5 patients, postinterventional control angiography showed complete angiographic elimination of the targeted angiomyolipoma, which was defined as treatment success. Figure 2 (patient A) and Figure 3 (patient D) show preembolization and postembolization angiograms. During follow-up examinations, therapeutic success could be confirmed in all cases using ultrasound, MRI, or CT scans. In 4 of the 5 patients (in patients A, B, C, D), no arterial perfusion was detectable in the postintervention ultrasound scan. In 1 patient (patient E), sonographic assessment was limited due to impaired ultrasound conditions. In 3 patients, follow-up cross-sectional imaging was initiated by the referring physicians 3 to 12 months after the intervention (patients C, D, and E). Complete target lesion elimination of the perfusion signal was confirmed in 1 patient (patient C), and a significant reduction of the target lesion perfusion was demonstrated in 2 patients (patients D and E). In all 3 patients, significant tumor size reductions were shown, ranging between 1.5 and 4.6 cm. Patient E had multiple angiomyolipoma s in both kidneys. Due to vasospasm, 1 of the 5 biggest lesions was not accessible during the initial procedure in this patient.

In 1 patient (patient D), an additional embolization had to be performed due to recurrent symptoms of abdominal pain and unexplained hematuria, although procedural success had been demonstrated in cross-sectional studies after the first embolization with an only weak residual arterial perfusion and a 20% size reduction in MRI. This was confirmed by re-angiography so that a small dose of 1 mL of 96% ethanol was applied (Figure 4). The final CT scan demonstrated a size reduction from 108 to 59 mm after both procedures (Figure 5).

Safety

Mild and self-limiting postembolic flank pain occurred in 2 patients (patients A and C). In 1 patient (patient E), moderate to severe abdominal pain required rehospitalization for analgetic therapy. In the same patient, a femoral pseudoaneurysm was detected at the puncture site which was treated successfully by ultrasound-guided compression. In this patient, mildly increased creatinine (from 86 to 99 μmol/L) and new onset of arterial hypertension was detected after the intervention. This complex patient had a history of a prior partial nephrectomy, due to the vast extent of multiple bilateral angiomyolipomas associated with TSC. Two elective consecutive embolizations were performed in her targeting multiple tumors.

Discussion

Angiomyolipomas are benign tumors of the kidney that require interdisciplinary management. Therapeutic options include

Table 1. Results and patient characteristics (patients labeled A through E).

PATIENT	A	B	C	D	E
Age, y	58	63	42	60	38
Sex	Female	Female	Female	Female	Female
Type	Sporadic	Sporadic	Sporadic	Sporadic	TSC
Extent of AMLs	Multiple, bilateral	2, unilateral	1	2, unilateral	Multiple, bilateral
Size of largest AML (cm)	5.8	4.5	5.6	10.8	6
Initial diagnostic method	CT scan, ultrasound	CT scan	MRI	CT scan	CT scan, MRI
Prior surgical treatment of the AML	Yes	No	No	No	Yes
Initial symptoms	Data not available	Side pain	Asymptomatic	Side pain, hematuria	Asymptomatic
Indication for treatment	Size	History of bleeding	Size	Size	Size
No. of treatments; if 2, planned (p)/unplanned, u))	2; (p)	1	1	2; (u)	2; (p)
Amount of alcohol used in each procedure (no. of procedure: mL)	1: 8.5 2: 5.5	2.2	10.3	1: 13 2: 1	1: 8 2: 13.3
Primary angiographic success	Yes	Yes	Yes	Yes	Yes, 1 AML not accessible
Treatment success on postinterventional sonography	Yes	Yes	Yes	Yes	Unfavorable sonographic conditions
Follow-up CT/MRI available	No	No	Yes	Yes	Yes
Size of biggest AML at follow-up/size reduction (cm)			4.1/1.5	8.8/2.0	3.4/2.6
Complications	Mild postembolization syndrome	None	Mild postembolization syndrome, nontarget embolization	None	Pseudoaneurysm, moderate postembolization syndrome, worsening of renal function

Abbreviations: AML, angiomyolipoma; CT, computed tomography; MRI, magnetic resonance imaging; TSC, tuberous sclerosis complex.

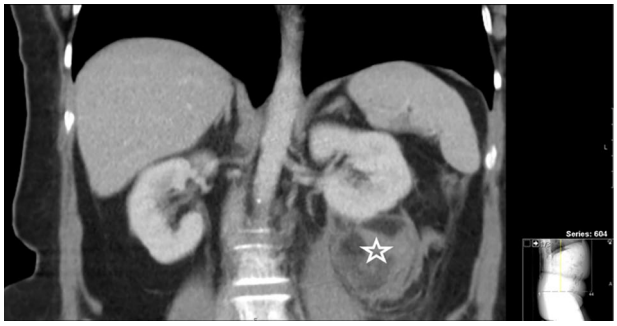

Figure 1. CT scan (arterial phase) of a 63-year-old female patient (patient B) who presented with a history of flank pain for 5 days, showing an angiomyolipoma-associated retroperitoneal hematoma. No active bleeding was detected; an elective embolization procedure of the angiomyolipoma was scheduled. CT indicates computed tomography.

partial or total nephrectomy.[6] However, nephron-sparing endovascular embolization has evolved as the standard therapy.

There is a variety of agents used for embolization.[6,8-14] In our practice, we preferably use pure 96% ethanol for tumor and vascular malformation embolizations.[15]

Ethanol denaturates proteins resulting in intravascular thrombosis and subsequent tissue infarction and fibrotic and necrotic tissue remodeling.[14] Application techniques of undiluted 96% ethanol may vary. Besides directly injecting alcohol under free flow, different other application options are described in the literature. Some authors describe using flow control devices such as balloons to attenuate the arterial perfusion or the venous drainage of the tumor to enhance the denaturating effect of the alcohol on the endothelial cells by increasing the contact time. Authors also describe that the alcohol can be aspirated after being left in situ for a minute, when the perfusion has been blocked with an occlusion balloon.[11-13] In our series, we injected 96% ethanol under free flow conditions, in the absence of flow control devices to avoid

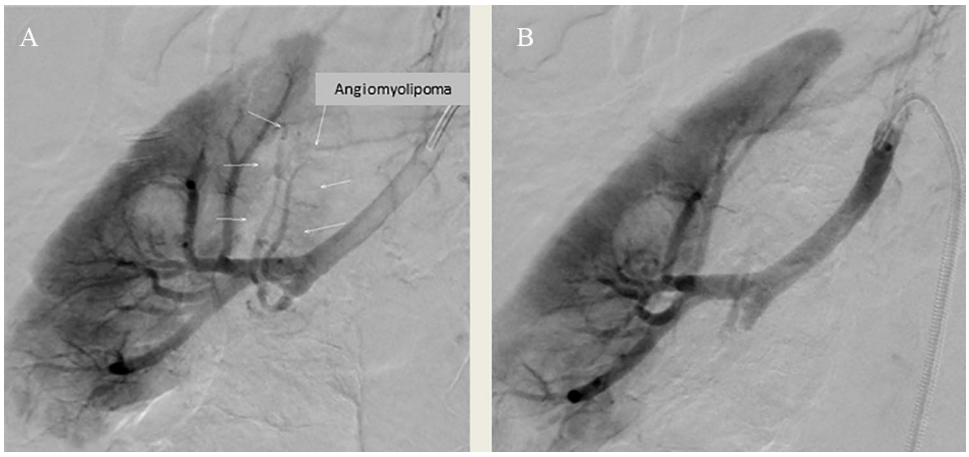

Figure 2. Preembolization (A) and postembolization angiogram (B) of a large angiomyolipoma (maximum diameter 5.8 cm) of the right kidney in a 58-year-old female patient (patient A) with multiple bilateral angiomyolipomas.

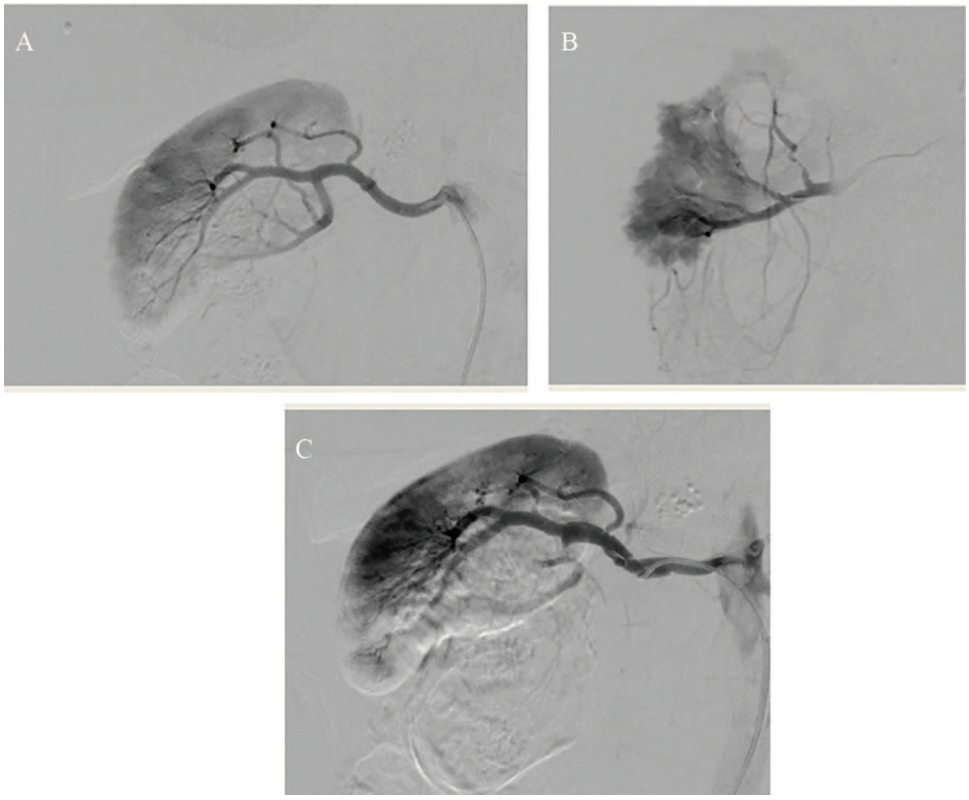

Figure 3. Embolization of a large angiomyolipoma located in the right kidney of a 60-year-old female patient (patient D). Showing the (A) initial selective angiogram, (B) a super-selective angiogram, and (C) the final angiogram after the first super-selective arterial embolization.

locoregional toxic effects seen with prolonged exposure to undiluted ethanol.

Possible adverse events of alcohol embolization include cardiopulmonary complications, which may lead to acute pulmonary hypertension and acute right heart failure as a consequence of pulmonary artery spasms or extensive microthromboembolization. Therefore, the intervention should be performed under close cardiopulmonary monitoring. However, according to Shin et al,[16] the risk of cardiopulmonary complications is low when <0.14 mL ethanol/kg body weight are applied every 10 minutes, with a maximum dose of <1 mL/kg body weight per session.[15-19] After having used pure ethanol for many years for treating of vascular malformations at our institution, we prefer to perform these procedures in general anesthesia, due to the painful nature of alcohol embolization as well as for precise cardiopulmonary monitoring.

In our series of patients, we had a primary angiographic success rate of 100% of the treated tumors. Regarding adverse events, in 1 of our 5 patients, a mild worsening of an already preexisting reduced renal function (pre- and postprocedure chronic kidney disease [CKD] stage II) was noted after the intervention together with new arterial hypertension. As the

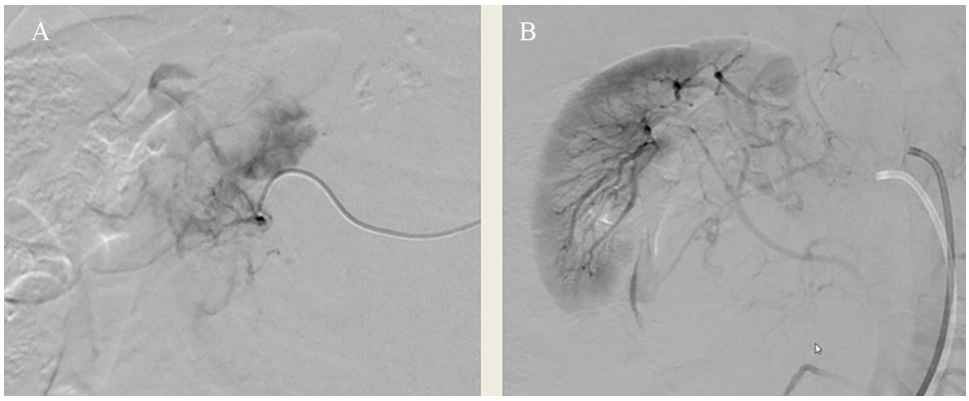

Figure 4. Patient D underwent an unplanned re-intervention due to recurrent symptoms. (A) Residual perfusion of the angiomyolipoma could be demonstrated and (B) the final angiogram shows an elimination of the perfusion signal after embolization with an overlaying signal from lumbar arteries.

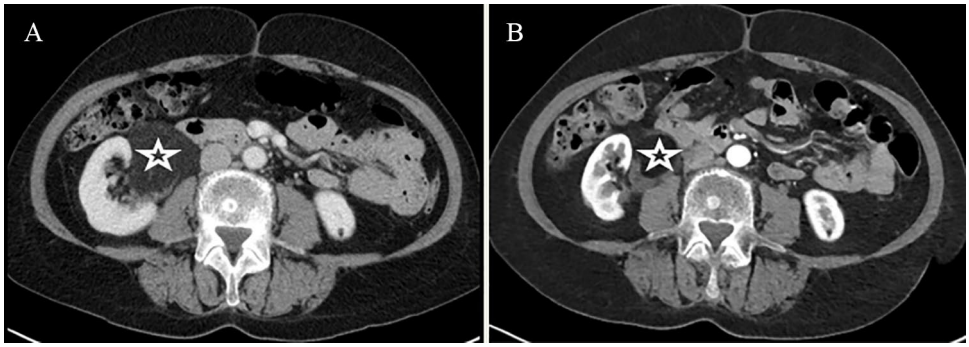

Figure 5. (A) Preinterventional and (B) postinterventional CT scan (arterial phase) of the same patient (patient D). A size reduction of the angiomyolipoma from 108 to 59 mm could be demonstrated after 2 embolization sessions. CT indicates computed tomography.

final angiogram showed intact healthy renal parenchyma, a nephrotoxic effect of the contrast was suspected in this long and complex procedure targeting multiple bilateral angiomyolipomas in 1 session. An additional third planned treatment session, which was considered necessary because of arterial spasm in one of the supplying arteries of 1 remaining angiomyolipoma, has not been performed to date. The consensus with the referring specialist was to postpone the intervention to not jeopardize kidney function further in this polymorbid patient. Of note, follow-up MRI showed only a residual perfusion signal in the treated angiomyolipomas and a size regression in most of the treated lesions in this patient.

In another patient, a limited nontarget embolization could be demonstrated in the final angiogram, affecting 10% to 15% of the vital kidney tissue. However, this finding remained asymptomatic, with no effects on renal function. As pure ethanol is not visible under fluoroscopy, possible nontarget embolization due to backflow is a concern. To limit this risk, ethanol either was mixed with contrast or was applied undiluted in only very small quantities using a 1-mL insulin syringes followed by super-selective repeated angiograms.

Nontarget embolizations are possible adverse events of any embolization therapy; however, these are rare events. In a literature review by Murray et al[6] the total postinterventional morbidity in patients undergoing embolization procedures for the treatment of angiomyolipomas was described in 6.9% of patients, which included nontarget embolization in 2.3% of patients, respiratory complications in 2.0%, abscess formation in 1.6%, active retroperitoneal hemorrhage in 1.0%, allergic reactions in 0.6%, urinary retention in 0.6%, urinary tract infections in 0.3%, femoral artery damage requiring repair in 0.3%, and renal artery spasm in 0.3% of patients.

An additional embolization was performed in 1 patient due to recurrent symptoms and otherwise not explained hematuria, despite radiological success of the treatment. Murray et al[6] in their systemic review describe that re-embolizations or surgeries are required in 20.9% of angiomyolipomas treated with embolization (at a medium follow-up time of 39 months). The most common indications for re-embolization procedures are described as revascularization on follow-up imaging (30.0%), unchanged or increasing tumor size (22.6%), refractory or recurring symptoms (16.7%), and acute retroperitoneal hemorrhage in 14.3% of the cases. However, re-angiography in our patient demonstrated subtotal angiomyolipoma occlusion so that only 1 mL of alcohol was applied. Because symptoms persisted after successful reintervention, an alternative explanation for the symptoms seems likely.

An inherent limitation of a case series of patients undergoing embolization procedures is that the included subjects have been previously chosen for this treatment modality and not for

another one. Our findings therefore are not necessarily applicable to all patients with angiomyolipomas.

In conclusion, our case report and literature review provides evidence that embolization using 96% ethanol is an option to treat renal angiomyolipomas. Please find teaching points and a quiz in the appendix.

Author Contributions

Iris Baumgartner encouraged Alexander Rosenov to write the manuscript and provided the idea and concept. Alexander Rosenov wrote the manuscript under supervision and Marc Schindewolf who contributed relevant parts to the manuscript. Iris Baumgartner contributed relevant parts to the manuscript. Christoph Saely supervised the findings of this manuscript and added relevant contributions. All authors discussed the findings and contributed to the final manuscript.

ORCID iD

Alexander Rosenov https://orcid.org/0000-0001-6673-9308

REFERENCES

1. Yamakado K, Tanaka N, Nakagawa T, Kobayashi S, Yanagawa M, Takeda K. Renal angiomyolipoma: relationships between tumor size, aneurysm formation, and rupture. *Radiology*. 2002;225:78-82.
2. Nelson CP, Sanda MG. Contemporary diagnosis and management of renal angiomyolipoma. *J Urol*. 2002;168:1315-1325.
3. Schieda N, Kielar AZ, Al Dandan O, McInnes MD, Flood TA. Ten uncommon and unusual variants of renal angiomyolipoma (AML): radiologic-pathologic correlation. *Clin Radiol*. 2015;70:206-220.
4. Radhakrishnan R, Verma S. Clinically relevant imaging in tuberous sclerosis. *J Clin Imaging Sci*. 2011;1:39.
5. Wang C, Yang M, Tong X, et al. Transarterial embolization for renal angiomyolipomas: a single centre experience in 79 patients. *J Int Med Res*. 2017;45:706-713.
6. Murray TE, Doyle F, Lee M. Transarterial embolization of angiomyolipoma: a systematic review. *J Urol*. 2015;194:635-639.
7. Ramon J, Rimon U, Garniek A, et al. Renal angiomyolipoma: long-term results following selective arterial embolization. *Eur Urol*. 2009;55:1155-1161.
8. Han YM, Kim JK, Roh BS, et al. Renal angiomyolipoma: selective arterial embolization—effectiveness and changes in angiomyogenic components in long-term follow-up. *Radiology*. 1997;204:65-70.
9. Kothary N, Soulen MC, Clark TW, et al. Renal angiomyolipoma: long-term results after arterial embolization. *J Vasc Interv Radiol*. 2005;16:45-50.
10. Rimon U, Duvdevani M, Garniek A, et al. Ethanol and polyvinyl alcohol mixture for transcatheter embolization of renal angiomyolipoma. *AJR Am J Roentgenol*. 2006;187:762-768.
11. Lee W, Kim TS, Chung JW, Han JK, Kim SH, Park JH. Renal angiomyolipoma: embolotherapy with a mixture of alcohol and iodized oil. *J Vasc Interv Radiol*. 1998;9:255-261.
12. Sawada Y, Shimohira M, Hashizume T, et al. Transcatheter arterial embolization for renal angiomyolipoma using a micro-balloon catheter and a mixture of ethanol and lipiodol. *Cardiovasc Intervent Radiol*. 2017;40:1933-1939.
13. Cantwell CP, Taubman KE, Scorza LB. Absolute alcohol embolization of sporadic angiomyolipoma. *Semin Intervent Radiol*. 2008;25:319-322.
14. Vaidya S, Tozer KR, Chen J. An overview of embolic agents. *Semin Intervent Radiol*. 2008;25:204-215.
15. Yakes W, Baumgartner I. Interventional treatment of arterio-venous malformations. *Gefässchirurgie*. 2014;19:325-330.
16. Shin BS, Do YS, Cho HS, et al. Effects of repeat bolus ethanol injections on cardiopulmonary hemodynamic changes during embolotherapy of arteriovenous malformations of the extremities. *J Vasc Interv Radiol*. 2010;21:81-89.
17. Do YS, Yakes WF, Shin SW, et al. Ethanol embolization of arteriovenous malformations: interim results. *Radiology*. 2005;235:674-682.
18. Shin BS, Do YS, Lee BB, et al. Multistage ethanol sclerotherapy of soft-tissue arteriovenous malformations: effect on pulmonary arterial pressure. *Radiology*. 2005;235:1072-1077.
19. Ko JS, Kim JA, Do YS, et al. Prediction of the effect of injected ethanol on pulmonary arterial pressure during sclerotherapy of arteriovenous malformations: relationship with dose of ethanol. *J Vasc Interv Radiol*. 2009;20:39-45; quiz 45.

Appendix

Teaching points

Established indications for embolization are clinically symptomatic angiomyolipomas (AMLs) of any size or a tumor size exceeding 4 cm of diameter. Pure, 96% ethanol is one of a variety of embolic agents currently being used.

Questions and answers

1. Which systemic side effects are possible when using pure ethanol as embolic agent for AMLs? (multiple answers possible)

   - Signs of alcohol intoxication after the procedure (applies)
   - Cardiopulmonary complications such as acute pulmonary hypertension and acute right heart failure (applies)
   - Elevated levels of blood alcohol during and after the procedure (applies)
   - High risk of pulmonary artery spasm when <0.14 mL ethanol/kg body weight are applied every 10 minutes, with a maximum dose of <1 mL/kg body weight per session
   - None of the above

Explanation: Systemic effects of ethanol are well known[16], including serious cardiopulmonary complications, especially when exceeding a weight and time depending ethanol dosage.

2. In which of the following cases an embolization therapy should be considered? (multiple answers possible)

   - An incidental finding of an AML (diameter 3.2 cm) in a 45-year-old female patient during a routine check up
   - A 35-year-old female patient with a completely asymptomatic AML in the right kidney (diameter 4.5 cm) (applies)
   - A patient with a small AML who has a history of self-limiting bleeding and was diagnosed 2 weeks after the suspected bleeding episode (applies)
   - A hemodynamically stable patient with an acute bleeding of an AML (diameter 5 cm) (applies)
   - A 60-year-old female patient with a 3-cm AML of the right kidney and a history of so far unexplained flank pain on the right side (applies)

Explanation: Indication for therapy is symptomatic AMLs of any size (including flank pain and history of bleeding) as well as tumors exceeding 4 cm in diameter[6]. An acutely bleeding

AML in a stable patient is an established indication for embolization therapy.

3. AMLs are associated with which of the following symptoms? (multiple answers possible)

   - Flank pain and/or palpable tender tumor mass (applies)
   - Microscopic or macroscopic hematuria (applies)
   - Retroperitoneal bleeding (applies)
   - Renal failure (applies)
   - Family history of polycystic kidney disease

Explanation: AMLs when symptomatic present most typically with flank pain, a palpable tender mass, and macroscopic or microscopic hematuria[2]. Other symptoms include nausea and vomiting, fever, hypertension, anemia, renal failure, as well as potentially life-threatening hemorrhage.

4. AMLs occur sporadically or in association with tuberous sclerosis complex (TSC), an autosomal dominant systemic disorder predisposing to benign tumor formation in multiple organs. Which of the following statements is true? (multiple answers possible)

   - Sporadic AMLs affect more female patients, TSC-associated AMLs affect more male patients
   - About 50% of patients with TSC develop AMLs (applies)
   - TSC-associated AMLs tend to bleed more compared with sporadic AMLs (applies)
   - TSC is an autosomal dominant disorder (applies)
   - On average, AMLs are diagnosed at the age of 50 in both groups

Explanation: In 20% of patients, AMLs are associated with TSC, an autosomal dominant multiorgan disorder[2]. About 50% of patients with TSC develop AMLs. TSC-associated AMLs occur at a younger age compared with sporadic AMLs, with a mean age at diagnosis of 30 versus 50 years, and they are associated with a greater tumor size, the presence of multiple renal AMLs, and a greater risk of hemorrhage. Both sporadic and TSC-associated AMLs affect women in almost 90% of cases.

5. Which are among the 5 most common factors associated with postinterventional morbidity as described by Murray et al? (multiple answers possible)

   - No-target embolization (applies)
   - Abscess formation (applies)
   - Active retroperitoneal bleeding (applies)
   - Respiratory complications (applies)
   - Femoral pseudoaneurysm requiring repair

Explanation: In Murray's review[6] on embolization of AMLs using different embolic agents, the total postinterventional morbidity was described in 6.9% of patients. The most common factors were nontarget embolization (2.3%), respiratory complications (2.0%), abscess formation (1.6%), active retroperitoneal hemorrhage (1.0%), and allergic reactions and urinary retention (both 0.6%).