


# Journal Pre-proof



Distal stent-graft induced new entry after TEVAR or FET - insights into a new disease from EuREC

Martin Czerny, MD MBA, Holger Eggebrecht, MD, Herve Rousseau, MD, Paul Revel Mouroz, MD, Rolf-Alexander Janosi, MD, Mario Lescan, MD, Christian Schlensak, MD, Dittmar Böckler, MD, Marius Ante, MD, Emma vdr Weijde, MD, Robin Heijmen, MD, Hans Henning Eckstein, MD, Benedikt Reutersberg, MD, Santi Trimarchi, MD, Jürg Schmidli, MD, Thomas Wyss, MD, Romina Frey, MD, Vladimir Makaloski, MD, Jan Brunkwall, MD, Spyridon Mylonas, MD, Zoltan Szeberin, MD, Josef Klocker, MD, Roman Gottardi, MD, Ingrid Schusterova, Julia Morlock, MD, Tim Berger, MD, Friedhelm Beyersdorf, MD, Bartosz Rylski, MD

PII: S0003-4975(20)30529-4

DOI: <https://doi.org/10.1016/j.athoracsur.2020.02.079>

Reference: ATS 33669

To appear in: *The Annals of Thoracic Surgery*

Received Date: 27 July 2019

Revised Date: 10 January 2020

Accepted Date: 4 February 2020

Please cite this article as: Czerny M, Eggebrecht H, Rousseau H, Mouroz PR, Janosi RA, Lescan M, Schlensak C, Böckler D, Ante M, Weijde Ev, Heijmen R, Eckstein HH, Reutersberg B, Trimarchi S, Schmidli J, Wyss T, Frey R, Makaloski V, Brunkwall J, Mylonas S, Szeberin Z, Klocker J, Gottardi R, Schusterova I, Morlock J, Berger T, Beyersdorf F, Rylski B, Distal stent-graft induced new entry after TEVAR or FET - insights into a new disease from EuREC, *The Annals of Thoracic Surgery* (2020), doi: <https://doi.org/10.1016/j.athoracsur.2020.02.079>.

This is a PDF file of an article that has undergone enhancements after acceptance, such as the addition of a cover page and metadata, and formatting for readability, but it is not yet the definitive version of record. This version will undergo additional copyediting, typesetting and review before it is published in its final form, but we are providing this version to give early visibility of the article. Please note that, during the production process, errors may be discovered which could affect the content, and all legal disclaimers that apply to the journal pertain.

© 2020 by The Society of Thoracic Surgeons

## Distal stent-graft induced new entry after TEVAR or FET - insights into a new disease from EuREC

Running head: dSINE after TEVAR/ FET

<sup>1</sup>Martin Czerny MD MBA, <sup>2</sup>Holger Eggebrecht MD, <sup>3</sup>Herve Rousseau MD, <sup>3</sup>Paul Revel Mouroz MD, <sup>4</sup>Rolf-Alexander Janosi MD, <sup>5</sup>Mario Lescan MD, <sup>5</sup>Christian Schlensak MD, <sup>6</sup>Dittmar Böckler MD, <sup>6</sup>Marius Ante MD, <sup>7</sup>Emma vdr Weijde MD, <sup>7</sup>Robin Heijmen MD, <sup>8</sup>Hans Henning Eckstein MD, <sup>8</sup>Benedikt Reutersberg MD, <sup>9</sup>Santi Trimarchi MD, <sup>10</sup>Jürg Schmidli MD, <sup>10</sup>Thomas Wyss MD, <sup>10</sup>Romina Frey MD, <sup>10</sup>Vladimir Makaloski MD, <sup>11</sup>Jan Brunkwall MD, <sup>11</sup>Spyridon Mylonas MD, <sup>12</sup>Zoltan Szeberin MD, <sup>13</sup>Josef Klocker MD, <sup>14</sup>Roman Gottardi MD, <sup>15</sup>Ingrid Schusterova, <sup>1</sup>Julia Morlock MD, <sup>1</sup>Tim Berger MD, <sup>1</sup>Friedhelm Beyersdorf MD, <sup>1</sup>Bartosz Rylski MD

<sup>1</sup> Department of Cardiovascular Surgery, University Heart Centre Freiburg, Bad Krozingen,

<sup>2</sup> Cardioangiological Center Bethanien, Frankfurt, Germany

<sup>3</sup> Department of Radiology, CHU Rangueil, Toulouse, France

<sup>4</sup> Department of Cardiology and Vascular Medicine, West-German Heart and Vascular Center Essen, University of Duisburg-Essen, Essen, Germany

<sup>5</sup> Department of Cardiothoracic and Vascular Surgery, University of Tübingen, Tübingen, Germany

<sup>6</sup> Department of Vascular Surgery, Ruprecht-Karls University Heidelberg, Germany

<sup>7</sup> Department of Cardiothoracic Surgery St. Antonius Hospital, Nieuwegein

<sup>8</sup> Department of Vascular and Endovascular Surgery Munich Aortic Centre Klinikum rechts der Isar Technical University of Munich Munich Germany

<sup>9</sup> Fondazione IRCCS Ca' Granda Ospedale Maggiore Policlinico Milan, Milan, Italy

<sup>10</sup> Department of Cardiovascular Surgery, Inselspital, Bern University Hospital, University of Bern, Bern, Switzerland

<sup>11</sup> Department of Vascular and Endovascular Surgery, University Hospital of Cologne, Cologne, Germany

<sup>12</sup> Department of Vascular Surgery, Semmelweis University, Budapest, Hungary

<sup>13</sup> Department of Vascular Surgery, Medical University of Innsbruck, Innsbruck, Austria

<sup>14</sup> Department of Cardiovascular and Endovascular Surgery, Paracelsus Medical University of Salzburg, Salzburg, Austria

<sup>15</sup> East Slovakian Heart Center. Kosice, Slovakia

Address reprint requests to

Dr. Czerny  
Department of Cardiovascular Surgery, University Heart Centre Freiburg,  
Albert Ludwigs University Freiburg, Faculty of Medicine  
Hugstetterstrasse 55, D-79106 Freiburg  
e-mail: [martin.czerny@universitaets-herzzentrum.de](mailto:martin.czerny@universitaets-herzzentrum.de)

**Abstract**

**Background.** To learn upon incidence and reasons for distal stent-graft induced new entry (dSINE) after thoracic endovascular aortic repair (TEVAR) or after frozen elephant trunk (FET) implantation, and to develop prevention algorithms.

**Methods.** Analysis of an international multi-center registry (European Registry of Endovascular Aortic Repair Complications- EuREC), 69 dSINE patients out of 1430 TEVAR patients for type B aortic dissection (4,8 %) and 6 dSINE patients out of 100 patients after the FET procedure for aortic dissection (6 %) with secondary morphological comparison.

**Results.** The underlying aortic pathology was acute type B aortic dissection in 33 patients (44%), subacute and/ or chronic type B aortic dissection in 34 patients (45%), acute type A aortic dissection in 3 patients and remaining dissection after type A repair in 3 patients (8%), acute type B intramural hematoma in 2 patients (3%). dSINE occurred in 4.4% of patients in the acute setting and in 4.9% of patients in the subacute/ chronic setting after TEVAR . After, the FET procedure, dSINE occurred in 5.3% of patients in the acute setting and in 6.5% of patients in the chronic setting. The interval between TEVAR/ FET and the diagnosis of dSINE was  $489 \pm 681$  days. Follow-up after dSINE was  $1340 \pm 1151$ days, 4 patients developed recurrence of dSINE (5%). Morphological analysis between patients after TEVAR with and without dSINE showed a smaller true lumen (TL) diameter, a more accentuated oval TL morphology and a higher degree of stent-graft oversizing in patients who have developed dSINE.

**Conclusions.** dSINE after TEVAR/ FET is not rare and occurs with similar incidence after acute and chronic aortic dissection- early and late. Avoiding oversizing in the acute and in the chronic setting as well as carefully selecting patients for TEVAR in post-dissection aneurysmal formation will aid in reducing the incidence of dSINE to a minimum.

Keywords: TEVAR, distal stent-graft induced new entry, complications, treatment

Thoracic endovascular aortic repair (TEVAR) since its introduction in the late 90ies, has become the standard treatment for various thoracic aortic pathology in particular in patients with acute complicated type B aortic dissection (1-5). However, as with each and every new treatment modality, limitations and complications become apparent. One of them when choosing the TEVAR/ FET approach was stent-graft induced new entry (SINE) either proximal (often leading to retrograde type A aortic dissection) or distal (dSINE- usually leading to antegrade false lumen reperfusion) (6-10). Knowledge regarding dSINE developed gradually Japanese and Chinese series pioneered knowledge and a recent review summarized the currently known key components (11-13). However, no multicenter effort pooling a large cohort of patients is available.

The aim of this study was to learn upon incidence and reasons for dSINE after TEVAR or FET and to develop prevention algorithms to reduce the remaining risk of occurrence to a minimum.

## Patients and Methods

*Patients.* Analysis of an international multi-center registry (European Registry of Endovascular Aortic Repair Complications- EuREC from November 1999 to March 2017), 69 dSINE patients out of 1430 TEVAR patients for type B aortic dissection (4,8 %) and 6 dSINE patients out of 100 patients after the FET procedure for aortic dissection (6 %). Secondary morphological comparison of the acute type B subgroup having developed dSINE with patients after TEVAR for acute type B aortic dissection without development of dSINE.

*Definition of dSINE, definition of true lumen shape (definition of ovality) and levels of measurement and evaluation of aortic TL and FL diameter and thrombosis status.* dSINE was defined as any newly detected communication between lumina at the distal end of the

stent-graft having been absent either during primary implantation or during completion imaging at follow-up. Oval true lumen shape was defined as difference between the long and the short axis diameter at the distal end of the stent-graft as shown in **Figure 1**. The long axis length was used to predict the pre-dissection aortic diameter in patients with acute dissection. In these patients, stent-graft diameter was chosen according to predicted pre-dissection aortic diameter with 0% oversizing. In case of chronic aortic dissection the average true lumen diameter (according to long and short axis) was used and about 10% oversizing was applied in the first author's center.

*Parameters.* We collected clinical data, including any kind of previous aortic surgery or intervention, underlying aortic pathology and extension of aortic disease. Procedural data included the index TEVAR procedure, elective or emergent intervention, number of prostheses, covered length and landing zones according to current definitions. The false lumen thrombosis status at different levels was recorded as was the timepoint of occurrence of dSINE. We collected treatment strategies applied and finally compared aortic diameters and aortic shape in patients having had TEVAR for acute type B aortic dissection developing dSINE with aortic diameters and aortic shape in a control group of patients having had TEVAR for acute type B aortic dissection not developing dSINE. We did not collect data regarding side-branch stenting during the index procedure. Information on clinical outcome after distal TEVAR extension or after open surgery was not collected.

*Statistical analysis.* All values are shown as number (percentage) or as mean  $\pm$  standard deviation. IBM SPSS Statistics 24 for Macintosh (Armonk; NY) was used for statistical analysis. The University Heart Centre Freiburg's acute type B aortic dissections database served to compare the aortic as well as the stent-graft diameters. The Mann-Whitney U test was used to compare continuous variables between both groups.

## Results

*Patient demographics.* Patient demographics are shown in **Table 1**. Mean age was  $58 \pm 13$  years and 24% had any kind previous aortic operation or intervention.

*Aortic characteristics.* The underlying aortic pathology was acute type B aortic dissection in 33 patients (44%), subacute and/ or chronic type B aortic dissection in 34 patients (45%), acute type A aortic dissection in 3 patients and remaining dissection after type A repair in 3 patients (8%), acute type B intramural hematoma in 2 patients (3%). In patients with chronic type B aortic dissection, the interval between the acute event and TEVAR was  $472 \pm 715$  days. The presumed etiology as well as the extent of the dissective process are shown in **Table 2**. The main indications for TEVAR were malperfusion and (contained) rupture in the acute phase and diameter increase in the subacute and chronic phase.

*Procedural characteristics- index procedure.* Forty-six procedures were performed electively whereas 36% were performed under emergency conditions. Procedural details are shown in **Table 3**. **Table 4** shows the thrombosis status of the false lumen at different levels after the index procedure. Fifteen patients received tapered stent-grafts whereas 8 had a primary tapered prosthesis and another 7 had a tapered stent-graft as the most distal prosthesis. One patient received a bare stent distal extension during the index procedure.

*dSINE incidence and time interval to index procedure.* dSINE was observed in 69 out of 1430 patients after TEVAR (4,8 %) and in 6 out of 100 patients after the FET procedure (6 %). dSINE occurred in 4.4% of patients in the acute setting (33 out of 739 patients) and in 4.9% of patients in the subacute/ chronic setting after TEVAR (34 out of 691 patients). After the FET procedure, dSINE occurred in 5.3% in the acute setting (3 out of 54 patients) and in

6.5% in the chronic setting (3 out of 46 patients). The interval between TEVAR/ FET and the diagnosis of dSINE was  $489 \pm 681$  days.

*dSINE management.* In 28 patients (37%) a conservative approach was chosen, 42 patients (56%) underwent TEVAR extension and 5 patients (7%) underwent open surgical conversion. Follow-up after dSINE was  $1340 \pm 1151$  days, 4 patients developed recurrence of dSINE (5%) (**Table 5**). **Figure 2** shows CTA scans of a patient with the recurrent occurrence of dSINE.

*Aortic diameters in patients with and without dSINE.* Morphological analysis between patients after TEVAR with and without dSINE showed a smaller TL diameter ( $23 \pm 7$  vs.  $34 \pm 6$ ,  $p < 0.001$ ), a more accentuated oval postoperative stent-graft morphology ( $5 \pm 4$  (ratio 1:1.18) vs.  $2 \pm 2$  (ratio 1:1.08),  $p < 0.001$ ) and a higher degree of stent-graft oversizing in patients having developed dSINE ( $10 \pm 6$  vs.  $3 \pm 6$ ,  $p < 0.001$ ) (**Table 6**). The entire measurements in several aortic segments are summarized in Supplemental Table 1.

## Comment

The majority of patients had acute type B aortic dissection as the underlying aortic pathology warranting TEVAR, followed by a high number of patients undergoing TEVAR for subacute and chronic type B aortic dissection. Where type B aortic dissection has been regarded as the hazard-free dissection without the need for treatment in many cases, recent knowledge upon risk factors for the presence or the development of early or late complications has completely turned the page (**4,15-17**). This has led to a broader application of TEVAR in this patient cohort which per se also leads to a potentially higher number of patients sustaining early or late complications such as dSINE.



Also in patients with post-dissection aneurysmal formation, TEVAR has gained widespread acceptance but it has to be taken into the consideration that TEVAR alone is rarely capable to effectively treat the complex underlying pathology where the efficacy is strongly dependent on various conditions (18). As to the nature of the disease, the membrane has often stiffened over time and the potential for remodeling is lower. Therefore, the shear-stress between the distal end of the stent-graft and the dissection membrane is high and may cause dSINE- early or late- tapered stent-graft seem to play a major role in reducing dSINE to a minimum in these clinical scenarios. Despite FET and TEVAR being different conceptual approaches, the pathophysiological mechanisms behind the occurrence of dSINE are very similar.

Results after surgery for acute type A aortic dissection have made a leap towards lower mortality in the last two decades and the FET technique is applied more frequently (19-21). As many patients will undergo a stringent follow-up in an aortic outpatient clinic, aneurysm formation in residual dissection after type A repair is frequently seen. (22,23). The FET technique is applied in patients with acute type A aortic dissection, mainly in those where the primary entry tear cannot be excluded by surgical means due to its distal location (24,25). Similar to classical TEVAR, the interaction between the distal end of the stent-graft and the dissection membrane may lead to dSINE due to the before mentioned mechanism with the addition that the stent-graft design of the FET prosthesis might also play an important role with regard to distribution of radial force (26).

With regard to procedural characteristics, there was an even distribution between acute and chronic indications for both TEVAR and FET. Manufacturer, size as well as number of prostheses were evenly distributed and in the majority of patients.

The incidence of dSINE was similar between the acute and the chronic setting after both- TEVAR and the FET procedure indicating mechanisms of occurrence beyond the timepoint of treatment. The high mean variation when dSINE occurred- early or late after the index procedure- shows the unpredictability. Interestingly, dSINE frequently was a diagnosis by chance during follow-up and was rarely associated with acute chest pain which is frequently seen in acute aortic dissection irrespective of type. Treatment approaches varied substantially from conservative therapy to thoracoabdominal replacement (27). As these are registry data and imaging was not available, the reasons why one or the other treatment modality was chosen, remain speculative.

As a classical control group is lacking, we aimed at understanding similarities and differences between patients with and without developing dSINE. Consequently, we selected the subgroup of patients who underwent TEVAR for acute type B aortic dissection and compared aortic diameter and shape at the level of the distal end of the stent-graft with patients who underwent TEVAR for acute type B aortic dissection in the first author's institution who did not develop dSINE. Patients developing dSINE had both- a smaller true lumen diameter and a more oval true lumen shape indicating true lumen compression and eventually malperfusion during the initial phase and eventually most important, that oversizing of the stent-grafts used was more frequent in the ones who developed dSINE underlining the importance of sizing. Recent evidence suggested that dSINE occurs more frequently in the hyperacute stage which prompted many do delay therapy if the clinical course permits to do so. When we set up this study, we did not differentiate into hyperacute and acute which does not let us to distinguish between these two phases.

Rationale for aggressive treatment- From a functional point of view in primary type B aortic dissection, we do have data to correlate the size of the primary entry tear to progression of

disease in particular with regard to diameter progression. This mirrors exactly what we do observe in dSINE- rapid diameter increase in the majority of cases. This is what drives the attitude to follow an aggressive treatment strategy.

Stent-graft sizing in patients with acute type B aortic dissection is demanding and several options are available. Most importantly, one has to understand that during the acute event, there is an acute diameter increase in particular in the proximal descending aorta by 20%, this has been shown by retrospective imaging studies (28). However, the proximal landing zone remains the most important determinant when choosing the appropriate stent-graft size- tapered devices present a very good solution in combining both- needs and demands- regarding the correct stent-graft size.

Recently, new approaches like the PETTICOAT or the STABILIZE concept have entered the clinical arena and it remains to be shown if their routine use will be able to further reduce the occurrence of dSINE (29,30). Additionally, a “distal first” concept of deployment in case of at least 2 prostheses has been advocated to prevent dSINE which also remains to be confirmed by larger studies (13).

*Limitations and strengths.* This analysis has all limitations associated with retrospectively collected registry data. Potential coding errors, absence of external validation and interobserver variability in particular due to the lack of imaging data for detailed morphologic analyses. On the other hand, this is a respectively large series of a new disease where- to date- little has been known with regard to incidence, mechanisms behind the development and finally, where initial recommendations for prevention can be provided.

Summarizing, dSINE after TEVAR/ FET is not rare and occurs with similar incidence after acute and chronic aortic dissection- early and late. Avoiding oversizing in the acute and in the chronic setting as well as carefully selecting patients for TEVAR in post-dissection aneurysmal formation will aid in reducing the incidence of dSINE to a minimum.

Journal Pre-proof

**References**

- 1) Grabenwöger M, Alfonso F, Bachet J, Bonser R, Czerny M, Eggebrecht H, Evangelista A, Fattori R, Jakob H, Lönn L, Nienaber C, Rocci G, Rousseau H, Thompson M, Weigang E, Erbel R. ESC/EACTS position statement on thoracic endovascular aortic repair (TEVAR) *Eur J Cardiothorac Surg* 2012;42:17-24.
- 2) Erbel R, Aboyans V, Boileau C, Bossone E, Di Bartolomeo R, Eggebrecht H, Evangelista A, Falk V, Frank H, Gaemperli O, Grabenwöger M, Haverich A, Iung B, Manolis AJ, Meijboom F, Roffi M, Rousseau H, Sechtem U, Sirnes PA, von Allmen RS, Vrints CJM. Document reviewers: Nihoyannopoulos P, Tednera M, Czerny M, Deanfield J, Di Mario C, Pepi M, Taboada MJS, van Sambeek MR, Vlachopoulos C, Zamorano JL. 2014 ESC Guidelines on the diagnosis and treatment of aortic diseases- Document covering acute and chronic aortic diseases of the thoracic and abdominal aorta of the adult- The Task Force for the Diagnosis and Treatment of Aortic Diseases of the European Society of Cardiology (ESC) *Eur Heart J* 2014;35:2873-926.
- 3) Weiss G, Wolner I, Folkmann S, Sodeck G, Schmidli J, Grabenwöger M, Carrel T, Czerny M. The location of the primary entry tear in acute type B aortic dissection affects early outcome. *Eur J Cardiothorac Surg* 2012;42:571–576.
- 4) Nienaber C, Kische S, Rousseau H, Eggebrecht H, Rehders T, Kundt G, Glass A, Scheinert D, Czerny M, Kleinfeldt T, Zipfel B, Labrousse L, Fattori R. Endovascular Repair of Type B Aortic Dissection - Long term Results of the randomized INvestigation of STEnt-grafts in Aortic Dissection (INSTEAD-XL) Trial. *Circ Cardiovasc Intervent* 2013;6:407-16.

- 5) Brunkwall J, Kasprzak P, Verhoeven E, Heijmen R, Taylor P; ADSORB Trialists, Alric P, Canaud L, Janotta M, Raithel D, Malina W, Resch T, Eckstein HH, Ockert S, Larzon T, Carlsson F, Schumacher H, Classen S, Schaub P, Lammer J, Lönn L, Clough RE, Rampoldi V, Trimarchi S, Fabiani JN, Böckler D, Kotelis D, Böckler D, Kotelis D, von Tenng-Kobligk H, Mangialardi N, Ronchey S, Dialetto G, Matussevitsh V. Endovascular repair of acute uncomplicated aortic type B dissection promotes aortic remodelling: 1 year results of the ADSORB trial. *Eur J Vasc Endovasc Surg* 2014;48:285-91.
- 6) Berger T, Kreibich M, Morlock J, Kondov S, Scheumann J, Kari FA, Rylski B, Siepe M, Beyersdorf F, Czerny M. True and false lumen diameter changes in the downstream aorta after frozen elephant trunk implantation. *Eur J Cardiothorac Surg* 2018;54:375-81.
- 7) Iafrancesco M, Goebel N, Mascaro J, Franke UFW, Pacini D, Di Bartolomeo R, Weiss G, Grabenwöger M, Leontyev SA, Mohr FW, Sioris T, Jakob H, Tsagakis K; International E-vita Open Registry Group. Aortic diameter remodelling after the frozen elephant trunk technique in aortic dissection: results from an international multicentre registry. *Eur J Cardiothorac Surg* 2017;52:310-318.
- 8) Shrestha M, Martens A, Kaufeld T, Beckmann E, Bertele S, Krueger H, Neuser J, Fleissner F, Ius F, Abd Alhadi F, Hanke J, Schmitto JD, Cebotari S, Karck M, Haverich A, Chavan A. Single-centre experience with the frozen elephant trunk technique in 251 patients over 15 years. *Eur J Cardiothorac Surg* 2017 ;52:858-866.

- 9) Weiss G, Santer D, Dumfarth J, Pisarik H, Harrer ML, Folkmann S, Mach M, Moidl R, Grabenwoger M. Evaluation of the downstream aorta after frozen elephant trunk repair for aortic dissections in terms of diameter and false lumen status. *Eur J Cardiothorac Surg* 2016;49:118-24.
- 10) Jánosi RA, Tsagakis K, Bettin M, Kahlert P, Horacek M, Al-Rashid F, Schlosser T, Jakob H, Eggebrecht H, Erbel R. Thoracic aortic aneurysm expansion due to late distal stent graft-induced new entry. *Catheter Cardiovasc Interv* 2015;85:E43-53.
- 11) Dong Z, Fu W, Wang Y, Wang C, Yan Z, Guo D, Xu X, Chen B. Stent-graft induced new entry after endovascular repair for Stanford type B aortic dissection. *J Vasc Surg* 2010; 52:1450-7.
- 12) Ninomiya M, Takamoto S, Kotsuka Y, Kubota H. Stent-graft induced intimal injury one year after surgery. *J Thorac Cardiovasc Surg* 2002;123:371-2.
- 13) Hughes GC. Stent-graft induced new entry tear (SINE): Intentional and NOT. *J Thorac Cardiovasc Surg* 2019;157:101-106.
- 14) Rylski B, Reser D, Kari F, Perez V, Beyersdorf F, Siepe M, Czerny M. Acute Non A, non B aortic dissection: definition, treatment and outcome. *Eur J Cardiothorac Surg* 2017;52:1111-7.
- 15) Loewe C, Czerny M, Sodeck GH, Ta J, Schoder M, Funovics M, Dumfarth J, Ehrlich M, Grimm M, Lammer J. A new mechanism by which an acute type B aortic dissection is primarily complicated, becomes complicated, or remains uncomplicated. *Ann Thorac Surg* 2012;93:1215-22.

- 16) Trimarchi S, Jonker FH, van Bogerijen GH, Tolenaar JL, Moll FL, Czerny M, Patel HJ. Predicting enlargement in type B aortic dissection. *Ann Cardiothorac Surg* 2014;3:285-91.
- 17) Ante M, Mylonas S, Skrypnik D, Bischoff MS, Rengier F, Brunkwall J, Böckler D. Prevalence of the Computed Tomographic Morphological DISSECT Predictors in Uncomplicated Stanford Type B Aortic Dissection. *Eur J Vasc Endovasc Surg* 2018;56:525-533.
- 18) Czerny M, Rodler S, Fakhimi S, Sodeck G, Funovics M, Dumfarth J, Holfeld J, Schoder M, Juraszek A, Dziodzio T, Zimpfer D, Krähenbühl E, Rosenhek R, Grimm M. Mid-term results of TEVAR in patients with aneurysms involving the descending aorta originating from chronic type B dissections. *Ann Thorac Surg* 2010;90:90-94.
- 19) Conzelmann LO, Weigang E, Mehlhorn U, Abugameh A, Hoffmann I, Blettner M, Eitz CD, Czerny M, Vahl CF; GERAADA Investigators. Mortality in patients with acute aortic dissection type A: analysis of pre- and intraoperative risk factors from the German Registry for Acute Aortic Dissection Type A (GERAADA). *Eur J Cardiothorac Surg* 2016;49:e44-52.
- 20) Sievers HH, Richardt D, Diwoky M, Auer C, Bucsky B, Nasser B, Klotz S. Survival and reoperation after valve-sparing root replacement and root repair in acute type A aortic dissection. *J Thorac Cardiovasc Surg* 2018;156:2076-2082.



- 21) Most H, Reinhard B, Gahl B, Englberger L, Kadner A, Weber A, Schmidli J, Carrel TP, Huber C. Is surgery in acute dissection type A still contraindicated in the presence of preoperative neurological symptoms? *Eur J Cardiothorac Surg* 2015;48:945-50.
- 22) Czerny M, Schmidli J, Adler S, van den Berg J, Bertoglio L, Carrel T, Chiesa R, Clough RE, Eberle B, Etz C, Grabenwöger M, Haulon S, Jakob H, Kari FA, Mestres CA, Pacini D, Resch T, Rylski B, Schönhoff F, Shrestha M, von Tengg-Kobligk H, Tsagakis K, Wyss TR. Current options and recommendations for the treatment of thoracic aortic pathologies involving the aortic arch- an expert consensus document of the European Association for Cardio-Thoracic Surgery (EACTS) and the European Society of Vascular Surgery (ESVS). *Eur J Cardiothorac Surg* 2019;55:133-62.
- 23) Rylski B, Hahn N, Czerny M, Wolkewitz M, Blanke P, Plonek T, Kondov S, Beyersdorf F. Fate of the dissected aortic arch after ascending replacement in type A aortic dissection. *Eur J Cardiothorac Surg* 2017;24:655-658.
- 24) Shrestha M, Bachet J, Bavaria J, Carrel T, De Paulis R, Di Bartolomeo R, Etz C, Grabenwöger M, Grimm M, Haverich A, Jakob H, Martens A, Mestres C, Pacini D, Resch T, Schepens M, Urbanski P, Czerny M. Current status and recommendations for use of the frozen elephant trunk technique- A position paper of the Vascular Domain of EACTS. *Eur J Cardiothorac Surg* 2015;47:759-69.

- 25) Kreibich M, Berger T, Siepe M, Rylski B, Beyersdorf F, Czerny M. Aortic Reinterventions after the Frozen Elephant Trunk Procedure. *J Thorac Cardiovasc Surg* 2019, e-pub ahead of print.
- 26) Berger T, Weiss G, Voetsch A, Arnold Z, Kreibich M, Rylski B, Krombholz-Reindl P, Winkler A, Mach M, Geissler D, Seitelberger R, Siepe M, Beyersdorf F, Grabenwoeger M, Czerny M, Gottardi R. Multicentre experience with two commercially available frozen elephant trunk prostheses in the treatment of acute aortic dissection. *Eur J Cardiothorac Surg* 2019, e-pub ahead of print.
- 27) Jassar A, Kreibich M, Morlock J, Kondov S, Scheumann J, Kari FA, Rylski B, Siepe M, Jonaszik A, Keyl C, Humburger F, Beyersdorf F, Czerny M. Thoracoabdominal aortic replacement after thoracic endovascular aortic repair with large stent-grafts: diameter correction with modified use of the Vascutek® Siena™ collared branched graft. *Ann Thorac Surg* 2018;105:587-91.
- 28) Rylski B, Munoz C, Reser D, Schoenhoff F, Carrel T, Eckstein HH, Reutersberg B, Erbel R, Janosi A, Lescan M, Schlensak C, Siepe M, Beyersdorf F, Czerny M. How does descending aorta geometry change when it dissects? *Eur J Cardiothorac Surg* 2018;53:815-21.
- 29) Nienaber CA, Kische S, Zeller T, Rehders TC, Schneider H, Lorenzen B, Bünger C, Ince H. Provisional extension to induce complete attachment after stent-graft placement in type B aortic dissection: the PETTICOAT concept. *J Endovasc Ther* 2006;13:738-46.

- 30) Faure EM, El Batti S, Abou Rjeili M, Julia P, Alsac JM. Mid-term Outcomes of Stent Assisted Balloon Induced Intimal Disruption and Relamination in Aortic Dissection Repair (STABILISE) in Acute Type B Aortic Dissection. *Eur J Vasc Endovasc Surg* 2018;56:209-215.

Journal Pre-proof

**Figure legends**

**Figure 1.** The CTA scan shows the measurement of the ovality of the stent-graft at the distal end and it's calculation.

**Figure 2.** (A) Postoperative computed tomography angiography (CTA) scan of a patient after total aortic arch replacement via the frozen elephant trunk technique. (B) Follow-up CTA revealed a dSINE and was treated by TEVAR (C) In the same patient a dSINE occurred once again (D) and was treated by TEVAR once more (E).

**Table 1- Baseline characteristics**

	n=75
<b>Demographics</b>	
Male	50 (67)
Age	58 ± 13
<b>Medical history</b>	
Hypertension	68 (91)
Coronary Artery Disease	11 (15)
Previous CABG	4 (5)
Previous aortic surgery/intervention*	18 (24)
Ascending	16 (21)
Arch	5 (7)
Descending	2 (3)
Abdominal	0 (0)

Data are presented as number (%); CABG, coronary artery bypass grafting \*multiple mentions possible

**Table 2- Aortic characteristics**

	n=75
<b>Underlying aortic disease</b>	
Acute type A dissection/ remaining dissection after type A repair	6 (8)
Acute type B dissection	33 (44)
Subacute/chronic type B dissection	34 (45)
Intramural hematoma	2 (3)
Days between acute event and TEVAR in chronic type B aortic dissection	472 ± 715
<b>Presumed etiology*</b>	
Atherosclerotic/hypertensive	61 (81)
Degenerative	7 (9)
Connective tissue disease	5 (7)
Traumatic	2 (3)
Other	1 (1)
<b>Extension of dissection</b>	
→ Descending	1 (1)
→ Abdominal	23 (31)
→ Iliac arteries	49 (65)
N/A	2 (3)

Data are presented as number (%) or as mean ± standard deviation; \*, multiple mentions possible; N/A, not available

**Table 3- Procedure characteristics**

	n=75
Type of procedure	
Elective	46 (61)
Emergency	27 (36)
N/A	2 (3)
Type of Prosthesis*	
Medtronic ©	32 (43)
Gore ©	16 (21)
Bolton Medical ©	20 (27)
Vascutek ©	6 (8)
N/A	2 (3)
Number of prostheses	
n=1	63 (84)
n=2	8 (11)
n=3	4 (5)
Landing zone	
Zone 2	47 (63)
Zone 3	27 (36)
Zone 4	1 (1)
Intended or accidental overstenting of arch vessels	35 (47)
Left subclavian artery	34 (45)
Brachiocephalic trunk	1 (1)
Supraaortic transposition*	21 (28)
Carotid-subclavian bypass	21 (28)
Extraanatomic bypass to the left subclavian artery	1 (1)
Ascendo-Bicarotical bypass	1 (1)
Distal part of the stent-graft crosses thoracoabdominal transition	9 (12)
Distal extension with bare stent	1 (1)
Covered length, mm	174 ± 51

Data are presented as number (%) or as mean ± standard deviation; mm, milimetre; \*, multiple mentions possible; N/A, not available;

**Table 4- Early and late postoperative aortic characteristics**

	n=75
Immediate postoperative false lumen status at stent-graft level	
Thrombosed	45 (60)
Partially thrombosed	26 (35)
Patent	3 (4)
Immediate postoperative false lumen status at thoracoabdominal transition	
Thrombosed	16 (21)
Partially thrombosed	25 (33)
Patent	32 (43)
N/A	2 (3)
Occurrence of dSINE, days since TEVAR	489 ± 681
False Lumen Status at stent-graft level (at diagnosis of dSINE)	
Thrombosed	28 (37)
Partially thrombosed	36 (48)
Patent	9 (12)
N/A	2 (3)
False Lumen Status at thoracoabdominal transition (at diagnosis of dSINE)	
Thrombosed	14 (19)
Partially thrombosed	23 (31)
Patent	35 (47)
N/A	3 (4)

Data are presented as number (%) or as mean ± standard deviation; N/A, not available



**Table 5- Management dSINE**

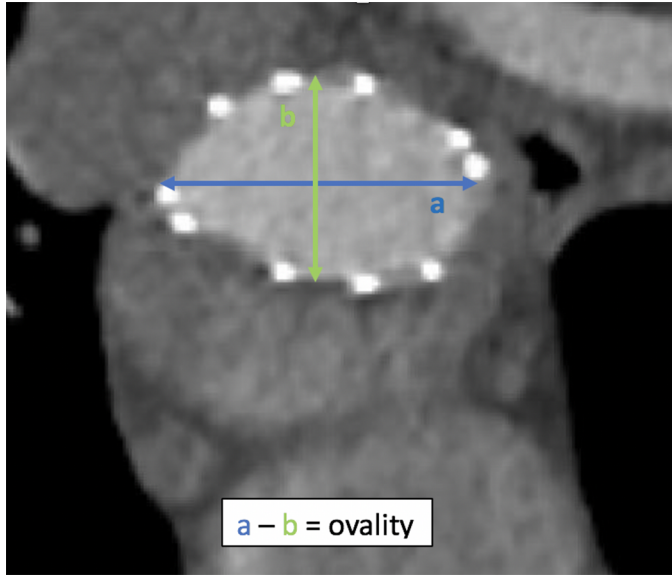
	n=75
Conservative	28 (37)
TEVAR extension	42 (56)
Classical surgery	5 (7)
Follow-up after dSINE, days	1340 ± 1151
Recurrence of dSINE	4 (5)

Data are presented as number (%) or as mean ± standard deviation

**Table 6- Aortic diameters**

	dSINE (+)	dSINE (-)	p-value
Patients with acute type B dissection	33	71	
Mean preoperative true lumen diameter mm	23 ± 7	34 ± 6	<0.001
Covered length, mm	171 ± 42	150 ± 35	0.013
Mean stent diameter, mm	33 ± 5	37 ± 5	<0.001
Postoperative stent diameter ovality, mm	5 ± 4	2 ± 2	<0.001
Mean oversizing, mm	10 ± 6	3 ± 6	<0.001

Data are presented as number (%) or as mean ± standard deviation; N/A, not available; mm, millimeter



Journal Pre-proof

