

# Quantitative motor unit action potential analysis of paraspinal muscles, diagnostic imaging and necropsy findings in 36 horses suspected of cervical impairment

C. Graubner<sup>1</sup>, W. Bergmann<sup>2</sup>, V. Gerber<sup>1</sup>, S. Veraa<sup>3</sup>, A. Oevermann<sup>4</sup>, ID. Wijnberg<sup>3</sup>

<sup>1</sup>Institut Suisse de Médecine Equine, Vetsuisse Faculty, University of Berne and Agroscope, Switzerland;

<sup>2</sup>Department of Pathobiology, Faculty of Veterinary Medicine, Utrecht University, The Netherlands;

<sup>3</sup>Department of Equine Sciences, Faculty of Veterinary Medicine, Utrecht University, NL; <sup>4</sup>Division of Neurological Sciences DCR-VPH, Vetsuisse Faculty, University of Berne, Switzerland

## Summary

**Aims:** To determine the relation between quantitative electromyography (QEMG) of the cervical ventral serratus muscle, radiographic findings and post-mortem gross and histopathological examination in order to calculate the ability of QEMG to localize the region of cervical compressive neuropathy and myelopathy in horses.

**Methods:** In this clinical, non-randomised, partially blinded study (QEMG and histology), 36 warmblood horses with clinical suspicion of cervical spine disease were examined with QEMG in different segments of the ventral serratus muscle. Results were compared to normative data. Diagnostic imaging was performed in 28 cases. All horses were euthanized because of poor clinical prognoses and/or recurrent clinical neurological signs despite treatment and underwent necropsy with emphasis on the cervical nervous tissue and vertebrae. Clinical and diagnostic imaging findings, QEMG results and post mortem findings were compared with each other.

**Results:** Overall mean values of duration (9.54 ms), polyphasia, number of phases (3.6) and size index (0.67) in horses with cervical lesions were significantly ( $P < 0.05$ ) higher than reference data. Clinical examination correlated significantly with several QEMG- and histological changes but not with radiological abnormalities. A reduced neck mobility seems to be a clinically relevant parameter to suspect cervical spine pathology. No significant correlations were found between radiology and any post mortem findings. For QEMG, in two (C5/6 right side and C6/7 left side) out of twelve cervical segments (C1-2, C2-3, C3-4, C4-5, C5-6, C6-7 on both

Quantitative Analyse der Nerven-erregung, diagnostische Bildgebung und Pathologiebefunde der paraspinalen Muskeln bei 36 Pferden mit Verdacht auf eine Schädigung der Nackenmuskulatur.

**Ziele:** Mittels quantitativer Elektromyographie (QEMG) des M. serratus ventralis und dem Vergleich zu den radiologischen Befunden, makroskopischen und histopathologischen Untersuchungen, sollte versucht werden die Lokalisation der neurogenen Kompression im Nackenbereich von Pferden festzustellen.

**Methoden:** In dieser klinischen, nicht randomisierten, teilweise verblindeten Studie (Histologie und QEMG) wurde bei 36 Warmblutpferde mit klinischem Verdacht auf eine Erkrankung der Halswirbelsäule mittels QEMG verschiedene Segmente des ventralen Serratusmuskels untersucht. Die Ergebnisse wurden mit den Referenzwerten verglichen. In 28 Fällen wurde eine diagnostische Bildgebung durchgeführt. Trotz Behandlung wurden alle Pferde aufgrund schlechter klinischer Prognosen und/oder wiederkehrender klinischer neurologischer Symptome eingeschläfert und einer Sektion mit Schwerpunkt auf die Nerven und Wirbeln der Halswirbelsäule unterzogen. Klinische und diagnostische Bildgebungsbefunde, QEMG-Ergebnisse und Pathologie-Befunde wurden miteinander verglichen.

**Ergebnisse:** Die Mittelwerte für die Dauer (9.54 ms), Polyphasie, Anzahl der Phasen (3.6) und Größenindex (0,67) bei Pferden mit Läsionen der Halswirbelsäule waren signifikant ( $P < 0,05$ ) höher als die Referenzdaten. Die klinische Untersuchung korrelierte signifikant mit

<https://doi.org/10.17236/sat00252>

Received: 06.01.2020  
Accepted: 10.03.2020

Quantitative motor unit action potential analysis of paraspinal muscles, diagnostic imaging and necropsy findings in 36 horses suspected of cervical impairment

C. Graubner et al.

sides) statistically significant relations with histopathological changes could be found.

#### Conclusions and Practical Relevance:

In this study, at the level of C5-6-7 QEMG could predict the site of the lesion in the nervous system whereas radiological imaging failed to identify the site of the lesions. Clinical examination correlated significantly with several QEMG- and histological changes but not with radiological abnormalities. QEMG can be added to the examination protocol of horses suspected clinically of suffering from cervical compressive neuropathy and myelopathy.

**Key words:** Horse, quantitative electromyography, cervical compressive neuropathy and myelopathy, cervical spine disease

mehreren QEMG- und histologischen Veränderungen, jedoch nicht mit radiologischen Anomalien. Eine verminderte Halsbeweglichkeit scheint ein klinisch relevanter Parameter für den Verdacht auf eine Pathologie der Halswirbelsäule zu sein. Es wurden keine signifikanten Korrelationen zwischen der Radiologie und pathologischen Befunden festgestellt. Für QEMG in zwei (C5/6 rechte Seite und C6/7 linke Seite) von zwölf Halswirbelsegmenten (C1-2, C2-3, C3-4, C4-5, C5-6, C6-7 auf beiden Seiten) konnten statistisch signifikante Zusammenhänge mit histopathologischen Veränderungen festgestellt werden.

#### Schlussfolgerungen und praktische Relevanz:

In dieser Studie konnte die Lokalisation der Nervenschädigung mittels QEMG auf der Ebene von C5-6-7 vorhersagt werden, während die radiologische Bildgebung diese nicht identifizieren konnte. Die klinische Untersuchung korrelierte signifikant mit mehreren QEMG- und histologischen Veränderungen, jedoch nicht mit radiologischen Befunden. Bei Pferden mit klinischem Verdacht auf neurogene Kompression der Halswirbelsäulen, kann die QEMG zum Untersuchungsprotokoll hinzugefügt werden.

**Schlüsselwörter:** Histologie, Pferd, Nervenkompressionsyndrom, Halswirbelsäule, quantitative Elektromyographie

## Introduction

Horses frequently suffer from neurological impairment related to lesions of the cervical spinal cord and nerve roots.<sup>1-4</sup> Clinical signs include reduced mobility and pain of the neck, dysmetric movements of the front and/or hindlimbs, variable degrees of lameness and ataxia (Mayhew Grade  $\geq 1$ ).<sup>5</sup> In most cases a clinical diagnosis is made by an orthopedic and neurological examination and diagnostic imaging.

Cervical compressive neuropathy and myelopathy can be due to various reasons such as joint effusion, degenerative joint disease, bone cysts, ventral protrusion of the ligamentum flavum, and thickening of the dorsal lamina.<sup>6,7</sup> Cervical compressive neuropathy and myelopathy should not be assessed only radiographically as demonstrated in a recent publication providing evidence that clinically normal horses may show functional narrowing of the vertebral canal in the dorsolateral and ventrolateral regions.<sup>8,9</sup> Additionally this region is not well visualized on standard cervical radiographs.<sup>8</sup>

Myelographic examination can be challenging for localizing a site of cervical compressive neuropathy and myelopathy. The percentage of agreement between the suspected site of the lesion based on myelographic examination with the lesion site based on post mortem

(67-78%) is not necessarily higher compared to the percentage of relation between standard radiographs and post mortem (65-71%).<sup>9,10</sup> More recent techniques like computer tomography (CT) and magnetic resonance imaging (MRI) can give further information.<sup>11,12</sup> For both techniques the size of the horse still remain limiting.<sup>1</sup>

While clinically upper motor neuron (UMN) damage can usually be detected based on clinical signs like incoordination of front and hind limbs, lower motor neuron (LMN) disorders can be more difficult to diagnose and interpret based on only clinical findings (muscle atrophy, weakness, reduced reflexes) and in these cases quantitative electromyography (QEMG) may be helpful.<sup>13,14</sup> This technique enables detection of neurogenic Motor Unit action Potentials (MUP). MUP characteristics' such as duration, amplitude, number of phases, number of turns, size index and percentage of polyphasia will increase as a result of re-innervation. For neurogenic neck problems, this technique has been proven to be useful in localization of a lesion.<sup>15,16</sup> Reference values for the analysis of muscle unit action potentials using QEMG in the neck musculature of horses have been defined by Wijnberg et al. 2012.<sup>17</sup> The usefulness of QEMG in identification of neuropathy in the equine neck has been described in 2009, 2012 and 2016 by the same author.<sup>16,18</sup>

We aimed to assess for the first time the agreement of QEMG findings of clinical cases to clinical signs, diagnostic imaging and post mortem macroscopic and histological examination of nervous tissue and facet joints. We hypothesized that QEMG findings would be associated with histological findings of the segmental nerve roots and spinal cord and the gross changes of the facet joints.

## Materials and Methods

### Horses

Horses presented with clinical signs like ataxia (Mayhew grade  $\geq 1$ ), reduced neck mobility and pain, non-defined lameness and/or muscle atrophy (*M. serratus ventralis*, *M. splenius pars cervicis*). Time from onset of the first clinical signs until presentation to one of the involved clinics could not be evaluated from the case history as owners might not have been aware of more subtle early clinical signs of cervical compressive neuropathy and myelopathy. They all had a neurological examination by the local internal medicine service. Vital parameters were controlled, cranial nerves were tested and the neck mobility and reaction to deep palpation of the brachiocephalic muscle were noted. Horses were looked at in walk and trot (if possible) on a straight line and in circles on both hands on hard and soft ground. They were backed up, walked on a straight line with the head elevated and walked up and down a slope in a straight and sinuous line. They were further examined using diagnostic imaging and QEMG. If a cervical compressive neuropathy and myelopathy was diagnosed and the horse had to be euthanized due to severe signs and expected bad prognosis or recurrence after treatment (n=1), the horse was included in the study if owners agreed to do a post mortem. Cases were collected from 2008 to 2013.

### QEMG examination and analysis

Within each clinic (UU, B) always the same person blinded to the results of the clinical and neurological examination performed the QEMG. QEMG was performed after clinical examination and after diagnostic imaging. Details on definition, and materials & methods of QEMG examination have been described in former publications.<sup>19,20</sup> Horizontal segments between the transverse processes were chosen for gross clinical localization of the segmental nerve roots and nerves. EMG signals were recorded using a portable apparatus<sup>1</sup> and 26-gauge concentric EMG needle electrodes. Band pass was between 5 Hz and 10 kHz. Sweep speed was 10-20ms/division. Amplifier gain was 50-100  $\mu\text{V}$  for spontaneous activity and 100-500  $\mu\text{V}$  for MUP recording.

Insertional activity, pathological spontaneous activity (PSA) like positive sharp waves, fibrillation potentials and complex discharges, MUPs and satellite potentials

were segmentally recorded in the ventral serratus muscle. Thirty-six horses were examined, 33 bilaterally, two only on the left side and one only on the right side. The first cervical segment (C1-2) was only examined in nine horses by QEMG as in this region muscle activity is difficult to induce and because this is not a potential area of interest since cervical pathology is most frequently present in the C4-Th1 region in adult warmblood horses.<sup>10,21</sup> Subsequently this segment was omitted for calculations due to inappropriate sample size. At least three insertions and three directions per insertion were made per cervical segment. The needle was redirected several times and by selecting sharp sounding MUPs while the needle was withdrawn with 3 mm increments, sampling was performed throughout the muscle. PSA was considered indicative of pathology if present repeatedly in  $\geq$  two locations. MUPs were selected partly in a semiautomatic way, using a trigger line that selects identical MUPs above chosen amplitude. The automatic MUPs selection was manually corrected off line. End point of MUP duration was corrected by on screen visual assessment.<sup>15,22-25</sup> Amplitude, duration and number of phases were obtained from 20-30 MUPs per muscle, with a maximal rise time of 0.8 ms rise and identically firing at least 4 times. Mean percentage of polyphasic MUPs was calculated. In addition, previously described parameters size index and MUP area were recorded and analysed.<sup>18</sup> Size index was calculated automatically by the EMG software using the formula  $2 \times \log(\text{amplitude}) + \text{area}/\text{amplitude}$ . Segments with values of one or more parameters higher than published reference values were coded as 1, normal segments as 0.

### Diagnostic imaging

In both facilities different boarded specialists in diagnostic imaging performed the interpretation of standard laterolateral and oblique images of the neck. Any abnormal findings were coded as 1, normal findings as 0.

Quantitative motor unit action potential analysis of paraspinal muscles, diagnostic imaging and necropsy findings in 36 horses suspected of cervical impairment

C. Graubner et al.

**Table 1:** Numbers of horses with gross pathology and histological examinations compared to quantitative electromyography (QEMG) examinations per segment.

|              | Nerve Roots | Spinal cord | Facet Joints | QEMG |
|--------------|-------------|-------------|--------------|------|
| <b>c1-2l</b> | 2           | 22          | 5            | 9    |
| <b>c1-2r</b> | 2           | 22          | 6            | 20   |
| <b>c2-3l</b> | 9           | 21          | 17           | 14   |
| <b>c2-3r</b> | 8           | 21          | 15           | 29   |
| <b>c3-4l</b> | 11          | 23          | 19           | 30   |
| <b>c3-4r</b> | 9           | 23          | 17           | 36   |
| <b>c4-5l</b> | 12          | 26          | 19           | 18   |
| <b>c4-5r</b> | 11          | 24          | 18           | 20   |
| <b>c5-6l</b> | 15          | 28          | 20           | 20   |
| <b>c5-6r</b> | 16          | 28          | 19           | 27   |
| <b>c6-7l</b> | 18          | 26          | 19           | 29   |
| <b>c6-7r</b> | 19          | 26          | 20           | 34   |

Nanocarrier in der Tiermedizin – eine Pilotstudie zur Behandlung der feline Hyperthyreose mit auf Nanocarriern basierender Thiamazolsalbe

D. Böhm et al.

Abnormalities were signs of degenerative facet joint pathology (thickened facet joints, irregular joint surfaces, periarticular new bone formation), dorsal or ventral disposition of the vertebral bodies and signs of narrowing of the cervical canal.

### Necropsy

All horses underwent a post mortem. Horses were euthanized just after diagnosis and prognosis had been made or at latest 4 weeks later (one horse was treated and euthanized as improvement was only marginal). Pathologists were blinded to the QEMG results and findings on radiographs. Histologically, segmental nerves (from C2-C3 to C7-Th1 on both sides) and nerve roots were examined in 24 horses and the spinal cord in 31 horses (table 1). The facet joints were macroscopically examined in 33 horses.

Any abnormal findings were coded as 1, normal findings as 0.

The cervical and the cranial part of the thoracic spine were disconnected from the body by sawing through the body of vertebra T4. Most of the musculature surrounding the neck was removed. Then the spinal nerves and their nerve roots were dissected and the dorsal vertebral arches subsequently removed to expose the spinal cord. After removal and gross examination of the spinal cord, the spinal canal, including the removed dorsal parts of the vertebrae, was inspected for space occupying processes. The vertebral column was flexed and extend-

ed to see whether obstruction of the spinal cord could occur during movement. The remaining vertebral bodies were sawn sagittally and flexion and extension with subsequent examination was performed a second time. The facet joints from C2 caudal to T2 were opened and macroscopically examined. The spinal cord, nerves and nerve roots were fixed in 10% buffered formalin with the dura mater cut open to allow optimal fixation. Representative samples of the spinal cord segments and nerve roots were embedded in paraffin, cut into sections of 3µm thickness, stained with haematoxylin and eosin (HE) and evaluated with light microscopy.

### Statistics

Data were assessed descriptively using NCSS 2009. To calculate relations, QEMG was compared with each of the following parameters: histology of the nerve roots, spinal cord histology and facet joint pathology. The same was done for radiographs and histology of the nerve roots, spinal cord histology and facet joint pathology. The parameters were assigned to the cervical segment and data were assessed using a T-Test for means and standard deviation, a two sample Cross Tabulation Chi-Square (Fischer's exact test; NCSS 2009) and logistic regression. In a second step using the same statistical methods, QEMG results of each segment were compared to histology of the nerve roots of the same side independent of cervical segments and the whole cervical spinal cord independent of cervical segments and side.

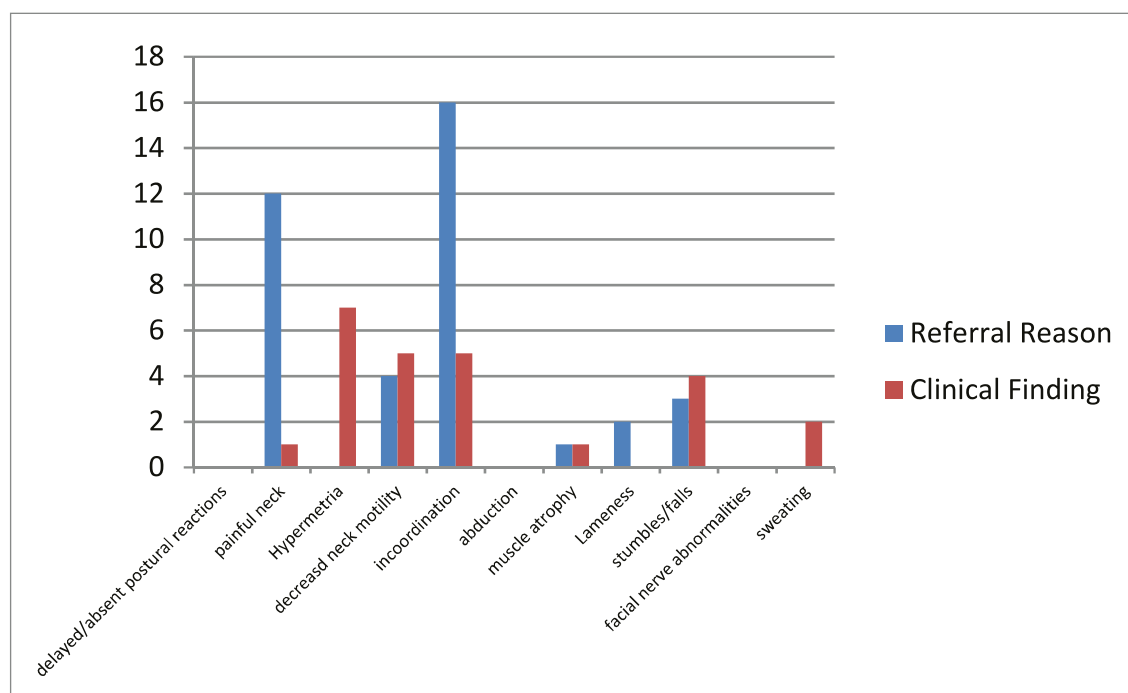


Fig 1: Clinical signs of horses included in the current study presented at the Equine Clinics of the Universities of Utrecht and Berne.

The same tests were used for calculating a relation of the clinical examination to QEMG results, histology of the nerve roots, segmental histology of the spinal cord and radiographs. Probability value for significance was set  $P < 0.05$ . Due to small sample size statistical trends were set for  $0.05 < P < 1$ .

## Results

Thirty-six client-owned warmblood horses met the inclusion criteria (4 stallions, 23 geldings, 9 mares). To get a larger sample size, it was decided to combine data sets of two referral clinics which had boarded specialists working in all relevant disciplines. Figure 1 shows the reason for referral to an equine clinic and the results of the clinical examination. In 28 horses radiographs of the neck were obtained.

### Clinical findings

Figure 1 shows the clinical findings the owner or referring veterinarians observed compared to the findings at the Equine Clinics of the Universities of Utrecht and Berne. Painful movement of the neck and uncoordinated gait of the horse were the main findings at the university clinics.

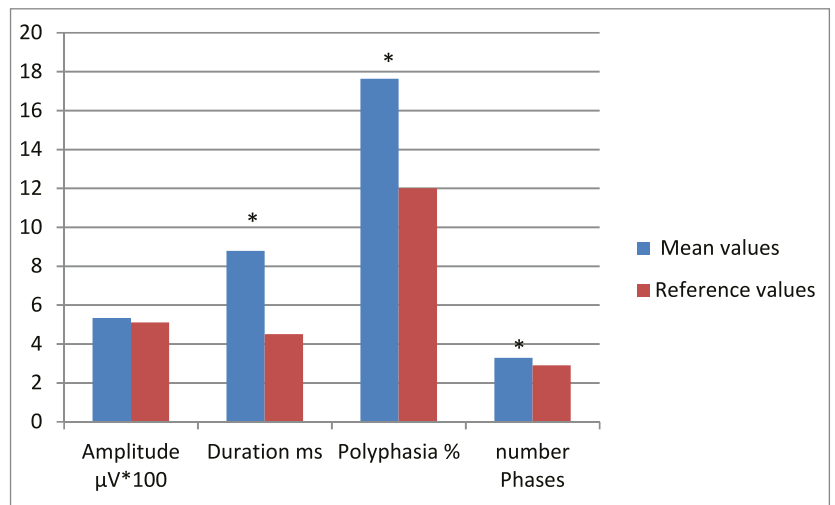
Pain during neck palpation or neck movement was the clinical parameter that showed statistically significant relations with abnormal QEMG results in region C5/6 and a frequency high enough to calculate odds ratios between this clinical parameter and QEMG.

### QEMG findings in patients and controls

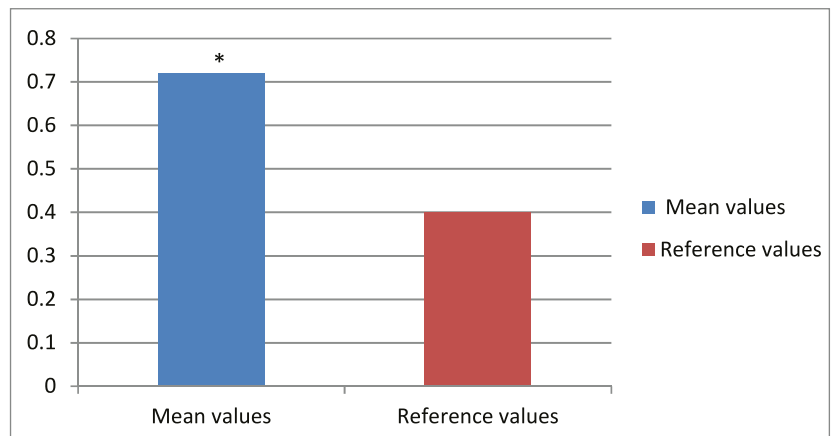
With QEMG no PSA (pathological spontaneous activity) at more than 2 locations within one segment was observed in any patient. The overall mean amplitude 537.2  $\mu\text{V}$  was similar compared to reference values (537.2.12  $\mu\text{V}$  [reference 510  $\mu\text{V}$ ];  $p=0.35$ ) (Wijnberg et al. 2011).<sup>18</sup> In contrast, the overall mean values of duration (9.54ms [reference 4.5ms];  $p<0.01$ ), polyphasia 18.9% [reference 12%];  $p=0.04$ ), number of phases (3.6 [reference 2.9];  $p<0.01$ ) and size index (0.67 [reference 0.4];  $p<0.01$ ) were significantly higher in affected horses than compared to reference values in normal warmblood horses (fig 2a, b) indicating reinnervation due to neuropathy.<sup>16,23,26</sup>

### Segmental correlations

There was no significant relation between segmental radiographic abnormalities and segmental post mortem findings, nor segmental QEMG abnormalities. The relation of QEMG and histology of the segmental nerve roots was not significant. The relation of QEMG and histology of the spinal cord was significant in segment C6/7 on the left side ( $p=0.0008$ ). Between QEMG re-



**Fig 2a:** Quantitative electromyography (QEMG) mean values in comparison to mean reference values for the same cervical segments on warmblood horses. The mean amplitude 537.2  $\mu\text{V}$  was not significantly higher compared to mean reference values (537.2.12  $\mu\text{V}$  [510  $\mu\text{V}$ ];  $p=0.35$ ) (Ref). The overall mean values of duration (9.54ms [4.5ms];  $p<0.01$ ), polyphasia 18.9% [12%];  $p=0.04$ ), number of phases (3.6 [2.9];  $p<0.01$ ) and size index (0.67 [0.4];  $p<0.01$ ) were significantly different to the mean reference values (\*).



**Fig 2b:** Quantitative electromyography (QEMG) size index was significantly (\*) higher in affected horses than compared to reference values in normal warmblood horses (0.67 [0.4];  $p<0.01$ )

sults and post mortem findings of the facet joints, a significant relation was found in the segment C5/6 on the right side ( $p=0.03$ ).

Relation between clinical signs and results of clinical, radiographic and pathological anatomic examinations is shown in table 4. Odds ratio could be calculated for “painful neck” and abnormal QEMG at C3/C4 left and C5/C6 right meaning that the likelihood to find an abnormal QEMG at C3/C4 left and C5/C6 right in case of a painful neck is higher than having a normal QEMG. Furthermore, “painful neck” was correlated to histological changes of the nerve roots at C2/C3 on the right and histological changes of the spinal cord at C4/C5 on the right side.



**Table 4:** Relation between clinical signs and results of clinical, radiographic and pathological anatomic examinations was tested by Chi-Square Fisher's exact test and logistic regression.

r=right, l=left, CI=confidence interval; OR=odds ratio; incoord. = incoordination; Histo = Histology; QEMG = quantitative electromyography

| Clinical sign | OR   | lower CI | upper CI | QEMG    | xray    | Histo nerve roots              | Histo spinal cord | Histo facet joint   | Fisher's exact test | Log. regression |
|---------------|------|----------|----------|---------|---------|--------------------------------|-------------------|---------------------|---------------------|-----------------|
| painful neck  | 54.5 | 2.3      | 5.7      | /       | /       | C2/3 r                         | /                 | /                   | ✓                   | ✓               |
| painful neck  | 54.6 | 2.2      | 5.8      | C3/C4 l | /       | /                              | /                 | /                   | ✓                   | ✓               |
| painful neck  | 18   | 1.2      | 260      | C5/C6 r | /       | /                              | /                 | /                   | ✓                   | ✓               |
| painful neck  | 11   | 1        | 114      | /       | /       | /                              | C4/C5 r           | /                   | ✓                   | ✓               |
| painful neck  | /    | /        | /        | /       | /       | C4/C5 l,<br>C6/C7 l<br>C3/C4 l |                   | C4/C5 r,<br>C6/C7 r | /                   | /               |
| Incoord.      | /    | /        | /        | /       | /       | /                              | C6/C7 r+l         | /                   | /                   | /               |
| sweating      | /    | /        | /        | /       | C4/C5 r | /                              | /                 | /                   | /                   | /               |
| stumbling     | /    | /        | /        | /       | C6/C7 l | /                              | /                 | /                   | /                   | /               |

## Discussion

To the best of our knowledge, this is the first study where results of clinical signs, QEMG, diagnostic imaging and post mortem examination are thoroughly compared to each other.

QEMG, as performed in our studies is focusing on signs of instability of muscle and nerve fibre membranes (pathological spontaneous activity), re-innervation (broad, large polyphasic MUPS) and motor neuron loss (doublet, triplets, poor interference pattern) rather than firing patterns and is used to detect signs of lower motor neuron disorders (LMND) and or neuropathies affecting the ventral horn of the grey matter of the spinal cord. Local muscle atrophy, weakness, reduced reflexes can be signs of a LMND and QEMG can be used to determine the location of a compressive neuropathy and myelopathy causing signs of LMND.<sup>14,16,18,27</sup>

Impairment affecting the spinal cord can result in bilateral neurophysiological changes. Because clinically and radiographically it can be challenging to define the side which is affected, bilateral QEMG should be performed in horses with suspicion of cervical spine impairment. This was done in our study in 32 of 36 horses.

Nerve root histology did not show significant relation to QEMG changes of the same segment. This finding was not expected because the nerve root is part of the LMN of which QEMG provides detailed information and should help localizing cervical segments where histological changes would be expected. Possibly this was because there was not enough time yet to develop histologically visible alterations or changes would only be

visible by electro-microscopy or only functional and no anatomic changes could have been present. Low statistical relation may unfortunately be due to small sample size and incomplete data per segment. If QEMG results were abnormal in a segment cranial to a spinal cord lesion this might be explained by the anatomy of the spinal nerve roots and the muscles they innervate. A reason for the relation of histological changes of the upper cervical spinal cord and QEMG changes of a lower cervical segmental nerve root might be that the electronic signal changes (higher amplitude, longer duration, more phases) at the site of cervical compressive neuropathy and myelopathy are recorded as a pathological potential further proximal at the QEMG electrode.<sup>28</sup>

Pain during neck palpation or neck movement was the clinical parameter that showed statistically significant relations with abnormal QEMG results in region C4/5 on the left and C5/6 on the right and a frequency high enough to calculate odds ratios. We can conclude that if a horse shows a painful neck, it has a high probability to have abnormal QEMG results in the mentioned regions, to have histological changes of the nerve roots in the region C3/4 on the right and C5/6 on the left and histological changes of the spinal cord in the region C4/5 on the right. If painful reactions on neck palpation and neck movement necessarily are dependent on the mentioned pattern of left and right side changes of facet joints, nerve roots and spinal cord, cannot be predicted by this study.

For this study, horses were only included if they that had a post mortem to find the pathognomonic correlate to the QEMG result. Neck pain was the second most reason for referral. One horse was treated and checked

with QEMG 4 weeks after local treatment of the cervical facet joints with corticosteroids. Clinical improvement was marginal and QEMG results did not change after this period of time. In this horse severe changes were found in the post mortem. To confirm the ability of QEMG to localize changes along the cervical spine in horses with and without neck pain and the reversibility and/or stability of QEMG changes after local anti-inflammatory treatment in horses a prospective, randomized study with a control group should be performed.

In this population, no relation was found between bony changes on radiographs and post mortem changes of the spinal cord or the cervical nerve roots which weakens the diagnostic power of this modality in determining the location of cervical compressive neuropathy and myelopathy and is in agreement with the formerly mentioned literature.<sup>8</sup> Appropriate large animal CT could help to localize cervical compressive neuropathy and myelopathy more precisely.

Despite limitations of this study (clinical cases, low case number, multicentric with many people involved), we have shown by calculating relations of QEMG data with post mortem results that in this study QEMG is a technique to localize relevant changes. Therefore, QEMG should be used at a larger scale in most equine clinics as an additional clinical diagnostic tool under practical conditions for horses suffering from cervical compressive neuropathy and myelopathy

## Abbreviations

B: Berne  
 QEMG: quantitative electromyography  
 PSA: pathological spontaneous activity  
 UMN: upper motor neuron  
 LMN: lower motor neuron  
 UMND: upper motor neuron disease  
 LMND: lower motor neuron disease  
 UU: University of Utrecht  
 CVM/CVS: Cervical vertebral myelopathy/stenosis

Nanocarrier in der Tiermedizin – eine Pilotstudie zur Behandlung der feline Hyperthyreose mit auf Nanocarriern basierender Thiamazolsalbe

D. Böhm et al.

## Acknowledgements

We would like to thank our clients for letting us perform necropsy on their horses, Dr. med. vet. Fabio Aloisio for his support considering the necropsy and technicians for post mortem examination.

## Conflicts of interest

The authors declare no potential conflicts.

## Manufacturers' Address

CareFusion Neurocare, Madison, Wisconsin, USA.  
 Viasys Health Care, Wisconsin, USA.

## Analyse quantitative du potentiel d'action de l'unité motrice des muscles para spinaux, imagerie diagnostique et résultats d'autopsie chez 36 chevaux soupçonné de déficience cervicale

**Objectifs:** Déterminer la relation entre l'électromyographie quantitative (QEMG) du muscle serratus ventral cervical, les résultats radiographiques et les examens macroscopiques et histopathologiques post mortem afin de calculer la capacité de la QEMG à localiser la région de compression neurogène dans l'encolure des chevaux.  
**Méthodes:** Dans cette étude clinique, non randomisée, partiellement aveugle (histologie et QEMG), 36 chevaux de sang soupçonnés d'affection du rachis cervical ont été examinés par QEMG sur différents segments du muscle serratus ventral. Les résultats ont été comparés aux données de référence. L'imagerie diagnostique a été réalisée dans 28 cas. Tous les chevaux ont été euthanasiés en raison de mauvais pronostics cliniques et/ou de signes neurologiques cliniques récurrents malgré le trai-

## Analisi quantitativa del potenziale d'azione dell'unità motoria dei muscoli paraspinali, diagnostica per immagini e risultati della necropsia in 36 cavali sospettati di disturbo cervicale.

**Obiettivo:** Determinare la relazione tra una elettromiografia quantitativa (QEMG) del muscolo serrato cervicale ventrale, i risultati radiografici e post mortem e l'esame istopatologico, per calcolare l'abilità del QEMG di localizzare la regione della neuropatia cervicale compressiva e della mielopatia nel collo dei cavalli.  
**Metodi:** In questo studio clinico, non randomizzato e parzialmente in ceco (istologico e QEMG) sono stati esaminati in 36 cavalli a sangue caldo, sospettati di essere affetti da una malattia delle vertebre cervicali, via QEMG i differenti segmenti del muscolo serrato ventrale. I risultati sono stati comparati ai dati di riferimento. La diagnostica per immagini è stata effettuata in 28 casi. Tutti i cavalli sono stati eutanasiati a causa della sfavorevole prognosi clinica e/o dei ricorrenti segni

Quantitative motor unit action potential analysis of paraspinal muscles, diagnostic imaging and necropsy findings in 36 horses suspected of cervical impairment

C. Graubner et al.

tement et ont subi une autopsie en mettant l'accent sur le tissu nerveux cervical et les vertèbres. Les résultats de l'imagerie clinique et diagnostique, les résultats de la QEMG et les résultats post mortem ont été comparés les uns aux autres.

**Résultats:** Les valeurs moyennes globales de durée (9,54 ms), de polyphasie, de nombre de phases (3,6) et d'indice de taille (0,67) chez les chevaux présentant des lésions cervicales étaient significativement ( $P < 0,05$ ) supérieures aux données de référence. L'examen clinique était en corrélation significative avec plusieurs changements dans la QEMG et en histologie mais pas avec des anomalies radiologiques. Une mobilité réduite du cou semble être un paramètre cliniquement pertinent pour suspecter une pathologie du rachis cervical. Aucune corrélation significative n'a été trouvée entre la radiologie et les résultats post mortem. Pour la QEMG, en deux (C5/6 côté droit et C6/7 côté gauche) sur douze segments cervicaux (C1-2, C2-3, C3-4, C4-5, C5-6, C6-7 des deux côtés), des relations statistiquement significatives avec des modifications histopathologiques ont pu être trouvées.

**Conclusions et pertinence pratique:** Dans cette étude, au niveau de C5-6-7, la QEMG 49 pourrait prédire le site de la lésion dans le système nerveux alors que l'imagerie radiologique n'a pas réussi à identifier le site des lésions. L'examen clinique était en corrélation significative avec plusieurs changements de la QEMG et de l'histologie mais pas avec des anomalies radiologiques. La QEMG peut être ajouté au protocole d'examen des chevaux suspectés cliniquement de souffrir d'une compression neurogène dans la région cervicale.

**Mots-clés:** histologie, cheval, encolure, QEMG

clinici neurologici ricorrenti nonostante il trattamento e sono stati sottoposti a necropsia in particolare nel tessuto nervoso cervicale e nelle vertebre. I risultati clinici e della diagnostica per immagini, quelli del QEMG e quelli post mortem sono stati comparati tra loro.

**Risultati:** I valori medi generali di durata (9.54 ms), polifasia, il numero di fasi (3.6) e l'indice della taglia (0.67) nei cavalli con lesioni cervicali erano significativamente superiori ( $P < 0.05$ ) ai dati di riferimento. L'esame clinico era significativamente correlato ai diversi QEMG e alle modifiche istologiche ma non con delle anomalie radiologiche. Una mobilità ridotta del collo sembra sia un parametro clinico rilevante per sospettare una patologia delle vertebre cervicali. Nessuna correlazione significativa è stata individuata tra i risultati radiologici e post mortem. Secondo QEMG, in due (C5/6 parte destra e C6/7 parte sinistra) dei 12 segmenti cervicali (C1-2, C2-3, C3-4, C4-5, C5-6, C6-7 entrambi i lati) è stata rilevata una significativa relazione statistica con le modifiche istopatologiche.

**Conclusione e applicazione:** In questo studio si è potuto anticipare con QEMG a livello della C5-6-7 la sede di una lesione nel sistema nervoso cosa impossibile con la diagnostica radiologica. L'esame clinico era significativamente correlato alle modifiche QEMG e istologiche ma non con anomalie radiologiche. La QEMG può essere inclusa al protocollo di esame dei cavalli sospettati clinicamente di soffrire di una compressione neurogena della regione cervicale.

**Parole chiave:** cavallo, elettromiografia quantitativa, neuropatia cervicale compressiva e mielopatia

## Literature

- Moore BR, Holbrook TC, Stefanacci JD, et al. Contrast-enhanced computed tomography and myelography in six horses with cervical stenotic myelopathy. *Equine Vet J* 1992;24:197-202. doi: 110.1111/j.2042-3306.1992.tb02814.x.
- Prange T, Shrauner BD, Blikslager AT. Epiduroscopy of the lumbosacral vertebral canal in the horse: Technique and endoscopic anatomy. *Equine Vet J* 2016;48:125-129. doi: 110.1111/evj.12470. Epub 12015 Aug 12421.
- Yovich JV, Gould DH, LeCouteur RA. Chronic cervical compressive myelopathy in horses: patterns of astrocytosis in the spinal cord. *Aust Vet J* 1991;68:334-337. doi: 310.1111/j.1751-0813.1991.tb03092.x.
- Yovich JV, leCouteur RA, Gould DH. Chronic cervical compressive myelopathy in horses: clinical correlations with spinal cord alterations. *Aust Vet J* 1991;68:326-334. doi: 310.1111/j.1751-0813.1991.tb03091.x.
- Mayhew IG, deLahunta A, Whitlock RH, et al. Spinal cord disease in the horse. *Cornell Vet* 1978;68:1-207.
- Powers BE, Stashak TS, Nixon AJ, et al. Pathology of the vertebral column of horses with cervical static stenosis. *Vet Pathol* 1986;23:392-399. doi: 310.1177/030098588602300408.
- Janes JG, Garrett KS, McQuerry KJ, et al. Cervical Vertebral Lesions in Equine Stenotic Myelopathy. *Vet Pathol* 2015;52:919-927. doi: 910.1177/0300985815593127. Epub 0300985815592015 Jul 0300985815593113.
- Schmidburg I, Pagger H, Zsoldos RR, et al. Movement associated reduction of spatial capacity of the equine cervical vertebral canal. *Vet J* 2012;192:525-528. doi: 510.1016/j.tvjl.2011.1008.1011. Epub 2011 Sep 1014.
- Hughes KJ, Laidlaw EH, Reed SM, et al. Repeatability and intra- and inter-observer agreement of cervical vertebral sagittal diameter ratios in horses with neurological disease. *J Vet Intern Med* 2014;28:1860-1870. doi: 1810.1111/jvim.12431.



- <sup>10</sup> Levine JM, Adam E, MacKay RJ, et al. Confirmed and presumptive cervical vertebral compressive myelopathy in older horses: a retrospective study (1992-2004). *J Vet Intern Med* 2007;21:812-819. doi: 810.1892/0891-6640(2007)1821[1812:capcvc]1892.1890.co;1892.
- <sup>11</sup> Furst A. Cervical vertebral arthrosis in horses: An overview. *PRAKTISCHE TIERARZT* 2006;87:956.
- <sup>12</sup> Rüedi M, Hagen R, Lüchinger U, et al. Subluxation von C2 und C3 und Fraktur von C2 nach einem schweren Schädelhirntrauma bei zwei Warmblutpferden. *Pferdeheilkunde* 2011;27:522-527.
- <sup>13</sup> Wijnberg ID, Franssen H, van der Kolk JH. Influence of age of horse on results of quantitative electromyographic needle examination of skeletal muscles in Dutch Warmblood horses. *Am J Vet Res* 2003;64:70-75. doi: 10.2460/ajvr.2003.2464.2470.
- <sup>14</sup> Wijnberg I, Graubner C, Back W, et al. Quantitative motor unit action potential analysis in two paraspinal muscles in sound adult Warmblood horses. 48th BEVA Congress 2009.
- <sup>15</sup> Sonoo M, Stalberg E. The ability of MUP parameters to discriminate between normal and neurogenic MUPs in concentric EMG: analysis of the MUP "thickness" and the proposal of "size index". *Electroencephalogr Clin Neurophysiol* 1993;89:291-303. doi: 210.1016/0168-5597(1093)90068-z.
- <sup>16</sup> Wijnberg ID, Franssen H. The potential and limitations of quantitative electromyography in equine medicine. *Vet J* 2016;209:23-31. doi: 10.1016/j.tvjl.2015.1007.1024. Epub 2015 Sep 1025.
- <sup>17</sup> Wijnberg ID, Graubner C, Auriemma E, et al. Quantitative motor unit action potential analysis in 2 paraspinal neck muscles in adult Royal Dutch Sport horses. *J Vet Intern Med* 2011;25:592-597. doi: 510.1111/j.1939-1676.2011.0724.x. Epub 2011 Apr 1112.
- <sup>18</sup> Wijnberg I, Graubner C, Auriemma E, et al. Quantitative motor unit action potential analysis in 2 paraspinal neck muscles in adult Royal Dutch Sport horses. *Journal of veterinary internal medicine* 2011;25:592-597.
- <sup>19</sup> Wijnberg ID. Diagnostic possibilities of EMG needle examination in the horse. Utrecht: Utrecht University, 2002.
- <sup>20</sup> Wijnberg ID, Franssen H, van der Kolk JH. Influence of age of horse on results of quantitative electromyographic needle examination of skeletal muscles in Dutch Warmblood horses. *Am J Vet Res* 2003;64:70-75.
- <sup>21</sup> Levine JM, Scrivani PV, Divers TJ, et al. Multicenter case-control study of signalment, diagnostic features, and outcome associated with cervical vertebral malformation-malarticulation in horses. *J Am Vet Med Assoc* 2010;237:812-822. doi: 810.2460/javma.2237.2467.2812.
- <sup>22</sup> Fuglsang-Frederiksen A. The role of different EMG methods in evaluating myopathy. *Clin Neurophysiol* 2006;117:1173-1189. doi: 1110.1016/j.clinph.2005.1112.1018. Epub 2006 Mar 1173.
- <sup>23</sup> Fuglsang-Frederiksen A, Pugdahl K. Current status on electrodiagnostic standards and guidelines in neuromuscular disorders. *Clin Neurophysiol* 2011;122:440-455. doi: 410.1016/j.clinph.2010.1006.1025. Epub 2010 Jul 1031.
- <sup>24</sup> Wijnberg ID, Franssen H, Jansen GH, et al. Quantitative electromyographic examination in myogenic disorders of 6 horses. *J Vet Intern Med* 2003;17:185-193. doi: 110.1111/j.1939-1676.2003.tb02432.x.
- <sup>25</sup> Stalberg E, Kouyoumdjian J, Sanders D. Reference values in concentric needle electrode studies. *Clin Neurophysiol* 2013;124:1255-1256. doi: 1210.1016/j.clinph.2012.1209.1028. Epub 2012 Oct 1230.
- <sup>26</sup> Daube JR, Rubin DI. Needle electromyography. *Muscle & Nerve* 2009;39:244-270.
- <sup>27</sup> Wijnberg ID, Back W, de Jong M, et al. The role of electromyography in clinical diagnosis of neuromuscular locomotor problems in the horse. *Equine Vet J* 2004;36:718-722. doi: 710.2746/0425164044848019.
- <sup>28</sup> Kimura. *Electrodiagnosis in diseases of nerve and muscle Principles and Practice*. 3 ed: OXFORD, 2001.
- Quantitative motor unit action potential analysis of paraspinal muscles, diagnostic imaging and necropsy findings in 36 horses suspected of cervical impairment
- C. Graubner et al.

## Corresponding author

Claudia Graubner  
Länggassstrasse 124  
CH-3012 Bern  
+41 31 631 2243  
E-Mail: claudia.graubner@vetsuisse.unibe.ch