Journal Pre-proof



Capillary-venule malformation a microfistulous variant of arteriovenous malformation

Nicolas Vuillemin, Sarah Bernhard, Axel Haine, Marc Schindewolf, Dario Häberli, Ulrike Hügel, Dominik Obrist, Iris Baumgartner

PII: S2213-333X(20)30317-6

DOI: https://doi.org/10.1016/j.jvsv.2020.05.012

Reference: JVSV 1025

To appear in: *Journal of Vascular Surgery: Venous and Lymphatic Disorders*

Received Date: 13 March 2020

Accepted Date: 12 May 2020

Please cite this article as: N. Vuillemin, S. Bernhard, A. Haine, M. Schindewolf, D. Häberli, U. Hügel, D. Obrist, I. Baumgartner, Capillary-venule malformation a microfistulous variant of arteriovenous malformation, *Journal of Vascular Surgery: Venous and Lymphatic Disorders* (2020), doi: https://doi.org/10.1016/j.jvsv.2020.05.012.

This is a PDF file of an article that has undergone enhancements after acceptance, such as the addition of a cover page and metadata, and formatting for readability, but it is not yet the definitive version of record. This version will undergo additional copyediting, typesetting and review before it is published in its final form, but we are providing this version to give early visibility of the article. Please note that, during the production process, errors may be discovered which could affect the content, and all legal disclaimers that apply to the journal pertain.

Copyright © 2020 Published by Elsevier Inc. on behalf of the Society for Vascular Surgery.

source: https://doi.org/10.7892/boris.144506 | downloaded: 26.4.2024

Journal Pre-proof

Capillary-venule malformation is a microfistulous variant of arteriovenous malformation

Nicolas Vuillemin[1], Sarah Bernhard[1], Axel Haine[1], Marc Schindewolf[1], Dario Häberli[1], Ulrike Hügel[1], Dominik Obrist[2], Iris Baumgartner[1]

[1] Division of Angiology, Swiss Cardiovascular Center, Inselspital, Bern University Hospital, University of Bern, Bern, Switzerland

[2] ARTORG Center for Biomedical Engineering Research, University of Bern, Bern, Switzerland

Corresponding author:

Iris Baumgartner, MD

Division for Angiology, Swiss Cardiovascular Centre

University Hospital Bern

3010 Bern, Switzerland

Phone: +41 31 632 3034

Fax: +41 31 632 0428

Email: iris.baumgartner@insel.ch

Article Highlights

Type of Research: Retrospective analysis of prospectively collected registry data,

Key Findings: 15 patients with a hyperdynamic capillary-venule malformation have been retrospectively analyzed. Anomalous dilated superficial veins with uncommon appearance in

Journal Pre-proof

Journal Pre-proof

size and location with regard to classical primary varicose veins and hypertrophy of the affected tissue were found in 80% of the patients.

Take Home Message: To prevent ineffective and unnecessary therapy and complications, clinical suspicion is needed to recognize a hyperdymanic capillary-venule malformation

Table of Contents Summary

15 patients with a hyperdynamic capillary-venule malformation have been analyzed with the focus on demographics, clinical presentation and localization. Anomalous dilated superficial veins with uncommon appearance in size and location with regard to classical primary varicose veins and hypertrophy of the affected tissue were found in 80% of the patients.

Abstract

Objective: To describe typical clinical presentation of patients with microfistular, capillary-venule (CV) malformation as a variant form of arterio-venous malformations (AVM).

Methods: A retrospective clinical analysis of 15 patients with CV-AVM confirmed by a computational flow model enrolled in a prospective database of patients with congenital vascular malformation between January 2008 and May 2018.

Results: Mean age of patients at first time of presentation was 30 years with balanced gender ratio. Presentation was dominated by soft tissue hypertrophy (n=12, 80.0%) and atypical varicose veins (n=11, 73.3%). Anatomical location of enlarged varicose veins gave no uniform pattern and did not correspond to the typical picture of primary varicose vein disease. Most often symptomatic CV-AVM was found at the lower extremities in this series of unselected patients.

Journal Pre-proof

Journal Pre-proof

The most frequent compartment affected was the subcutis (n=14, 93.3%), involvement of muscle was recorded in a third and cutis in a fourth of patients.

Conclusions: A high grade of clinical suspicion is needed to recognize CV-AVM and to prevent inadequate therapy due to failed diagnosis.

Keywords

vascular malformation; varicose veins; venous insufficiency; chronic venous disease; microcirculation

Conflict of interest

The authors have no competing interests

Introduction

Congenital vascular malformations (CVM) are inborne anomalies of the vascular system [1]. The prevalence of CVM is approximately 1.5% in the general population [2]. Peripheral arterio-venous malformations (AVM) are the least common type of CVM representing less than one fourth of all CVM [3]. A lack of understanding for hemodynamic characteristics of various AVM types has led to incorrect therapeutic approaches with high complication rates described in the literature [4, 5]. Although various classification systems were proposed[6, 7], there are microfistular, high-flow malformations not fitting into the established schemes [8].

Journal Pre-proof

Journal Pre-proof

Since 2008 the Division of Angiology at the University Hospital Bern has treated 15 patients with microfistular AVMs [8], which do not fully match to the classification proposed by Yakes[6, 9, 10] or the classification of CVM as defined by the International Society of Vascular Anomalies[11]. Depending on the size, these atypical AVM usually have monophasic high flow in feeding arteries and continuous flow in draining veins close to the malformation. Main ultrasound indicator is high vascular density and spontaneous high flow directly in the tissue affected by the malformation similar to findings seen in hemangiomas[12]. Digital subtraction angiography (DSA) shows no typical early venous shunting. Venous drainage is considerably delayed and dispersed as compared to other types of AVM [14], and even can be missed with insufficient angiographic technique as it becomes obvious only with long DSA sequences after disappearance of arterial contrast flow.

Frey et al were the first to describe the hypothesis that the structural pathology of this subgroup of AVM probably is at the level of capillary venules after assessing multiple types of AVM with an analyzing program developed for this purpose [13]. The model was robust to simulate different types of AVM and to differentiate classical types in patients [13, 14]. It was shown that CV-AVM show a particularly slow and dispersive venous shunting behavior that is different from other high flow AVM and that the anatomical change mathematically should be on the venule side following the capillary bed. Computational flow simulation suggests that the fistulous paths is anatomically assigned to the intermediate venous end of the capillary unit (capillary-venule) and draining venules.

When AVM affect parts of the microcirculation, their angioarchitecture cannot be resolved with contrast agent-based clinical imaging techniques. The specifically designed computational biomedical engineering model described by Frey et all was aimed at identifying microvascular

Journal Pre-proof

Journal Pre-proof

malformation morphologies based on macroscopic contrast transport patterns. The model consists of a small network of capillary vessels with a feeding arteriole and draining venule and a set of prototype malformation morphologies. Flow rates and pressures are computed with a lumped parameter description of the network, while contrast propagation is determined by solving the 1D advection-diffusion equation. Among all considered pathological networks, two lesion types, which correlate with the two most distinctive arteriovenous transport patterns in patients, one being fast and non-dispersive and a second type exhibiting slow and dispersive transport, were identified. The model enables the identification of sub-resolution lesions with current clinical imaging modalities and can be extended to explore further unknown microvascular AVM morphologies.

Aim of this analysis is to describe typical clinical findings associated with this variant type of AVM with hyperdynamic, capillary-venule shunting.

Method

This is a retrospective analysis based on a prospective database consecutively enrolling patients with CVM at the University Hospital Bern since 2008. The database was locked for this analysis on May 31st 2018. There were 398 patients enrolled at this time point. Those 398 patients where retrospectively reviewed to identify patients with CV-AVM. Criteria to define a CV-AVM were: 1. hyperdynamic AVM characteristics using duplex ultrasound and/or magnetic resonance imaging, 2. delayed venous shunting defined as an occurrence after arterial contrast transit using DSA (Figures 1;3;4) [13, 14].

Journal Pre-proof

Journal Pre-proof

Patient selection was performed in a 2-step process. First, the database was filtered by the search term AVM. Second, DSA of all patients with the filter term AVM were evaluated by two experienced vascular specialists to select those patients with angiographic criteria as defined.

All patients signed a general informed consent (IC) for anonymized data analysis implemented at the University Hospital Bern since 2013. Patients enrolled before 2013 were contacted and without any exception signed the IC for anonymized data analysis.

Patients with a questionable diagnosis of CV-AVM or CV-AVM in cerebral and spinal region, patients with a documentation of any denial to further use of patient`s data and patients under 18 years of age at the point of analysis were excluded.

In addition to demographic and disease related information given in the database, information was cross-checked using hospital charts of patients available.

A publication consent has been signed by all patients needed for the publication of their Figures.

The study was approved by the Ethics Committee of the Canton of Bern (local ethics board number ID 2016–01503)

Data collection

Demographic data collection included gender and age at first diagnosis of CVM. D-dimer levels were routinely measured in venous blood samples. D-dimers were determined using an immunoturbidimetrically method with pathologic result defined as D-dimer > 500µg/l [16, 17] Pain was recorded using a numeric rating score (NRS) [18]. Pain was scored by the patient between 1 and 10 with 1 defined as no pain and 10 as the worst pain the patient could imagine. Signs related to CVM systematically collected were soft tissue hypertrophy, localized increase in skin temperature, edema distal to the malformation defined as a palpable swelling produced by

Journal Pre-proof

Journal Pre-proof

increase of the interstitial volume[19]. Soft tissue hypertrophy was described as local overgrowth in an area infiltrated by the CVM compared to the surrounding tissue not infiltrated by visual estimation. The skin temperature was measured using a thermographic camera, if the temperature in the region of the malformation was +0.4 C° compared to the surrounding skin, it was defined as local increase in skin temperature. The anatomical location and the size of anomalous enlarged venous vessels were systematically recorded and divided in telangiectasias, reticular veins and varicose veins. Telangiectasias were defined as visible enlargement of small sized vessels less than 1mm. Reticular veins were defined as 2-3 mm in size, varicose veins were defined as dilated, elongated, tortuous veins with a diameter of 3 mm or greater.

All patients were classified according to the Schobinger classification [20] a staging system to define hyperdynamic circulatory signs and symptoms of CVM. Stage I is defined as quiescence of disease, stage II as local expansion, stage III as destruction of surrounding tissue due to CVM and stage IV as decompensation as cardiac failure and symptomatic local steal syndrome, respectively.

On first presentation the anatomical location and hemodynamic characterization of the lesion was recorded. CVM were distinguished into high-flow or low-flow using duplex sonography. Localization and infiltration were defined by magnetic resonance imaging.

Anatomically upper extremity, lower extremity, trunk and neck/face were distinguished. Tissue compartments infiltrated were separated into cutis, subcutis, muscle, bone and organs.

Statistical methods

The research data were collected in ClinicWinData (E&L medical systems, Germany) and transferred to excel (Microsoft, Redmond, Washington, U.S.). The file has been stored on a

Journal Pre-proof

Journal Pre-proof

SharePoint 2013 (Microsoft, Redmond, Washington, U.S.) platform that was centrally set up by the Clinical Trial Unit Bern. It fulfills all requirements of the Human Research Act (HRA). Continuous variables are presented as mean ± standard deviation (SD) and minimun to maximum values (min-max). Categorical variables are presented as numbers and percent.

Results

Filtering the database for the search term AVM, there were 67 patients (67/398, 16.8%) identified in the Bernese CVM cohort. In all patients AVM was verified by DSA. DSAs were analyzed by two experienced vascular specialists and 15 patients (15/67; 22.4%) were identified to have CV-AVM. Demographic data among these 15 patients are shown in Table I. Mean age at first time of presentation was 30 years.

Clinical presentation

The NRS pain score was in the lower third and gave a mean of 2.7 ± 0.9 (1 to 4). On first presentation 12 patients (80.0%) were diagnosed with soft tissue hypertrophy, 11 (73.3%) had objectively verified local increase in skin temperature in the region of the CV-AVM, and edema formation was present in 4 (26.6%), respectively.

Enlarged superficial veins were recorded in 11 (73.3%) patients with the proportion of size shown in Table II. Starting from a variable location of the CV-AVM with increased venous drainage instead of venous reflux as mechanism of origin and depending on the drainage area, the clinical picture gave no uniform pattern and ranged from enlarged trunk or lateral branch varices to limited localized reticular veins (Figure 2; 5). Duplex sonography showed high vascular density and spontaneous flow directly in the tissue affected by the malformation

Journal Pre-proof

accompanied by a wide range of enlarged superficial veins. Out of all 15 patients one patient had a Schobinger classification higher than stage 2 with soft tissue hypertrophy, skin destruction, ulcer and pain in the region of the CV-AVM (Figure 5).

Localization of capillary-venule malformation

Anatomical localization of CV-AVM is given in Table III. Most frequently symptomatic CV-AVM was found at the lower extremity (80.0%) in this series of unselected patients. There were 2 patients (13.3%) with CV-AVM of the upper extremity and one patient (6.6%) with a CV-AVM of the face. None of the patients had a malformation recorded in the region of the body trunk. One patient presented with multifocal CV-AVM (Figure 5). The most frequent compartment affected was the subcutis (93.3%), involvement of muscle was recorded in a third and the cutis in a fourth of patients. In one patient additional bone involvement was seen. Organs were not recorded to be affected in any of the cases. In 26.6% of patients two or more tissue compartments were affected by the same CV-AVM.

Discussion

This is a detailed clinical description of patients with microfistular AVM, defined as hyperdynamic capillary-venule malformation (CV-AVM). Most prominent findings were anomalously dilated superficial veins with uncommon appearance in size and location with regard to classical varicose veins and hypertrophy of the affected tissue.

D-dimer levels were moderately elevated and of little use for the diagnosis of CV-AVM. Although symptoms and signs of chronic venous disease dominated clinically, CV-AVM showed no relevant accompanying localized intravascular coagulopathy as is typical for venous

Journal Pre-proof

malformation. The finding of low and normal D-dimer levels is well in accordance that CV-AVM represent a hyperdynamic CVM, although clinically the signs and symptoms of venous disease were dominating [16, 17, 21]. An increased microfistular flow strains the venous drainage system that becomes clinically enlarged, but the underlying pathophysiology explains that classical varicose vein treatment, leaving the CV-AVM unaffected, will result in high recurrence rates.

The majority of subcutaneously located CV-AVM were manifest as a warm, enlarged tissue mass. The mass effect can be explained by an enlargement of anomalous vessels as well as an associated soft tissue hypertrophy and fibrosis[22, 23], a finding well described in AVM [24]. The local increase in skin temperature is typically to high flow malformations within the cutis and subcutis due to shunts skipping the capillary autoregulation and high flow dynamics.

As this analysis does not represent a cross-sectional design, but describes unselected patients seeking medical attention for symptomatic disease, findings cannot be generalized for all patients with CV-AVM. In our series findings of anomalous enlarged veins and increased skin temperature with tissue hypertrophy were the reason for most of the patients to consult a physician. Hyperdynamic flow characteristics in CV-AVM are less obvious as compared to classical high-flow AVM and therefore a high grade of clinical suspicion is needed. Careful ultrasound assessment of enlarged trunk or lateral branch varices as well as local reticular vein collections of unusual appearance or localization has to be performed to detect increased venous drainage and high vascular density with spontaneous flow directly in the tissue affected by the malformation to differentiate CV-AVM from chronic venous insufficiency.

Muliken et al published a subgroup of patients with regional capillary malformation of the lower extremity in association with phlebectasia. This capillary venous malformation should not be

Journal Pre-proof

Journal Pre-proof

confused with the variant described in this publication. Although both forms have capillary and venous components, shunt-related high flow is sole characteristic of the latter [15].

Undirected treatment of superficial venous disease is accompanied with a high rate of recurrences and even bleeding complications. It is important not to overlook the hyperdynamic perfusion in patients with unusual appearance and location of superficial venous disease to prevent ineffective procedures. To treat those enlarged superficial veins based on a CV-AVM the same way as chronic venous insufficiency in primary varicose vein disease [25] would be a predictable error due to the fact that the venous hypertension does not occur due to insufficient venous valves . The hypertension in veins relates to high pressure due to shunts in the microcirculation, leading to shear stress followed by the symptoms and signs well known for chronic venous insufficiency [26] but in unusual anatomical locations.

Therapeutically the CV-AVM has to be removed first, before stripping or sclerotherapy of varicose veins can be planned [7, 9]. Due to the infiltrating character of CV-AVM complete surgical extraction is often not possible. It was not a main subject of this publication to describe the treatment of CV-AVM. In brief, all patients were treated with percutaneous injections of 50% to 96% ethanol to hit the nidus [3, 4]. Treatment of CV-AVM is particularly laborious due to its diffuse character and often innumerable venules attributed to the nidus

Conclusion

Patients with the capillary-venule variant of AVM seem to become clinically apparent with enlarged superficial veins of atypical appearance and tissue hypertrophy with increased overlying skin temperature. Referral was most often for management of chronic venous insufficiency after treatment failure, soft tissue hypertrophy and local pain. To prevent

Journal Pre-proof

Journal Pre-proof

ineffective and unnecessary therapy and complications clinical suspicion is needed to recognize the diagnosis. Description of an individualized treatment plan exceeds the focus of this study. To establish definite guidelines for diagnosis and treatment would exceed the focus of this work.

References

1. Gupta A, Kozakewich H. Histopathology of Vascular Anomalies. *Clinics in Plastic Surgery* 2011;38:31-44.

2. Eifert S, Villavicencio J, Kao T, Taute B, Rich N. Prevalence of deep venous anomalies in congenital vascular malformations of venous predominance. Journal of Vascular Surgery 2000;31:462-471.

3. Lee B, Baumgartner I, Berlien H, Bianchini G, Do Y, Ivancev K, et al. Consensus Document of the International Union of Angiology. Current concept on the management of arterio-venous management. International Angiology 2013;32:9-36.

4. Yakes WF, Rossi P, Odink H. How I do it. Arteriovenous malformation management. CardioVascular and Interventional Radiology 1996;19:65-71.

5. Lee S, Do Y, Kim C, Park K, Kim Y, Cho Y. Efficacy and Safety of Transvenous Embolization of Type II Renal Arteriovenous Malformations with Coils. Journal of Vascular and Interventional Radiology 2019;30:807-812.

6. Yakes W, Yakes A. Classification of Arteriovenous Malformation and Therapeutic Implication. In: Mattassi R, Loose DA and Vaghi M (eds) *Hemangiomas and Vascular Malformations: An Atlas of Diagnosis and Treatment*. Milano: Springer Milan, 2015, pp.263-276.

Journal Pre-proof

Journal Pre-proof

7. Park K, Do Y, Kim D, Park H, Shin S, Cho S, et al. Endovascular treatment results and risk factors for complications of body and extremity arteriovenous malformations. Journal of Vascular Surgery 2019;69:1207-1218.

8. Stein M, Guilfoyle R, Courtemanche D, Moss W, Bucevska M, Arneja J. The "Little AVM": A New Entity in High-flow versus Low-flow Vascular Malformations. Plastic and Reconstructive Surgery – Global Open 2014; 2:e187.

9. Yakes W, Baumgartner I. Interventional treatment of arterio-venous malformations. *Gefässchirurgie* 2014;19:325-330.

10. Arneja J, Gosain A. An approach to the management of common vascular malformations of the trunk. Journal of Craniofacial Surgery 2006;17:761-766.

11. ISSVA. Classification for vascular anomalies. Approved at the 20th ISSVA Workshop, Melbourne, April 2014, last revision May 2018.

12. Laroche J, Blaise S, Becker F, Laaeng Massoni C, Nou-Howaldt M, Pichot o, et al. Quality standards for ultrasonographic assessment of peripheral vascular malformations and vascular tumors. Report of the french society for vascular medicine. Journal de Médecine Vasculaire 2018; 43:36-51.

13. Frey S, Haine A, Kammer R, von Tengg-Kobligk H, Obrist D, Baumgartner I. Hemodynamic Characterization of Peripheral Arterio-venous Malformations. Annals of Biomedical Engineering 2017; 45:1449-1461.

14. Frey S, Cantieni T, Vuillemin N, Haine A, Kammer R, von Tengg-Kobligk H, et al. Angioarchitecture and hemodynamics of microvascular arterio-venous malformations. *PLOS ONE* 2018;13:e0203368.

Journal Pre-proof

Journal Pre-proof

15. Uihlein L, Liang M, Fishman S, Alomari A, Mulliken J. Capillary-Venous Malformation in the Lower Limb. Pediatric Dermatology 2013; 30: 541-548

16. Dompmartin A, Ballieux F, Thibon P, Lequerrec A, Hermans C, Clapuyt P, et al. Elevated D-dimer level in the differential diagnosis of venous malformations. Archives of Dermatology 2009; 145:1239-1244.

17. Mazoyer E, Enjolras O, Bisdorff A, Perdu J, Wassef M, Drouet L. Coagulation disorders in patients with venous malformation of the limbs and trunk: a case series of 118 patients. Archives of Dermatology 2008; 144:861-867.

18. Hawker G, Mian S, Kendzerska T, French M. Measures of adult pain: Visual Analog Scale for Pain (VAS Pain), Numeric Rating Scale for Pain (NRS Pain), McGill Pain Questionnaire (MPQ), Short-Form McGill Pain Questionnaire (SF-MPQ), Chronic Pain Grade Scale (CPGS), Short Form-36 Bodily Pain Scale (SF-36 BPS), and Measure of Intermittent and Constant Osteoarthritis Pain (ICOAP). Arthritis Care & Research 2011; 63:240-252.

19. Reed R, Rubin K. Transcapillary exchange: role and importance of the interstitial fluid pressure and the extracellular matrix. Cardiovascular Research 2010; 87:211-217.

20. Schobinger R. Diagnostic and therapeutic possibilities in peripheral angiodysplasias. Helvetica chirurgica acta 1971;38:213-220.

21. Dompmartin A, Acher A, Thibon P, Tourbach S, Hermans C, Deneys V, et al. Association of localized intravascular coagulopathy with venous malformations. Archives of Dermatology 2008;144:873-877.

22. Parsi K, Partsch H, Rabe E, Ramelet A. Reticulate eruptions. Part 1: Vascular networks and physiology. Australasian Journal of Dermatology 2011;52:159-166.

Journal Pre-proof

Journal Pre-proof

23. Parsi K, Partsch H, Rabe E, Ramelet A. Reticulate eruptions: Part 2. Historical perspectives, morphology, terminology and classification. Australasian Journal of Dermatology 2011;52:237-244.

24. Parsi K. Dermatological Manifestations of Vascular Malformations. In: Mattassi R, Loose DA, Vaghi M, editors. *Hemangiomas and Vascular Malformations: An Atlas of Diagnosis and Treatment*.Second Edition Milan. Springer Milan, 2015, pp.199-205.

25. Gloviczki P, Comerota A, Dalsing M, Eklof B, Gillespie D, Golviczki M, et al. The care of patients with varicose veins and associated chronic venous diseases: Clinical practice guidelines of the Society for Vascular Surgery and the American Venous Forum. Journal of Vascular Surgery 2011;53:2-48.

26. Bergan J, Schmid-Schönbein G, Smith P, Coleridge Nicolaides A, Boisseau M, Eklof B. Chronic Venous Disease. *New England Jurnal of Medicine* 2006;355:488-498.

Journal Pre-proof

Journal Pre-proof

Table I

Characteristics	
Female, N (%)	7 (46.6)
Age, mean±SD (min-max), years	29.7±23.0 (1.0-81.0)
D-Dimer, mean±SD; (min-max), µg/l	677.8±647.1 (81.0-2071.0)

Legend: Demographic data of patients with capillary-venulous malformation

Journal Pre-proof

Journal Pre-proof

Table II

	N (%)
Total	11 (73.3)
Telangiectasias	6 (40.0)
Reticular veins	5 (33.3)
Varicose veins	5 (33.3)

Legend: Appearance of enlarged atypical superficial veins

Journal Pre-proof

Journal Pre-proof

Table III

Compartment	N (%)
Subcutis	14 (93.3)
Muscle	5 (33.3)
Cutis	4 (26.6)
Bone	1 (6.6)
Organs	none

Legend: Tissue involvement in patients with capillary-venulous malformation

Journal Pre-proof

Journal Pre-proof

Figure Legends

Figure 1: Patient 1; Digital subtraction angiography of a 58-year old patient with late shunting typically for CV-AVM.

Figure 2: Patient 1; Right leg of a 58-year old patient with dermatosclerosis and extensive recurrent varicose veins

Figure 3: Patient 2; Digital subtraction angiography of a 78-year old patient of the right foot.

Figure 4: Patient 2; Digital subtraction angiography of a 78-year old patient of the left foot.

Figure 5: Patient 2; Right leg of a 78-year old patient, with a severe form of CV-AVM with Schobinger stage 3 and a second, multifocal lesion at the dorsum of his left foot.

Table Legends

Table I: Demographic data of patients with capillary-venule malformation

Table II: Appearance of enlarged atypical superficial veins

Table III: Tissue involvement in patients with Capillary-venule malformation malformation

Journal Pre-proof

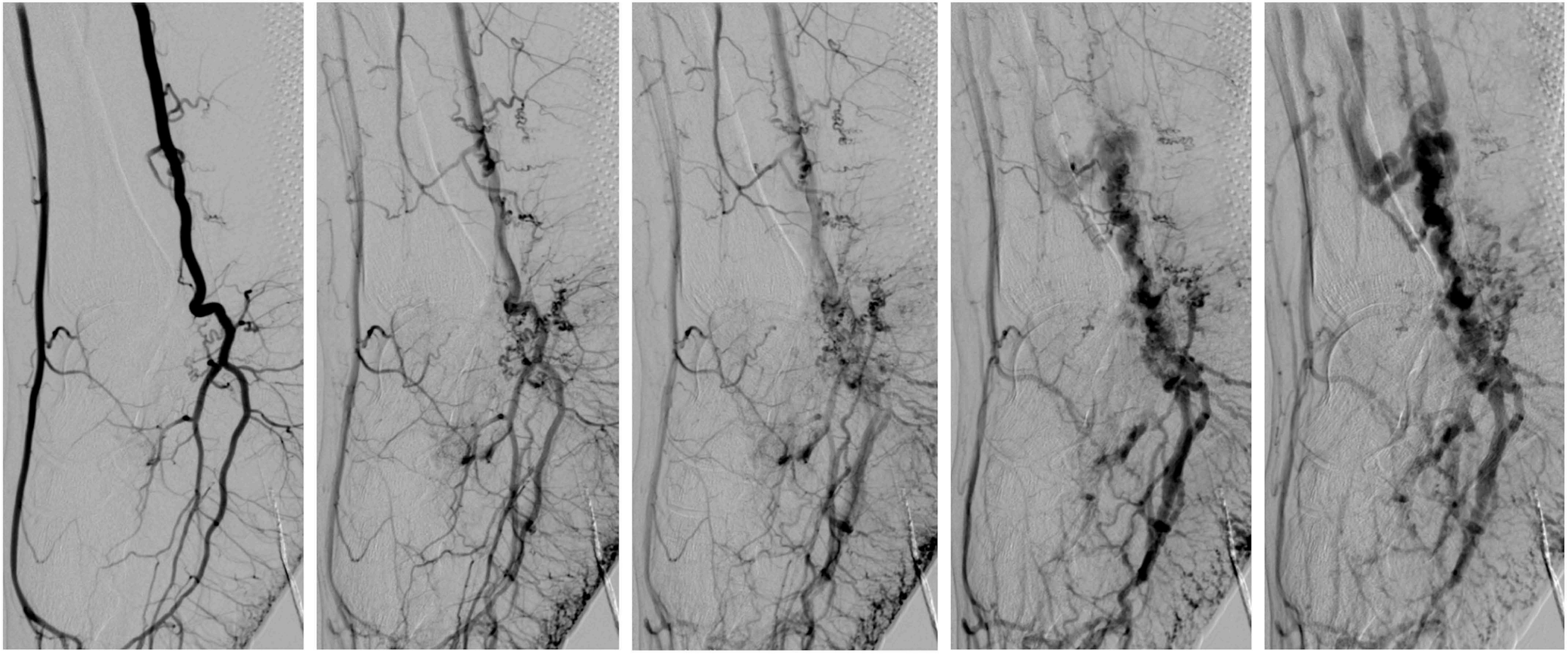
Early image
Late image

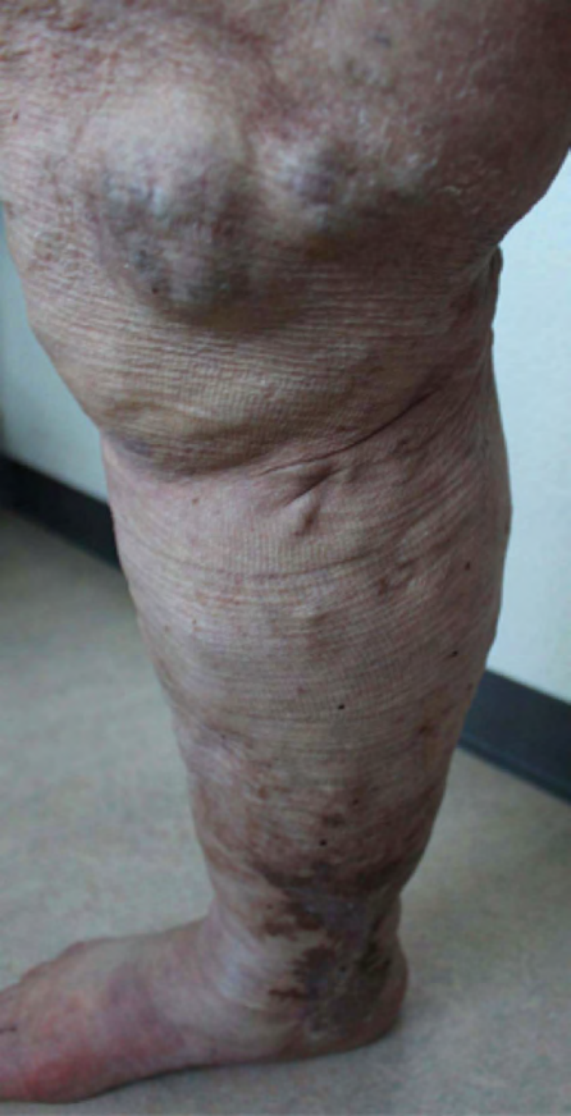

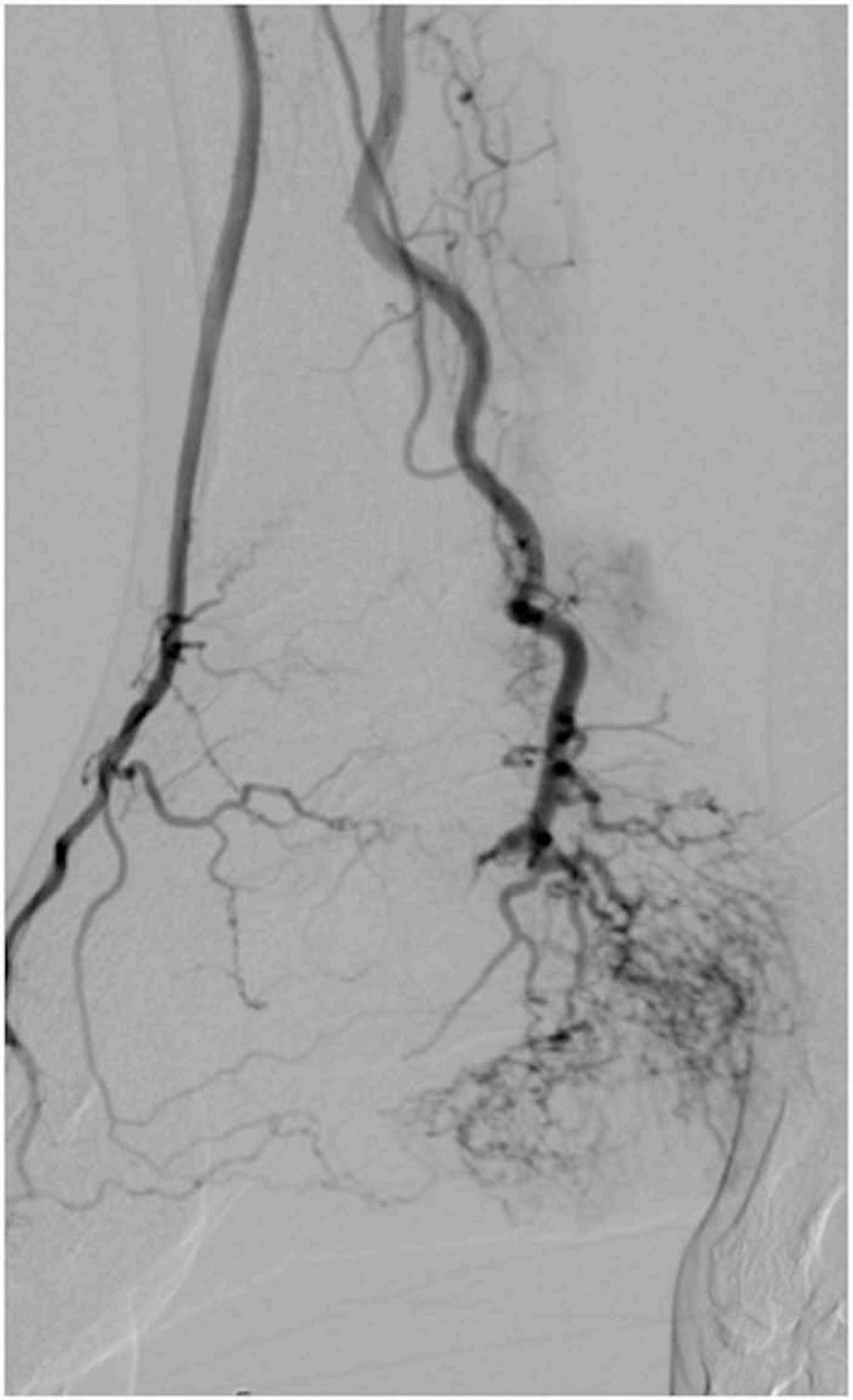

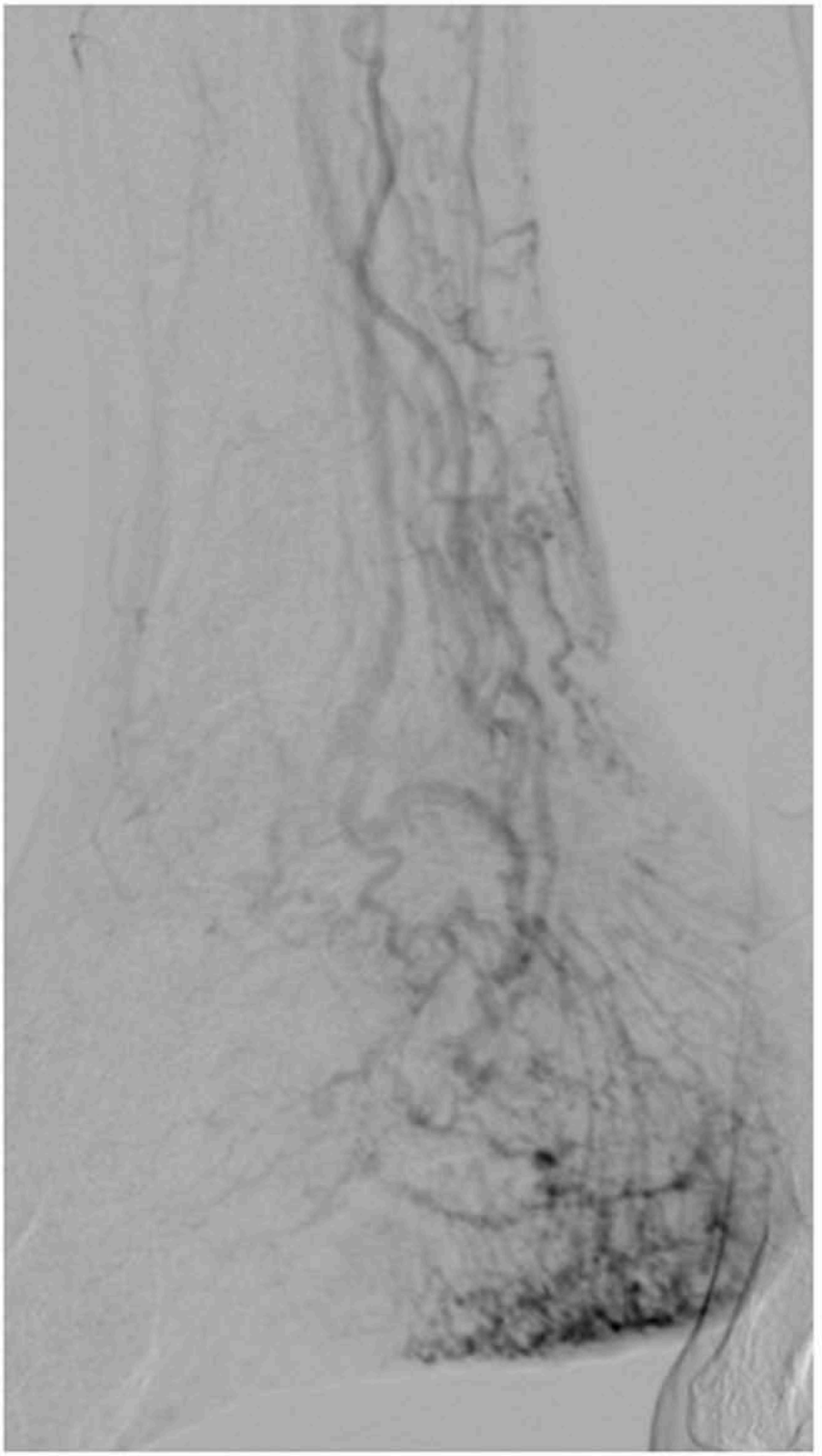

Early image

Late image

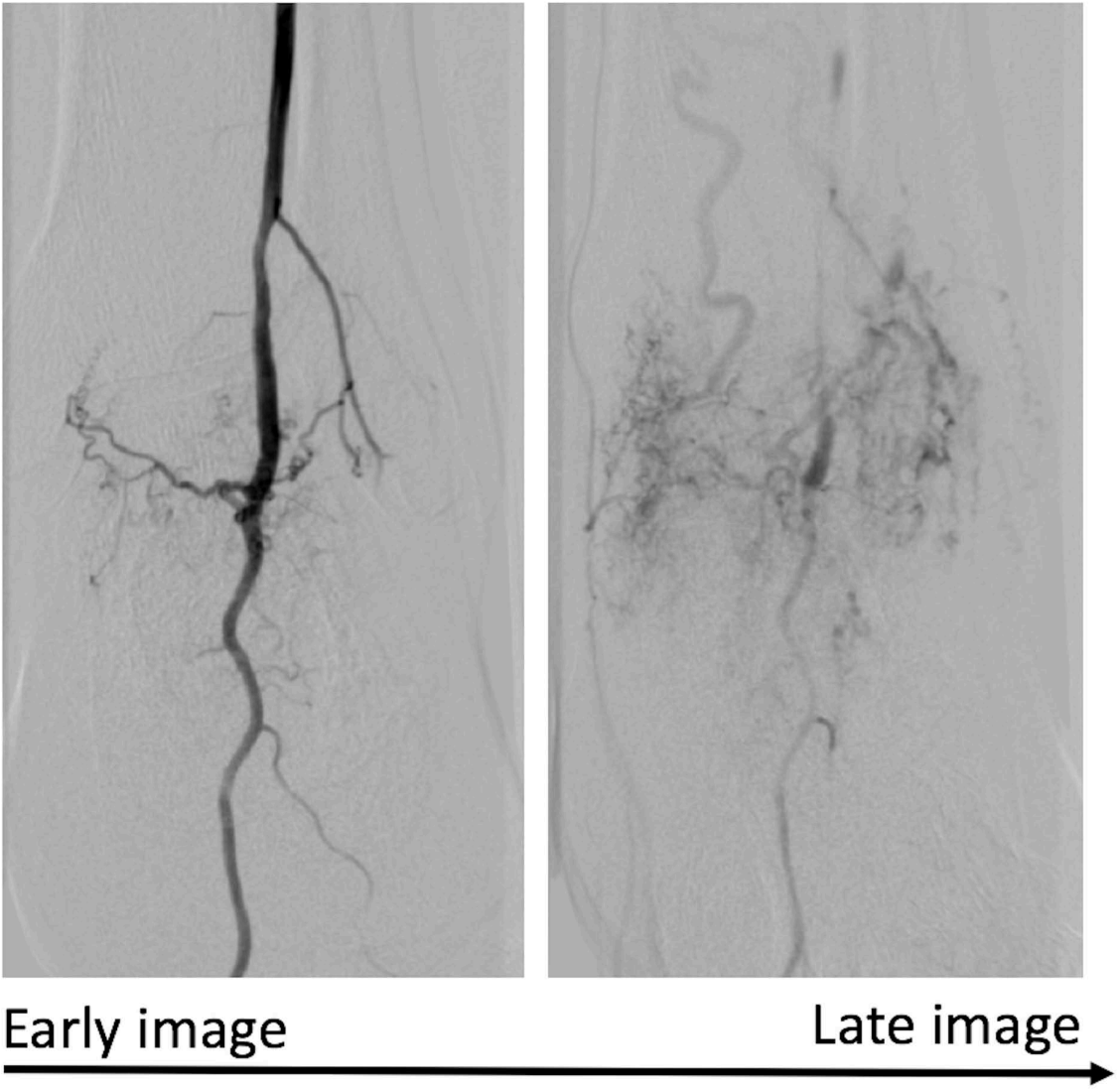
Early image
Late image