CARDIOVASCULAR FLASHLIGHT

doi:10.1093/eurheartj/ehaa825

Pulmonary haemorrhage on veno-arterial ECMO: consequences of missed aortic valve regurgitation

Romy Sweda[1], David Berger [2], Johannes T. Heverhagen [3], and Lukas Hunziker[1]*

[1]Swiss Cardiovascular Center, Bern, Switzerland; [2]Department of Intensive Care Medicine, Inselspital, University Hospital Bern, Bern, Switzerland; and [3]Department of Diagnostic, Interventional, and Pediatric Radiology, Inselspital, University Hospital Bern, Bern, Switzerland

*Corresponding author. Tel: +41 31 63 2 71 28, Fax: +41 31 63 2 45 60, Email: lukas.hunziker@insel.ch

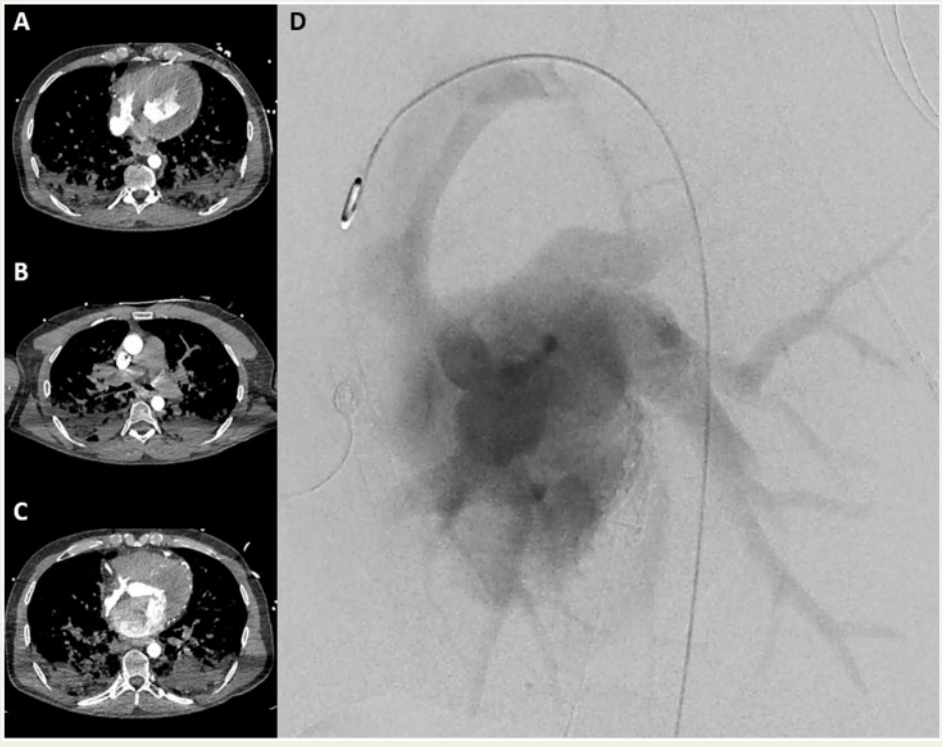

A 42-year-old male was admitted under ongoing cardiopulmonary resuscitation after having suffered a cardiac arrest from ventricular fibrillation while watching a sports event. Upon hospital arrival, he was in pulseless electrical activity; transthoracic echocardiography—limited by poor acoustic windows—indicated a hypertrophic left ventricle (LV) without pericardial effusion. The decision to place a veno-arterial extracorporeal membrane oxygenation (va-ECMO) was made and following peripheral cannulation, the flow was started with 3.8 L/min. A coronary angiogram displayed normal coronaries, whereas computed tomography angiography of the chest showed bilateral ground-glass opacities, a collapsed right ventricle (*Panel A*) without filling of the pulmonary arteries (*Panel B*) and a contrasted left atrium (*Panel C*). Three hours after va-ECMO placement, during most of which there was no pulsatility on the arterial pressure tracing, the patient developed progressive haemoptysis with a haemoglobin drop from 165 to 102 g/L. Bronchoscopy showed active bleeding predominantly from the right upper and left lower lobes that were refractory to the application of epinephrine and cyclocaprone. A subsequent angiogram revealed severe aortic valve regurgitation (AVR) with retrograde filling of the left ventricle and atrium up to the pulmonary veins (*Panel D*, Supplementary material online, *Video S1*), which was ameliorated by reducing ECMO flow (Supplementary material online, *Video S2*). This case illustrates the consequences of AVR during va-ECMO support, especially in combination with a non-ejecting heart, which results in LV-distension, secondary mitral regurgitation, and transmission of excessive pressures to the pulmonary vasculature. Maintaining contractility, adequate venting, and urgent referral for valve repair are crucial in this situation.

Supplementary material is available at *European Heart Journal* online.

Conflict of interest: The authors have submitted their declaration which can be found in the article Supplementary Material online.

Published on behalf of the European Society of Cardiology. All rights reserved. © The Author(s) 2020. For permissions, please email: journals.permissions@oup.com.

Downloaded from https://academic.oup.com/eurheartj/advance-article/doi/10.1093/eurheartj/ehaa825/5922864 by E-Library Insel user on 20 October 2020

source: https://doi.org/10.7892/boris.147174 | downloaded: 12.10.2024