



Seeing is repairing: how imaging-based timely interference with CXCR4 could improve repair after myocardial infarction

Yvonne Döring^{1,2,3}, Heidi Noels⁴, Emiel van der Vorst^{1,2,3,4,5,6}, and Christian Weber^{2,3,7,8*}

¹Department of Angiology, Swiss Cardiovascular Center, Inselspital, Bern University Hospital, University of Bern, Switzerland; ²Institute for Cardiovascular Prevention (IPEK), Ludwig-Maximilians-Universität München, Munich, Germany; ³DZHK (German Centre for Cardiovascular Research), partner site Munich Heart Alliance, Munich, Germany; ⁴Institute for Molecular Cardiovascular Research (IMCAR), RWTH Aachen University, Aachen, Germany; ⁵Department of Pathology, Cardiovascular Research Institute Maastricht (CARIM), Maastricht University Medical Centre, Maastricht, The Netherlands; ⁶Interdisciplinary Center for Clinical Research (IZKF), RWTH Aachen University, Aachen, Germany; ⁷Department of Biochemistry, Cardiovascular Research Institute Maastricht (CARIM), Maastricht University Medical Centre, Maastricht, The Netherlands; and ⁸Munich Cluster for Systems Neurology (SyNergy), Munich, Germany

Online publish-ahead-of-print 11 September 2020

This editorial refers to ‘Molecular imaging-guided repair after acute myocardial infarction by targeting the chemokine receptor CXCR4[†]’, by A. Hess et al., on page 3564.

Applying CXCR4-guided imaging to mediate myocardial repair after MI

Myocardial infarction (MI) occurs when coronary arteries become obstructed by ruptured atherosclerotic lesions, resulting in ischaemic injury to the heart tissue that is normally oxygenized by this vessel. Shortly after the ischaemic insult, the cardiac repair process starts, which entails a complex and fine-tuned series of events, including inflammatory and reparative responses.¹ In this issue of the *European Heart Journal*, Hess et al.² explore the value of the chemokine receptor CXCR4 in molecular imaging-guided therapy after acute MI.

The authors examined the effect of administering the CXCR4 antagonist AMD3100 on cardiac function after MI, guided by positron emission tomography (PET) imaging of CXCR4 expression as read-out of inflammatory cell accumulation in the heart in order to determine the best timing of therapeutic CXCR4 targeting. Building on their previous observations of molecular imaging of CXCR4 in the infarcted heart using the radiotracer [⁶⁸Ga]pentixafor,³ cardiac CXCR4 expression was confirmed to increase directly after MI and to remain significantly up-regulated up to 3 days after infarction. The CXCR4 signal localized in the infarcted region and coincided both

locally and temporally with the accumulation of neutrophils and monocytes. Of note, early infarct CXCR4 signal could predict subsequent cardiac outcome as measured as acute left ventricular rupture as well as left ventricular ejection fraction 6 weeks after MI, independent of infarct size. Based on these findings, the therapeutic value of timely CXCR4 targeting was examined (*Figure 1*). This revealed that single-dose on-peak CXCR4 blockade, but not off-peak blockade, with AMD3100 improved cardiac function after MI, which was associated with a reduced cardiac infiltration of mainly neutrophils and proinflammatory monocytes.²

Cardiac repair after MI: a delicate balance between inflammatory and reparatory processes

The first cells that respond to myocardial injury, already within minutes, are resident mast cells by releasing pre-formed granules, as well as resident macrophages and cardiomyocytes that start producing inflammatory cytokines and chemokines.⁴ This initial inflammatory trigger produced by resident cells results in the recruitment of neutrophils and Ly6C^{hi} monocytes from the circulation into the cardiac tissue within 1 day.⁴ Recruited cells mainly participate in the phagocytosis of dead and dying cardiomyocytes and produce more inflammatory cytokines to further stimulate the inflammatory response. Neutrophils disappear rather quickly again from the cardiac tissue, with their numbers decreasing already after 3 days and a complete

The opinions expressed in this article are not necessarily those of the Editors of the *European Heart Journal* or of the European Society of Cardiology.

[†] doi:10.1093/eurheartj/ehaa598.

*Corresponding author. Institute for Cardiovascular Prevention, LMU Munich, Pettenkoferstr. 9, D-80336 München, Germany, Tel: +49 89 4400 54350, Fax: +49 89 4400 54352, Email: chweber@med.lmu.de

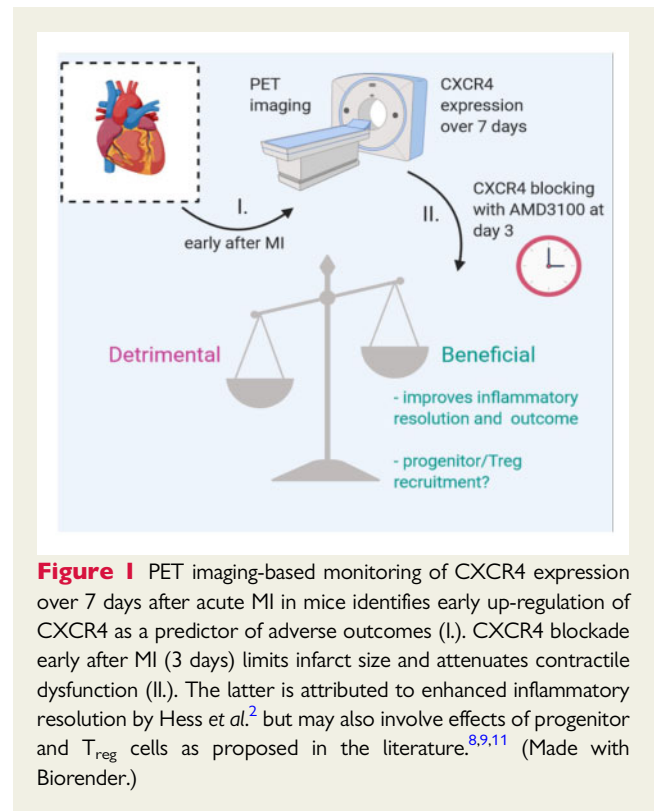
Published on behalf of the European Society of Cardiology. All rights reserved. © The Author(s) 2020. For permissions, please email: journals.permissions@oup.com.

absence after 7 days. Apoptotic neutrophils release transforming growth factor- β (TGF- β), lactoferrin, and annexin A1, and thereby trigger the rise of anti-inflammatory, reparative macrophages (M2-like).^{4,5} In contrast to neutrophils, monocytes persist and continue to accumulate. However, during the transition from the inflammation phase to the reparative phase around day 7, predominantly Ly6C^{low} monocytes accumulate and differentiate into M2-like macrophages.⁴ Besides the role of these innate immune cells, lymphocytes have also been demonstrated to be involved in cardiac repair after MI. During the early inflammatory phase, CD4⁺ helper T cells and CD8⁺ cytotoxic T cells accumulate in the cardiac tissue, fuelling the inflammatory response. During the reparative phase, regulatory T cells prevail and secrete interleukin-10 (IL-10) and TGF- β , thereby contributing to inflammatory resolution and stimulating the differentiation of macrophages towards an M2-like phenotype.⁴ M2-like macrophages predominantly produce TGF- β and vascular endothelial growth factor (VEGF), thereby promoting fibrosis and angiogenesis.⁴ Fibrosis, comprised of fibroblast proliferation and matrix production, is needed to form a collagen-rich scar at the site of injury. This scar formation tends to increase the physical load on the neighbouring viable myocardium.⁴ Therefore, angiogenesis, in part contributed by mobilized progenitor cells, is important to provide sufficient perfusion of the surrounding tissues to overcome the effects of scar formation. Viewed in conjunction, the process of cardiac repair involves a complex interaction of different immune cells and tissue resident cells that cooperate in a timely manner to optimally repair the damaged cardiac tissue.

Since inflammation is a crucial player in cardiac remodelling after ischaemia, a careful balance between proinflammatory and reparatory aspects of inflammation is extremely important to prevent myocardial damage by unconstrained inflammation, and therapeutic strategies to improve this delicate balance are highly challenging. This holds especially true for patients subjected to fast reperfusion therapy following MI, which itself evokes considerable myocardial reperfusion injury and thereby significantly contributes to heart failure complications in patients initially surviving MI.⁶

A complex role for the chemokine receptor CXCR4 in cardiac remodelling after myocardial ischaemia

A role for CXCR4 in inflammation and cardiac remodelling after myocardial ischaemia as well as ischaemia/reperfusion (I/R) injury has been intensely investigated over the last decades, revealing a dual role for CXCR4 and its bona fide ligand CXCL12. For example, intramyocardial injection of CXCL12 in animal models reduced infarction size and increased cardiac function after MI. The latter was attributed to improved survival of hypoxic myocardium, and increased neoangiogenesis.⁷ Moreover, CXCL12-overexpressing adenovirus, CXCL12-transgenic skeletal myoblasts, or CXCL12-releasing hydrogels revealed enhanced recruitment and incorporation of CXCR4⁺ stem and progenitor cells in the infarcted area.⁷ Hence, progenitor cell recruitment through local engagement of the CXCL12–CXCR4



axis may contribute over increased neovascularization to cardiac repair after MI. Within this concept, animal models of MI investigating pharmacological blockade of CXCR4 in mice and pigs with the small-molecule antagonists plerixafor (AMD3100) or burixafor (TG-0054) revealed improved heart function after MI.^{8–10} Here, beneficial effects of CXCR4 blocking after MI were again associated with enhanced mobilization and cardiac recruitment of endothelial progenitor cells and increased infarct vascularization,^{8,9} in line with the role of CXCR4 in regulating progenitor cell homing in the bone marrow and its unleashing upon systemic CXCR4 antagonism.⁷ Furthermore, POL5551 (another CXCR4 antagonist) promotes tissue repair and functional adaptation after MI, mobilizing splenic T_{reg} cells into the peripheral blood, followed by enhanced T_{reg} cell accumulation in the infarcted region.¹¹ In this regard, the CXCL12–CXCR4 axis provides protective effects by recruiting T_{reg} and progenitor cells into the heart after ischaemic insult.

On the other hand, reduced CXCR4 expression by *Cxcr4* heterozygosity in mice reduced infarct size after MI along with reduced proinflammatory cell recruitment in the heart, delaying and shifting monocyte subset infiltration.¹² In turn, adenovirus-mediated overexpression of CXCR4 in the heart increased infarct size and reduced cardiac function, associated with an enhanced recruitment of proinflammatory cells, presence of inflammatory mediators, and increased apoptosis of cardiomyocytes.⁷ Thus, with CXCR4 widely expressed in the haematopoietic system, local CXCL12/CXCR4 stimulation mediates the recruitment of reparatory cells vs. proinflammatory leucocytes in ischaemic tissue, whereas systemic CXCR4 antagonism mobilizes not only haematopoietic stem and progenitor cells but also CXCR4⁺ leucocytes, affecting all haematopoietic lineages in patients and mice.⁷

Depending on the time point and duration of CXCR4 blocking, reparatory or proinflammatory effects may predominate. Thus, although not addressed in this study of Hess *et al.*,² it remains to be further examined whether the observed cardioprotective effects of single-dose CXCR4 antagonism after MI are at least partly also attributable to beneficial effects on T_{reg} cell and/or progenitor cell incorporation as well as neo-angiogenesis in the infarcted region. Cardioprotective effects of progenitor cell recruitment upon single, but not continuous, CXCR4 antagonism after MI and/or myocardial I/R injury have already been reported,^{7,11} but a real time-wise comparison with proinflammatory and T_{reg} recruitment in the ischaemic heart in relation to the time frame and/or duration of CXCR4 blockade remains to be properly elucidated.

Molecular imaging to guide timely therapeutic targeting of CXCR4 after MI

Over the last years, the value of molecular PET imaging of cardiac CXCR4 expression after MI using [⁶⁸Ga]pentixafor has been studied in pre-clinical as well as clinical settings.^{3,13} Similar efforts of PET-based molecular imaging were previously also performed to track proinflammatory CCR2+ leucocyte accumulation in the heart over time after myocardial I/R injury in mice¹⁴ as well as to trace VCAM-1 expression as a biomarker of local inflammation in the heart after MI.¹⁵ Also, PET tracing of superoxide production as read-out of oxidative stress in the injured heart recently revealed a correlation of signal intensity with reduced chronic cardiac function.¹⁶ Such local imaging provides advantages over analysis of systemic inflammation biomarkers by directly providing insights into the ongoing molecular mechanisms in the injured tissue itself. In the current study, Hess *et al.* further build on these insights and elegantly illustrate the advantages of molecular imaging in guiding therapeutic intervention by identifying the most promising time point for drug application in a pre-clinical model.² Although the findings are mainly related to myocardial ischaemia, patients early after ST-elevation MI and reperfusion revealed increased, albeit highly variable, CXCR4 expression in the infarcted region. As this signal inversely correlated with cardiac function at follow-up, molecular CXCR4 imaging may be useful to identify patients that would benefit most from anti-inflammatory therapy following reperfusion treatment as well as to monitor the optimal time point of drug administration.

In conclusion, building on the virtues of molecular PET imaging for non-invasive analysis of biomarker expression within injured tissue in a pre-clinical as well as in a clinical setting, the study of Hess *et al.* demonstrates the value of CXCR4 PET imaging in identifying the best time point of anti-inflammatory treatment by CXCR4 antagonism with respect to chronic cardiac function.²

Conflict of interest: none declared.

References

- Liu Y, Xu J, Wu M, Kang L, Xu B. The effector cells and cellular mediators of immune system involved in cardiac inflammation and fibrosis after myocardial infarction. *J Cell Physiol* 2020;doi: 10.1002/jcp.29732.
- Hess A, Derlin T, Koenig T, Diekmann J, Wittneben A, Wang Y, Wester H-J, Ross TL, Wollert KC, Bauersachs J, Bengel FM, Thackeray JT. Molecular imaging-guided repair after acute myocardial infarction by targeting the chemokine receptor CXCR4. *Eur Heart J* 2020;**41**:3564–3575.
- Thackeray JT, Derlin T, Haghikia A, Napp LC, Wang Y, Ross TL, Schafer A, Tillmanns J, Wester HJ, Wollert KC, Bauersachs J, Bengel FM. Molecular imaging of the chemokine receptor CXCR4 after acute myocardial infarction. *JACC Cardiovasc Imaging* 2015;**8**:1417–1426.
- Swirski FK, Nahrendorf M. Cardioimmunology: the immune system in cardiac homeostasis and disease. *Nat Rev Immunol* 2018;**18**:733–744.
- Horckmans M, Ring L, Duchene J, Santovito D, Schloss MJ, Drechsler M, Weber C, Soehnlein O, Steffens S. Neutrophils orchestrate post-myocardial infarction healing by polarizing macrophages towards a reparative phenotype. *Eur Heart J* 2017;**38**:187–197.
- Frohlich GM, Meier P, White SK, Yellon DM, Hausenloy DJ. Myocardial reperfusion injury: looking beyond primary PCI. *Eur Heart J* 2013;**34**:1714–1722.
- Doring Y, Pawig L, Weber C, Noels H. The CXCL12/CXCR4 chemokine ligand/receptor axis in cardiovascular disease. *Front Physiol* 2014;**5**:212.
- Jujo K, Hamada H, Iwakura A, Thorne T, Sekiguchi H, Clarke T, Ito A, Misener S, Tanaka T, Klyachko E, Kobayashi K, Tongers J, Roncalli J, Tsurumi Y, Hagiwara N, Losordo DW. CXCR4 blockade augments bone marrow progenitor cell recruitment to the neovasculature and reduces mortality after myocardial infarction. *Proc Natl Acad Sci USA* 2010;**107**:11008–11013.
- Jujo K, Li M, Sekiguchi H, Klyachko E, Misener S, Tanaka T, Tongers J, Roncalli J, Renault MA, Thorne T, Ito A, Clarke T, Kamide C, Tsurumi Y, Hagiwara N, Qin G, Asahi M, Losordo DW. CXCR4 antagonist TG-0054 mobilizes mesenchymal stem cells, attenuates inflammation, and preserves cardiac systolic function in a porcine model of myocardial infarction. *Cell Transplant* 2015;**24**:1313–1328.
- Wang Y, Dembrowsky K, Chevalier E, Stuve P, Korf-Klingebiel M, Lochner M, Napp LC, Frank H, Brinkmann E, Kanwischer A, Bauersachs J, Gojnyosi M, Sparwasser T, Wollert KC. C-X-C motif chemokine receptor 4 blockade promotes tissue repair after myocardial infarction by enhancing regulatory T cell mobilization and immune-regulatory function. *Circulation* 2019;**139**:1798–1812.
- Liehn EA, Tuchscheerer N, Kanzler I, Drechsler M, Fraemohs L, Schuh A, Koenen RR, Zander S, Soehnlein O, Hristov M, Grigorescu G, Urs AO, Leabu M, Bucur I, Merx MW, Zerneck A, Ehling J, Gremse F, Lammers T, Kiessling F, Bernhagen J, Schober A, Weber C. Double-edged role of the CXCL12/CXCR4 axis in experimental myocardial infarction. *J Am Coll Cardiol* 2011;**58**:2415–2423.
- Lapa C, Reiter T, Werner RA, Ertl G, Wester HJ, Buck AK, Bauer WR, Herrmann K. [⁶⁸Ga]Pentixafor-PET/CT for imaging of chemokine receptor 4 expression after myocardial infarction. *JACC Cardiovasc Imaging* 2015;**8**:1466–1468.
- Heo GS, Kopecky B, Sultan D, Ou M, Feng G, Bajpai G, Zhang X, Luehmann H, Detering L, Su Y, Leuschner F, Combadiere C, Kreisel D, Gropler RJ, Brody SL, Liu Y, Lavine KJ. Molecular imaging visualizes recruitment of inflammatory monocytes and macrophages to the injured heart. *Circ Res* 2019;**124**:881–890.
- Nahrendorf M, Keliher E, Panizzi P, Zhang H, Hembrador S, Figueiredo JL, Aikawa E, Kelly K, Libby P, Weissleder R. ¹⁸F-4V for PET-CT imaging of VCAM-1 expression in atherosclerosis. *JACC Cardiovasc Imaging* 2009;**2**:1213–1222.
- Boutagy NE, Wu J, Cai Z, Zhang W, Booth CJ, Kyriakides TC, Pfau D, Mulnix T, Liu Z, Miller EJ, Young LH, Carson RE, Huang Y, Liu C, Sinusas AJ. *In vivo* reactive oxygen species detection with a novel positron emission tomography tracer, ¹⁸F-DHMT, allows for early detection of anthracycline-induced cardiotoxicity in rodents. *JACC Basic Trans Sci* 2018;**3**:378–390.