Surgical Endoscopy (2020) 34:5469–5476
https://doi.org/10.1007/s00464-019-07343-3

Tailored access to the hepatobiliary system in post-bariatric patients: a tertiary care bariatric center experience

Dino Kröll[1] · Alexandra Charlotte Müller[1] · Philipp C. Nett[1] · Reiner Wiest[1] · Johannes Maubach[1] · Guido Stirnimann[1] · Daniel Candinas[1] · Yves Michael Borbély[1]

Received: 29 May 2019 / Accepted: 24 December 2019 / Published online: 28 January 2020

Abstract

Background In bariatric surgery patients, pancreaticobiliary access via endoscopic retrograde cholangiopancreatography (ERCP) is technically challenging and the optimal approach for the evaluation and treatment of biliary tree-related pathologies has been debated. Besides laparoscopy-assisted ERCP (LA-ERCP) as standard of care, EUS-directed transgastric ERCP (EDGE) and hepaticogastrostomy (HGS) with placement of a fully covered metal stent have emerged as novel techniques. The objective of this study was to evaluate safety and efficacy of three different endoscopic approaches (LA-ERCP, EDGE, and HGS) in bariatric patients.

Methods In this retrospective review, consecutive patients with Roux-en-Y gastric bypass (RYGB) and Sleeve Gastrectomy (SG) who underwent from 2013 to 2019 a LA-ERCP, an EDGE, or a HGS at a tertiary care reference center for bariatric surgery were analyzed. Patient demographics, type of procedure and indication, data regarding cannulation and therapeutic intervention of the common bile duct (procedure success), and clinical outcomes were analyzed.

Results A total of 19 patients were included. Indications for LA-ERCP, EDGE, or HGS were mostly choledocholithiasis (78.9%) and in a few cases papillitis stenosans. Eight patients (57.1%) with LA-ERCP underwent concomitant cholecystectomy. Procedure success was achieved in 100%. Adverse events (AEs) were identified in 15.7% of patients (all ERCP related). All AEs were rated as moderate and there were no serious AEs.

Conclusion This case series indicates that ERCP via a transgastric approach (LA-ERCP, EDGE, or HGS) is a minimally invasive, effective, and feasible method to access the biliary tree in bariatric patients. These techniques offer an appealing alternative treatment option compared to percutaneous transhepatic cholangiography and drainage- or deep enteroscopy-assisted ERCP. In bariatric patients who earlier had a cholecystectomy, EUS-guided techniques were the preferred treatment options for biliary pathologies.

Keywords Roux-en-Y gastric bypass · Bariatric surgery · Endoscopic retrograde cholangiopancreaticography · Laparoscopically assisted · EDGE · HGS

Electronic supplementary material The online version of this article (https://doi.org/10.1007/s00464-019-07343-3) contains supplementary material, which is available to authorized users.

✉ Dino Kröll
dino.kroell@insel.ch

Alexandra Charlotte Müller
alexandracharlotte.mueller@insel.ch

Philipp C. Nett
philipp.nett@insel.ch

Reiner Wiest
reiner.wiest@insel.ch

Johannes Maubach
johannes.maubach@insel.ch

Guido Stirnimann
guido.stirnimann@insel.ch

Daniel Candinas
daniel.candinas@insel.ch

Yves Michael Borbély
yves.borbely@insel.ch

[1] Department of Visceral Surgery and Medicine, Inselspital, Bern University Hospital and University of Bern, 3010 Bern, Switzerland

Bariatric surgery is the most effective treatment for morbid obesity and associated metabolic disorders, and Roux-en-Y gastric bypass (RYGB) is one of the most performed interventions worldwide. Despite being effective at weight loss, bariatric surgery is associated with significant adverse events. In bariatric patients, pancreaticobiliary diseases are not uncommon in the post-surgical course. Gallstones for example develop in about 30% of patients within six months after bariatric surgery and the risk for stones in the common bile duct is increased in the setting of excessive weight reduction and changes in the composition of the bile [1, 2].

Due to the altered anatomy, surgeons as well as gastroenterologists face several challenges. Traditional transoral endoscopic retrograde cholangiopancreaticography (ERCP) after bariatric surgery is challenging if feasible at all due to alteration so the anatomy of the stomach or the length of the Roux limb, especially when the latter is > 150 cm long. Percutaneous transhepatic cholangiography and drainage is not ideal due to the percutaneous access and surgical exploration poses an additional burden on the patient.

Therefore, alternative techniques have been developed and described in case reports or small series. Pancreaticobiliary interventions have advanced to enteroscopy-assisted ERCP by using single-balloon, double-balloon, or spiral enteroscopy, but these techniques are associated with lower success rates compared to standard interventions [3]. More recently, the enteroscopy techniques evolved in the direction of laparoscopic surgically assisted gastrostomy with transgastric ERCP (LA-ERCP). A systematic review of 26 studies including over 500 open or laparoscopic transgastric ERCP revealed a biliary cannulation rate of 98.5%, which is comparable to transoral ERCP performed in patients with preserved anatomy [3]. Yet, adverse events rates have been reported in up to 36% of patients [4].

In bariatric patients, LA-ERCP is currently considered as gold standard due to a high technical success rate reaching the major papilla compared to enteroscopy-assisted ERCP approaches (100% vs. 72%; $P = 0.005$) [5].

Alternative minimal invasive procedures using endoscopic ultrasound (EUS)-guided biliary access techniques have been developed in recent years, but literature on these techniques is still scarce [6, 7]. In EUS-directed gastroenterostomy, a transgastric ERCP (EDGE) with a conventional duodenoscope can be performed via a temporary gastric remnant access after placing a fully covered lumen-apposing stent [8].

Similar to the EDGE technique, EUS-guided hepaticogastrostomy (HGS) can be performed from the proximal gastric pouch or the Roux limb into a dilated intrahepatic duct in the left liver lobe [9] and both techniques are encouraging given their high technical success rate and limited number of complications [10].

The objective of this study was to review our institution's longitudinal experience regarding safety and efficacy of minimally invasive transgastric endoscopic procedures using a standard duodenoscope in bariatric surgery patients with biliary diseases and to provide a practical and patient tailored approach as applied in our center.

Methods

This retrospective single-center analysis was conducted in a tertiary care referral center for bariatric surgery. Data of patients undergoing bariatric surgery between January 2013 and March 2019 were analyzed. The following criteria were used for inclusion: Patients ≥ 18 years of age,Sleeve Gastrectomy (SG) or RYGB, and LA-ERCP, EDGE ,or HGS in the post-surgical course. Data of initial bariatric procedure were obtained in patients referred from outside. This study has been approved by the independent local ethics committee. All procedures have been performed by three surgeons and two gastroenterologists. The following data were collected: demographic and clinical information, obesity-related comorbidities, year and type of bariatric surgery, cholecystectomy status, indication for biliary procedure, therapeutic interventions (biliary sphincterotomy, dilation of stricture, biliary stent placement or extraction, stone/sludge removal), success rate, adverse events, length of hospital stay and length of follow-up.

Outcome measures and definitions

The primary outcome was procedure success defined as follows: 1. Reaching the major papilla and 2. Performing the desired therapeutic maneuvers as clinically indicated. Secondary outcomes were total cumulative procedure time (laparoscopic and ERCP) and adverse events. Adverse events were classified as either ERCP related (pancreatitis, cholangitis, sphincterotomy-related perforation and bleeding) or laparoscopy related (bleeding, leak, surgical site infections, perforation). Severity of adverse events was classified according the American Society for Gastrointestinal Endoscopy lexicon [11] and the Clavien–Dindo Classification [12].

Procedural techniques

LA-ERCP

LA-ERCP requires both, surgical and endoscopy teams. Laparoscopy was performed using three to four trocars (10 mm optiview supraumbilical, 10 mm in the left midline

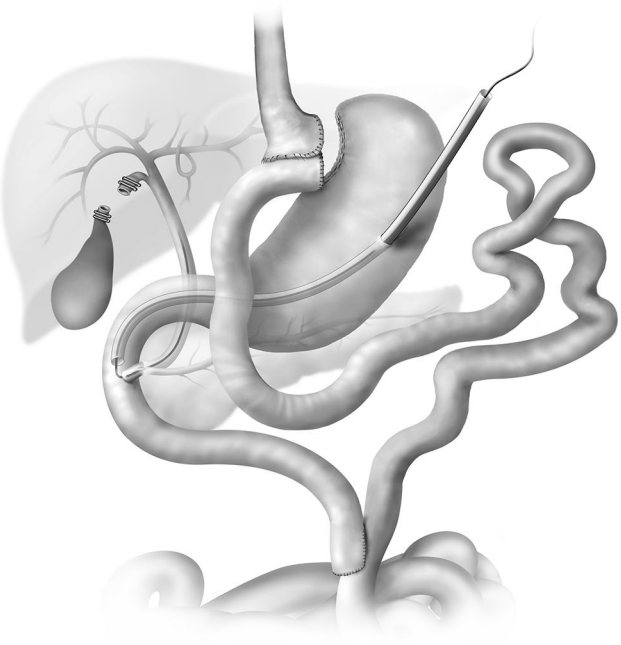

Fig. 1 Schematic representation of transgastric access to the remnant in Roux-en-Y gastric bypass (LA-ECRP)

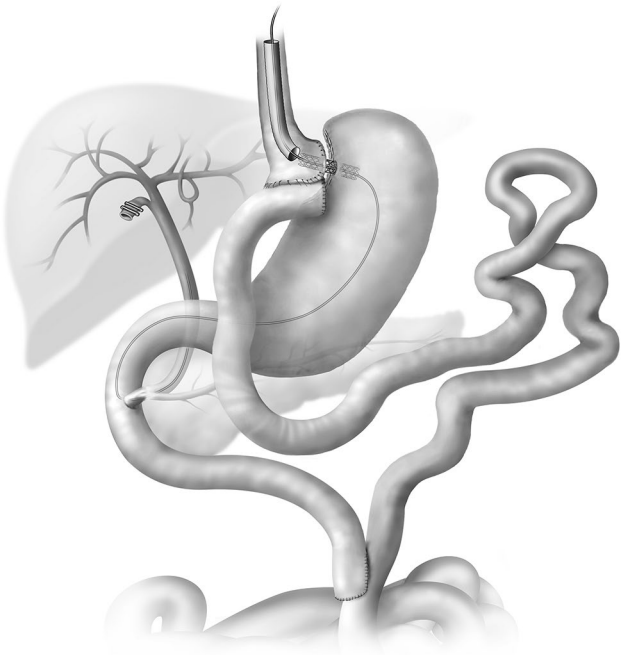

Fig. 2 Schematic representation of EUS-directed transgastric ERCP (EDGE) with puncture of the remnant through the pouch with placement of a fully covered metal stent

quadrant, 5 mm trocar in right lower quadrant and 5 mm trocar epigastric in case of a planned simultaneous cholecystectomy) (Fig. 1). Stay sutures were placed on the gastric remnant. A gastrostomy was then made and a 15 mm trocar advanced into the stomach (Supp. Figure 1). ERCP was performed trough temporary gastrostomy. After completion, the gastrostomy was closed with a running absorbable suture.

EDGE

EDGE is a two-step procedure: After proper identification of the gastric remnant with EUS, a needle puncture from the alimentary limb to the excluded stomach was performed. A gastrojejunostomy was then performed placing a lumen-apposing metal stent (LAMS). A few days after, the papilla was accessed via the duodenum passing a duodenoscope through the LAMS and the excluded stomach (Fig. 2, Supp. Figure 2). A regular ERCP with sphincterotomy and complete stone clearance of the common bile duct was then performed. After confirmed stone removal, the LAMS was removed and the gastrojejunostomy closed with an Over-The-Scope Clip.

HGS

In patients with dilated intrahepatic bile ducts, biliary drainage of the hepatic segment II/III to the Roux-en-Y limb was performed by a EUS-guided insertion of a self-expanding covered metal stent (SEMS). Three weeks later, after

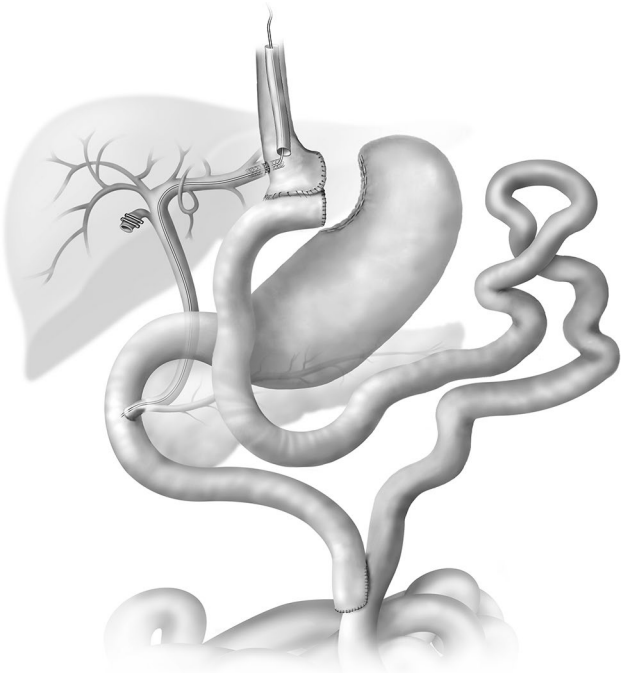

Fig.3 Schematic representation of EUS-directed transgastric hepaticogastrostomy (HGS) with puncture of the dilated left bile duct and with placement of a fully covered metal stent

maturing of the hepaticojejunostomy, a transjejunal cholangioscopy was performed by advancing a spyscope through the SEMS (Supp. Figure 3). If biliary stones were identified in the common bile duct, they were fragmented by electrohydraulic lithotripsy (EHL, Supp. Fig. 4). In the final step, the papilla was cannulated and a guidewire was passed into the duodenum. The papilla was dilated to 10 mm and a 10F 15 cm double-pigtail stent was inserted as shown in Fig. (3). The SEMS was extracted at the end of the procedure and the fistula was closed using endoscopic Over-The-Scope-Clip. The double-pigtail stents was removed after 6 weeks.

Statistical analysis

The statistical analysis was performed with Stata® 13.1 (StataCorp, College Station, Texas, USA). The distribution of continuous variables was described by mean and standard deviation. Categorical variables were shown as total number and percentages.

Results

Baseline characteristics

In total, 19 patients were included. Of these, 14 patients were treated with LA-ERCP, two patients with EDGE and three with HGS (two after RYGB, one with prior SG). Baseline demographics and clinical characteristics are displayed in Table 1.

Mean age of all patients was 50 (28–72) years and 63% of the patients were female. Mean BMI at the time of the endoscopic intervention was 31 kg/m^2 (24–45). The average time between bariatric surgery and endoscopic procedure was 5 years (range 0–12 years).

Main indications for LA-ERCP and EDGE were biliary tract pathologies The most frequent reason for the interventions was choledocholithiasis (78.6%); other indications included sphincter oddi dysfunction, biliary leakage after cholecystectomy, sepsis caused by cholecystitis perforata, and papillary stenosis (one patient each).

Therapeutic interventions are further detailed in Table 2, Most common were biliary sphincterotomy (88.8%) and stone extraction (88.8%).

Eight patients (42.8%) underwent LA-ERCP with combined cholecystectomy. Another eight patients had cholecystectomy already performed prior to the biliary intervention. One patient of the LA-ERCP group required conversion to an open surgical approach due to adhesions. Procedural and clinical outcomes are summarized in Table 2.

Overall, procedure success was achieved in 100%. Median total (laparoscopy and ERCP) procedure time was overall 145 (50–465) minutes, for LA-ERCP 165 (100–465) minutes, for EDGE 101 min (56–147) and for HGS 130 min (53–156), respectively. Median length of hospital stay was 7.5 days (3–13 days).

All adverse events were ERCP related: one patients suffered from a post-ERCP pancreatitis and two from a cholangitis (Clavien–Dindo grade 2). No surgery-related adverse

Table 1 Patient characteristics and clinical characteristics

	LA-ERCP	EDGE	HGS	Overall
Number of patients, *n* (%)	14 (78.0)	2 (10.5)	3 (16.5)	19 (100)
Age (years), median (range)	45.5 (72–28)	50.5 (49–52)	57 (51–67)	50 (28–72)
Gender, male/female	3/11	2/0	2/1	7/12
BMI (kg/m^2), median (range)	30.0 (24–45)	36.3 (35–37.6)	36 (27–41)	31 (24–45)
Type of bariatric surgery				
RYGB, *n*	14	2	2	18
SG, *n*	0	0	1	1
Cholecystectomy				
Prior to ERCP, *n* (%)	6 (42.8)	0 (0)	2 (66.7)	8 (42.1)
Simultaneous ERCP, *n* (%)	8 (57.1)	n.a	n.a	8 (42.1)
After ERCP, *n* (%)	0 (0)	0 (0)	1 (33.3)	1 (5.2)
Indication				
Biliary stones, *n* (%)	11 (78.6)	2 (100)	2 (66.7)	15 (78.9)
Suspected papillary stenosis, *n* (%)	2 (14.3)	0 (0)	0 (0)	2 (10.5)
Other biliary indications, *n* (%)	1 (7.1)	0 (0)	1 (33.3)	2 (9.5)
Pancreatic indication, *n* (%)	0 (0)	0 (0)	0 (0)	0 (0)

BMI Body Mass Index, *RYGB* Roux-en-Y Gastric Bypass, *SG*: sleeve gastrectomy, *ERCP* endoscopic retrograde cholangiopancreatography, *LA* laparoscopic, *EDGE* EUS-directed transgastric ERCP, *HGS* EUS-directed transgastric hepaticogastrostomy, *n.a.* not applicable

Table 2 Procedural data and clinical outcomes

	LA-ERCP ($n=14$)	EDGE ($n=2$)	HGS ($n=3$)	Overall ($n=19$)
ERCP: procedure success, *n* (%)	14 (100)	2 (100)	3 (100)	19 (100)
Biliary sphincterotomy/dilatation, *n* (%)	14 (100)	1 (100)	1 (33.3)	17 (88.8)
Stone/sludge/cast extraction, *n* (%)	14 (100)	1 (100)	1 (33.3)	17 (88.8)
Adverse events				
ERCP related, *n* (%)	2 (14.3)	*0* (0)	1 (33.3)	3 (15.7)
Pancreatitis, *n* (%)	1 (7.1)	0 (0)	0 (0)	1 (5.3)
Cholangitis, *n* (%)	1 (7.1)	0 (0)	1 (33.3)	2 (10.5)
Surgery related, *n* (%)	0 (0)	n.a	n.a	0 (0)
Procedure time*, mean (range)	165 (100–465)	101(56–147)	130 (53–156)	145 (50–465)
Median	196	101	113	137
Hospital stay, days (range)	6.5 (3–11)	8 (5–11)	9 (6–13)	7.5 (3–13)

BMI Body Mass Index, *RYGB* Roux-en-Y Gastric Bypass, *SG* sleeve gastrectomy, *ERCP* endoscopic retrograde cholangiopancreatography, *LA* laparoscopic, *EDGE* EUS-directed transgastric ERCP, *HGS* EUS-directed transgastric hepaticogastrostomy *n.a.* not applicable

*Cumulative procedure time, i.e., laparoscopy and ERCP time

events were reported. There was no mortality at 30-day follow-up.

Discussion

Access to biliary tree in post-bariatric patients with altered anatomy is technically challenging. To perform ERCPs in these patients, different endoscopic approaches, techniques and devices have been described in the recent past. However, data about the use of conventional ERCP technique with a side-viewing duodenoscope in combination with a laparoscopy or a EUS are still very limited. This study reviews the outcome of three approaches, i.e., laparoscopic assisted ERCP, EDGE and HGS that were performed according a structured pathway. This tailored approach results in a high success rate with minimal morbidity.

The primary success rate defined as reaching and cannulating the papilla vateri and performing therapeutic intervention with a transgastric/transenteric ERCP approaches was 100% in the three study groups investigated. This is in the range of previously reported success rates for biliary cannulation with LA-ERCP or EUS-guided treatments ranging from 80 to 100% [13, 14]. A reason for the different success rates reported in the literature might be different criteria for procedure success in the respective studies.

In our study all ERCP-related adverse events (one pancreatitis and two cholangitis) were classified as mild to moderate. There were no surgical related adverse events attributed to laparoscopy in the group with the LA-ERCP approach.

The ERCP-related adverse events rate (16.6%) was comparable to standard ERCP in patients with normal upper GI tract anatomy [13, 15].

In patients who underwent bariatric surgery, only a few EUS-directed ERCP techniques have been described [6, 7]. In these small case series, a regular duodenoscope with conventional devices for cannulation and intervention has been used.

In our series, EDGE was successfully performed in two cases through a temporary LAMS connecting the gastric pouch or the Roux limb and the remnant of the gastric bypass.

This approach has several advantages. It allowed for an antegrade ERCP with a minimally invasive technique that was associated with a high success rate and a shorter procedure time compared to LA-ERCP or HGS (EDGE 101 min, LA-ERCP 165 min, HGS 130 min, respectively). However, it is important to note the EDGE is a staged procedure performed on two different days. In the limited number of patients with EDGE and HGS, the acceptance of a two stage procedure was good. The EDGE procedure could also be performed in a one-stop-one-shot procedure using a thin duodenoscope, which reduces the risk of stent migration. The advantage of EDGE is that this approach can be used for repeat antegrade duodenoscope investigations. Dislodgment of the stent has been described [6], but did not occur in any of the patients of this series.

After removing the LAMS, the gastrojejunostomy can be closed easily, as has been the case in the patients of this series. The formation of a fistula after removal of the stent is of some concern, especially in the context of long-term weight regain [10]. However, this has not been seen in our small series after 12 months follow-up.

Another promising approach with advantages similar to those of the above described procedures is the access of the biliary system via HGS. EUS-guided puncture from the

proximal gastric pouch into an intrahepatic duct in the left lobe of the liver is performed to facilitate advancement of devices for subsequent peroral cholangioscopy by advancing a spyscope trough SEMS and subsequent stone fragmentation by a electrohydraulic lithotripsy [16]. This technique was performed in two cases in our study, one after Sleeve Gastrectomy with an unsuccessful conventional ERCP due to a narrow antrum and one after RYGB. Both cases demonstrated feasibility and efficacy of this access route.

To date, the best approach for diagnosis and treatment of pancreaticobiliary complications in patients with RYGB is not clear and a generally accepted algorithm on how to proceed in this patient population is not yet available. Reasons for this are the different endoscopic modalities and devices in use, the anatomic challenges in post-bariatric patients (inconstant length of Roux and pancreaticobiliary limb, potential adhesions, internal hernia, looping etc.) and t varying expertise of endoscopists and bariatric surgeons that are available to perform the respective ERCP interventions with or without laparoscopic assistance.

Traditional transoral push endoscopy performed in patients after RYGB is associated with relatively low ERCP success rates (16.2%) [17]. In patients with a Roux-en-Y anastomosis, success rates of enteroscopy-assisted ERCP techniques (e.g., single-/double-balloon and spiral enteroscopy), defined as reaching the major papilla, are higher (up to 100% for double-balloon techniques), but the rates of successful therapeutic ERPC were considerably lower (56–67%) [18-22]. Important is not only the therapeutic success rate, but also the rate of complications. Shah et al. a complication rate of 12% in patients with overtube-assisted enteroscopy to facilitate ERCP, including pancreatitis, abdominal pain and perforations [20].

It is important to note that the array of ERCP devices that are compatible with long-length enteroscopes (< 200 cm) is limited. Compared to the transoral endoscopic maneuvers, LA-ERCP is more invasive and especially challenging in terms of coordination between the endoscopist and the laparoscopic surgeon [5].

In our opinion, a crucial factor for successful interventions is the integration of gastroenterology and visceral surgery in one clinic in our department, facilitating collaboration and provision of ERCP during surgical interventions."

It is clear that defining an evidence-based treatment strategy based on the existing data for patients with complicated choledocholithiasis after bariatric surgery-related alteration of the intestinal anatomy is challenging. Therefore we propose a pragmatic approach to treat this patient group.

To select the best procedure for a given patient, careful evaluation of all locally available options including surgical and interventional expertise and interdisciplinary collaboration are important to achieve good outcomes. Based on the local situation, the optimal approach can vary from center to center. Moreover, type of bariatric procedure, need for cholecystectomy, and putative adhesions have to be taken into account while making a decision regarding the best procedure in a specific patient.

A LA- ERCP can be considered as the first-line approach in patients after RYGB where a cholecystectomy is required. In our population, concomitant cholecystectomy was performed in 57% of patients.

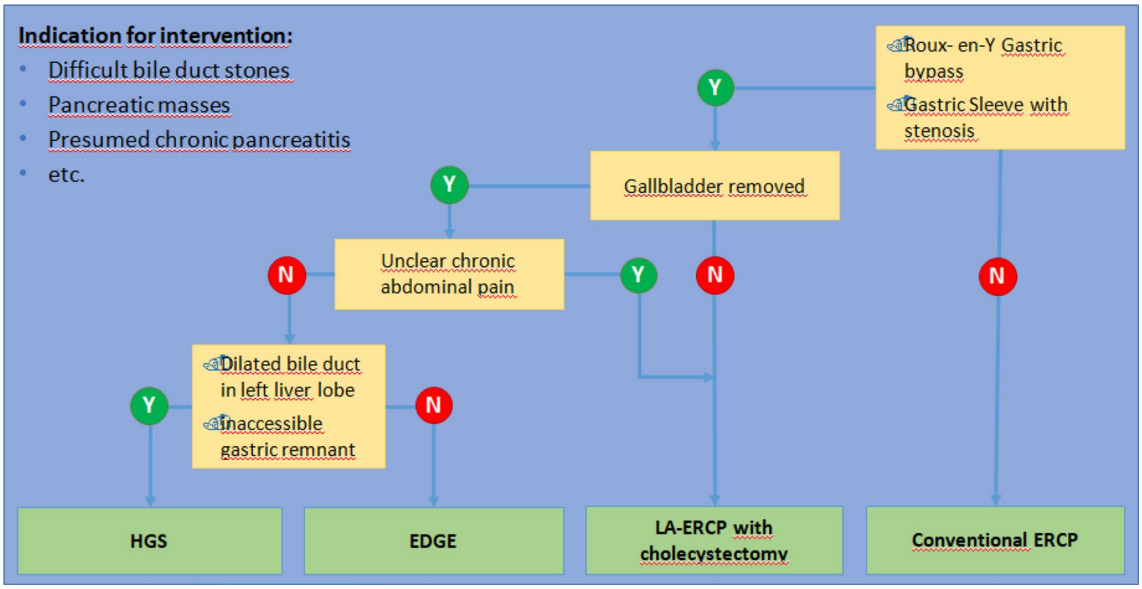

Fig. 4 Flow chart-tailored access to the hepatobiliary system in post-bariatric patients. *ERCP* endoscopic retrograde cholangio pancreatography, *LA* laparoscopic, *EDGE* EUS-directed transgastric ERCP, *HGS* EUS-directed transgastric hepaticogastrostomy

Additionally, in patients with chronic abdominal pain after gastric bypass, the laparoscopic approach also facilitates diagnosis and treatment of problems that may be of various origins, e.g., internal hernias, adhesions, pathologies of the jejunojejunostomy etc. According to Greenstein et al. chronic abdominal pain of various etiologies is a frequent problem after RYGB affecting up to 50% of patients [23].

In bariatric patients with pancreaticobiliary problems, in our opinion a transenteric/transgastric endoscopic approach to the biliary system with a standard diagnostic duodenoscope should be aimed at, especially when a conventional ERCP is not feasible, e.g., in patients with a history of RYGB or biliopancreatic diversion with duodenal switch with prior cholecystectomy.

If the endoscopic ultrasound reveals dilated intrahepatic bile ducts and the gastric remnant cannot be visualized, a HGS is preferred over an EDGE (Fig. 4).

Nonetheless, the medical center should have knowledge and expertise in bariatric surgery and advanced endoscopy (e.g., EUS) and a multidisciplinary approach with bariatric surgeons and endoscopists is essential.

This series demonstrates that ERCPs with a transgastric approach (LA-ERCP, EDGE or HGS) using a conventional duodenoscope have a high success rate and an acceptable safety profile. However, there is a need for prospective studies evaluating the risk–benefit ratio and analyzing long-term data including cost effectiveness for EUS-guided ERCP techniques compared to LA-ERCP.

Limitations of this study are the retrospective design and the small sample size. However, to date only a few small retrospective case series have described the use of laparoscopically assisted ERCP and EUS-guided transgastric/transjejunal approaches after bariatric procedures (RYGB, SG). Furthermore, no prospective evaluation of bariatric patients with hepatobiliary disease and endoscopy with a standard duodenoscope/cholangioscope is available.

Conclusions

The results of this study indicate that in patients after bariatric surgery ERCP with a transgastric approach (LA-ERCP, EDGE or HGS) is a minimally invasive, effective and feasible method to access the major papilla. In bariatric patients with prior cholecystectomy, EUS-guided techniques should be considered if an ERCP is required.

Compliance with ethical standards

Disclosures Dino Kröll, Alexandra Charlotte Müller, Philipp C. Nett, MD, Reiner Wiest, Johannes Maubach, Guido Stirnimann, Daniel Candinas, and Yves Michael Borbély have no conflict of interest or financial ties to disclose.

References

1. Shiffman ML, Sugerman HJ, Kellum JH, Brewer WH, Moore EW (1993) Gallstones in patients with morbid obesity Relationship to body weight, weight loss and gallbladder bile cholesterol solubility. Int J Obes Relat Metab Disord 17(3):153–158
2. Sugerman HJ, Brewer WH, Shiffman ML, Brolin RE, Fobi MA, Linner JH et al (1995) A multicenter, placebo-controlled, randomized, double-blind, prospective trial of prophylactic ursodiol for the prevention of gallstone formation following gastric-bypass-induced rapid weight loss. Am J Surg 169(1):91–96
3. Banerjee N, Parepally M, Byrne TK, Pullatt RC, Cote GA, Elmunzer BJ (2017) Systematic review of transgastric ERCP in Roux-en-Y gastric bypass patients. Surg Obes Relat Dis 13(7):1236–1242
4. Frederiksen NA, Tveskov L, Helgstrand F, Naver L, Floyd A (2017) Treatment of common bile duct stones in gastric bypass patients with laparoscopic transgastric endoscopic retrograde cholangiopancreatography. Obes Surg 27(6):1409–1413
5. Schreiner MA, Chang L, Gluck M, Irani S, Gan SI, Brandabur JJ et al (2012) Laparoscopy-assisted versus balloon enteroscopy-assisted ERCP in bariatric post-Roux-en-Y gastric bypass patients. Gastrointest Endosc 75(4):748–756
6. Ngamruengphong S, Nieto J, Kunda R, Kumbhari V, Chen YI, Bukhari M et al (2017) Endoscopic ultrasound-guided creation of a transgastric fistula for the management of hepatobiliary disease in patients with Roux-en-Y gastric bypass. Endoscopy 49(6):549–552
7. Kedia P, Sharaiha RZ, Kumta NA, Kahaleh M (2014) Internal EUS-directed transgastric ERCP (EDGE): game over. Gastroenterology 147(3):566–568
8. Kedia P, Tyberg A, Kumta NA, Gaidhane M, Karia K, Sharaiha RZ et al (2015) EUS-directed transgastric ERCP for Roux-en-Y gastric bypass anatomy: a minimally invasive approach. Gastrointest Endosc 82(3):560–565
9. Binmoeller KF, Nguyen-Tang T (2011) Endoscopic ultrasound-guided anterograde cholangiopancreatography. J Hepato-Biliary-Pancreat Sci 18(3):319–331
10. Tyberg A, Nieto J, Salgado S, Weaver K, Kedia P, Sharaiha RZ et al (2017) Endoscopic ultrasound (EUS)-directed transgastric endoscopic retrograde cholangiopancreatography or EUS: mid-term analysis of an emerging procedure. Clin Endosc 50(2):185–190
11. Cotton PB, Eisen GM, Aabakken L, Baron TH, Hutter MM, Jacobson BC et al (2010) A lexicon for endoscopic adverse events: report of an ASGE workshop. Gastrointest Endosc 71(3):446–454
12. Dindo D, Demartines N, Clavien PA (2004) Classification of surgical complications: a new proposal with evaluation in a cohort of 6336 patients and results of a survey. Ann Surg 240(2):205–213
13. Abbas AM, Strong AT, Diehl DL, Brauer BC, Lee IH, Burbridge R et al (2018) Multicenter evaluation of the clinical utility of laparoscopy-assisted ERCP in patients with Roux-en-Y gastric bypass. Gastrointest Endosc 87(4):1031–1039
14. Weilert F, Binmoeller KF, Marson F, Bhat Y, Shah JN (2011) Endoscopic ultrasound-guided anterograde treatment of biliary stones following gastric bypass. Endoscopy 43(12):1105–1108
15. Szary NM, Al-Kawas FH (2013) Complications of endoscopic retrograde cholangiopancreatography: how to avoid and manage them. Gastroenterol Hepatol 9(8):496–504

16. Maubach J, Gruber M, Nett P, Macpherson AJ, Worni M (2018) EUS-guided hepaticojejunostomy with transjejunal per-oral cholangioscopy and electrohydraulic lithotripsy in a patient with complicated choledocholithiasis after Roux-en-Y gastric bypass. VideoGIE 3(11):351–353
17. Raithel M, Dormann H, Naegel A, Boxberger F, Hahn EG, Neurath MF et al (2011) Double-balloon-enteroscopy-based endoscopic retrograde cholangiopancreatography in post-surgical patients. World J Gastroenterol 17(18):2302–2314
18. Moreels TG, Hubens GJ, Ysebaert DK, de Beeck BO, Pelckmans PA (2009) Diagnostic and therapeutic double-balloon enteroscopy after small bowel Roux-en-Y reconstructive surgery. Digestion 80(3):141–147
19. Itoi T, Ishii K, Sofuni A, Itokawa F, Tsuchiya T, Kurihara T et al (2011) Long- and short-type double-balloon enteroscopy-assisted therapeutic ERCP for intact papilla in patients with a Roux-en-Y anastomosis. Surg Endosc 25(3):713–721
20. Shah RJ, Smolkin M, Yen R, Ross A, Kozarek RA, Howell DA et al (2013) A multicenter, U.S. experience of single-balloon, double-balloon, and rotational overtube-assisted enteroscopy ERCP in patients with surgically altered pancreaticobiliary anatomy (with video). Gastrointest Endosc 77(4):593–600
21. Hatanaka H, Yano T, Tamada K (2015) Tips and tricks of double-balloon endoscopic retrograde cholangiopancreatography (with video). J Hepato-biliary-pancreatic Sci 22(6):E28–34
22. Skinner M, Popa D, Neumann H, Wilcox CM, Monkemuller K (2014) ERCP with the overtube-assisted enteroscopy technique: a systematic review. Endoscopy 46(7):560–572
23. Greenstein AJ, O'Rourke RW (2011) Abdominal pain after gastric bypass: suspects and solutions. Am J Surg 201(6):819–827