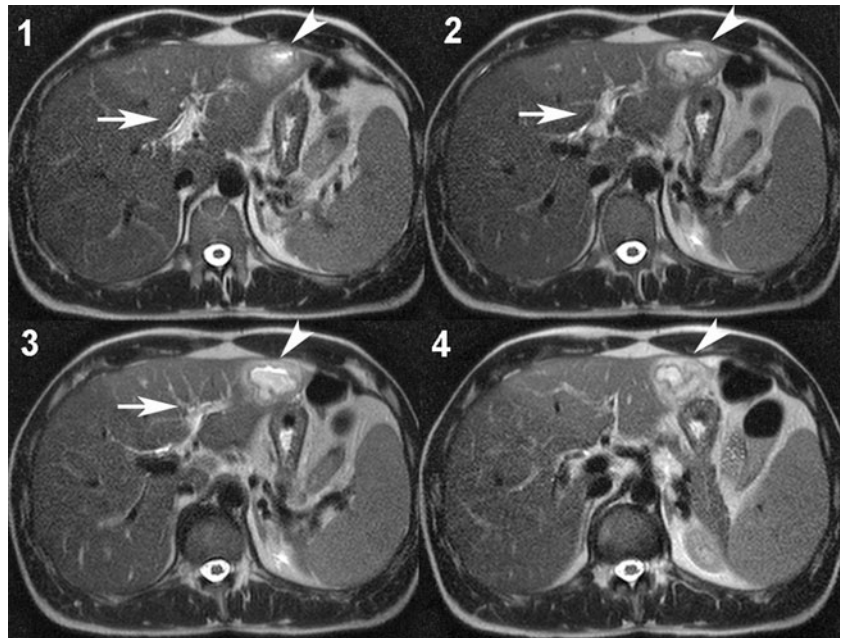


Lemierre's syndrome in the liver

D. Kröll · P. Sendi

Received: 16 November 2011 / Accepted: 30 March 2012 / Published online: 20 April 2012
© Springer-Verlag 2012

Fig. 1 Magnetic resonance imaging (MRI) of the liver with four consecutive T2-weighted images from cranial (1) to caudal (4). The images show a portal vein thrombosis (arrows) and an abscess with multiple septa in the left lobe of the liver (arrowheads)



A 34-year-old physician presented with fever, malaise, and epigastric pain. One month previously, a dental procedure was performed because of a periapical abscess in the lower left molar area. Shortly thereafter, he claimed to have fever and chills for 1 day, but was then symptom-free until 4 days prior to admission. His body temperature was

39.1 °C. Blood test results revealed leukocytosis [19.6 (normal range $3.5\text{--}10.5$) $\times 10^9/\text{L}$] and elevated C-reactive protein [261 (normal <5) mg/L]. Abdominal ultrasound showed a liver abscess. This finding was further elaborated by magnetic resonance imaging, which also demonstrated a portal vein thrombosis (Fig. 1). Blood cultures were obtained and antimicrobial treatment, including ceftriaxone and metronidazole, as well as anticoagulation therapy, were initiated. His clinical condition rapidly improved, and the abscess was drained. However, blood culture and specimen analysis obtained from the liver puncture remained negative. A 16 sRNA gene sequence analysis of the abscess fluid identified *Fusobacterium necrophorum* as the causative pathogen. Antibiotics were streamlined accordingly and anticoagulants continued until radiological

D. Kröll
Department of Visceral Surgery and Medicine, University Clinic for Infectious Diseases, Bern University Hospital and University of Bern, Inselspital PKT2B, 3010 Bern, Switzerland

P. Sendi (✉)
University Clinic for Infectious Diseases, University Hospital and University of Bern, Bern, Switzerland
e-mail: sendi-pa@magnet.ch

resolution of both the abscess and thrombosis. At the clinical follow-up examination 1 year later, the physician was in good health.

Lemierre's syndrome is characterized by distant metastatic abscesses, most frequently in the lungs, after a primary infection of the oropharynx. Therefore, the disease is described as anaerobic 'postanginal' sepsis also. It is generally caused by *F. necrophorum* and commonly found in young adults [1]. In addition, internal jugular venous thrombophlebitis represents a hallmark of the syndrome, but is not always present [2].

In this case, the dental abscess was likely the primary source of infection. We postulate a translocation of *F. necrophorum* from the oral flora, causing a transient anaerobic sepsis. However, thrombophlebitis and metastatic abscess were not found in the internal jugular vein and in the lung, respectively, but, instead, in the liver and portal vein. This observation is in agreement with the described pathogenesis of Lemierre's syndrome [3]. Moreover, Lemierre himself emphasized that septic thrombophlebitis occurs in *F. necrophorum* infection at other sites than the lung also [3, 4].

Invasive interventions in *F. necrophorum* infections are indicated when purulent fluid collections are drainable.

Susceptibility testing to penicillin is important because some strains produce β -lactamases [5]. The use of anticoagulation is controversial, since patients have also recovered without this treatment [1, 2].

Conflict of interest None.

References

1. Chirinos JA, Lichtstein DM, Garcia J, Tamariz LJ. The evolution of Lemierre syndrome: report of 2 cases and review of the literature. *Medicine (Baltimore)*. 2002;81:458–65.
2. Riordan T, Wilson M. Lemierre's syndrome: more than a historical curiosa. *Postgrad Med J*. 2004;80:328–34.
3. Riordan T. Human infection with *Fusobacterium necrophorum* (Necrobacillosis), with a focus on Lemierre's syndrome. *Clin Microbiol Rev*. 2007;20:622–59.
4. Lemierre A, Grégoire R, Laporte A, Couvelaire R. Les aspects chirurgicaux des infections à *Bacillus funduliformis*. *Acad Méd*. 1938;119:352–9.
5. Aldridge KE, Ashcraft D, Cambre K, Pierson CL, Jenkins SG, Rosenblatt JE. Multicenter survey of the changing in vitro antimicrobial susceptibilities of clinical isolates of *Bacteroides fragilis* group, *Prevotella*, *Fusobacterium*, *Porphyromonas*, and *Peptostreptococcus* species. *Antimicrob Agents Chemother*. 2001;45:1238–43.