

Closure of Large Rectal Iatrogenic Perforation by Endoscopic Suture Device: Go for it

Marion Bionda, Johannes Lenglinger, Abedin Haxhija and Reiner Wiest*

Department of Visceral Surgery and Medicine, Bern University Hospital Inselspital, Bern, Switzerland

Received: July 18, 2020; **Accepted:** July 25, 2020; **Published:** July 27, 2020

R-Infotext Citation: Marion B, Johannes L, Abedin H, Reiner W (2020) Closure of Large Rectal Iatrogenic Perforation by Endoscopic Suture Device: Go for it. *J Emerg Med & traum* 01(01): 13–15.

Colorectal perforation induced by anorectal manometry is very rare. 7 cases have been published in four reports (5 males, 2 females, age 63 – 78 years) [1–4]. Park et al. calculated an incidence of 0.13% for colorectal perforation during anorectal manometry [4]. Therapeutic measures to manage such complications are not standardized [5] but include conservative approach with antibiotics without intervention, surgical closure or endoscopic maneuvers such as clipping or suturing utilizing corresponding devices. Here we report the case of 86 year old patient that suffered a large middle rectal perforation during an anorectal manometry.

Novel endoscopic techniques are supplanting traditional surgical procedures for several conditions. The OverStitch (Apollo Endosurgery, Austin, Tex) (Figure 1) is an endoscopic suturing device enabling full thickness tissue apposition [6]. The device is attached to a double-channel endoscope consisting of a curved needle driver with the ability to release and recapture the needle. By that full-thickness stitches can be placed in a variety of suture patterns. After suture placement, the needle is released and does serve as tissue anchor.

Utilizing the Apollo OverStitch-system we immediately after detecting the perforation post-manometry did close the large perforation (Figure 2). Under analgesedation in a 40 minute intervention we could endoscopic suture

the perforation (Figure 2). Technically the device was introduced with over tube; sutures were placed without helix but adaption of tissue by forceps. A total of four individual stitches were carried out, the final placement being a figure of eight.

Rectal perforation by anal manometry is a rare event. Five of the affected patients reported in the literature had previously undergone rectal resection for rectal cancer. Grade III hemorrhoids and mucosal prolapse were found in one individual. No colorectal disease except stool incontinence was present in one female patient. Here, the patient has had mucosectomy for rectal mucosal prolapse years earlier that might have caused scarring as underlying risk factor. The treatment options are divers but we do think that immediate endoscopic closure seems to be a favorable approach. Endoscopic suturing enables repair without need for utilizing an operating theatre or general anesthesia and is readily available at least in specialized tertiary centers. In fact, the same technique has been applied before for colonic perforations [7] showing even favorable results as compared to clipping.

The patient has been asymptomatic ever since. In the clinical visit 4 days after the procedure we could palpate the suture which did heal without problems. Bowel movements were painless and outcome for the patient fine.

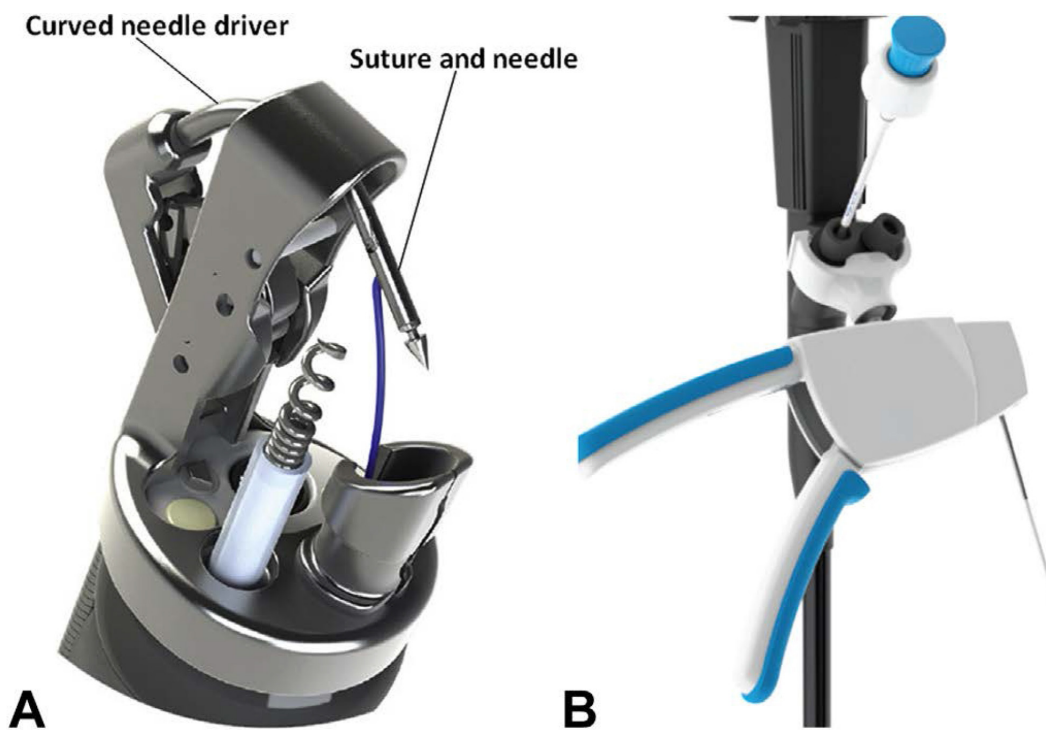


Figure 1: A, Apollo OverStitch needle and tissue helix. B, Device control handle (modified from Abu Dayyeh et al [8]).

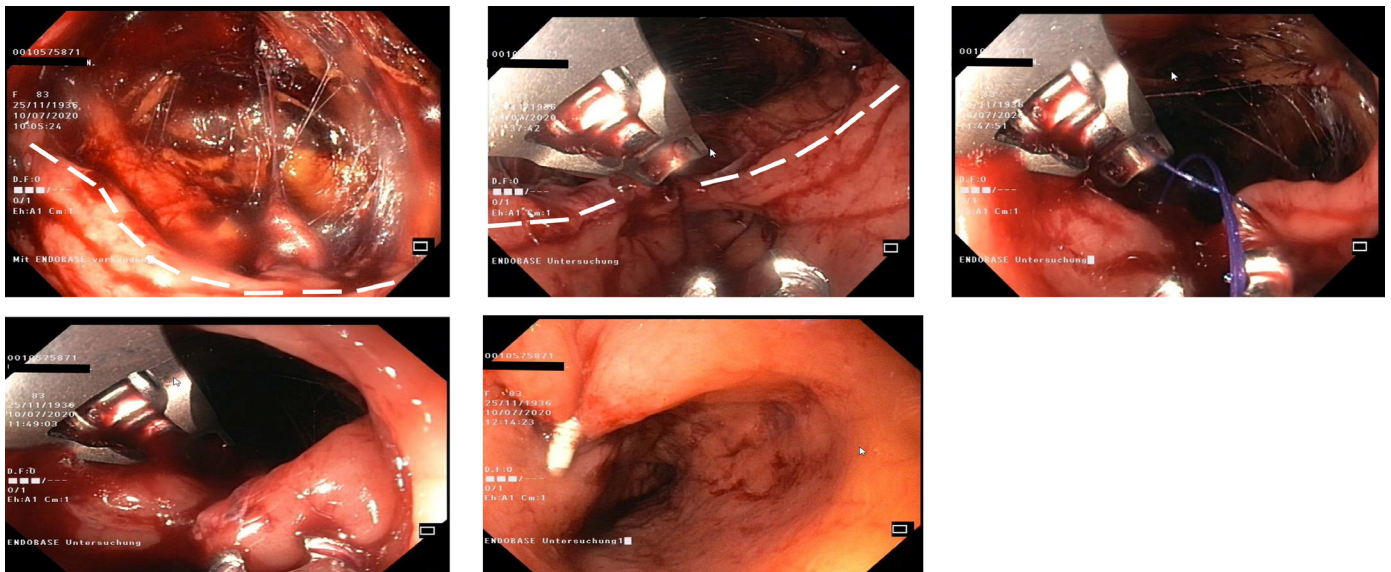


Figure 2: A, large rectal perforation with dashed line indicating rim of intact mucosa; B, Suture device on-site having placed first stitch adapting the two rims defining the perforation site (left and right dashed lines); C, suture lines during maneuver; D, after three stitches almost and E, after last suture full closure of defect.

References

1. Cho YB, Lee WY, Yun HR, Lee WS, Yun SH, Chun HK (2008) Colonic perforation caused by anorectal manometry. *International journal of colorectal disease* 23: 219–20. [View]
2. Núñez Otero JA, Gómez Rubio M, Durán Aguado Á R, Martínez Albares JL (2013) Rectal perforation after anorectal manometry without prior known rectal disease: an exceptional complication resolved with medical treatment. *Gastroenterología y hepatología* 36: 577–9. [View]
3. Lee KH, Kim JY, Sul YH (2017) Colorectal Perforation after Anorectal Manometry for Low Anterior Resection Syndrome. *Annals of coloproctology* 33: 146–9. [View]
4. Park JS, Kang SB, Kim DW, Kim NY, Lee KH, Kim YH (2007) Iatrogenic colorectal perforation induced by anorectal manometry: report of two cases after restorative

- proctectomy for distal rectal cancer. *World journal of gastroenterology* 13: 6112–4. [[View](#)]
5. Di Venere B, Testini M, Miniello S, et al. (2002) Rectal perforations. Personal experience and literature review. *Minerva chirurgica* 57: 357–62. [[View](#)]
 6. Kantsevov SV (2020) the Development of the Overstitch System and Its Potentials. *Gastrointestinal endoscopy clinics of North America* 30: 107–14. [[View](#)]
 7. Kantsevov SV, Bitner M, Hajiyeva G, et al. (2016) Endoscopic management of colonic perforations: clips versus suturing closure (with videos). *Gastrointestinal endoscopy* 84: 487–93. [[View](#)]
 8. Abu Dayyeh BK, Rajan E, Gostout CJ (2013) Endoscopic sleeve gastropasty: a potential endoscopic alternative to surgical sleeve gastrectomy for treatment of obesity. *Gastrointestinal endoscopy* 78: 530–5. [[View](#)]

***Corresponding author:** Reiner Wiest, MD, Department Visceral Surgery and Medicine, Bern University Hospital Inselspital, Inselspital, Bern 3010, Switzerland;

Fax: +41-31-6325900;

Email: reiner.wiest@insel.ch