

# Checking the integrity of eyes in prone position: A novel application of video laryngoscopes

SAGE Open Medical Case Reports  
Volume 9: 1–4  
© The Author(s) 2021  
Article reuse guidelines:  
sagepub.com/journals-permissions  
DOI: 10.1177/2050313X211015885  
journals.sagepub.com/home/sco



Daniel Gerber<sup>id</sup>, Balthasar Eberle and Gabor Erdoes

## Abstract

Perioperative visual loss is a rare but severe complication after surgery in prone position. One of several mechanisms is direct ophthalmic compression. This can be avoided through optimal positioning and padding of the head, but position and integrity of the eyes need to be checked at regular intervals. We describe the use of a conventional video laryngoscope during vascular surgery in prone position as a simple solution for intermittent monitoring of external integrity of the eyes and size of the pupils. This requires no additional material and allows documentation of the findings. Our method might reduce complications and improve patient outcome.

## Keywords

Video laryngoscopy, prone position, perioperative visual loss, ophthalmic compression

Date received: 6 January 2021; accepted: 19 April 2021

## Introduction

Postoperative visual loss (POVL) after non-ocular surgery is a rare but severe complication. In a study of more than 400,000 patients, the estimated risk of prolonged POVL was 0.0008%, and prone position was not an independent risk factor for visual loss.<sup>1</sup> A 10-year study of the prevalence of perioperative visual loss by Shen et al.<sup>2</sup> reported an overall incidence of 2.35 per 10,000 cases, with higher odds ratio (OR) in spinal fusion (OR 19.1) and cardiac surgery (OR 12.7). Some authors conclude on a risk ranging from 0.013% to 1% with the most frequently quoted risk of 0.2%.<sup>3,4</sup> In addition to patient positioning, possible risk factors included male sex, longer duration of anesthesia, Wilson frame use, greater blood loss, obesity, and lower incidence of colloid administration.<sup>5</sup>

Several mechanisms may cause ophthalmic injury. The most obvious is retinal ischemia, which can be further divided into ischemic optic neuropathy (ION), central retinal artery occlusion (CRAO), and branch retinal artery occlusion (BRAO). ION results from inadequate perfusion pressure, and may occur bilaterally. Individual susceptibility varies with preexisting comorbidities, such as arterial hypertension, anatomical variation in arterial supply, and vascular disease. Perfusion pressure for the optic nerve is calculated as mean arterial pressure minus intraocular pressure or orbital venous pressure, whichever is greater. Arterial

hypotension (e.g. from decreased cardiac output in prone position), and increased venous (e.g. due to abdominal compression) or intraocular pressure (e.g. from external compression or orbital edema) can jeopardize blood supply to the optical nerve. This leads to inadequate oxygenation and ischemic axonal damage. Mechanisms leading to BRAO and CRAO in the perioperative period are vasospasm, emboli, nerve compression, and systemic hypotension with either regional or global effects on the eyes. According to Roth and Moss,<sup>6</sup> the prognosis for ION is poor and no effective treatment exists, complicated also by the fact that diagnosis is most often made several hours after the initiating event.

The above mechanisms for ophthalmic injury thus call for consequent use of preventive measures. Evidence supporting such measures is generally limited to expert opinion, retrospective observational studies, and case reports. Optimal positioning and safeguarding of head and eyes need to be confirmed regularly while the patient is in prone position, since head position may inadvertently change under muscle

Department of Anaesthesiology and Pain Medicine, Inselspital, Bern University Hospital, University of Bern, Bern, Switzerland

### Corresponding Author:

Daniel Gerber, Department of Anaesthesiology and Pain Medicine, Inselspital, Bern University Hospital, University of Bern, 3010 Bern, Switzerland.

Email: daniel.gerber@insel.ch



Creative Commons Non Commercial CC BY-NC: This article is distributed under the terms of the Creative Commons Attribution-NonCommercial 4.0 License (<https://creativecommons.org/licenses/by-nc/4.0/>) which permits non-commercial use, reproduction and distribution of the work without further permission provided the original work is attributed as specified on the SAGE and Open Access pages (<https://us.sagepub.com/en-us/nam/open-access-at-sage>).

relaxation or with tilting of the operating table and surgical manipulation.

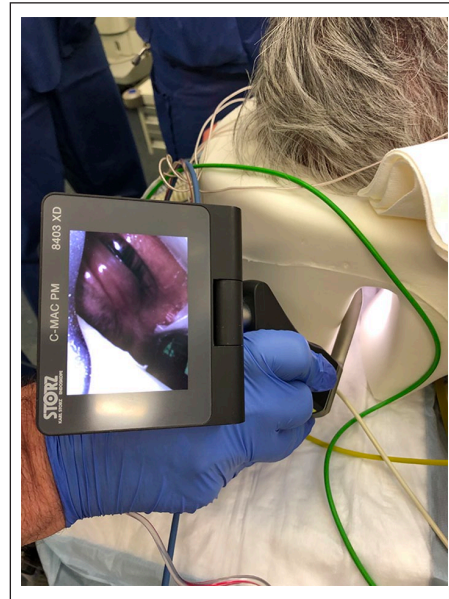
While direct visual eye inspection of the prone patient can be cumbersome, continuous visual monitoring can be performed with a mirror attached to the headrest. This however requires additional equipment and limits the field of view. Such limitations even motivated other clinicians to build a camera and laptop-based video streaming system to provide assistance.<sup>7</sup>

We obtained written informed consent of our patient for the publication of this case report. The manuscript was prepared according to the CARE statement checklist (<http://www.care-statement.org/>).

## Case description

We present the case of a patient in whom a customary video laryngoscope was used (off label) to evaluate the eyes and the correct positioning of the periorbital padding. This 51-year-old male patient was to undergo, in prone position, resection of a partially thrombosed popliteal aneurysm and replacement with a brachial venous interponate. Relevant comorbidities were arterial hypertension, coronary heart disease with previous coronary artery bypass surgery, and obesity with a body mass index of 36.

General anesthesia was induced with propofol (fractionated application of 170 mg) and 200 mcg fentanyl. Rocuronium (100 mg) was administered to facilitate intubation, which was uneventfully performed using standard handheld video laryngoscope (C-MAC®, Karl Storz, Tuttlingen, Germany) with a Macintosh blade size 4. Anesthesia was maintained with 1.4–2.1 vol.% sevoflurane, and ventilation with a tidal volume of 6–8 mL/kg of ideal body weight as well as a rate adapted to keep end tidal carbon dioxide (CO<sub>2</sub>) concentration between 35 and 40 mmHg. The eyes were protected by transparent ointment (Viscotears®, Bausch & Lomb Swiss, Zug, Switzerland) after intubation. The venous graft was harvested in supine position, and the patient was turned into prone position thereafter. The eyes were taped closed with a transparent dressing according to hospital standard. A soft foam rest was put in place for positioning of the head. After manual disinfection, the video laryngoscope used for intubation was used to check the position of the head and eyes on the foam rest. This is an off-label use of the video laryngoscope and the images were obtained without physical contact of the video laryngoscope to the patient. The video laryngoscope not only served as a light source but also allowed excellent visualization of the eye and periorbital region on screen. We were careful to ensure absence of external compression and periorbital edema and controlled adequate closure of the eyes under the transparent dressing on each eye check. With permission of the patient, we present an exemplary image in Figure 1. During the subsequent 3.5 h, eye and position checks were performed on a regular basis (20–30 min in our practice). Vital parameters were kept within 15% of the baseline with norepinephrine



**Figure 1.** View of the patient's left eye via the video laryngoscope (C-MAC®, Karl Storz, Tuttlingen, Germany, Macintosh blade size 4). The eye is taped over with a transparent dressing. Reproduced with permission of the patient.

infusion with a maximal infusion rate of 0.026 mcg/kg/min. Central venous pressure was monitored and kept between 8 and 15 mmHg with fluids and positioning of the operating table. The further course of the operation was uneventful with 6 h 18 min anesthesia duration, of which 3 h 50 min in prone position. Prior to extubation, the transparent dressing was removed, and the ointment used does not require flushing. The patient reported no signs or symptoms of eye injury or visual impairment after the procedure.

## Discussion

There are several ways to check integrity of the eyes during and after positioning the face into a headrest in prone position, such as by visual control underneath surgical tables with cutouts, by using mirrors, or just by manual palpation of the eyes and orbit. The ASA Practice Advisory for Perioperative Visual Loss associated with Spine Surgery 2019<sup>8</sup> recommends periodic checks of the eyes but does not specify the frequency, largely due to insufficient data from the literature. Roth<sup>9</sup> recommend monitoring the eyes every 20 min on the basis of rodent models of elevated IOP. Chui and Craen<sup>10</sup> in their update on prone positioning recommend checks every 30 min without clear evidence. The French Society for Anesthesia and Intensive Care (SFAR) states in her expert opinion that “It is probably recommended that absence of any extrinsic compression of the eyeball during the procedure be checked.”<sup>11</sup> In our case, the video laryngoscope proved to be a simple but effective (and efficient) tool for checking proper guarding of the patient's eyes directly

after a change to prone position as well as during regular checks thereafter. In connection with a digital patient information system, the resulting images might even be stored for medico-legal documentation.

In our evaluation, the view we had of the periorbital region using video laryngoscopy was superior to any method used previously. Implementation was simple and fast, since no additional material or equipment was needed, as we used the handheld video device and the same Macintosh blade size 4 used for intubation. In case of small headrests, one might even consider switching to a pediatric blade, for example, Miller blade size 0. Application of this technique is clearly limited by the availability of video laryngoscopes, but recent publications have documented their increasing availability and use in various parts of the world.<sup>12,13</sup> In view of the potential tight space conditions in prone cases, handheld devices might be an advantage compared to monitors mounted on separate stands. Of course, optimal monitoring of the eyes including pupil size and reactivity, scleral injection, and conjunctival swelling, is hardly compatible with optimal eye protection, for example, against corneal abrasion, since most guidelines recommend taping the eyes closed and applying a lubricant especially if the patient is placed in prone position. Due to the relatively higher risk of corneal abrasion compared to POVL, we decided to tape our patient's lubricated eyes closed with a transparent dressing, which did not allow to monitor the eyeball and pupils itself.

Optimal positioning of the patient on the headrest is an important factor, but by far not the only one in prevention of POVL. Most of the following recommendations are based on case reports and expert opinion.<sup>8–11</sup> Authors agree on the benefit of avoiding hypotension, and suggest invasive blood pressure monitoring especially in high-risk cases. There is no agreement on a transfusion threshold, but periodic monitoring of hematocrit is suggested. The head should be placed in a neutral position and direct pressure to the eyes is to be avoided. If feasible, a slight reverse Trendelenburg position (head level above heart) is endorsed by all authors. Staging of long surgical procedures is a possible strategy mentioned in three of four guidelines. Measures not covered in current guidelines are carotid Doppler ultrasonography monitoring and maintenance of a physiologic arterial CO<sub>2</sub> level. The influence of CO<sub>2</sub> on retinal perfusion is well known.<sup>14</sup> We propose to keep arterial CO<sub>2</sub> in the normal to mild hypercapnic range to optimize retinal perfusion. The role of intraoperative carotid Doppler ultrasonography in prone position has yet to be determined, while the use of transcranial Doppler ultrasonography in many cases gets into conflict with padding and positioning the head.

## Conclusion

Given the heterogeneous etiology and generally low incidence of perioperative visual injury, we do not suggest that

any such simple aid for monitoring eye protection in prone position will ever be proven to reduce event rate significantly. Nevertheless, we believe that after careful prone positioning, videoscopic control and documentation at regular intervals improve visualization of the periorbital region. This is a simple and efficient means to prevent or rule out inadvertent extraneous damage to the eyes, as one potential contributor to the catastrophic experience of POVL.

## Acknowledgements

The authors would like to thank Jeannie Wurz (BA), Medical Writer at the Department of Anaesthesiology and Pain Medicine, Inselspital, Bern University Hospital, University of Bern, Bern, Switzerland, for reviewing a previous draft of the manuscript.

## Declaration of conflicting interests

The author(s) declared no potential conflicts of interest with respect to the research, authorship, and/or publication of this article.

## Funding

The author(s) received no financial support for the research, authorship, and/or publication of this article.

## Ethical approval

Our institution does not require ethical approval for reporting individual cases or case series.

## Informed consent

Written informed consent was obtained from the patient for their anonymized information to be published in this article.

## ORCID iD

Daniel Gerber  <https://orcid.org/0000-0001-6267-2409>

## References

1. Warner ME, Warner MA, Garrity JA, et al. The frequency of perioperative vision loss. *Anesth Analg* 2001; 93(6): 1417–1421.
2. Shen Y, Drum M and Roth S. The prevalence of perioperative visual loss in the United States: a 10-year study from 1996 to 2005 of spinal, orthopedic, cardiac, and general surgery. *Anesth Analg* 2009; 109(5): 1534–1545
3. Epstein NE. Perioperative visual loss following prone spinal surgery: a review. *Surg Neurol Int* 2016; 7(Suppl. 13): S347–S360.
4. Epstein NE. How to avoid perioperative visual loss following prone spinal surgery. *Surg Neurol Int* 2016; 7(Suppl. 13): S328–S330.
5. Postoperative Visual Loss Study Group. Risk factors associated with ischemic optic neuropathy after spinal fusion surgery. *Anesthesiology* 2012; 116(1): 15–24.
6. Roth S and Moss HE. Update on perioperative ischemic optic neuropathy associated with non-ophthalmic surgery. *Front Neurol* 2018; 9: 557.

7. Woodruff C, English M, Zaouter C, et al. Postoperative visual loss after plastic surgery: case report and a novel continuous real-time video monitoring system for the eyes during prone surgery. *Br J Anaesth* 2011; 106(1): 149–151.
8. Practice Advisory for Perioperative Visual Loss Associated with Spine Surgery. 2019: an updated report by the American Society of anesthesiologists task force on perioperative visual loss, the North American Neuro-Ophthalmology Society, and the Society for Neuroscience in Anesthesiology and Critical Care. *Anesthesiology* 2019; 130(1): 12–30.
9. Roth S. Perioperative visual loss: what do we know, what can we do. *Br J Anaesth* 2009; 103(Suppl. 1): i31–40.
10. Chui J and Craen RA. An update on the prone position: continuing professional development. *Can J Anaesth* 2016; 63(6): 737–767.
11. French Society for Anaesthesia and Intensive Care (SFAR); French Ophthalmology Society (SFO) French-speaking Intensive Care Society (SRLF); Keita H, et al. Eye protection in anaesthesia and intensive care. *Anaesth Crit Care Pain Med* 2017; 36(6): 411–418.
12. Gill RL, Jeffrey AS, McNarry AF, et al. The availability of advanced airway equipment and experience with videolaryngoscopy in the UK: two UK surveys. *Anesthesiol Res Pract* 2015; 2015: 152014.
13. Nagy B and Rendeki S. A national survey of videolaryngoscopes and alternative intubation devices in Hungary. *PLoS ONE* 2019; 14(10): e0223645.
14. Harris A, Arend O, Wolf S, et al. CO<sub>2</sub> dependence of retinal arterial and capillary blood velocity. *Acta Ophthalmol Scand* 1995; 73(5): 421–424.