REVIEW ARTICLE

JOURNAL OF PANCREATOLOGY®

OPEN

# A narrative review on endopancreatic interventions: an innovative access to the pancreas

Michael C. Frey[a], Benjamin Eigl[b], Daniel C. Steinemann[c], Thilo Hackert[d], Fabian Rössler[e], Felix Nickel[d], Beat P. Müller-Stich[d], Kaspar Z'graggen[f], Philip C. Müller[e,f,*]

**Abstract**

The natural connection between the duodenum and the pancreatic duct enables a minimally invasive access to the pancreas. Endoscopically this access is already regularly used, mainly for diagnostic and even for certain therapeutic purposes. With per-oral pancreatoscopy the endopancreatic approach allows the direct visualization of the pancreatic duct system potentially improving the diagnostic work-up of pancreatic cystic neoplasms, intrapancreatic strictures and removal of pancreatic duct stones. However, the endopancreatic access can equally be applied for surgical interventions. The objective of this review is to summarize endoscopic and surgical interventions using the endopancreatic access. Endopancreatic surgery stands for a further development of the endoscopic technique: a rigid endoscope is transabdominally introduced over the duodenum and the papilla to enable resections of strictures and inflamed tissue from inside the pancreas under visual control. While the orientation and localization of target structures using this minimally invasive approach is difficult, the development of an accurate image guidance system will play a key role for the clinical implementation and widespread use of endoscopic and surgical endopancreatic interventions.

**Keywords:** Computer-assisted surgery, Endopancreatic surgery, Image-guided surgery, Minimally invasive pancreatic surgery, Pancreatic surgery

Downloaded from http://journals.lww.com/pancreatology by BhDMf5ePHKav1zEoum1tQfN4a+kJLhEZgbsIHo4XMi0hCywCX1AWnYQp/IlQrHD3i3D0OdRyi7TvSFl4Cf3VC1y0abggQZXdgGj2MwlZLeI= on 07/14/2021

source: https://doi.org/10.48350/157269 | downloaded: 12.10.2024

## Introduction

Visualization of the pancreaticobiliary system is challenging and evaluation mainly relies on radiographic techniques such as computed tomography (CT), magnetic resonance imaging (MRI) and endoscopic ultrasound (EUS). However, the natural connection between the duodenum and the pancreatic duct enables both diagnostic and therapeutic interventions. Foremost, endoscopic retrograde cholangiopancreatography uses this connection for diagnostic and therapeutic options. For example, endoscopic retrograde cholangiopancreatography enables pancreatic duct stone extraction and has a success rate of around 50%.[1–5] Potential improvement could be brought through direct visualization of the pancreatic duct with subsequent intervention through the duct, as made possible by per-oral pancreatoscopy (POP). POP was first described in 1976 by Kawai et al.[6] It is clinical implementation was initially limited by several problems such as the need for two endoscopists, the fragility of the instruments and poor image quality. In 2007 a single operator, fiberoptic scope system was introduced, which enabled execution of the procedure by a single endoscopist but still had the limitation of poor image quality and instability.[7,8] In 2015 a digital cholangio-pancreatoscope overcoming these issues was introduced (SpyGlass DS, Boston Scientific).[9] POP is useful for the visualization and histological diagnosis of intraductal papillary mucinous neoplasms (IPMN). Furthermore, POP can be helpful in the challenging differentiation between benign and malignant pancreatic duct strictures. POP enables direct interventions, such as the removal of pancreatic duct stones by pancreatoscopy guided lithotripsy.[10] Recently, more advanced intraductal techniques have gained interest, for example, in the form of intraductal radiofrequency ablation (RFA).[11] The natural connection between duodenum and pancreatic duct was furthermore evaluated as a minimally invasive surgical access to the pancreas, the so called endopancreatic surgery (EPS).[12–15] This technique is using a rigid endoscope enabling stable access and the use of rigid resection instruments.[12] Endopancreatic procedures—either performed via per-oral flexible endoscope or surgically with rigid instruments present a fascinating and quickly evolving field, therefore, we aimed to present an up-to date review of recent developments and outcomes using the endopancreatic access.

[a] Department of Surgery, Kantonsspital Baden, Baden, [b] CAScination AG, Bern, [c] Department of Surgery, Clarunis University Hospital Basel, Basel, Switzerland, [d] Department of General, Visceral and Transplantation Surgery, University Hospital Heidelberg, Heidelberg, Germany, [e] Department of Visceral and Transplant Surgery, University Hospital Zurich, Zurich, [f] Department of Surgery, Hirslanden Klinik Beau-Site, Bern, Switzerland

[*] Corresponding author: Philip C. Müller, MD, Department of Visceral and Transplant Surgery, University Hospital Zurich, Rämistrasse 100, 8091 Zurich; Department of Surgery, Hirslanden Klinik Beau-Site, Bern, Switzerland. E-mail: philip.mueller@hotmail.com

Copyright © 2021 The Chinese Medical Association, Published by Wolters Kluwer Health, Inc. under the CCBY-NC-ND license.
This is an open access article distributed under the terms of the Creative Commons Attribution-Non Commercial-No Derivatives License 4.0 (CCBY-NC-ND), where it is permissible to download and share the work provided it is properly cited. The work cannot be changed in any way or used commercially without permission from the journal.

Journal of Pancreatology (2021) 4:2

Published online 15 June 2021

http://dx.doi.org/10.1097/JP9.0000000000000069

## Database search strategy

We searched PubMed to find articles on endopancreatic interventions that were published between 2000 and 2021.

## Endoscopic interventions

### POP

POP has the advantage of direct visibility of the pancreatic duct system with the possibility to perform diagnostic and therapeutic

interventions. Technical progress resolved initial issues of the technique like poor image resolution and complicated and fragile handling. Compared to endoscopic retrograde cholangiopancreatography, POP offers advanced endoscopic treatment options for pancreatolithiasis with the combination of endoscopy and lithotripsy in one device. Through the POP working channel it is possible to perform intraductal laser lithotripsy. A success rate between 38% and 100%[16] has been shown for POP lithotripsy compared to 59% to 76% with extracorporeal shock wave lithotripsy.[17] Attwell et al used dual operator-based (n=31) and single operator-based (n=15) pancreatoscopes. Complete clearance was achieved in 68% for dual operator-based POP and 73% for single operator-based POP. Clinical success was defined as >50% reduction in opiate use, pain or hospitalization and was achieved in 74%. Of note, 10% had POP-related complications.[18] In general POP-guided laser lithotripsy leads to a pancreatic duct clearance between 79% and 85%.[19,20] Moreover, POP adds valuable diagnostic information, especially in the challenging diagnostic of mucin-producing tumors of the pancreas (MPTP). Particularly main duct IPMN have an increased risk for malignant transformation[21] and the differentiation between low and high risk IPMN remains challenging.[22] According to the POP visualization the cystic lesions can be divided into 5 groups (Fig. 1) according to the different potential of malignant transformation.[23] In groups 3 to 5, where over 89% of the cystic lesions were malignant, POP had a sensitivity of 68% and a specificity of 87% detecting malignancy. When using POP additional diagnostic information affecting clinical decision-making was found in 76% of the patients by Arnelo et al. The sensitivity was 84% and the specificity 75% for identifying malignant lesions.[24] With three passes of either POP-guided biopsy, POP-assisted fluoroscopic-guided biopsy or POP-guided brushing, El Hajj et al reached high sensitivity and specificity for the detection of pancreatic duct neoplasia (PDAC or main duct IPMN). In a cohort of 33 patients the diagnosis was confirmed in 88% of the cases with POP-guided tissue sampling. The sensitivity and specificity of the visual diagnosis with POP was 87% and 86%, compared to 91% and 95% for POP with tissue sampling.[25] To visualize lesions in distant branches a very useful addition to POP is intraductal ultrasound (IDUS). Mukai et al found that the sensitivity for detecting lesions ≥3 mm was significantly higher for IDUS (100%) compared to other diagnostic modalities (CT 21%, EUS 86%, POP 83%).[26] Adding IDUS to POP is especially beneficial in the evaluation of branch duct lesions, where the accuracy of differentiating benign and malignant lesions increased from 67% with POP alone to 88% for POP with IDUS.[23] Preoperative POP adds valuable information for preoperative surgical planning. According to Tyberg et al preoperative POP changed the surgical plan in 62%, with a very high correlation (88%) between POP and final histology.[27] If used intraoperatively POP can be of use to detect lesions which were missed in the preoperative work-up. In a prospective study Kaneko et al found intraductal MPTP in ten out of 24 patients which were missed by preoperative imaging and EUS. The sensitivity, specificity and accuracy of intraoperative POP for diagnosis of MPTP was 100%.[28] POP adds valuable information for the evaluation of cystic lesions of the pancreas and may as well be beneficial in the assessment of pancreatic duct strictures, especially in patients with chronic pancreatitis (CP).

### *Intraductal ablation*

Intraductal RFA is mainly applied in the biliary duct system for the palliative management of malignant biliary strictures, in case of stent occlusion or for the treatment of ampullary neoplasms.[11] Overall, RFA applied in the biliary system showed promising results regarding stent patency and survival.[29–33] Due to the sensitive nature of the pancreas parenchyma and the delicate surrounding structures thermal ablation is only applied in highly selected cases, mainly in patients who are unfit for surgery. More recently EUS-guided RFA of pancreatic tumors has gained interest.[34,35] Since this approach does not use the natural connection between the duodenum and pancreas, EUS-guided RFA is outside the scope of this review. Nevertheless, studies which assessed efficacy and safety of RFA for the treatment of residual intraductal lesions after endoscopic papillectomy have been conducted.[36] Camus et al found a 70% chance for dysplasia eradication at 12 months after a single session of intraductal RFA in patients which had residual neoplasia after papillectomy.[37] Rustagi et al found a treatment success of 92% for patients with intraductal extension (common bile duct or pancreatic duct) of ampullary neoplasms treated with RFA. However, adverse events are common and occurred in 43%, especially mild pancreatitis or ductal strictures.[38] Although these smaller studies showed the feasibility of intraductal RFA, future studies have to clarify the actual benefit of this treatment. Furthermore, the RFA devices are still undergoing a technical development. Choi et al addressed the problem of adverse events caused by heat with a temperature-controlled probe. The study population was small, with 10 patients, but the treatment was successful in 90% of the cases, with adverse events in 30%.[36]

| Histopathological diagnosis | Type 1 | Type 2 | Type 3 | Type 4 | Type 5 |
|---|---|---|---|---|---|
| Hyperplasia | 3 | 0 | 0 | 0 | 0 |
| Adenoma | 0 | 6 | 2 | 1 | 1 |
| CIS | 0 | 0 | 7 | 3 | 5 |
| Invasive carcinoma | 0 | 0 | 9 | 9 | 5 |
| % malignant lesions | 0 | 0 | 89 | 96 | 91 |

**Figure 1.** Distribution of 51 protruding lesions by histopathological diagnosis and POPS (adapted with permission from Hara et al[23]). The cystic lesions are divided into 5 types according to the POPS visualization. CIS=carcinoma in-situ, POPS=per-oral pancreatoscopy.

Intraductal RFA was furthermore applied for the treatment of IPMN in an 82-year-old man who was unfit for surgery. The treatment with RFA was successful and there were no signs of residual disease after 3 months follow-up.[39] Adverse events after RFA are still common,[40] besides the thermal damage, the challenging navigation could be another key point to reduce adverse events. The advancement of computer assisted image-guided interventions or direct visualization of POP will facilitate the targeting of intraparenchymal lesions. Interestingly, RFA recently attracted interest for pancreatic stump closure after surgery.[41,42] In a porcine model intraductal sealing of the pancreatic duct was feasible in all animals without complications (Fig. 2). After 30 days, successful occlusion of the pancreatic duct was confirmed in all cases.[42] Although only applied in very selected indications, intraductal RFA has shown potential in treatment of residual ampullary adenomas, sealing of the pancreatic duct and might even be applied in highly selected patients with IPMN unfit or unwilling to undergo surgery. However, studies comparing intraductal RFA to current standard treatment are required to reassure the benefit of this technique.

## Surgical interventions

### *Endopancreatic surgery*

EPS stands for a newly developed minimally invasive surgical technique. The concept is similar to the transurethral resection of the prostate. After laparoscopic access to the duodenum and the papilla, diagnostic and therapeutic procedures (especially resections) can be performed from inside the pancreatic duct with a rigid endoscope under visual control (Fig. 3). The use of rigid instruments compared to a flexible endoscope in this sensitive organ brings several advantages like stability when performing interventions, the option for various treatments through the working channel and potentially a shorter learning-curve.[43] As previously mentioned, endoscopic treatment in CP has limitations, as it is impossible to resect the inflamed pancreatic tissue, which is responsible for the progression of the disease. While the surgical treatment has been shown to be more effective,[44,45] the duodenum-preserving pancreatic head resection and other procedures are associated with relevant morbidity.[46] Minimally invasive procedures such as EPS could potentially lower the morbidity while a resection of inflamed tissue is possible from inside the organ.[47] First animal experiments showed promising results and the feasibility of a similar resection with EPS as with a duodenum-preserving pancreatic head resection (Fig. 4).[12] The resected area accounted for 30% of the total pancreatic surface with a resected volume of 14.2 $cm^3$. Furthermore, the often-present pancreatic duct stenosis can be resected by EPS as well, as shown in a bovine pancreas model with artificial pancreatic duct strictures. In 8 specimens all stenoses could be resected and the stenotic area could then be passed with the 2.7 mm rigid endoscope. There were no complications, especially no organ perforations. EPS is performed with a rigid endoscope and a single working channel, therefore this technique needs effective instruments for the resection and especially for hemostasis. Both a conventional monopolar electrosurgical device (MES) and a green light laser (GLL) have been evaluated for EPS. Standardized resections were performed in an in vivo porcine model (Supplementary Table 1, http://links.lww.com/JP9/A9). Blood loss was less pronounced with GLL than with MES [1.7 (0.6–2.6) mL vs 5.1 (3.8–13.2) mL; $P < .01$], while there was no uncontrollable bleeding with either technique. GLL also showed a shorter median procedure time than MES [109 (81–127) seconds vs 390 (337–555) seconds; $P < .01$]. However in the histopathological workup, GLL was associated with more pronounced heat-damage than MES

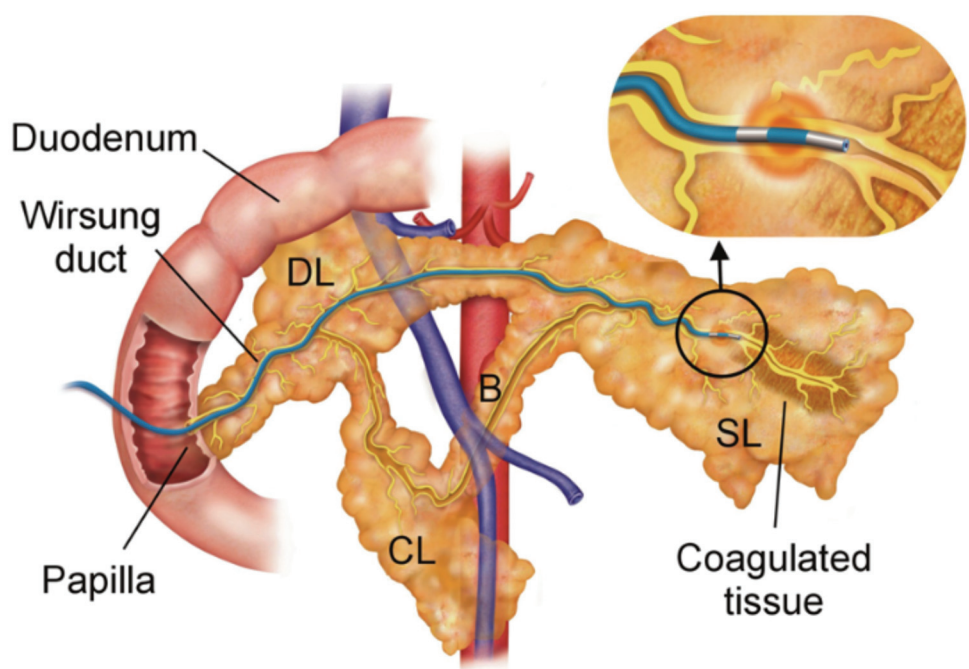


**Figure 2.** In a porcine experiment the radiofrequency probe was inserted transpapillary and used to prevent leakage of the pancreatic duct (adapted with permission from Andaluz et al[41]). B = bridge, CL = connecting lobe, DL = duodenal lobe, SL = splenic lobe.

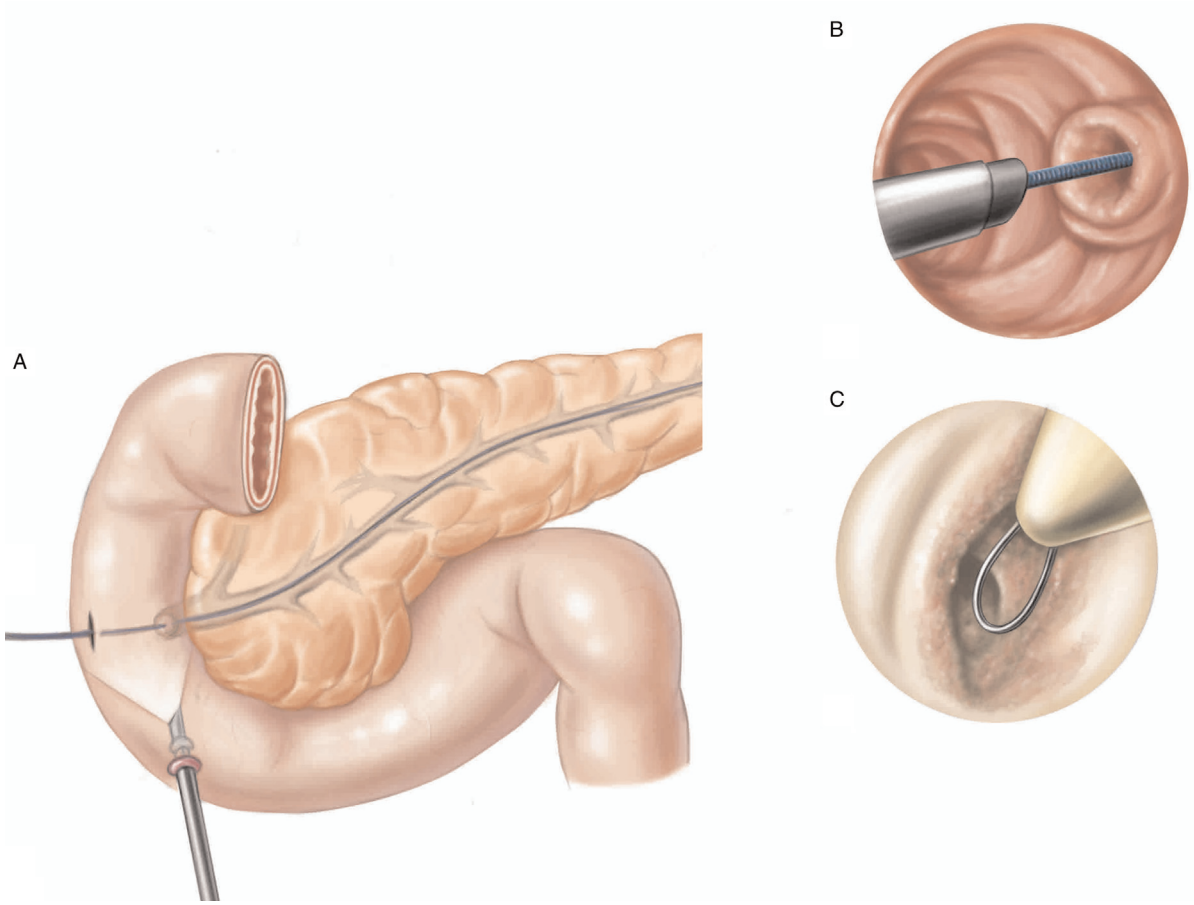


**Figure 3.** Transduodenal endopancreatic resection with a rigid endoscope. (A) A duodenotomy is made opposite to the papilla. (B) The endoscope is advanced over the papilla into the pancreatic duct. (C) Resection is performed from inside the duct.

[4.12 mm (3.48–4.89) vs 1.33 mm (1.09–1.48); $P<.01$],[13] which could potentially lead to fatal complications in the postoperative course, such as postoperative pancreatitis or organ perforations. However, the study was limited to an in-vivo experiment without survival of the animals. One of the main limitations of resections performed by EPS is the limited orientation in the small pancreatic duct that relies on visual feedback only. Unsurprisingly, two pancreatic perforations occurred in the animal models because of difficulties in the identification of the organ margins.[12] To overcome this difficulty, image-guidance with a computer assisted navigation system was proposed in an experimental model. The CT scan of a 3D reconstruction of a silicon pancreas model was therefore transferred to the CAS-One navigation system (CAScination AG, Bern, Switzerland).[48,49] To fuse the virtual with the real world, two techniques were evaluated. First, registration with distinctive surface landmarks (LM) and second registration with intraparenchymal LM was proposed. Different combinations of these techniques were evaluated (1. surface LM only, 2. surface + intraparenchymal LM, and 3. intraparenchymal LM only). The registration accuracy was measured as fiducial registration error (FRE).[50,51] Using surface LM resulted in an FRE of 3.5 mm, compared with 2.5 mm for combined intraparenchymal and surface LM registration and 2.2 mm for intraparenchymal LM registration ($P=.052$ and $P=.035$, respectively). The registration process was faster using surface LM (01:51 minutes) than combined intraparenchymal and surface LM registration (02:12 minutes) or intraparenchymal LM registration alone (02:58 minutes). In a second experiment computer-assisted image-guided resections were performed in a pancreatic phantom. The resection was made using a rigid endoscope with a monopolar loop. Six of 7 lesions that were invisible on the endoscopic view were successfully targeted and completely resected on macroscopic evaluation of the pancreatic phantoms (Fig. 5). Given the limited direct visibility and the complex anatomy of the pancreas, EPS benefits of an image-guided navigation system (IG-NS) which was feasible and useful in pancreatic models.[14] To date EPS has solely been performed in pancreas phantoms and animal models. In our opinion a first human study should be planned as a next step for a thorough evaluation of EPS in highly selected clinical cases. As in open pancreatic surgery, adequately placed drains around the pancreas would be of paramount importance to manage potential postoperative pancreatic fistula. If successful, EPS could potentially fill the gap between current endoscopic and conventional surgical treatments.

### *Image-guided endopancreatic interventions*

Given the delicate anatomical structures surrounding the pancreas, orientation and differentiation between benign and malignant tissue remains difficult, especially when minimally invasive techniques are used. As the minimization of the access in

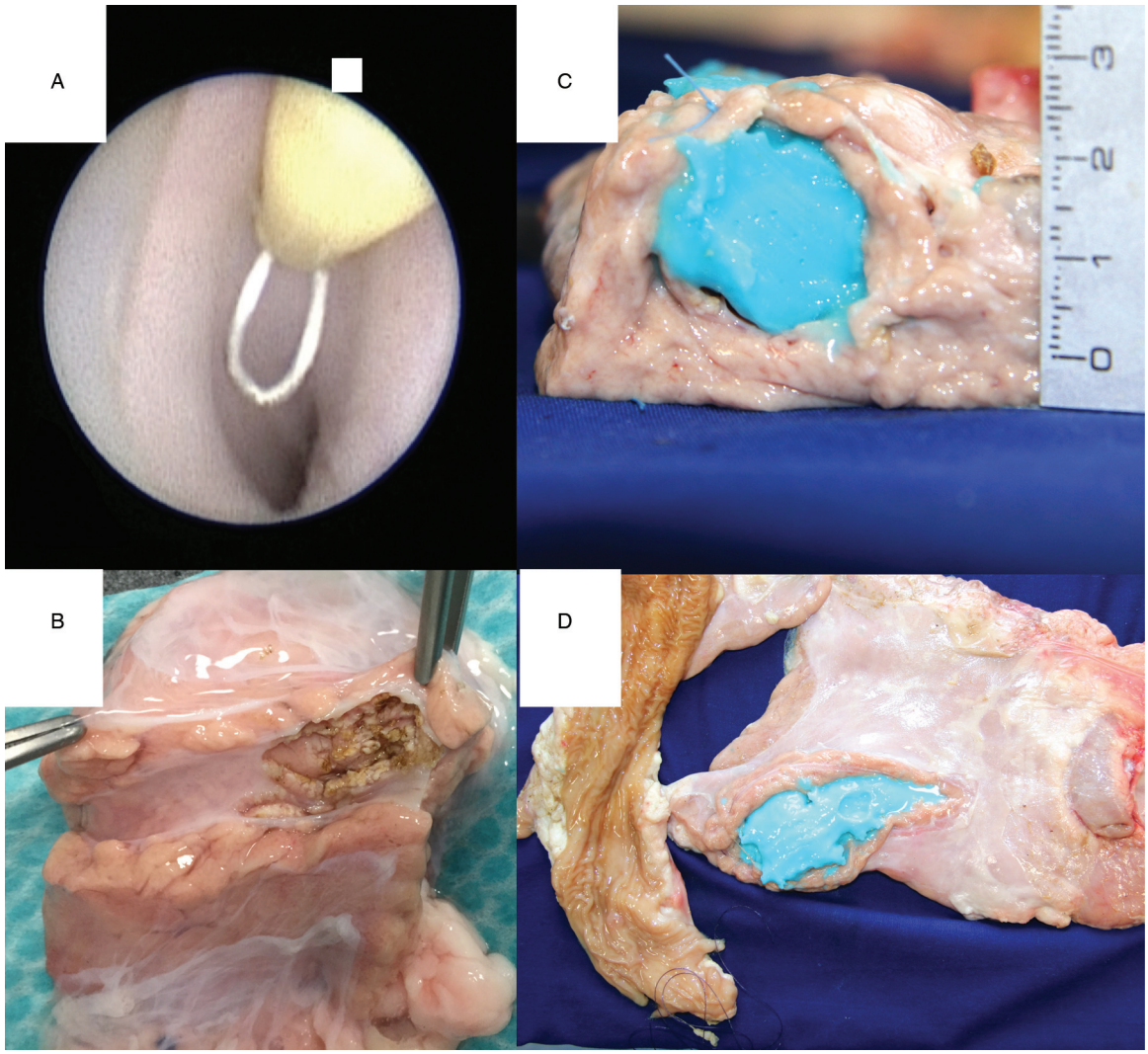


**Figure 4.** Experimental evaluation of endopancreatic surgery: (A) View of the pancreatic duct during endopancreatic surgery. (B) After resection, the pancreatic duct was cut open to demonstrate the resection area. (C) Cut surface after the endopancreatic resection; the resection cavity was filled with blue polysiloxane. (D) The resection cavity was cut open to demonstrate the extent of the resection from inside the pancreas.

endopancreatic interventions prevents palpation and direct view on the situs, more advanced imaging and guidance modalities are required to identify, locate and treat diseased tissue. This led researchers to investigate the applicability of image-guided surgery systems to navigate surgical tools through the patient's body.[52]

While the liver has been considered extensively,[53–57] the use of IG-NS in the pancreas has been sparse. However, the bottleneck of minimally invasive IS-surgery is the intraoperative organ deformation due to pneumoperitoneum and mobilization.[58,59] Compared to the liver and other intraabdominal organs,[60–62] the pancreas is potentially less susceptible to intraoperative deformation due to its retroperitoneal location and may therefore be a more suitable organ for IG-NS.

Initial attempts have used a projection of preoperatively created 3D pancreas models onto the patient's skin during laparoscopic pancreas surgery (Fig. 6). However, the evaluated system did not provide instrument navigation.[63] Stillström et al[54] evaluated a navigation system designed for open liver surgery during laparoscopic pancreas ablation. The system provided means to register the real world with preoperative 3D reconstructions of the pancreas and the surrounding anatomy to navigate optically tracked instruments. The navigation information was primarily used for the orientation of ablation needles in relation to the tumor (Fig. 7).[54]

The main limitations of a clinical application of IG in minimally invasive pancreatic surgery are large registration errors that were already experienced during the application in open surgery.[55,64,65] As already mentioned for EPS the CAS-One navigation system is promising, as it showed successful targeting of pancreatic lesions that indicates a sufficient registration accuracy for navigation purposes.[14]

POP combined with IG would enable more precise diagnostic procedures as the direct visualization is sometimes limited. However, this approach requires a tracking modality that does not suffer from the line-of-sight problem to track the endoscopes flexible tip. The use of electromagnetic tracking can be seen as an alternative to conventional optical tracking and was previously described in preclinical studies for laparoscopic ultrasound-guided ablation of hepatic tumors.[66,67] It is likely

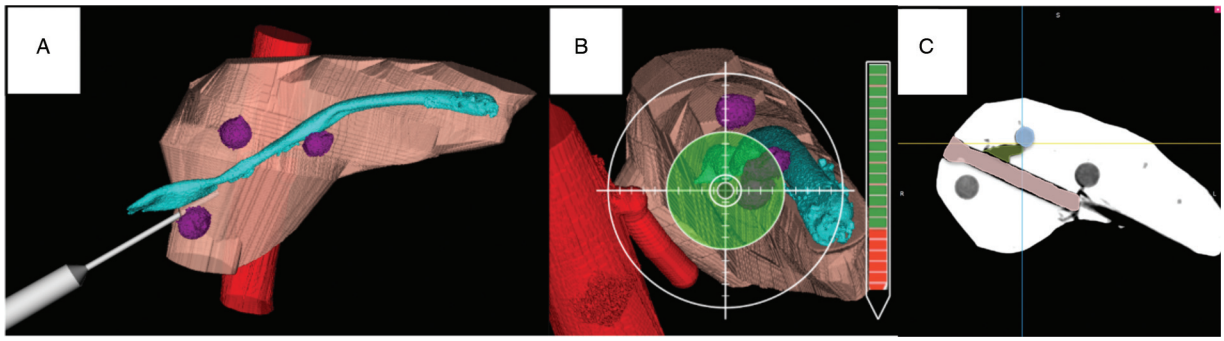


**Figure 5.** Combination of the endopancreatic resection with the computer assisted navigation system. (A, B) The image-guided navigation system provides a 3D visualization of the preoperative CT scan with the lateral and longitudinal displacement view relative to a selected target lesion, allowing for precise targeting and resection. (C) The postoperative CT scan shows the accurate image-guided targeting of a pancreatic lesion (blue) from inside the pancreatic duct (pink); the resection cavity is depicted in green.

that with the improvement of IG surgery, not only the quality of the diagnosis can be improved, but also the safety of the intervention. In the future, a steep further technical progress can be expected, that brings novel and improved concepts of image guidance to endopancreatic interventions, making the use of this access more accurate, more intuitive and therefore safer.

## Conclusion

The natural connection between the duodenum and the pancreatic duct is already regularly used, mainly for diagnostic and for certain therapeutic purposes. In animal models, the endopancreatic access allows the direct visualization of the pancreatic duct system potentially improving the diagnostic work-up of pancreatic cystic neoplasms and intrapancreatic strictures. Furthermore, the endopancreatic access could enable interventions like the removal of pancreatic stones, intraductal RFA and resection of pancreatic tissue from inside the pancreas. Orientation and localization of target structures using this minimally invasive approach is difficult therefore the development of an accurate image guidance system will play a key role for the further clinical implementation and widespread use of endopancreatic interventions.

## Acknowledgments

None.

## Author contributions

Design of the manuscript, literature search, writing the manuscript: MCF, BE, PCM. Literature search, critical revision of the manuscript: DCS, TH, FR, FN, BPMS, KZ. All authors approved the final version of the manuscript.

## Financial support

None.

## Conflicts of interest

BE was employed as a PhD student at CASCINATION AG until 12/2020, with his salary covered by the European Union's

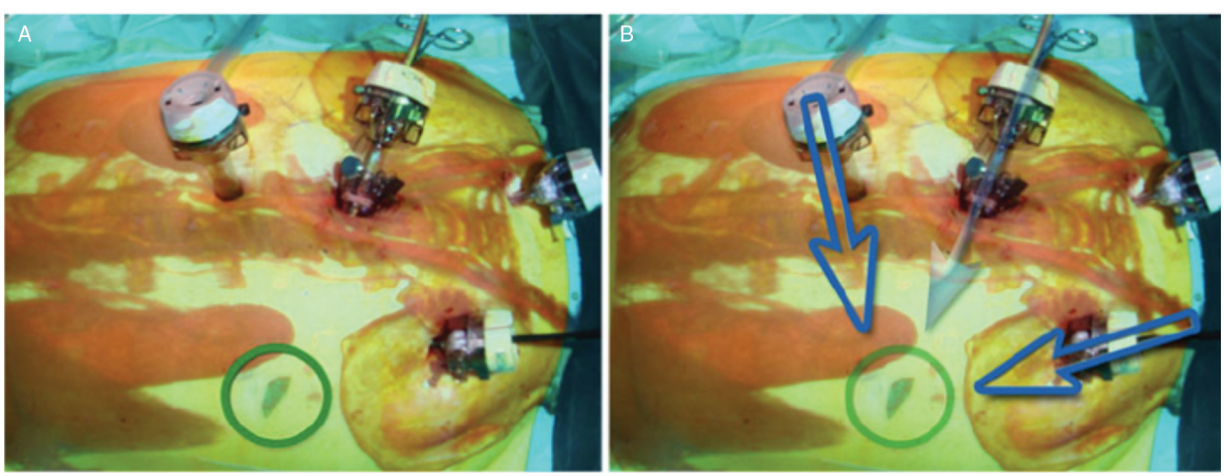


**Figure 6.** Image projection on the patient's body surface for the accurate identification of nodule (green circle) (A), and visual triangulation with laparoscopic instruments (blue arrow) (B) (adapted with permission from Volonté et al[63]).

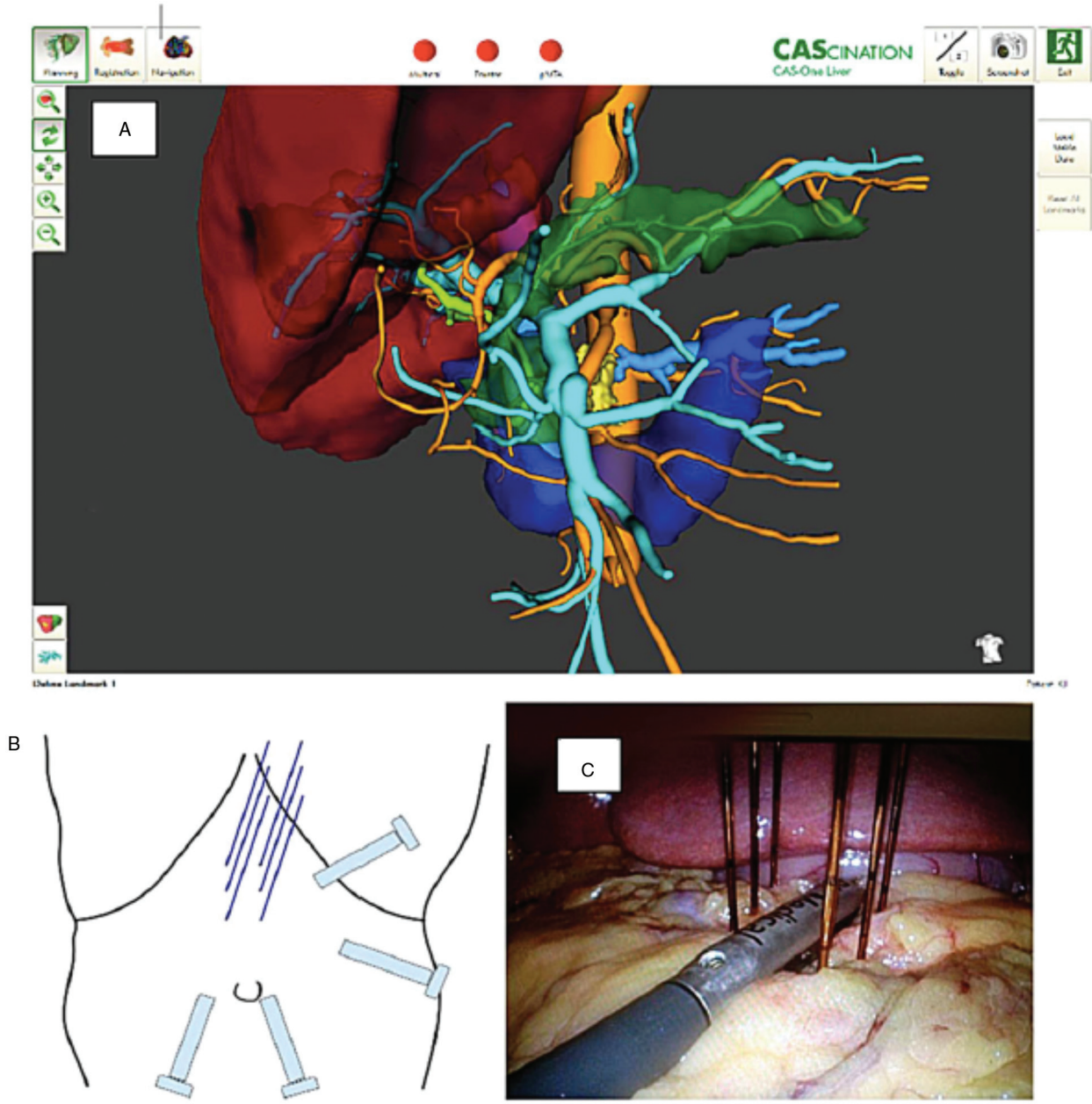


**Figure 7.** Overview of intraoperative needle navigation with 3D reconstructions (A), planning of needle placement (B) and intraoperative setup with the laparoscopically placed ablation needles (C) (adapted with permission from Stillström et al[54]).

Horizon 2020 research and innovation program. All other authors declare no conflicts of interest.

## References

[1] Tringali A, Boskoski I, Costamagna G. The role of endoscopy in the therapy of chronic pancreatitis. Best Pract Res Clin Gastroenterol 2008;22:145–165.
[2] Heyries L, Sahel J. Endoscopic treatment of chronic pancreatitis. World J Gastroenterol 2007;13:6127–6133.
[3] Delhaye M, Arvanitakis M, Verset G, et al. Long-term clinical outcome after endoscopic pancreatic ductal drainage for patients with painful chronic pancreatitis. Clin Gastroenterol Hepatol 2004;2:1096–1106.
[4] Howell DA. Pancreatic stones: Treat or ignore? Can J Gastroenterol 1999;13:461–465.
[5] Howell DA, Dy RM, Hanson BL, et al. Endoscopic treatment of pancreatic duct stones using a 10F pancreatoscope and electrohydraulic lithotripsy. Gastrointest Endosc 1999;50:829–833.
[6] Kawai K, Nakajima M, Akasaka Y, et al. A new endoscopic method: the peroral choledocho-pancreatoscopy (author's transl). Leber Magen Darm 1976;6:121–124.
[7] Chen YK, Pleskow DK. SpyGlass single-operator peroral cholangio-pancreatoscopy system for the diagnosis and therapy of bile-duct disorders: a clinical feasibility study (with video). Gastrointest Endosc 2007;65:832–841.
[8] Chen YK, Parsi MA, Binmoeller KF, et al. Single-operator cholangio-scopy in patients requiring evaluation of bile duct disease or therapy of biliary stones (with videos). Gastrointest Endosc 2011;74:805–814.
[9] Navaneethan U, Hasan MK, Kommaraju K, et al. Digital, single-operator cholangiopancreatoscopy in the diagnosis and management of pancreatobiliary disorders: a multicenter clinical experience (with video). Gastrointest Endosc 2016;84:649–655.

[10] Luca L. De , Repici A, Koçollari A, et al. Pancreatoscopy: an update. World J Gastrointest Endosc 2019;11:22–30.
[11] Auriemma F, De Luca L, Bianchetti M, et al. Radiofrequency and malignant biliary strictures: an update. World J Gastrointest Endosc 2019;11:95–102.
[12] Müller PC, Steinemann DC, Nickel F, et al. Transduodenal-transpapillary endopancreatic surgery with a rigid resectoscope: experiments on ex vivo, in vivo animal models and human cadavers. Surg Endosc 2017;31:4131–4135.
[13] Müller PC, Steinemann DC, Chinczewski L, et al. Transpapillary endopancreatic surgery: decompression of duct system and comparison of greenlight laser with monopolar electrosurgical device in ex vivo and in vivo animal models. Surg Endosc 2018;32:3393–3400.
[14] Müller PC, Haslebacher C, Steinemann DC, et al. Image-guided minimally invasive endopancreatic surgery using a computer-assisted navigation system. Surg Endosc 2020;35:1610–1617.
[15] Müller PC, Steinemann DC, Sauer P, et al. Balloon dilatation of the minor duodenal papilla up to 4 mm is safe in a porcine model. Surg Laparosc Endosc Percutan Tech 2017;27:e44–47.
[16] Kaura T, Willingham FF, Chawla S. Role of pancreatoscopy in management of pancreatic disease: a systematic review. World J Gastrointest Endosc 2019;11:155–167.
[17] Tandan M, Talukdar R, Reddy DN. Management of pancreatic calculi: an update. Gut Liver 2016;10:873–880.
[18] Attwell AR, Brauer BC, Yen RD, et al. Endoscopic retrograde cholangiopancreatography with per oral pancreatoscopy for calcific chronic pancreatitis using endoscope and catheter-based pancreatoscopes: a 10-year single-center experience. Pancreas 2014;43:268–274.
[19] Attwell AR, Patel S, Kahaleh M, et al. ERCP with per-oral pancreatoscopy-guided laser lithotripsy for calcific chronic pancreatitis: A multicenter U.S. experience. Gastrointest Endosc 2015;82:311–318.
[20] Parbhu SK, Siddiqui AA, Murphy M, et al. Efficacy, safety, and outcomes of endoscopic retrograde cholangiopancreatography with per-oral pancreatoscopy: a multicenter experience. J Clin Gastroenterol 2017;51:e101–105.
[21] Hirono S, Yamaue H. Surgical strategy for intraductal papillary mucinous neoplasms of the pancreas. Surg Today 2020;50:50–55.
[22] Käppeli RM, Müller SA, Hummel B, et al. IPMN: surgical treatment. Langenbeck's Arch Surg 2013;398:1029–1037.
[23] Hara T, Yamaguchi T, Ishihara T, et al. Diagnosis and patient management of intraductal papillary-mucinous tumor of the pancreas by using peroral pancreatoscopy and intraductal ultrasonography. Gastroenterology 2002;122:34–43.
[24] Arnelo U, Siiki A, Swahn F, et al. Single-operator pancreatoscopy is helpful in the evaluation of suspected intraductal papillary mucinous neoplasms (IPMN). Pancreatology 2014;14:510–514.
[25] El Hajj II, Brauer BC, Wani S, et al. Role of per-oral pancreatoscopy in the evaluation of suspected pancreatic duct neoplasia: a 13-year U.S. single-center experience. In: Gastrointestinal Endoscopy 2017;85:737–745.
[26] Mukai H, Yasuda K, Nakajima M. Differential diagnosis of mucin-producing tumors of the pancreas by intraductal ultrasonography and peroral pancreatoscopy. Endoscopy 1998;30 (Suppl 1):A99–102.
[27] Tyberg A, Raijman I, Siddiqui A, et al. Digital pancreaticocholangioscopy for mapping of pancreaticobiliary neoplasia: Can we alter the surgical resection margin? J Clin Gastroenterol 2019;53:71–75.
[28] Kaneko T, Nakao A, Nomoto S, et al. Intraoperative pancreatoscopy with the ultrathin pancreatoscope for mucin-producing tumors of the pancreas. Arch Surg 1998;133:263–267.
[29] Steel AW, Postgate AJ, Khorsandi S, et al. Endoscopically applied radiofrequency ablation appears to be safe in the treatment of malignant biliary obstruction. Gastrointest Endosc 2011;73:149–153.
[30] Sharaiha RZ, Natov N, Glockenberg KS, et al. Comparison of metal stenting with radiofrequency ablation versus stenting alone for treating malignant biliary strictures: Is there an added benefit? Dig Dis Sci 2014;59:3099–3102.
[31] Dolak W, Schreiber F, Schwaighofer H, et al. Endoscopic radiofrequency ablation for malignant biliary obstruction: a nationwide retrospective study of 84 consecutive applications. Surg Endosc 2014;28:854–860.
[32] Kallis Y, Phillips N, Steel A, et al. Analysis of endoscopic radiofrequency ablation of biliary malignant strictures in pancreatic cancer suggests potential survival benefit. Dig Dis Sci 2015;60:3449–3455.
[33] Sharaiha RZ, Sethi A, Weaver KR, et al. Impact of radiofrequency ablation on malignant biliary strictures: results of a collaborative registry. Dig Dis Sci 2015;60:2164–2169.
[34] Testoni SGG, Healey AJ, Dietrich CF, et al. Systematic review of endoscopy ultrasound-guided thermal ablation treatment for pancreatic cancer. Endosc Ultrasound 2020;9:83–100.
[35] Signoretti M, Valente R, Repici A, et al. Endoscopy-guided ablation of pancreatic lesions: technical possibilities and clinical outlook. World J Gastrointest Endosc 2017;9:41–54.
[36] Choi YH, Yoon SB, Chang JH, et al. The safety of radiofrequency ablation using a novel temperature-controlled probe for the treatment of residual intraductal lesions after endoscopic papillectomy. Gut Liver 2020;15:307–314.
[37] Camus M, Napoléon B, Vienne A, et al. Efficacy and safety of endobiliary radiofrequency ablation for the eradication of residual neoplasia after endoscopic papillectomy: a multicenter prospective study. Gastrointest Endosc 2018;88:511–518.
[38] Rustagi T, Irani S, Reddy DN, et al. Radiofrequency ablation for intraductal extension of ampullary neoplasms. Gastrointest Endosc 2017;86:170–176.
[39] Lorenzo D, Barret M, Bordacahar B, et al. Intraductal radiofrequency ablation of an intraductal papillary mucinous neoplasia of the main pancreatic duct. Endoscopy 2018;50:176–177.
[40] Mensah ET, Martin J, Topazian M. Radiofrequency ablation for biliary malignancies. Curr Opin Gastroenterol 2016;32:238–243.
[41] Andaluz A, Ewertowska E, Moll X, et al. Endoluminal radiofrequency ablation of the main pancreatic duct is a secure and effective method to produce pancreatic atrophy and to achieve stump closure. Sci Rep 2019;9:5928.
[42] Ewertowska E, Andaluz A, Moll X, et al. Development of a catheter-based technique for endoluminal radiofrequency sealing of pancreatic duct. Int J Hyperth 2019;36:677–686.
[43] Haney CM, Karadza E, Limen EF, et al. Training and learning curves in minimally invasive pancreatic surgery: from simulation to mastery. J Pancreatol 2020;3:101–110.
[44] Cahen DL, Gouma DJ, Nio Y, et al. Endoscopic versus surgical drainage of the pancreatic duct in chronic pancreatitis. N Engl J Med 2007;356:676–684.
[45] Díte P, Ružicka M, Zboril V, et al. A prospective, randomized trial comparing endoscopic and surgical therapy for chronic pancreatitis. Endoscopy 2003;35:553–558.
[46] Jimenez RE, Fernandez-del Castillo C, Rattner DW, et al. Outcome of pancreaticoduodenectomy with pylorus preservation or with antrectomy in the treatment of chronic pancreatitis. Ann Surg 2000;231:293–300.
[47] Haney CM, Kowalewski KF, Schmidt MW, et al. Endoscopic versus surgical treatment for infected necrotizing pancreatitis: a systematic review and meta-analysis of randomized controlled trials. Surg Endosc 2020;34:2429–2444.
[48] Peterhans M, Vom Berg A, Dagon B, et al. A navigation system for open liver surgery: design, workflow and first clinical applications. Int J Med Robot Comput Assist Surg 2011;7:7–16.
[49] Banz VM, Müller PC, Tinguely P, et al. Intraoperative image-guided navigation system: development and applicability in 65 patients undergoing liver surgery. Langenbeck's Arch Surg 2016;401:495–502.
[50] Serej ND, Ahmadian A, Mohagheghi S, et al. A projected landmark method for reduction of registration error in image-guided surgery systems. Int J Comput Assist Radiol Surg 2015;10:541–554.
[51] Widmann G, Stoffner R, Sieb M, et al. Target registration and target positioning errors in computer-assisted neurosurgery: proposal for a standardized reporting of error assessment. Int J Med Robot Comput Assist Surg 2009;5:355–365.
[52] Jolesz FA. Jolesz FA. Introduction. Intraoperative Imaging and Image-Guided Therapy New York, NY: Springer; 2014:1–23.
[53] Beermann M, Lindeberg J, Engstrand J, et al. 1000 consecutive ablation sessions in the era of computer assisted image guidance—lessons learned. Eur J Radiol Open 2019;6:1–8.
[54] Stillström D, Nilsson H, Jesse M, et al. A new technique for minimally invasive irreversible electroporation of tumors in the head and body of the pancreas. Surg Endosc 2017;31:1982–1985.
[55] Yasuda J, Okamoto T, Onda S, et al. Application of image-guided navigation system for laparoscopic hepatobiliary surgery. Asian J Endosc Surg 2020;13:39–45.
[56] Tinguely P, Fusaglia M, Freedman J, et al. Laparoscopic image-based navigation for microwave ablation of liver tumors—a multi-center study. Surg Endosc 2017;31:4315–4324.
[57] Kingham TP, Jayaraman S, Clements LW, et al. Evolution of image-guided liver surgery: transition from open to laparoscopic procedures. J Gastrointest Surg 2013;17:1274–1282.

[58] Teatini A, Pelanis E, Aghayan DL, et al. The effect of intraoperative imaging on surgical navigation for laparoscopic liver resection surgery. Sci Rep 2019;9:1–11.
[59] Prevost GA, Eigl B, Paolucci I, et al. Efficiency, accuracy and clinical applicability of a new image-guided surgery system in 3D laparoscopic liver surgery. J Gastrointest Surg 2020;24:2251–2258.
[60] Nickel F, Kenngott HG, Neuhaus J, et al. Navigation system for minimally invasive esophagectomy: experimental study in a porcine model. Surg Endosc 2013;27:3663–3670.
[61] Nickel F, Kenngott HG, Neuhaus J, et al. Computer tomographic analysis of organ motion caused by respiration and intraoperative pneumoperitoneum in a porcine model for navigated minimally invasive esophagectomy. Surg Endosc 2018;32:4216–4227.
[62] Kenngott HG, Wagner M, Gondan M, et al. Real-time image guidance in laparoscopic liver surgery: first clinical experience with a guidance system based on intraoperative CT imaging. Surg Endosc 2014;28:933–940.
[63] Volonté F, Pugin F, Bucher P, et al. Augmented reality and image overlay navigation with OsiriX in laparoscopic and robotic surgery: not only a matter of fashion. J Hepatobiliary Pancreat Sci 2011;18:506–509.
[64] Onda S, Okamoto T, Kanehira M, et al. Short rigid scope and stereoscope designed specifically for open abdominal navigation surgery: clinical application for hepatobiliary and pancreatic surgery. J Hepatobiliary Pancreat Sci 2013;20:448–453.
[65] Okamoto T, Onda S, Yasuda J, et al. Navigation surgery using an augmented reality for pancreatectomy. Dig Surg 2015;32:117–123.
[66] Thomas MN, Dieplinger G, Datta RR, et al. Navigated laparoscopic microwave ablation of tumour mimics in pig livers: a randomized ex-vivo experimental trial. Surg Endosc 2020;doi: 10.1007/s00464-020-08180-5.
[67] Paolucci I, Schwalbe M, Prevost GA, et al. Design and implementation of an electromagnetic ultrasound-based navigation technique for laparoscopic ablation of liver tumors. Surg Endosc 2018;32:3410–3419.

**How to cite this article:** Frey MC, Eigl B, Steinemann DC, Hackert T, Rössler F, Nickel F, Müller-Stich BP, Z'graggen K, Müller PC. A narrative review on endopancreatic interventions: an innovative access to the pancreas. J Pancreatol 2021;4:90–98. doi: 10.1097/JP9.0000000000000069