

Surgical Planning Tool for Robotically Assisted Hearing Aid Implantation

Nicolas Gerber^{1*}, Brett Bell¹, Kate Gavaghan¹, Christian Weisstanner²,
Marco Caversaccio³, Stefan Weber¹

1 ARTORG Center for Biomedical Engineering Research, University of Bern, Switzerland

2 University Institute of Diagnostic and Interventional Neuroradiology, University hospital of Bern (Inselspital), Switzerland

3 Department of Ear, Nose and Throat Diseases (ENT), Head and Neck Surgery, University hospital of Bern (Inselspital), Switzerland

***Corresponding author:**

*ARTORG Center for Biomedical Engineering Research
Murtenstrasse 50
3010 Bern
Switzerland*

Phone: +41 (0)32 632 76 15

Fax: +41 (0)32 632 76 24

nicolas.gerber@artorg.unibe.ch

www.artorg.unibe.ch

Abstract:

Purpose: For the facilitation of minimally invasive robotically performed direct cochlea access (DCA) procedure, a surgical planning tool which enables the surgeon to define landmarks for patient-to-image registration, identify the necessary anatomical structures and define a safe DCA trajectory using patient image data (typically computed tomography (CT) or cone beam CT (CBCT)) is required. To this end, a dedicated end-to-end software planning system for the planning of DCA procedures that addresses current deficiencies has been developed.

Methods: Efficient and robust anatomical segmentation is achieved through the implementation of semiautomatic algorithms; high accuracy patient-to-image registration is achieved via an automated model based fiducial detection algorithm and functionality for the interactive definition of a safe drilling trajectory based on case specific drill positioning uncertainty calculations was developed. **Results:** The accuracy and safety of the presented software tool was validated during the conduction of eight DCA procedures performed on cadaver heads. The plan for each ear was completed in less than 20 minutes and no damage to vital structures occurred during the procedures. The integrated fiducial detection functionality enabled final positioning accuracies of 0.15 ± 0.08 mm. **Conclusions:** Results of this study demonstrated that the proposed software system could aid in the safe planning of a DCA tunnel with an acceptable time.

Keywords: *surgical planning, hearing aid implantation, robotically assisted microsurgery, segmentation*

Introduction

Implantable hearing aids are able to restore hearing in moderately and profoundly deaf people. The majority of devices, such as the cochlear implant (CI) and the direct acoustical cochlea stimulator (DACS), require access to the middle and/or inner ear created by drilling in the lateral skull base. The most invasive component of the procedure is the mastoidectomy during which a large cavity is milled out of the mastoid, in order to locate and preserve risk structures such as nerves.

Because the mastoidectomy ($\varnothing 30 - 40$ mm) is much larger than is physically required to insert implantable hearing aids, several surgical strategies have been proposed to reduce invasiveness [1], [2]. A percutaneous or direct cochlear access (DCA) approach was introduced by Warren et al [3], who suggested that access could be gained by drilling a tunnel only slightly larger than the implant in diameter (1 mm – 2 mm in case of CI) with the aid of image guidance. The drilled trajectory would originate on the outer surface of the mastoid, pass through the facial recess, and terminate in the middle ear cavity in the region of the round or oval window.

Feasibility of an image-guided DCA was previously investigated and it was found that a drilling accuracy of at least 0.5 mm is required in order to safely drill through the facial recess without damaging any surrounding structures [4]. To achieve such accuracy, a robotically assisted procedure which overcomes the inability to precisely position the surgical drill using hand held instruments [5] was suggested [6–10]. The safe and effective conduction of an image guided, robotically assisted DCA procedure, strongly relies on the quality of the surgical plan and the accuracy at which the surgical plan can be registered to the physical patient intraoperatively.

The primary objective of the surgical plan is the definition of a safe path along which a surgical drill could pass without penetrating any sensitive structure. These structures include the facial nerve, the chorda tympani, the external auditory canal wall and the ossicles. The facial nerve controls all movement of the ipsilateral face and any injury would result in temporary or permanent paralysis of half of

the patient's face. Damage to the chorda tympani would cause temporary or permanent loss of taste of the ipsilateral tongue. Possible future infection could be caused by a breach of the external auditory canal. Looking from the mastoid surface to the cochlea, all of the aforementioned structures are contained within a window, typically 1.0 mm to 3.5 mm in diameter [11], through which the trajectory must also pass. As a result, preoperative planning software solutions, which allow for the segmentation of critical structures, are needed to safely and effectively plan DCA procedures.

Trajectory planning on 2D image slices is difficult due to poor representation of the spatial arrangements of anatomical structures. 3D environments greatly facilitate this process [12–15], however, segmentation of the preoperative image data is required in order to create 3D surface models of the anatomy of interest. Several segmentation algorithms have been proposed and are reviewed in [16]. However, very few of these algorithms have been implemented and verified in a preoperative planning software tool. Automatic segmentation of the aforementioned anatomical structures for DCA procedure planning was described by Noble *et al.* [17] using an atlas-based solution. One important underlying assumption of atlas-based identification method is that the image volumes used to create the atlas have similar topology. As a result, errors in segmentation may occur in cases of malformed ears. In addition, automatic algorithms remove the surgeon from the segmentation process, thus, reducing feedback regarding segmentation margins. As a result, a framework which allows visualisation of the segmentation output for verification, as well as tools for the possible alteration of segmentation results, is required for a robust preoperative planning tool suitable for clinical use.

Automatic trajectory definition and optimisation for DCA procedures based on: 3D modelled structures, user supplied structure preservation weightings and general system accuracy, has been previously proposed [11]. Optimal trajectory positioning should not, however, be determined on the basis of anatomy alone and in such algorithms, case specific error, patient indications, surgeon preferences and experience, and local regulations have not been considered. Additionally, adjustments to the automatically defined trajectories by the surgeon are not possible. A tool that can provide a case specific prediction of safety margins and

enable surgeons to define the optimal trajectory based on all of the available patient information is yet to be described.

For conduction of the defined surgical plan, a planning tool for DCA must provide functionality for registering the plan to the patient with an accuracy approximately 10 times better (0.1 – 0.2 mm) than that available in commercial navigation systems. It has been shown that the target registration error (TRE), the Euclidean distance between points in the physical space and corresponding points from the image space transformed via the registration process depends on the fiducial localisation error (FLE) [18]. Thus, localisation of the fiducial markers in the image plays an important role in the achievement of accuracy required to complete a successful DCA. Automated fiducial detection, which eliminates user variability, has been widely reported in image-guided neurosurgery and ear, nose, and throat surgery, [19–27], however, these methods provide accuracies insufficient for DCA procedures.

For the facilitation of middle ear access through a minimally invasive DCA procedure, a surgical planning tool which enables the surgeon to define landmarks for patient-to-image registration, identify the necessary anatomical structures and define a safe DCA trajectory using patient image data (typically computed tomography (CT) or cone beam CT (CBCT)) is required. However, to our knowledge, no end-to-end solution is available. To this end, we have developed a dedicated end-to-end software planning system for the planning of DCA procedures that addresses current deficiencies.

The proposed software tool, including methods of fiducial localisation, structure segmentation, trajectory definition and error prediction are described within this work. In addition, the results of an initial validation of the software as conducted during the drilling of DCA tunnels for CI implantation in cadaver heads, is presented.

Methods

The proposed planning software tool was designed to interface with the robotic system described in [28]. The five degrees of freedom (DoF) serial kinematic surgical robot system was developed as a dedicated solution for DCA cochlear implantation surgery. The robotic arm contains a six degrees of freedom force torque sensor in its wrist (Mini40, ATI, USA), which allows the user to

manipulate the end effector within the robot’s workspace through admittance control. Navigation is provided by a high precision optical tracking system (CamBar B1, Axios 3D GmbH, Germany) which is attached to the robot’s base and operates at a distance of 150 mm to 350 mm from the situs. It tracks active tracking markers attached to the tool and the patient within a cubic workspace of approximately 200 mm × 200 mm × 200 mm with an accuracy of 0.05 mm. Patient-to-image registration is achieved through pair point matching of bone implanted $\varnothing 1.5 \times 3$ mm titanium surgical screws (M-5220.03, Medartis, Switzerland), which are localised in the patient coordinate system through a semiautomatic ball-in-cone positioning method [27]. The robot is designed to autonomously drill a preoperatively planned trajectory through the mastoid to the middle ear following the workflow depicted in Figure 1.

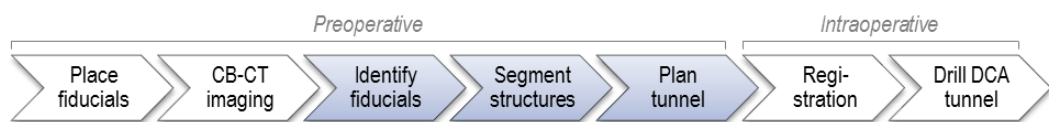


Figure 1 : Clinical workflow using the proposed software planning system for DCA surgery. Steps highlighted in blue are performed preoperatively using the proposed planning software system.

Initially, at least three (typically four) fiducial screws are implanted into the patient’s temporal bone to provide correspondence between the patient and the image data set. Fiducials are inserted around the external auditory canal at the zygomatic process, the mastoid process, and two additional positions approximately equidistant on the opposite side of the external auditory meatus. Preoperative images of the patient’s mastoid are then acquired using a CBCT system (i.e. ProMax 3D Max, Planmeca, Finland) in high resolution mode (0.15 mm × 0.15 mm × 0.15 mm).

After loading the patient image data, a plan is performed in three primary steps: the detection of fiducial marker positions for patient-to-image registration; the segmentation of relevant anatomical structures and the definition of a trajectory. These three steps are described below in detail. Once the plan is complete, it is saved and exported for use by the robotic system described above. Finally, the DCA is drilled by the robotic system intraoperatively.

The proposed planning software system (see Figure 2) was developed using the C++ programming language and open source libraries including: Qt (Digia,

Helsinki, Finland), Open Inventor (Coin3D, Kongsberg, Norway), the DICOM Toolkit (DCMTK, OFFIS computer science institute, Germany), the Visualization Toolkit (VTK, Kitware Inc., USA) and the Insight Segmentation and Registration Toolkit (ITK, Kitware Inc., USA). It was designed to be run on a standard laptop computer by medical staff.

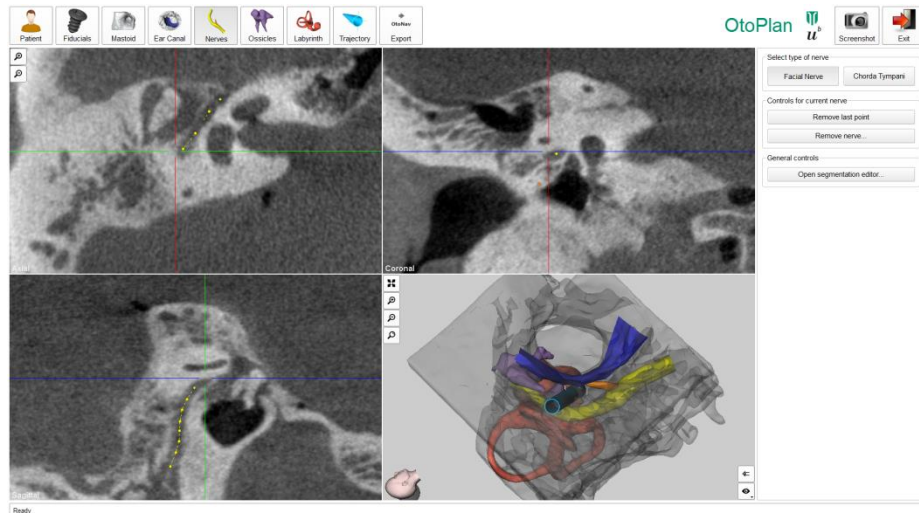


Figure 2: User interface of the proposed planning software system showing a completed plan.

Fiducial Localisation

To enable the drilling of a DCA tunnel with accuracy greater than 0.5 mm, a target registration error of less than 0.2 mm is required. In order to achieve such high accuracy, an automated technique that removes user variability was developed [27].

Within the image, the screw location must be defined as the position at which the robotic system's registration tool sits in the conical indent in the fiducial screw head (refer to Figure 3 (d)). An initial coarse localisation of each fiducial screw is manually defined with a user-supplied single selection. Thereafter, the exact registration position of the fiducial is determined automatically by the proposed planning software system using the following methodology (see Figure 3):

1. A small sub-volume encompassing each screw is cropped from image volume data.
2. Features corresponding to the boundary of the fiducial screw are extracted by applying a gradient magnitude filter followed by a thresholding of the sub-volume.

3. A threshold is applied to the gradient magnitude in order to extract the voxels located at the boundary of the fiducial screw.
4. A coarse registration of the 3D surface model to the corresponding binary sub-volume is computed using their respective centroids and principal axes.
5. The 3D surface model is iteratively matched to the extracted features via a standard iterative closest point matching algorithm.
6. The position of the screw, transformed to the calibrated registration tool position within the screw's indent, is returned.

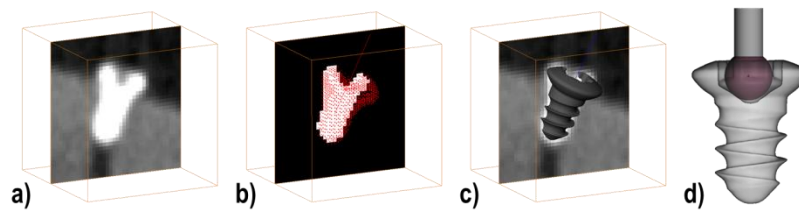


Figure 3: Fiducial detection workflow in the image: cropped subvolume (a); Extracted features with binary subvolume (b); and co-registered fiducial model and image (c). Ball-in-cone representation (d).

This methodology was verified on phantoms with clinically relevant fiducial and target locations. The fiducial localisation in the image (FLE_{im}) was found to have a ground truth error of $0.153 \text{ mm} \pm 0.061 \text{ mm}$ ($N = 30$) and, when used in conjunction with the automatic fiducial detection technique on the patient ($FLE_{pat} = 0.046 \text{ mm} \pm 0.029 \text{ mm}$) a mean TRE of $0.101 \text{ mm} \pm 0.40 \text{ mm}$ ($N = 144$). For a more detailed description of the registration methodology and its verification, we direct the reader to [27].

Anatomical Structures Segmentation

The definition of a safe DCA trajectory initially requires 3D segmented models of the relevant anatomical structures of the ear and middle ear. The required structures include: the mastoid for definition of the trajectory entry position; the round window or the oval window as a target for the drilled trajectory; and the auditory ear canal wall, the facial nerve, the chorda tympani and the ossicles as anatomy to preserve during the drilling process.

A semi-automatic approach to segmentation was adopted in order to allow structures to be quickly and easily segmented whilst allowing the operator to maintain control over the segmentation margins and segmentation verification.

After loading the patient's images, a 3D surface model of the mastoid is created using three steps. Firstly, the user defines a lower and an upper threshold to select the bony structures in the image data set. Voxels with a value inside the defined range are displayed with a red overlay mask (see Figure 4). Secondly, a box is delimited to select the volume of interest, encompassing the mastoid surface, the external auditory canal, and the middle ear and inner ear. This step reduces the time required for segmentation and is required because the mastoid is highly pneumatised and therefore results in a large surface area. Subsequent image processing operations are performed in the volume of interest with VTK filters using the selected voxels. To smooth the image, a Gaussian filter is applied ($\sigma = 0.4$ in x, y and z directions). Image thresholding is performed using previously user-defined lower and upper thresholds. The resulting binary mask is further processed with an island removal filter. The marching cube algorithm [29] is used to create the 3D surface model before usage of a windowed sinc smoothing filter.

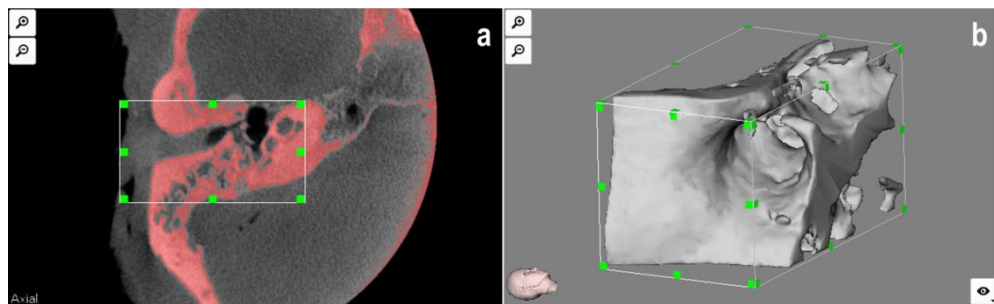


Figure 4 : Mastoid segmentation with selected red overlay (a). 3D surface model of the mastoid region (b).

The posterior external auditory canal wall (EAC) is segmented from four user-supplied mouse clicks. The EAC is first located on the axial view and its axis is defined by selecting two points (points one and two on Figure 5). The software displays the sagittal plane that passes through the middle of the axis. The user is then prompted to define an angle incorporating the desired wall portion to segment by clicking points three and four on the sagittal view. The EAC wall is automatically computed using a customised algorithm based on a threshold intensity value. Starting from the EAC's axis moving radially in the defined region, the wall is located when the voxel intensity reaches the specified threshold. The threshold is initially defined as the value used to segment the mastoid, however, alteration of its value can be performed in the user interface.

Finally, a 3D surface is computed using the resulting point cloud by means of the VTK surface reconstruction filter.

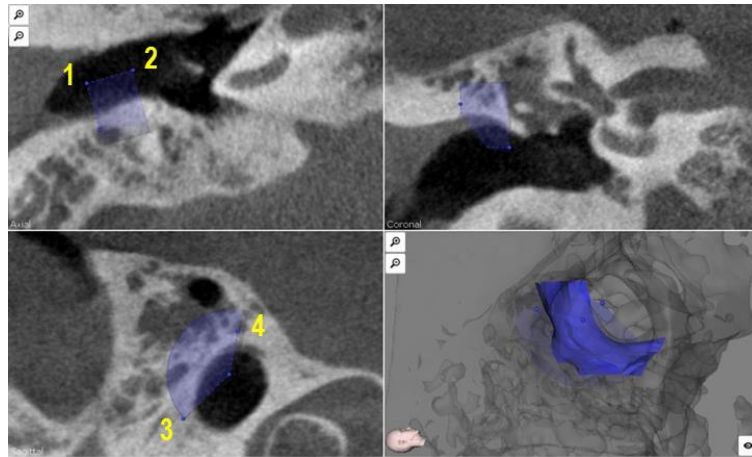


Figure 5 : External auditory canal wall segmentation using 4 points and a defined threshold.

Segmentation of the facial nerve and chorda tympani are performed in two steps. In a first step, the centreline of each nerve is interactively drawn as a number of mouse clicks on any of the standard axial, coronal and sagittal planes (see Figure 6 a).

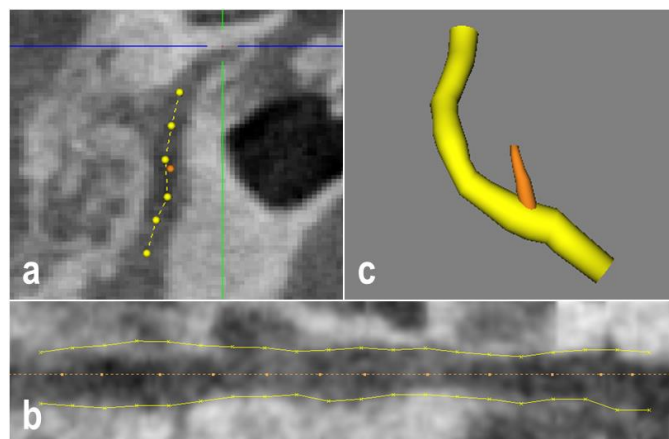


Figure 6 : Interactive drawing of the facial nerve and chorda tympani centrelines (a). Curved planar reconstruction (CPR) along the facial nerve's centreline (b). 3D surface model of the facial nerve and chorda tympani (c).

In a second step, curved planar reconstruction (CPR) [30] is used to create a panoramic view of the nerve along its centreline (see Figure 6 b). A first identification of the nerve's borders is automatically suggested to the user. Starting from equally spaced points on the centreline, and moving up and down until a predefined threshold intensity is reached, the boundary of the nerve is

found. Alteration of the borders is left to the user, who can drag and drop any drawn border points. Furthermore, the CPR plane can be manually rotated along the nerve's centreline for visual inspection in the 3D volume. Finally, the 3D surface model of the nerve is created by connecting cylinders based on the CPR segmentation (see Figure 6 c).

The segmentation of the ossicles is divided into segmentation of the incus and malleus, and segmentation of the stapes. A region growing algorithm with connected thresholds criterion is initiated after point selection on the incus or malleus (see Figure 7). The thresholds can be modified in the graphical user interface. Similarly to the mastoid, a marching cubes algorithm [29] is then used to create the 3D surface model of the structures.

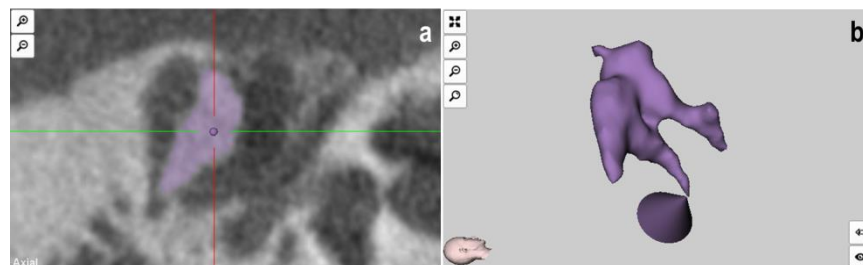


Figure 7 : Incus and malleus segmentation (a). 3D surface model of the incus, malleus and stapes (b).

The stapes is manually segmented using three landmarks. First, the tip of the incus lenticular process is selected. Secondly, the anterior border of the oval window is selected. Thirdly, the posterior border of the oval window is defined. A cone shape is created using these three landmarks to define the volume region of the stapes.

Tunnel Definition

Having the necessary anatomical structures modelled, a trajectory can be defined. The target, typically the middle of the round window for a CI or the middle of the oval window for a DACS implant, is manually selected on the image data set by a single mouse click. Subsequently, the entry point is manually designated on the surface of the mastoid in order to establish a suitable tunnel avoiding the previously modelled structures. The trajectory is optimised by dragging the entrance point until sufficient distance to the anatomical structures is found or until the surgeon determines that the facial recess is of insufficient size for robotic

surgery eligibility. To aid the surgeon in the determination of a safe trajectory, predicted error pertaining to the DCA procedure is calculated and displayed as a 3D model around the planned trajectory. In addition, safety margins, measured from the surface of the trajectory model (including error) to anatomical structures, are computed and displayed.

Error associated with a robotically performed DCA procedure is composed of case specific and general system error. System error pertaining to the, robotic system and drilling process (primarily composed of tracking error and error due to tool bending) is entered as a static value into the planning tool by the user. For the described robotic system, general system error has been previously determined as approximately 0.05 mm. Case specific errors are attributed to the error pertaining to the patient-to-image registration. Whilst a specific registration error cannot be determined until after the registration process, a prediction of target registration error (TRE), can be approximated in the planning phase using equation (1) from [18] where: k is the number of dimensions, d_k is the distance of the target from principal axis k of the fiducials; f_k is the root mean square distance of the fiducials from principal axis k ; N is the number of fiducials; and FLE is a static value (0.159 mm) defined by the previously determined statistical FLEs associated with the employed fiducial detection methods within the image and on the patient [27].

$$\langle TRE^2 \rangle \approx \frac{\langle FLE^2 \rangle}{N} \left(1 + \frac{1}{3} \sum_{k=1}^3 \frac{d_k^2}{f_k^2} \right) \quad (1)$$

where $\langle FLE^2 \rangle = \langle FLE_{im}^2 \rangle + \langle FLE_{pat}^2 \rangle$

Because registration error (TRE) varies with distance from the registration plane, the value is calculated for 1 mm increments along the user selected trajectory. The total error value, defined as the addition of system error and predicted registration error for each increment, is calculated and displayed around the trajectory in the 3D model view. Additionally, distances to anatomical structures are computed including total error and are displayed to the user (see Figure 8).

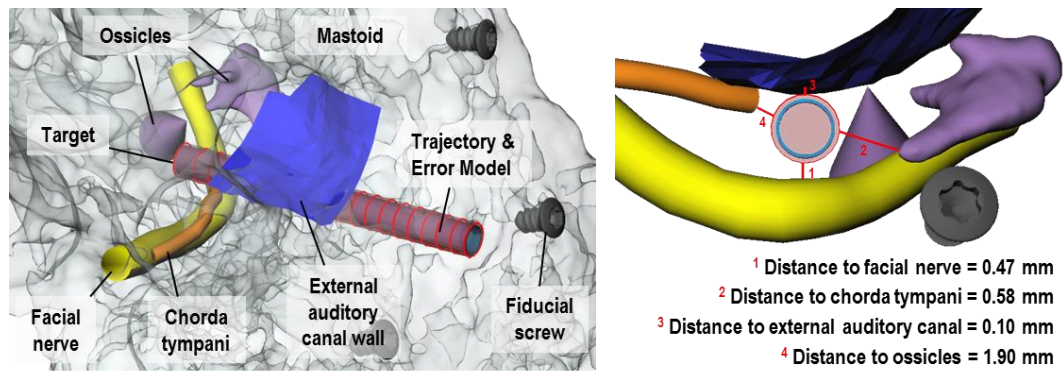


Figure 8 : Trajectory definition including minimum distances to structures.

Verification

Ten ears from five whole cadaver heads were used to evaluate the proposed method. For each ear, four fiducial screws were implanted prior to CBCT imaging in high resolution mode. For each ear, a trajectory of $\varnothing 1.8$ mm was planned from the mastoid surface to the middle of the round window through the facial recess with the objective of preserving all vital anatomical structures. Because of the importance of the facial nerve, any case in which it was not possible to define a trajectory with safety margin (from the tunnel to the facial nerve surface) greater than 0.2 mm, was classified as ineligible for a DCA procedure and automatically excluded from the study. The time to create each of the ten plans was recorded. Each plan was imported into the image-guided robotic system and used for registration and guidance of the DCA procedure.

Postoperatively, a $\varnothing 1.8$ mm titanium Kirschner wire was inserted into the drilled tunnels and a CBCT image in high resolution mode was acquired. On the resulting postoperative image data, the wire was segmented using region growing ($I > 2500$ HU). Linear least squares regression was used on the segmented voxels to find the axis of the DCA tunnel. Pair point matching was used to register the postoperative image data to the preoperative image data using the fiducial screw positions extracted with the proposed planning software system. The deviation of entrance was determined by computing the Euclidian distance between the planned entrance position and its projection onto the drilled trajectory axis. Similarly, the target deviation was obtained by computing the Euclidian distance between the planned target position and its projection onto the drilled trajectory axis. In order

to verify the segmentation, the postoperative images were additionally examined for the presence of damage to vital structures.

Results

The proposed planning software system was successfully used to plan the ten DCA procedures. One head was found to have insufficient safety margins on both sides and was thus excluded from the study. Feedback from the software revealed that it was impossible to define a tunnel without penetrating both the facial nerve and the external auditory canal on the left side and that, on the right side, safety margins (including predicted errors) greater than 0.15 mm to the facial nerve were not possible. For eight of the ten ears, trajectories were planned to pass through the facial recess avoiding all vital anatomical structures (see Figure 9). The planning software did not predict damage to any vital structure for any of the eight DCA procedures. The plan for each ear was completed in less than 20 minutes.

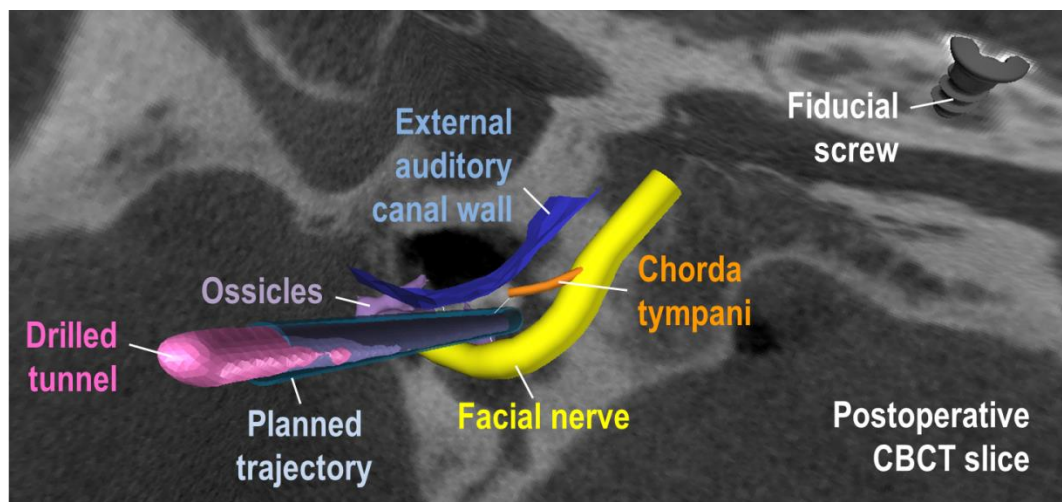


Figure 9: Drilling results with drilled trajectory overlaid with preoperative plan.

Accurate DCA drilling was enabled via a dedicated fiducial detection algorithm in the image and resulted in mean drilling errors at the entrance and at the target of 0.08 ± 0.05 mm (N = 8) and 0.15 ± 0.08 mm (N = 8) respectively [31]. Through visual inspection of the postoperative images, it was observed that all vital anatomy was preserved in all eight DCA procedures and thus, predicted safety margins for all cases were sufficient.

Discussion

Within this work we propose a dedicated surgical planning software tool for robotically performed DCA that enables safe trajectory planning and sufficiently accurate patient-to-image registration. Results of this study demonstrated that the software could aid in the safe planning of a DCA tunnel with an acceptable time. In addition, it provided fiducial localisation accuracy that enabled an overall procedure error of less than 0.26 mm and enabled procedures to be performed without damage to any vital anatomical structure.

Additionally, it is expected that the proposed planning software system would aid in the determination of a patient's eligibility for robotic DCA implantation. With very small distances between the drilled trajectory and critical anatomical structures, the ability of the surgeon to successfully assess the safety of the procedure and the eligibility of each patient is vital. Eligibility is based on the expected error of the procedure and on the size of the facial recess through which the drilling trajectory passes. By providing a 3D visualisation of the internal anatomy, surgical plan and predicted surgical error and through the display of a quantitative analysis of predicted safety margins, the proposed planning software system aids the surgeon in this process. The definition of a general "sufficient" safety margin for an individual anatomical structure is not possible. The importance of preservation of structures such as the chorda tympani or ossicles is, for example, additionally influenced by the presence of residual hearing or local customs or regulations and thus, must be determined by the operating surgeon for each individual case. It is thus believed, that providing surgeons with useful, interpretable information regarding the predicted surgical situation within the planning phase and enabling them, with their extensive knowledge and experience, to make decisions regarding procedure safety, remains an optimal solution, superior to any fully automatic procedure planning algorithm or safety determination.

Additionally, due to small safety margins, the accuracy of the segmentation of anatomical structures throughout the planning process is paramount. Currently, the gold standard in segmentation is achieved through manual segmentation [32]. Unfortunately, integration of manual segmentation of all structures required for a DCA plan in clinical routine is not feasible due to the time involved. The proposed planning software system has been designed to increase the speed of the

segmentation process whilst preserving the surgeons control over segmentation margins and their knowledge of the segmentation quality. Whilst fully automatic segmentation tools such as that described by Nobel *et al.* [14], reduces the interaction time, all feedback pertaining to the quality of the images and thus the segmentation is removed. Moreover, In order to maintain safety control over the procedure, it is important that the surgeon is aware if structures have been over or more importantly under segmented. By involving the surgeon in the planning process and by displaying visualisations of segmentation regions to the user on standard image planes, verification of the segmentation can be conducted throughout the segmentation process.

The verification of segmentation and surgical planning software remains a challenge, especially due to the subjective nature of structure boundaries within a medical image. Within this study, the plan has been verified through the visualised preservation of anatomical structures on the postoperative CBCT data as this is the measure of success for such a planning tool. Future studies evaluating the intra- and inter-segmentation variance using the presented semiautomatic methods will aim to further assess the quality of the segmentations through cross examinations by qualified users.

Whilst the proposed planning software system currently aids the surgeon in constructing a safe and effective plan and in determining patient-specific eligibility for robotically assisted DCA, intraoperative error can never be completely predicted. For this reason, error predictions in the planning software provide only an approximate of drill positioning uncertainty and should thus, be coupled with intraoperative error prediction methods, that can be conducted after patient-to-image registration and throughout the drilling process. For example, error prediction can be reapproximated after registration using matching error results and a technique, which correlates the drilling force history with bone density data to predict a tool's position within a porous structure like the mastoid [33], can be employed to continually reassess error during drilling.

In addition to interfacing with robotic systems, the proposed planning software system could support the planning of conventional hearing aid implantations, where patient-specific anatomy could be displayed in a 3D environment to increase the surgeon's spatial awareness.

Whilst this work focuses on the planning of the safe conduction of a DCA procedure for gaining access of the middle ear cavity, additional functionality that would aid in the implantation of a specific hearing device will be considered and integrated in future work. For example, the determination of a trajectory, approximately tangential to the basal turn of the cochlea could aid to reduce trauma during the insertion of a cochlear implant electrode and functionality for the planning of a device bed and configuration will be required for the positioning of more complex devices such as the DACS.

References

- [1] R. Häusler, "Cochlear implantation without mastoidectomy: the pericanal electrode insertion technique.," *Acta oto-laryngologica*, vol. 122, no. 7, pp. 715–9, Oct. 2002.
- [2] J. Kronenberg, W. Baumgartner, L. Migirov, T. Dagan, and M. Hildesheimer, "The suprameatal approach: an alternative surgical approach to cochlear implantation.," *Otology & Neurotology*, vol. 25, no. 1, pp. 41–4; discussion 44–5, Jan. 2004.
- [3] F. M. Warren, R. Balachandran, J. M. Fitzpatrick, and R. F. Labadie, "Percutaneous cochlear access using bone-mounted, customized drill guides demonstration of concept in vitro.," *Otology & Neurotology*, vol. 28, no. 3, pp. 325–9, Apr. 2007.
- [4] J. Schipper, A. Aschendorff, I. Arapakis, T. Klenzner, C. B. Teszler, G. J. Ridder, and R. Laszig, "Navigation as a quality management tool in cochlear implant surgery," *The Journal of Laryngology and Otology*, vol. 118, no. 10, pp. 764–770, Oct. 2004.
- [5] R. F. Labadie, P. Chodhury, E. Cetinkaya, R. Balachandran, D. S. Haynes, M. R. Fenlon, A. S. Juszczek, and J. M. Fitzpatrick, "Minimally invasive, image-guided, facial-recess approach to the middle ear: demonstration of the concept of percutaneous cochlear access in vitro.," *Otology & Neurotology*, vol. 26, no. 4, pp. 557–62, Jul. 2005.
- [6] R. Balachandran, J. E. Mitchell, G. Blachon, J. H. Noble, B. M. Dawant, J. M. Fitzpatrick, and R. F. Labadie, "Percutaneous cochlear implant drilling via customized frames: an in vitro study.," *Otolaryngology--head and neck surgery : official journal of American Academy of Otolaryngology-Head and Neck Surgery*, vol. 142, no. 3, pp. 421–6, Mar. 2010.
- [7] R. F. Labadie, J. Mitchell, R. Balachandran, and J. M. Fitzpatrick, "Customized, rapid-production microstereotactic table for surgical targeting: description of concept and in vitro validation.," *International journal of computer assisted radiology and surgery*, vol. 4, no. 3, pp. 273–80, May 2009.
- [8] O. Majdani, K. Thews, S. Bartling, M. Leinung, C. Dalchow, R. Labadie, T. Lenarz, and G. Heidrich, "Temporal bone imaging: comparison of flat panel volume CT and multisection CT.," *AJNR Am J Neuroradiol*, vol. 30, no. 7, pp. 1419–1424, Aug. 2009.
- [9] T. Klenzner, C. C. Ngan, F. B. Knapp, H. Knoop, J. Kromeier, A. Aschendorff, E. Papastathopoulos, J. Raczkowski, H. Wörn, and J. Schipper, "New strategies for high precision surgery of the temporal bone using a robotic approach for cochlear implantation.," *European archives of oto-rhino-laryngology : official journal of the European Federation of Oto-Rhino-Laryngological Societies (EUFOS) : affiliated with the*

German Society for Oto-Rhino-Laryngology - Head and Neck Surgery, vol. 266, no. 7, pp. 955–60, Jul. 2009.

- [10] S. Baron, H. Eilers, B. Munske, J. L. Toennies, R. Balachandran, R. F. Labadie, T. Ortmaier, and R. J. Webster, “Percutaneous inner-ear access via an image-guided industrial robot system,” *Proceedings of the Institution of Mechanical Engineers, Part H: Journal of Engineering in Medicine*, vol. 224, no. 5, pp. 633–649, May 2010.
- [11] J. H. Noble, B. Dawant, and J. M. Fitzpatrick, “Automatic determination of optimal linear drilling trajectories for cochlear access accounting for drill-positioning error,” *International Journal*, no. May, pp. 281–290, 2010.
- [12] T. Rodt, P. Ratiu, H. Becker, S. Bartling, D. F. Kacher, M. Anderson, F. a Jolesz, and R. Kikinis, “3D visualisation of the middle ear and adjacent structures using reconstructed multi-slice CT datasets, correlating 3D images and virtual endoscopy to the 2D cross-sectional images.,” *Neuroradiology*, vol. 44, no. 9, pp. 783–90, Sep. 2002.
- [13] B.-C. Jun, S.-W. Song, J.-E. Cho, C.-S. Park, D.-H. Lee, K.-H. Chang, and S.-W. Yeo, “Three-dimensional reconstruction based on images from spiral high-resolution computed tomography of the temporal bone: anatomy and clinical application.,” *The Journal of laryngology and otology*, vol. 119, no. 9, pp. 693–8, Sep. 2005.
- [14] J. H. Noble, B. M. Dawant, F. M. Warren, and R. F. Labadie, “Automatic identification and 3D rendering of temporal bone anatomy.,” *Otol Neurotol*, vol. 30, no. 4, pp. 436–442, Jun. 2009.
- [15] H. G. Jang, M. S. Chung, D. S. Shin, S. K. Park, K. S. Cheon, H. S. Park, and J. S. Park, “Segmentation and surface reconstruction of the detailed ear structures, identified in sectioned images.,” *Anatomical record (Hoboken, N.J. : 2007)*, vol. 294, no. 4, pp. 559–64, Apr. 2011.
- [16] A. Ferreira, J. M. R. S. Tavares, and F. Gentil, “A review of segmentation algorithms for ear image data,” in *Information Systems and Technologies (CISTI), 2012 7th Iberian Conference on*, 2012, pp. 1–6.
- [17] J. H. Noble, B. M. Dawant, F. M. Warren, and R. F. Labadie, “Automatic identification and 3D rendering of temporal bone anatomy.,” *Otol Neurotol*, vol. 30, no. 4, pp. 436–442, Jun. 2009.
- [18] J. M. Fitzpatrick, J. B. West, and C. R. Maurer, “Predicting error in rigid-body point-based registration.,” *IEEE transactions on medical imaging*, vol. 17, no. 5, pp. 694–702, Oct. 1998.
- [19] O. Schermeier, T. Lueth, J. Glagau, D. Szymanski, R. Tita, D. Hildebrand, M. Klein, K. Nelson, and J. Bier, “Automatic patient registration in computer assisted maxillofacial surgery.,” *Studies in health technology and informatics*, vol. 85, pp. 461–7, Jan. 2002.
- [20] R. F. Labadie, R. J. Shah, S. S. Harris, E. Cetinkaya, D. S. Haynes, M. R. Fenlon, A. S. Jusczyk, R. L. Galloway, and J. M. Fitzpatrick, “Submillimetric target-registration error using a novel, non-invasive fiducial system for image-guided otologic surgery.,” *Computer aided surgery : official journal of the International Society for Computer Aided Surgery*, vol. 9, no. 4, pp. 145–53, Jan. 2004.
- [21] M. Y. Wang, C. R. Maurer, J. M. Fitzpatrick, and R. J. Maciunas, “An automatic technique for finding and localizing externally attached markers in CT and MR volume images of the head.,” *IEEE transactions on bio-medical engineering*, vol. 43, no. 6, pp. 627–37, Jun. 1996.

- [22] L. Gu and T. Peters, "3D Automatic Fiducial Marker Localization Approach for Frameless Stereotactic Neuro-surgery Navigation Morphological Treatment for the Detection of Fiducial Markers," *MIAR 2004*, vol. LNCS 3150, pp. 329–336, 2004.
- [23] R. Krishnan, E. Hermann, R. Wolff, M. Zimmermann, V. Seifert, and A. Raabe, "Automated fiducial marker detection for patient registration in image-guided neurosurgery.," *Computer aided surgery : official journal of the International Society for Computer Aided Surgery*, vol. 8, no. 1, pp. 17–23, Jan. 2003.
- [24] C. R. Maurer, J. M. Fitzpatrick, M. Y. Wang, R. L. Galloway, R. J. Maciunas, and G. S. Allen, "Registration of head volume images using implantable fiducial markers.," *IEEE transactions on medical imaging*, vol. 16, no. 4, pp. 447–62, Aug. 1997.
- [25] C. R. Maurer, J. M. Fitzpatrick, M. Y. Wang, and R. J. Maciuna, "Estimation of localization accuracy for markers in multimodal volume images," in *Proceedings of the 15th Annual International Conference of the IEEE Engineering in Medicine and Biology Societ*, 1993, vol. Im, no. 2, pp. 124–125.
- [26] M. Wang and Z. Song, "Automatic Detection of Fiducial Marker Center Based on Shape Index and Curvedness," *MIAR 2008*, vol. LNCS 5128, pp. 81–88, 2008.
- [27] N. Gerber, K. Gavaghan, B. Bell, T. Williamson, C. Weisstanner, M. Caversaccio, and S. Weber, "High Accuracy Patient-to-Image Registration for the Facilitation of Image Guided Robotic Microsurgery on the Head.," *IEEE transactions on bio-medical engineering*, vol. In Print, Jan. 2013.
- [28] B. Bell, C. Stieger, N. Gerber, A. Arnold, C. Nauer, V. Hamacher, M. Kompis, L. Nolte, M. Caversaccio, and S. Weber, "A self-developed and constructed robot for minimally invasive cochlear implantation.," *Acta oto-laryngologica*, pp. 1–6, Mar. 2012.
- [29] W. E. Lorensen and H. E. Cline, "Marching Cubes: A High Resolution 3D Surface Construction Algorithm," *Computer Graphics*, vol. 21, no. 4, pp. 163–169, 1987.
- [30] A. Kanitsar, D. Fleischmann, R. Wegenkittl, P. Felkel, and M. E. Gröller, "CPR-curved planar reformation," in *IEEE Visualization, 2002. VIS 2002.*, 2002, pp. 37–44.
- [31] B. Bell, T. Williamson, N. Gerber, K. Gavaghan, W. Wimmer, M. Caversaccio, and S. Weber, "In Vitro Accuracy Evaluation of Image-Guided Robot System for Direct Cochlear Access," *Otology & Neurotology*, vol. in review, 2013.
- [32] S. D. Olabariaga and a W. Smeulders, "Interaction in the segmentation of medical images: a survey.," *Medical image analysis*, vol. 5, no. 2, pp. 127–42, Jun. 2001.
- [33] T. M. Williamson, B. J. Bell, N. Gerber, L. Salas, P. Zysset, M. Caversaccio, and S. Weber, "Estimation of tool pose based on force-density correlation during robotic drilling," *IEEE Transactions on Biomedical Engineering*, p. in print.