Check for updates

Case reports/Neuroimages/Videos

CLINICAL and TRANSLATIONAL NEUROSCIENCE

*Clinical & Translational Neuroscience*
January-June 2021: 1–4
© The Author(s) 2021
Article reuse guidelines:
sagepub.com/journals-permissions
DOI: 10.1177/2514183X211020157
journals.sagepub.com/home/ctn
SAGE

# Stroke and splenic infarct in a 17-year-old patient with COVID-associated hypercoagulable state and relative ADAMTS13 deficiency

**Maximilian Pistor[1], Angelika Hoffmann[2], Thomas Horvath[1], Michael Oberholzer[1], Marcel Arnold[1], and Sara Magdalena Pilgram-Pastor[2]**

**Abstract**

In this case report, we present the case of a 17-year-old stroke patient suffering from coronavirus disease (COVID)-19. He was successfully treated with intravenous and endovascular treatment. After extensive work-up, a hypercoagulable state due to the COVID-19 infection was assumed as probable cause of stroke.

**Keywords**

Stroke, endovascular therapy, SARS-CoV2, ADAMTS13, hypercoagulable state, young stroke, COVID-19, COVID

We report the case of an otherwise healthy 17-year-old male patient with acute wake-up stroke. A severe acute respiratory syndrome coronavirus 2 (SARS-CoV2) infection was diagnosed 1 week before, presenting as a febrile disease without clinical respiratory involvement. On awakening, he experienced unilateral weakness and speech difficulties. He presented himself febrile and with a right-sided faciobrachial hemiparesis, a nonfluent aphasia, possible apraxia of speech, and altered mental status in the Emergency Room (10/42 on the NIHSS (National Institutes of Health Stroke Scale).

Initial lab analysis showed an inflammatory profile with elevations in acute phase reactants and marked leukocytosis. We additionally saw a significantly elevated troponin (182 ng/ml, $n < 14$) and B-type natriuretic peptide (BNP; 6847 pg/ml, $n < 115$).

Magnetic resonance imaging (MRI) of the head revealed an acute, Fluid-attenuated inversion recovery (FLAIR)-demarcated stroke in the left middle cerebral artery (MCA)-territory with an occlusion of the MCA in the distal M2/M3-junction (Figure 1(a) and (b)B). In addition, a cytotoxic lesion of the corpus callosum (CLOCC) was identified incidentally (Figure 1(d)).

We conducted an intravenous (i.v.) thrombolysis with alteplase (Actilyse ©; Boehringer-Ingelheim, Germany). Subsequently, endovascular therapy was performed using a stent retriever (catch mini©; BALT-Germany) and proximal aspiration through a balloon guiding catheter leading to successful recanalization (thrombolysis in cerebral infarction III; Figure 1(b)).

The same day, the patient experienced an acute onset of left-sided abdominal pain. A computed tomography (CT)-abdomen showed a partial splenic ischemia, supposedly due to ongoing embolization. He eventually was fully anticoagulated (first with unfractionated heparin), later switched to low-molecular-weight heparin (enoxaparin).

[1] Department of Neurology, Inselspital University Hospital Bern, Bern, Switzerland
[2] Department of Diagnostic and Interventional Neuroradiology, Inselspital University Hospital Bern, Bern, Switzerland

**Corresponding author:**
Maximilian Pistor, Department of Neurology, Inselspital University Hospital Berne, Freiburgstrasse 18, 3010 Bern, Switzerland.
Email: maximilian.pistor@insel.ch

Creative Commons Non Commercial CC BY-NC: This article is distributed under the terms of the Creative Commons Attribution-NonCommercial 4.0 License (https://creativecommons.org/licenses/by-nc/4.0/) which permits non-commercial use, reproduction and distribution of the work without further permission provided the original work is attributed as specified on the SAGE and Open Access pages (https://us.sagepub.com/en-us/nam/open-access-at-sage).

source: https://doi.org/10.48350/157436 | downloaded: 12.10.2024

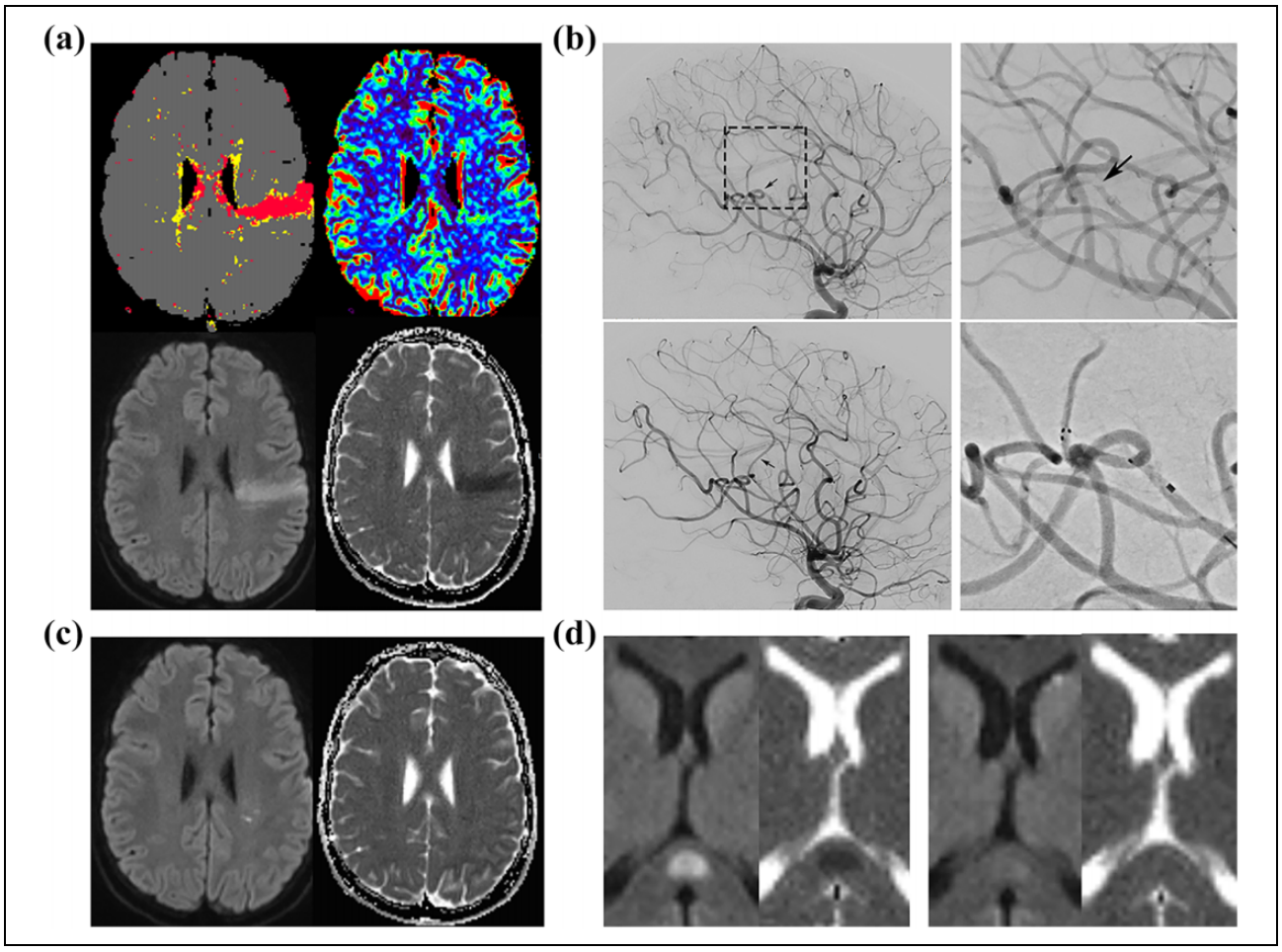


**Figure 1.** Cerebral imaging findings. (a) Tmax and CBV map with FLAIR image and corresponding ADC map illustrating the partial MCA infarction. (b) The occlusion of the left M2/3 junction branch is shown (square and arrow) on the top row. On the bottom row, the successfully recanalized vessel can be appreciated (blue arrow) next to the image with expanded stent retriever. (c) After successful recanalization, subtotal reversal of the ADC lesion was visible. (d) In the initial MRI, a cytotoxic lesion in the splenium of the corpus callosum was additionally present (shown on diffusion-weighted imaging and the corresponding ADC map, left part), which had resolved after 4 days (right part). Additionally, a small, most likely peri-interventional ischemic lesion is visible in the caudate nucleus on the left side on follow-up imaging after 4 days. CBV: cerebral blood volume; FLAIR: fluid-attenuated inversion recovery; ADC: apparent diffusion coefficient; MCA: middle cerebral artery; MRI: magnetic resonance imaging.

A CT chest showed no pulmonary signs of coronavirus disease (COVID)-19 and no sign of pulmonary embolism. The electrocardiogram (ECG) at admission showed non-specific ST- and T-changes, a transthoracic echocardiography showed no wall motion abnormalities and a normal systolic/diastolic heart function as well as no valve abnormalities. With elevations in cardiac biomarkers (troponin and BNP), ECGs changes, and in light of the known cardiotropism of SARS-CoV2, we suspected a subclinical myocardial involvement.

A transesophageal echocardiography showed no intracardiac thrombus or valve vegetations. There were no signs of patent foramen ovale or arteriovenous fistula on "bubble testing." Overall, a paradox-embolic etiology seemed to be unlikely. Blood cultures drawn at admission returned without microbial growth, so even in the context of a strong paraclinical inflammation and fever, endocarditis seemed to be unlikely. Heart-rhythm monitoring (4 days) showed no signs of atrial fibrillation as does the ambulatory Holter-ECG (3 × 7 days). Taken together, we concluded that there were no signs of a cardioembolic etiology of the stroke.

Because of the ongoing embolization (brain and spleen), we decided to not pursue a cerebrospinal fluid analysis (e.g. for a SARS-CoV2 viral load) and therefore pausing the anticoagulation. The absence of radiographic signs of vasculitis in the conventional angiography interventionally, the CLOCC as a sign of a more systemic inflammation process, because of the rapid clinical recovery and the absence of new or suspicious lesions on follow-up imaging additionally argued against an urgent lumbar puncture.

A hemostaseologic evaluation showed relevant elevations of D-dimer (2465 μg/L, $n < 500$) and fibrinogen

(5.26 g/L, $n < 3.75$). Antiphospholipid antibodies were negative.

We saw elevations of von Willebrand factor (vWF)—antigen (257%, *n* (normal range): 42–136%) and activity (236%, *n*: 42–168%) on day 4 after stroke and splenic infarctions. "A disintegrin and metalloproteinase with thrombospondin 13" (ADAMTS13) activity on day 4 was 93% ($n > 51\%$). The vWF-antigen/ADAMTS13 ratio was 2.7. Factor VIII was also markedly elevated 212% (*n*: 55–164%).

The patient recovered rapidly and was afebrile on day 3. The follow-up imaging with MRI showed a timely evolution of the stroke with a small petechial hemorrhage. The CLOCC sign was resolving and was barely visible on the MRI on day 4 (Figure 1(d)). He rapidly left the readaptation clinic and an extensive neuropsychological work-up 3 months after the event revealed no neuropsychological as well as subjective sequelae of the stroke. Enoxaparin was stopped after 4 weeks when hemostaseologic parameters normalized. It was switched to aspirin, although the evidence for secondary prophylaxis in this particular case is not completely clear.

## Discussion

We here presented a case of a young, otherwise healthy, 17-year old with multiple thromboembolic events including a "wake up" MCA-occlusion and splenic infarction, who was tested positive for SARS-CoV2 the week before. He suffered from a febrile illness without clinical or radiographic signs of pulmonary involvement. A subclinical myocardial involvement was additionally suspected (troponin, BNP-elevations, and nonspecific ECG changes). The stroke was successfully treated with i.v. thrombolysis therapy and mechanical recanalization. After extensive work-up, no cardio- or paradox-embolic causes of stroke were identified. We eventually suspected a hypercoagulable state associated with COVID-19.

Thromboembolic events, especially pulmonary embolism, occur frequently in SARS-CoV2 infections and are a significant cause of morbidity and mortality in COVID-19.[1]

Stroke also occurs in COVID-19, especially in older patients with severe disease course and traditional cardiovascular disease risk factors and is as high as 5% in some case series.[2] On the other hand, Yaghi et al. also reported a case series of five young patients suffering from SARS-CoV2 without respiratory symptoms and stroke.[3] A systematic review of Fridman et al. on COVID-19 and stroke cases showed for the younger cohort (<50 years) a high proportion of absent traditional risk factors and comorbidities and higher elevations in troponin and D-dimer.[4]

The latter may represent a sign of hypercoagulability, for which the pathophysiology is not completely understood. SARS-CoV2 is able to infect endothelial cells and cause endotheliitis.[5] As one of several mechanisms, some authors proposed a presumably inflammation-driven endothelial secretion of vWF and reduced cleavage of large vWF-polymers by ADAMT13 with enhanced thrombogenic potential.[6,7]

Also in our patient, we detected elevations of vWF-Ag and factor VIII alongside D-dimer and fibrinogen. The ADAMTS13-activity was normal with a consecutively elevated vWF-Ag/ADAMTS13 ratio (2.7). Elevation of this ratio as a substrate of relative ADAMTS13 deficiency in comparison to vWF as well as factor VIII activation is a possible substrate of COVID hypercoagulability. A recent Italian study showed ratios as high as 8 in severely affected COVID patients on intensive care unit.[8] Ratios above 2.6 in non-COVID stroke patients have been associated with higher mortality in stroke and decrease by thrombolysis therapy.[9] Therefore, hypothetically, the ratio might be even higher prior to the thrombolysis in our patient.

## Concluding remarks

- Thromboembolic events occur frequently in SARS-CoV2, also in young patients without traditional cardiovascular risk factors and without pulmonary or life-threatening systemic involvement.
- CLOCC occurs in the context of COVID and might be due to cytokine storm.[10] It rapidly disappeared in follow-up imaging after resolution of systemic inflammation and fever in our patient.
- Patients with SARS-CoV2-associated hypercoagulability and stroke can effectively be treated by recanalization techniques like i.v. thrombolysis and mechanical thrombectomy.
- vWF and ADAMTS13 with elevated vWF/ADAMTS13 ratios in the context of presumed endothelial damage and endotheliitis might play a role in COVID hypercoagulability.

### Acknowledgments

We thank Paul Bhogal (Department of Interventional Neuroradiology, The Royal London Hospital, London, UK) for his valuable discussion on COVID hypercoagulable state.

### Declaration of conflicting interests

The author(s) declared no potential conflicts of interest with respect to the research, authorship, and/or publication of this article.

### Funding

The author(s) received no financial support for the research, authorship, and/or publication of this article.

### ORCID iD

Maximilian Pistor https://orcid.org/0000-0002-0703-9974

## References


1. Helms J, Tacquard C, Severac F, et al. High risk of thrombosis in patients with severe SARS-CoV-2 infection: a multicenter prospective cohort study. *Intensive Care Med* 2020; 46: 1089–1098.
2. Zhang Y, Xiao M, Zhang S, et al. Coagulopathy and antiphospholipid antibodies in patients with covid-19. *N Engl J Med* 2020; 382: e38.
3. Yaghi S, Ishida K, Torres J, et al. SARS-CoV-2 and stroke in a New York healthcare system. *Stroke* 2020; 51: 2002–2011.
4. Fridman S, Bullrich MB, Jimenez-Ruiz A, et al. Stroke risk, phenotypes, and death in COVID-19: systematic review and newly reported cases. *Neurology* 2020; 95: E3373–E3385.
5. Varga Z, Flammer AJ, Steiger P, et al. Endothelial cell infection and endotheliitis in COVID-19. *Lancet* 2019; 395: 1417–1418.
6. Doevelaar AAN, Bachmann M, Hoelzer B, et al. COVID-19 is associated with relative ADAMTS13 deficiency and VWF multimer formation resembling TTP. *medRxiv* 2020; 2019: 2020.08.23.20177824.
7. Sonneveld MAH, De Maat MPM, Portegies MLP, et al. Low ADAMTS13 activity is associated with an increased risk of ischemic stroke. *Blood* 2015; 126: 2739–2746.
8. Mancini I, Baronciani L, Artoni A, et al. The ADAMTS13-von Willebrand factor axis in COVID-19 patients. *J Thromb Haemost* 2021; 19: 513–521.
9. Taylor A, Vendramin C, Singh D, et al. Von Willebrand factor/ADAMTS13 ratio at presentation of acute ischemic brain injury is predictive of outcome. *Blood Adv* 2020; 4: 398–407.
10. Edjlali M, Le Gal A, Louvet M, et al. Teaching neuroimages: cytotoxic lesions of the corpus callosum (CLOCCs) in encephalopathic patients with COVID-19. *Neurology* 2020; 95: 1021–1022.